

A Nasal Complication of Nasopharyngeal Swab for Reverse Transcription Polymerase Chain Reaction (RT-PCR) Detection of SARS-CoV-2 mRNA

Mario Rigante ¹, Pasqualina M. Picciotti ¹, Claudio Parrilla ¹

1. Department of Otolaryngology - Head and Neck Surgery, Fondazione Policlinico Universitario A. Gemelli Istituto di Ricovero e Cura a Carattere Scientifico (IRCCS) Università Cattolica del Sacro Cuore, Rome, ITA

Corresponding author: Pasqualina M. Picciotti, pasqualinamaria.picciotti@unicatt.it

Abstract

Nasopharyngeal (NP) and oropharyngeal (OP) specimens in the detection of the SARS-Cov-2 RNA are considered to have the highest diagnostic sensitivity and they have been recommended by the World Health Organization as the most reliable test. However, collecting NP specimens require specialized operators and adequate technique.

We describe an intranasal breaking of the nasopharyngeal swab for anatomical reasons needing a surgical removing. We conclude that a safely procedure needs possibly a check for septal deviations or other causes of nasal obstruction.

Categories: Otolaryngology

Keywords: sars-cov-2 mrna, nasopharyngeal swab, covid-19, nasal cavities, complication

Introduction

Nasopharyngeal (NP) and oropharyngeal (OP) specimens in the detection of the SARS-Cov-2 RNA are considered to have the highest diagnostic sensitivity and they have been recommended by the World Health Organization as the most reliable test. However, collecting NP specimens requires specialized operators and adequate technique.

Wang et al. reported that OP swabs were used much more frequently than NP ones in China, however, the SARS-CoV-2 RNA was detected only in 32% of OP swabs, which was significantly lower than that of NP (63%) [1]. A COVID-19 investigation team in the US comparing NP and OP specimens found similar results and the US Centers for Disease Control and Prevention (CDC) recommends collecting the upper respiratory NP swab [2].

Different papers have been recently published in order to define the better way to perform a proper nasal and oropharyngeal swab procedure. A correct technique is essential in the screening of COVID-19 infection [3-5].

Case Presentation

With the approval of the ethics committee of the Fondazione Policlinico Universitario A. Gemelli IRCCS Università Cattolica del Sacro Cuore, we describe a case of intranasal breaking of the nasopharyngeal swab for anatomical reasons needing a surgical removing.

We hereby report the case of a 32-year-old male patient admitted to the intensive care of trauma center after a motorcycle accident during the pandemic time of COVID-19. OP and NP swabs were performed for SARS-CoV-2 RNA test but during the removal by the healthcare professional, part of the swab broke into the right nasal fossa, with nasal bleeding. The ENT (ear, nose and throat) was referred and the anterior rhinoscopy revealed an important septal deviation into the right with a sub occlusion of the nasal cavity. Therefore, a CT scan was performed for the evaluation of cranial trauma and the swab was located in the upper part of nasal cavity (Figure 1) behind the septal deviation, going down to the nasopharynx. Location was confirmed by nasal endoscopy, but it was not easy to perform because of bleeding and septal deviation that did not allow a complete visualization and extraction of the foreign body. For this we performed a mini-septoplasty, and removal of septal spur was followed by removal of the two swab in two fragment (Figure 2).

Review began 05/07/2021

Review ended 05/12/2021

Published 07/05/2021

© Copyright 2021

Rigante et al. This is an open access article distributed under the terms of the Creative Commons Attribution License CC-BY 4.0., which permits unrestricted use, distribution, and reproduction in any medium, provided the original author and source are credited.

How to cite this article

Rigante M, Picciotti P M, Parrilla C (July 05, 2021) A Nasal Complication of Nasopharyngeal Swab for Reverse Transcription Polymerase Chain Reaction (RT-PCR) Detection of SARS-CoV-2 mRNA. Cureus 13(7): e16183. DOI 10.7759/cureus.16183

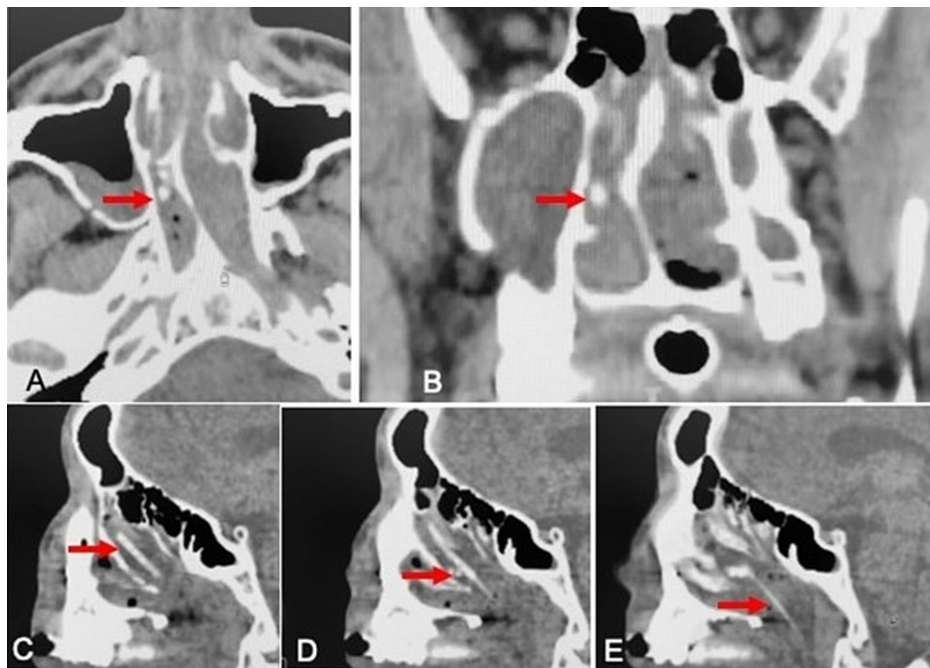


FIGURE 1: CT scan of the nose

CT scan showing the swab (arrow) behind the septal spur in axial and coronal view (A,B) and the entire swab in the sagittal projection (C,D,E) reaching the nasopharynx and after rupture dislocated in the upper part of the nose and also migrated below the middle turbinate.



FIGURE 2: Nasal swab

The extracted swab in two parts after performance of septal spur removal.

Discussion

The described case confirms that NP swab must be carefully performed as described by other authors for detection of SARS-CoV-2 mRNA avoiding false negative findings [3, 5].

Recent papers by Piras et al. [5] described that nasopharyngeal swabbing could be considered as a trivial procedure, and an inappropriate nasopharyngeal sampling, performed by untrained operators, can cause false negative findings and, it can expose healthcare workers and patients to risks of contagion. Di Maio et al. [3] and Petrucci et al. [4] also described how to correctly collect sample by nasopharyngeal (NP) swab in order to avoid false negative.

Another subject related to NP swab is possible complications of the procedure. Nasal traumatism related to NP swab can be due to an unfavorable anatomy as we showed. An accurate anterior rhinoscopy is useful to evaluate the opening of the nasal fossa and to guide the operator in the correct execution of the swab. Nasal obstruction can be due to common conditions (septal deviations and/or turbinate hypertrophy) previously evaluated by a physician familiar with the nasal anatomy.

Recently, iatrogenic cerebrospinal fluid fistulas have also been described after nasal swab for COVID-19 [6-8]. The authors hypothesized that improper technique where the swab is not entered parallel to the palate

due to incorrect head tilt increases the risk of complications. As a possible mechanism in fistulas and in our case the swab was not inserted horizontally but in upwards direction. Moreover, it is necessary to be very careful in cases of maxillofacial trauma due to the possible bone modifications that can predispose to important complications.

In our personal experience, we also can argue that septal deviation caused the swab rupture during the removal from the nose, and finally another possible problem is related to the position: our patient was lying on the bed and not sitting.

A final consideration is about the bilaterally swab sampling. There is a significant heterogeneity in guidance for nasopharyngeal swab performance unilaterally or bilaterally. Recent guidelines of the CDC for collecting nasal specimen (Updates on February 2021) [9] described the position head (back 70 degrees), the performance modality until resistance is encountered or the distance is equivalent to that from the ear to the nostril of the patient. These indications also claimed that specimens can be collected from both sides but it is not necessary if a deviated septum or blockage creates difficulty in obtaining the specimen from one nostril. In this condition, the same swab should be used to obtain the specimen from the other nostril.

Our experience confirms this indication: in presence of an apparent septal deviation and or a difficulty introducing the swab, it can be performed only in the more patent nasal fossa, to avoid nasal traumatism and potential swab rupture.

Conclusions

A safely procedure needs possibly a check for septal deviations, other causes of nasal obstruction or nasal traumatism. A correct procedure should be performed, and when the operator finds obstacle in the insertion of swab in one nostril it should be carried out carefully in the most patent nasal fossa, without forcing or pointing the swab upwards both incoming and outgoing.

Additional Information

Disclosures

Human subjects: Consent was obtained or waived by all participants in this study. **Conflicts of interest:** In compliance with the ICMJE uniform disclosure form, all authors declare the following: **Payment/services info:** All authors have declared that no financial support was received from any organization for the submitted work. **Financial relationships:** All authors have declared that they have no financial relationships at present or within the previous three years with any organizations that might have an interest in the submitted work. **Other relationships:** All authors have declared that there are no other relationships or activities that could appear to have influenced the submitted work.

References

1. Wang W, Tang J, Wei F: Updated understanding of the outbreak of 2019 novel coronavirus (2019-nCoV) in Wuhan, China. *J Med Virol*. 2020, 92:441-447. [10.1002/jmv.25689](https://doi.org/10.1002/jmv.25689)
2. Kujawski S, Wong KK, Collins JP, et al.: Clinical and virologic characteristics of the first 12 patients with coronavirus disease 2019 (COVID-19) in the United States. *Nat Med*. 2020, 26:861-868. [10.1038/s41591-020-0877-5](https://doi.org/10.1038/s41591-020-0877-5)
3. Di Maio P, Iocca O, Cavallero A, Giudice M: Performing the nasopharyngeal and oropharyngeal swab for 2019-novel coronavirus (SARS-CoV-2) safely: how to dress, undress, and technical notes. *Head Neck*. 2020, 42:1548-1551. [10.1002/hed.26230](https://doi.org/10.1002/hed.26230)
4. Petruzzi G, De Virgilio A, Pichi B, et al.: COVID-19: nasal and oropharyngeal swab. *Head Neck*. 2020, 42:1503-1504. [10.1002/hed.26212](https://doi.org/10.1002/hed.26212)
5. Piras A, Rizzo D, Longoni E, et al.: Nasopharyngeal swab collection in the suspicion of Covid-19. *Am J Otolaryngol*. 2020, 41:102551. [10.1016/j.amjoto.2020.102551](https://doi.org/10.1016/j.amjoto.2020.102551)
6. Sullivan CB, Schwalje AT, Jensen M, Li L, Dlouhy BJ, Greenlee JD, Walsh JE: Cerebrospinal fluid leak after nasal swab testing for coronavirus disease 2019. *JAMA Otolaryngol Head Neck Surg*. 2020, 146:1179-1181. [10.1001/jamaoto.2020.3579](https://doi.org/10.1001/jamaoto.2020.3579)
7. Alberola-Amores FJ, Valdeolivas-Urbelz E, Torregrosa-Ortiz M, Álvarez-Sauco M, Alom-Poveda J: Meningitis due to cerebrospinal fluid leak after nasal swab testing for COVID-19 (PREPRINT). *Eur J Neurol*. 2021, [10.1111/ene.14736](https://doi.org/10.1111/ene.14736)
8. Rajah J, Lee J: CSF rhinorrhoea post COVID-19 swab: a case report and review of literature. *J Clin Neurosci*. 2021, 86:6-9. [10.1016/j.jocn.2021.01.003](https://doi.org/10.1016/j.jocn.2021.01.003)
9. CDC. Interim guidelines for collecting and handling of clinical specimens for COVID-19 testing. (2021). Accessed: February 26, 2021; <https://www.cdc.gov/coronavirus/2019-ncov/lab/guidelines-clinical-specimens.html>.