

## Delayed severe bleeding complications after treatment of pancreatic fluid collections with lumen-apposing metal stents

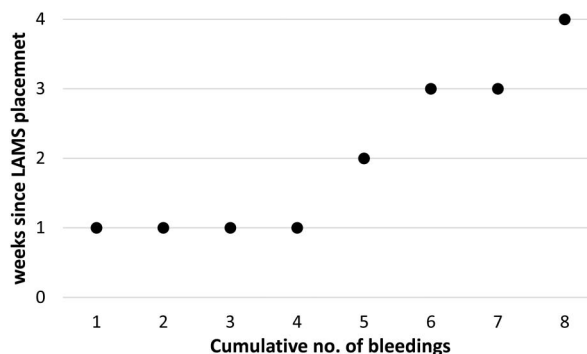
With interest we read the paper by Bang *et al.*<sup>1</sup> who observed delayed severe adverse events after endoscopic treatment of pancreatic fluid collections (PFCs) with the Hot AXIOS lumen-apposing metal stent (LAMS), which was unrelated to the initial procedure, in a randomised controlled trial. LAMS are increasingly used for transmural endoscopic ultrasound-guided drainage of PFC and infected walled-off pancreatic necrosis (WOPN).<sup>2</sup> Procedure associated bleeding is a frequent adverse event after transmural drainage.<sup>3</sup> While our experience confirms our colleagues' findings we would like to emphasize

that complications are not restricted to Hot AXIOS stents and that certain insertion techniques may be more prone to early bleeding while non-pigtail, LAMS can cause late bleeding complications.

From June 2013 to October 2016, we treated 46 patients with LAMS (8×Hot AXIOS 15×10 mm (Boston Scientific); 38×TAEWOONG MEDICAL Niti-S biliary covered stent (NAGI) 10.5F 14×20 mm) for infected WOPNs. The overall 90-day mortality of our 46 patients was 8.7%, median APACHE score at intervention was 17. Bleeding complications occurred in eight patients (17.4%) (figure 1), five of which suffered from multiorgan failure (table 1). Two of these patients died because bleeding persisted after unsuccessful coiling and surgery (two out of eight, 25%). Seven of these patients received treatment with NAGI-S stents and one patient was treated with a Hot AXIOS stent. In three cases treated with NAGI-S stents, the GI bleeding occurred within the first 24 hours after LAMS placement leading to haemorrhagic shock controlled

by conservative measures. In these cases, balloon dilatation of the access route had caused injury to gastric veins. In five patients we observed delayed bleeding into the necrotic cavity over a period of up to 5 weeks after LAMS placement (62.5% of bleeders or 11% of all patients treated with LAMS). The mean time from LAMS placement to bleeding was 9.5±9.8 days (2.7; 16.3). In 3 of the 48 patients the metal stent dislocated. However, in all cases stent removal was achieved endoscopically without further complications. One patient suffered from visceral organ perforation by the stent without the need for surgery. In our series we did not observe other severe adverse events such as buried LAMS syndrome or biliary strictures.

The high rate of early bleeding complications in patients receiving the Niti-S biliary covered stent seems to be caused by the different placement procedure. For the placement of the Niti-S stent, the stomach wall is dilated with a balloon catheter to up to 8 mm over a guide wire



**Figure 1** Scatter plot showing timing and incidence of bleeding complications following lumen-apposing metal stent (LAMS) treatment over time.

**Table 1** Characteristics of patients with bleeding complications

No	Age	Aetiology	Time from onset of symptoms to intervention	Cultured germ WOPN	Organ failure	Coagulopathy	Time to first bleed (days)	Outcome
1	75	WOPN, biliary	30 days	<i>C. albicans</i> <i>E. faecium</i>	Respiratory, renal, circulatory	Thrombocytopenia	1	Passed away
2	47	WOPN, alcoholic	28 days	n.d., ongoing antibiotic treatment	None	None	1	Alive
3	65	WOPN, alcoholic, underlying chronic pancreatitis	61 days	<i>E. faecium</i>	Respiratory	None	1	Alive
4	53	WOPN, biliary	35 days	<i>E. faecium</i>	Respiratory, renal, circulatory	Yes	15	Passed away
5	79	WOPN, alcoholic	25 days	<i>E. faecium</i>	Circulatory	None	17	Alive
6	54	Infected pseudocyst, alcoholic, chronic pancreatitis	>3 months	n.d., ongoing antibiotic treatment	None	None	28	Alive
7	66	WOPN, alcoholic	32 days	<i>E. faecium</i>	Respiratory, renal, circulatory	Yes	8	Passed away
8	54	WOPN, underlying alcoholic chronic pancreatitis	>3 months	<i>E. faecium</i>	Respiratory, renal, circulatory	None	5	Alive

*C. albicans*, *Candida albicans*; *E. faecium*, *Enterococcus faecium*; n.d., not detected; WOPN, walled-off pancreatic necrosis.

causing early bleeding. Five of our patients suffered from multiorgan failure and, even in the absence of coagulopathy, this seems to be a risk factor of its own—while being an indication for draining an infected necrosis in the first place. Of note, 80% of our patients with delayed bleeding events needed angiographic intervention of the left gastric artery. As coiling of the left gastric artery very rarely induces necrotic changes to the stomach prophylactic coiling in high-risk patients (persistent multiorgan failure, coagulopathy and metabolic acidosis) in whom LAMS are kept in place for more than 21 days should be prospectively studied. Exchanging LAMS for plastic pigtail stents before hospital discharge of a patient with LAMS drainage of WOPN may be even more feasible and could reduce late bleeding. Diffuse late bleeding often occurs in patients with a nearly clean necrotic cavity, in the absence of signs of systemic inflammation and after a final mechanical cleansing of the cavity. How complete the removal of the necrotic debris from a WOPN should be remains a point for further investigation.

SS Stecher,<sup>1</sup> P Simon,<sup>2</sup> S Friesecke,<sup>1</sup> A Glitsch,<sup>3</sup> JP Kühn,<sup>4</sup> MM Lerch,<sup>2</sup> J Mayerle<sup>5</sup>

<sup>1</sup>Department of Medicine B, University Medicine, Ernst-Moritz-Arndt-University, Greifswald, Germany

<sup>2</sup>Department of Medicine A, University Medicine, Ernst-Moritz-Arndt-University, Greifswald, Germany

<sup>3</sup>Department of General Surgery, University Medicine, Ernst-Moritz-Arndt-University, Greifswald, Germany

<sup>4</sup>Institute of Radiology, University Medicine, Ernst-Moritz-Arndt-University, Greifswald, Germany

<sup>5</sup>Medizinische Klinik und Poliklinik II, Klinikum der LMU, München-Grosshadern, Munich, Germany

**Correspondence to** Dr Julia Mayerle, Medizinische Klinik und Poliklinik II, Klinikum der LMU München-Grosshadern, Anstalt des öffentlichen Rechts, Marchioninstr. 15, München D-81377, Germany; julia.mayerle@med.uni-muenchen.de

**Contributors** SSS and JM have compiled the clinical data. JPK has provided angiography pictures and was involved in patients' care. SF was the responsible consultant intensivist, JM, PS and MML have designed the manuscript. The manuscript was drafted by SSS and JM and reviewed by all authors.

**Funding** This work was supported by the Deutsche Krebshilfe/Dr Mildred-Scheel-Stiftung (109102), the Deutsche Forschungsgemeinschaft (DFG MA 4115/1-2/3), the Federal Ministry of Education and Research (BMBF GANI-MED 03IS2061A and BMBF 0314107, 01ZZ9603, 01ZZ0103, 01ZZ0403, 03ZIK012) and the European Union (EU-FP-7: EPC-TM).

**Competing interests** None declared.

**Provenance and peer review** Not commissioned; internally peer reviewed.



CrossMark

**To cite** Stecher SS, Simon P, Friesecke S, *et al.* *Gut* 2017;**66**:1871–1872.

Received 12 December 2016

Revised 20 December 2016

Accepted 21 December 2016

Published Online First 12 January 2017

*Gut* 2017;**66**:1871–1872.

doi:10.1136/gutjnl-2016-313562

## REFERENCES

- 1 Bang JY, Hasan M, Navaneethan U, *et al.* Lumen-apposing metal stents (LAMS) for pancreatic fluid collection (PFC) drainage: may not be business as usual. *Gut* 2016. doi:10.1136/gutjnl-2016-312812. [Epub ahead of print 31 Aug 2016].
- 2 Fabbri C, Luigiano C, Maimone A, *et al.* Endoscopic ultrasound-guided drainage of pancreatic fluid collections. *World J Gastrointest Endosc* 2012;**4**:479–88.
- 3 Vazquez-Sequeiros E, Baron TH, Pérez-Miranda M, *et al.* Evaluation of the short- and long-term effectiveness and safety of fully covered self-expandable metal stents for drainage of pancreatic fluid collections: results of a Spanish nationwide registry. *Gastrointest Endosc* 2016;**84**:450–7.e2.