

Clinical Letter

Eyelash depigmentation in a patient with metastasized melanoma

DOI: 10.1111/ddg.14806

Dear Editors,

vitiligo-like dermatoses are frequently described side effects under anti-PD1 and anti-CTLA4 therapy of metastatic melanoma [1]. Its occurrence has often been described as a prognostically favorable outcome parameter and serves as an impressive example of the relationship between tumor response and autoimmunity [2].

We report on a 61-year-old female patient who presented to our outpatient clinic for tumor follow-up. In September 2011, a malignant melanoma with a tumor thickness of 2.3 mm was excised on the right abdominal side with a safety margin of 2 cm. Detection of melanoma cells in the axillary and right inguinal sentinel lymph nodes prompted lymph node dissection at both sites, without evidence of melanoma cells in the resected tissue. In October 2017, an elevated serum level of the tumor marker S100 was detected. The subsequent positron emission tomography-computed tomography (PET-CT) scan showed newly appeared melanoma metastases in the mediastinal, hilar, and inguinal lymph nodes as well as lung and spleen metastases. In January 2018, systemic therapy was initiated with the anti-CTLA-4 antibody ipilimumab and the anti-PD-1 antibody nivolumab. After two rounds of immunotherapy, the patient observed depigmentation of individual eyelashes (Figure 1). We made a diagnosis

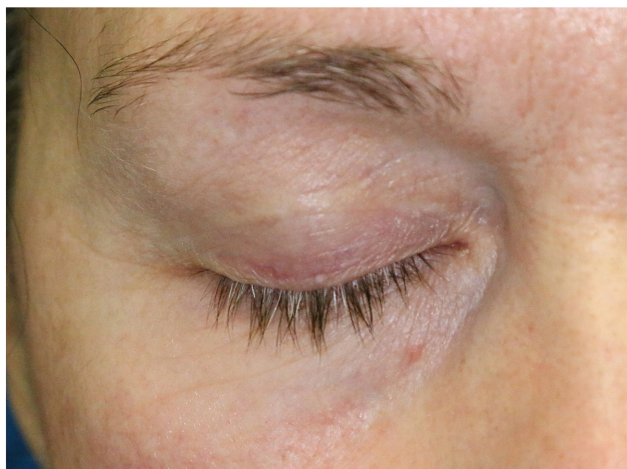


Figure 1 Depigmentation of individual eyelashes after two rounds of immunotherapy.

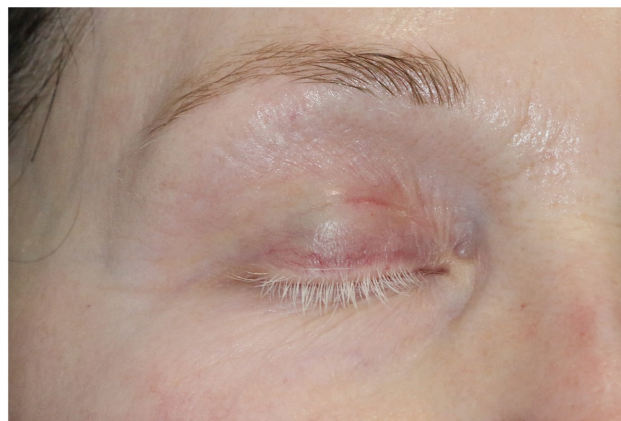


Figure 2 Complete depigmentation of eyelashes after termination of therapy.

of leukotrichia induced by immunotherapy with checkpoint inhibitors. Three years later, after cessation of therapy, there was complete discoloration of the eyelashes (Figure 2) and vitiligo on the entire integument.

Vitiligo is a disease with a prevalence of 0.5-2 % worldwide. Leukotrichia as a circumscribed white coloration of the hair is considered a special form of vitiligo. The loss of melanocytes results in the appearance of depigmented macules and, with involvement of hair follicles, leukotrichia [3]. There is evidence that melanocytes in vitiligo lesions are particularly sensitive to hazardous noxae such as UV radiation or chemicals [4]. Exposure leads to the generation of reactive oxygen species (ROS), which can trigger programmed cell death. In addition, immunological factors play a pathogenetic role, which explains the association of vitiligo with other autoimmune diseases. Increased numbers of CD8+ T cells are found in perilesional skin as well as in the vitiligo lesions. Furthermore, T lymphocytes directed against melanocytic antigens, expressing the inflammatory mediators tumor necrosis factor- α (TNF- α) and interferon- γ (IFN- γ), could be detected in the blood of patients. In addition, natural killer cells, which are increased in both skin and blood in patients with vitiligo, also activate lymphocytes, the melanocyte-destroying effect of which is enhanced by IFN- γ [5].

The clinical manifestation of non-segmental vitiligo (NSV) is sharply demarcated white macules. It usually begins with bilateral symmetry on the extensor sides of the extremities as well as in the intertrigines or even periorally. The predilection sites can be explained by mechanical irritation provoking the skin change (Köbner phenomenon). Leukotrichia may occur in the vitiligo lesions and is a prognostically unfavorable factor [5].

The incidence of vitiligo as a side effect of checkpoint inhibitors is estimated to be as high as 25 % [6]. In these cases, vitiligo appears after a mean of five months and

often manifests with bilateral symmetry [1]. This form differs in clinical presentation from classic vitiligo. Here, the hypopigmented macules show a speckled distribution pattern and may coalesce into plaques. Rather than in mechanically stressed areas, the predilection sites are found on light-exposed skin. The association with autoimmune diseases and familial predisposition play a minor role [6, 7]. Depigmentation of hair may be concomitant or occur in isolation [1].

It may reasonably be assumed that vitiligo in the context of antibody therapy in melanoma patients has a different immune-mediated pathogenesis than classical vitiligo. Increased CXCR3+ CD8- T-cell infiltrates have been found in vitiligo lesions resulting from melanoma therapy [7]. The same T-cell clones could also be detected in melanoma metastases [8]. Melanoma cells and melanocytes express proteins such as TRP-1 (tyrosinase and related proteins, gp75) and TRP-2 (dopachrome tautomerase) as well as gp100 and melan-A [9]. CD8+ cells attack both tumor cells and melanocytes, leading to the development of hypopigmented areas [2].

Patients who develop vitiligo with checkpoint inhibition have a twofold lower risk of tumor progression than those without vitiligo. The risk of dying from melanoma is even fourfold lower [10]. Moreover, partial or complete remission of melanoma is associated with a higher likelihood of developing vitiligo [6]. Response rates to therapy ranged from 44 % to 73 %. Complete remission occurred in 22–26 % of patients [2, 8].

In the presented case, the development of leukotrichia is also associated with a good response to melanoma therapy. By August 2019, our patient had received 13 rounds of immunotherapy, resulting in a complete remission of the disease. Fortunately, there has since been no indication of disease progression.

Acknowledgement

Open access funding enabled and organized by Projekt DEAL.

Conflict of interest

None.

**Veronika Zenderowski, Konstantin Drexler,
Mark Berneburg, Sebastian Haferkamp**

Department of Dermatology, University Hospital Regensburg, Regensburg, Germany

Correspondence to

Priv.-Doz. Dr. med. Sebastian Haferkamp
Klinik und Poliklinik für Dermatologie
Universitätsklinikum Regensburg

Franz-Josef-Strauß-Allee 11
93053 Regensburg

E-mail: sebastian.haferkamp@ukr.de

References

- 1 Sibaud V. Dermatologic reactions to immune checkpoint inhibitors: skin toxicities and immunotherapy. *Am J Clin Dermatol* 2018; 19(3): 345–61.
- 2 Guida M, Strippoli S, Maule M et al. Immune checkpoint inhibitor associated vitiligo and its impact on survival in patients with metastatic melanoma: an Italian Melanoma Intergroup study. *ESMO Open* 2021; 6(2): 100064.
- 3 Bergqvist C, Ezzedine K. Vitiligo: a review. *Dermatology* 2020; 236(6): 571–92.
- 4 Harris JE. Cellular stress and innate inflammation in organ-specific autoimmunity: lessons learned from vitiligo. *Immunol Rev* 2016; 269(1): 11–25.
- 5 Deutsche Dermatologische Gesellschaft e. V. (DDG). S1-Leitlinie Diagnostik und Therapie der Vitiligo AWMF-Register-Nr.: 013–093, 2021 ICD-10 Code: L80.X [Internet]. Available from: https://www.awmf.org/uploads/tx_szleitlinien/013-093l_S1_Diagnostik-Therapie-Vitiligo_2021-04.pdf [Last accessed March 31, 2022].
- 6 Stauner CT, Drexler K, Berneburg M, Haferkamp S. Complete response to pembrolizumab after initial progress in a patient with metastatic uveal melanoma. *J Dtsch Dermatol Ges* 2018; 16(11): 1376–8.
- 7 Larsabal M, Marti A, Jacquemin C et al. Vitiligo-like lesions occurring in patients receiving anti-programmed cell death-1 therapies are clinically and biologically distinct from vitiligo. *J Am Acad Dermatol* 2017; 76(5): 863–70.
- 8 Nakamura Y, Tanaka R, Asami Y et al. Correlation between vitiligo occurrence and clinical benefit in advanced melanoma patients treated with nivolumab: A multi-institutional retrospective study. *J Dermatol* 2017; 44(2): 117–22.
- 9 Byrne KT, Turk MJ. New perspectives on the role of vitiligo in immune responses to melanoma. *Oncotarget* 2011; 2(9): 684–94.
- 10 Teulings H-E, Limpens J, Jansen SN et al. Vitiligo-like depigmentation in patients with stage III–IV melanoma receiving immunotherapy and its association with survival: a systematic review and meta-analysis. *J Clin Oncol* 2015; 33(7): 773–81.