

University of Nebraska - Lincoln

DigitalCommons@University of Nebraska - Lincoln

---

USDA Wildlife Services - Staff Publications

U.S. Department of Agriculture: Animal and  
Plant Health Inspection Service

---

7-1-2022

## Comparative susceptibility of eastern cottontails and New Zealand white rabbits to classical rabbit haemorrhagic disease virus (RHDV) and RHDV2

Fawzi Mohamed

USDA ARS Plum Island Animal Disease Center, Fawzi.Mohamed@usda.gov

Thomas Gidlewski

USDA Animal and Plant Health Inspection Service (APHIS)

Mary L. Berninger

USDA ARS Plum Island Animal Disease Center

Heather M. Petrowski

USDA ARS Plum Island Animal Disease Center

Follow this and additional works at: [https://digitalcommons.unl.edu/icwdm\\_usdanwrc](https://digitalcommons.unl.edu/icwdm_usdanwrc)



Alexa J. Bracht  
Part of the Natural Resources and Conservation Commons, Natural Resources Management and  
USDA ARS Plum Island Animal Disease Center

Policy Commons, Other Environmental Sciences Commons, Other Veterinary Medicine Commons,  
Population Biology Commons, Terrestrial and Aquatic Ecology Commons, Veterinary Infectious Diseases  
See next page for additional authors and Immunobiology Commons, Veterinary Preventive Medicine,  
Epidemiology, and Public Health Commons, and the Zoology Commons

---

Mohamed, Fawzi; Gidlewski, Thomas; Berninger, Mary L.; Petrowski, Heather M.; Bracht, Alexa J.; de Rueda, Carla Bravo; Barrette, Roger W.; Grady, Meredith; O'Hearn, Emily S.; Lewis, Charles E.; Moran, Karen E.; Sturgill, Tracy L.; Capucci, Lorenzo; and Root, J. Jeffrey, "Comparative susceptibility of eastern cottontails and New Zealand white rabbits to classical rabbit haemorrhagic disease virus (RHDV) and RHDV2" (2022). *USDA Wildlife Services - Staff Publications*. 2593.  
[https://digitalcommons.unl.edu/icwdm\\_usdanwrc/2593](https://digitalcommons.unl.edu/icwdm_usdanwrc/2593)

This Article is brought to you for free and open access by the U.S. Department of Agriculture: Animal and Plant Health Inspection Service at DigitalCommons@University of Nebraska - Lincoln. It has been accepted for inclusion in USDA Wildlife Services - Staff Publications by an authorized administrator of DigitalCommons@University of Nebraska - Lincoln.

---

## Authors

Fawzi Mohamed, Thomas Gidlewski, Mary L. Berninger, Heather M. Petrowski, Alexa J. Bracht, Carla Bravo de Rueda, Roger W. Barrette, Meredith Grady, Emily S. O'Hearn, Charles E. Lewis, Karen E. Moran, Tracy L. Sturgill, Lorenzo Capucci, and J. Jeffrey Root



---



U.S. Department of Agriculture  
Animal and Plant Health Inspection Service  
Wildlife Services

U.S. Government Publication

---

## ORIGINAL ARTICLE

# Comparative susceptibility of eastern cottontails and New Zealand white rabbits to classical rabbit haemorrhagic disease virus (RHDV) and RHDV2

Fawzi Mohamed<sup>1</sup>  | Thomas Gidlewski<sup>2</sup> | Mary L. Berninger<sup>1</sup> | Heather M. Petrowski<sup>1</sup> | Alexa J. Bracht<sup>1</sup> | Carla Bravo de Rueda<sup>1</sup> | Roger W. Barrette<sup>1</sup> | Meredith Grady<sup>2</sup> | Emily S. O'Hearn<sup>1</sup> | Charles E. Lewis<sup>1</sup>  | Karen E. Moran<sup>1</sup> | Tracy L Sturgill<sup>3</sup> | Lorenzo Capucci<sup>4</sup>  | J. Jeffrey Root<sup>5</sup> 

<sup>1</sup> United States Department of Agriculture, Animal and Plant Health Inspection Service, Foreign Animal Disease Diagnostic Laboratory, Plum Island Animal Disease Center, Greenport, New York, USA

<sup>2</sup> United States Department of Agriculture, Animal and Plant Health Inspection Service, Wildlife Services, National Wildlife Disease Program, Fort Collins, Colorado, USA

<sup>3</sup> United States Department of Agriculture, Animal and Plant Health Inspection Service, Veterinary Services, Regionalization Evaluation Services, Raleigh, North Carolina, USA

<sup>4</sup> Istituto Zooprofilattico Sperimentale della Lombardia e dell'Emilia Romagna and OIE Reference Laboratory for Rabbit Hemorrhagic Disease, Brescia, Italy

<sup>5</sup> United States Department of Agriculture, Animal and Plant Health Inspection Service, Wildlife Services, National Wildlife Research Center, Fort Collins, Colorado, USA

## Correspondence

Fawzi Mohamed, United States Department of Agriculture, Animal and Plant Health Inspection Service, Foreign Animal Disease Diagnostic Laboratory, Plum Island Animal Disease Center, Greenport, NY 11944, USA.  
Email: [Fawzi.Mohamed@usda.gov](mailto:Fawzi.Mohamed@usda.gov)

## Funding information

U.S. Department of Agriculture, Animal and Plant Health Inspection Service

## Abstract

Rabbit haemorrhagic disease virus (RHDV) is associated with high morbidity and mortality in the European rabbit (*Oryctolagus cuniculus*). In 2010, a genetically distinct RHDV named RHDV2 emerged in Europe and spread to many other regions, including North America in 2016. Prior to this study it was unknown if eastern cottontails (ECT(s); *Sylvilagus floridanus*), one of the most common wild lagomorphs in the United States, were susceptible to RHDV2. In this study, 10 wild-caught ECTs and 10 New Zealand white rabbits (NZWR(s); *O. cuniculus*) were each inoculated orally with either RHDV (RHDVa/GI.1a;  $n = 5$  per species) or RHDV2 (a recombinant GI.1bP-GI.2;  $n = 5$  per species) and monitored for the development of disease. Three of the five ECTs that were infected with RHDV2 developed disease consistent with RHD and died at 4 and 6 days post-inoculation (DPI). The RHDV major capsid protein/antigen (VP60) was detected in the livers of three ECTs infected with RHDV2, but none was detected in the ECTs infected with RHDV. Additionally, RHD viral RNA was detected in the liver, spleen, intestine and blood of ECTs infected with RHDV2, but not in the ECTs infected with RHDV. RHD viral RNA was detected in urine, oral swabs and rectal swabs in at least two of five ECTs infected with RHDV2. One ECT inoculated with RHDV2 seroconverted and developed a high antibody titre by the end of the experimental period (21 DPI). ECTs inoculated with the classic RHDV did not seroconvert. In comparison, NZWRs inoculated with RHDV2 exhibited high mortality (five of five) at 2 DPI and four of five NZWRs inoculated with RHDV either died or were euthanized at 2 DPI indicating both of these viruses were highly pathogenic to this species. This experiment indicates that ECTs are susceptible to RHDV2 and can shed viral RNA, thereby suggesting this species could be involved in the epidemiology of this virus.

## KEYWORDS

Eastern cottontail, experimental infection, lagomorpha, New Zealand white rabbit, *Oryctolagus*, pathology, rabbit haemorrhagic disease virus, rabbit haemorrhagic disease virus 2, *Sylvilagus*

## 1 | INTRODUCTION

Rabbit haemorrhagic disease (RHD) is a highly contagious fatal disease of the European rabbit (*Oryctolagus cuniculus*) caused by rabbit haemorrhagic disease virus (RHDV), a member of the family *Caliciviridae*, genus *Lagovirus* (Abrantes et al., 2012; Capucci et al., 2020). RHDV is non-cultivable in cell culture (Abrantes et al., 2012); therefore, detection of virus genome, virions, antigens or antibodies is required for diagnosis. In 2010, a new *Lagovirus* named RHDV2 emerged in France and has since been detected in many European countries, North America, the Middle East, North Africa, Australia and New Zealand (Ambagala et al., 2021; Le Gall-Reculé et al., 2011; Le Gall-Reculé et al., 2013).

Several naturally occurring recombination events have been reported between the new emergent virus and pathogenic and non-pathogenic strains that served as donors for the viral non-structural proteins. The recombination breakpoint is often located at the 5' region of VP60 and divides the genome into one that encodes the structural protein and another that encodes the major and minor structural proteins, VP60 and VP10, respectively (Abrantes et al., 2020; Mahar et al., 2018; Silvério et al., 2018). This recombination plays an important role in generating diversity in emerging RHD viruses (Lopes et al., 2015).

Based on a new nomenclature, the classical RHDV was classified under the genotype G1.1 and RHDV2 under genotype G1.2 (Le Pendu et al., 2017). These two viruses will be referred to as RHDV and RHDV2 hereinafter. The United States had several sporadic RHDV outbreaks starting in 2000, all of which were caused by RHDV (variant RHDVa) (McIntosh et al., 2007). The first report of RHDV2 in North America was in Quebec, Canada, in 2016 (Ambagala et al., 2021). Additional RHDV2 outbreaks occurred on Vancouver Island and other areas of British Columbia, Canada, in 2018, causing high mortality rates in feral and domestic European rabbits (Ambagala et al., 2021). The emergent virus first appeared in the United States in 2018 in a domestic rabbit in Ohio (USDA, 2018), over 1 year after the current study was conducted. As with many outbreaks of RHD, the source of this incident was inconclusive (USDA, 2019).

RHDV2 has a capsid protein sequence identity of approximately 82% with RHDV and a distinct antigenic profile. RHDV2 has the capacity to cause disease in RHDV-vaccinated and young domestic European rabbits less than 30 days-old, while RHDV was known to only cause clinical disease in rabbits 6 weeks of age or older (Dalton et al., 2014; Dalton et al., 2012). Overall, RHDV2 appears to have a broader host range, as it has been reported to affect Cape hares (*Lepus capensis* subsp. *mediterraneus*), European brown hares (*Lepus europaeus*), Italian hares (*Lepus corsicanus*), mountain hares (*Lepus timidus*) and Iberian hares (*Lepus granatensis*) (Le Gall-Reculé et al., 2017; Neimanis et al., 2018; Puggioni et al., 2013; Velarde et al., 2021; Velarde et al., 2017). The host range appears to be determined by the specific expression of glycan motifs in the upper respiratory and digestive tract. Interestingly, the B and H types that are expressed by ECT can bind to RHDV2 (Lopes et al., 2018). A recent outbreak that was first detected in 2020 in the southwestern United States and Mexico expanded the list of susceptible species further to include black-tailed jackrabbits (*Lepus californi-*

*cus*), antelope jackrabbits (*Lepus alleni*), desert cottontail rabbits (*Sylvilagus audubonii*), eastern cottontail rabbits (ECT; *Sylvilagus floridanus*) and mountain cottontail rabbits (*Sylvilagus nuttallii*) (USDA, 2020).

RHDV2 was originally reported to be less virulent than RHDV (Le Gall-Reculé et al., 2013); however, subsequent outbreaks appeared to demonstrate a mortality rate comparable to that of RHDV (Capucci et al., 2017; Hall et al., 2021). Previously, ECTs (*S. floridanus*) were reported to be resistant to RHDV (Lavazza et al., 2015) and field evidence suggested they do not play a role as reservoirs for this virus (D'angelo et al., 2019). However, it was unknown how RHDV2 would affect this species prior to the current study. The objective of this study was to assess the susceptibility of ECTs to RHDV2 and compare the pathogenicity of the virus in ECTs to that found in New Zealand white rabbits (NZWRs). For comparative purposes, we also assessed the pathogenicity of classical RHDV in ECTs and NZWRs.

## 2 | MATERIALS AND METHODS

### 2.1 | Animals

Twelve specific-pathogen-free 6-8-week-old male NZWRs were obtained from a commercial breeding farm (Millbrook Labs, Amherst, MA). Eleven wild caught ECTs were trapped and collected from Long Island, New York, under the authority of a scientific collection permit from the New York Department of Environmental Conservation. The 11 ECTs were assessed to be sub-adults or adults at their time of capture with masses ranging from 0.33 to 1.16 Kg. Three male and two female ECTs were used in each treatment group. All rabbits were acclimated for a minimum of 5 days before the start of the experiment.

### 2.2 | Viruses

The RHDV (RHDVa; G1.1a; GenBank accession number EU003578) used for inoculum in this study was obtained as a liver homogenate derived from the 2005 Indiana, U.S. outbreak (McIntosh et al., 2007). The virus was passaged once in a NZWR. The RHDV2 used in this study was obtained from the OIE Reference Laboratory for Rabbit Haemorrhagic Disease (Istituto Zooprofilattico Sperimentale della Lombardia e dell'Emilia Romagna, Brescia, Italy), and was originally derived from an outbreak in southern Italy in 2014. This virus is a recombinant virus (G1.1bP-G1.2) between classical RHDV (G1.1b) and RHDV2 (G1.2) with a 99% shared nucleotide identity with a recombinant strain identified in Portugal (GenBank accession number KM115716). This virus will be referred to as RHDV2 hereinafter.

### 2.3 | Sequence analysis of viruses

Liver homogenates were processed for next generation sequencing based on previously described methods (Wang et al., 2003). RNA extraction, cDNA synthesis and library preparation were performed

also as previously described (Bracht et al., 2016). Briefly, DNase treatment (DNase I, Invitrogen) was used prior to the first strand synthesis of cDNA, which was performed with random primers and Superscript III reverse transcriptase (Invitrogen) at 50°C for 30 min, followed by 5 min at 65°C. An additional 1 µl of Superscript III was added to the reaction mix and incubated at 50°C for 30 min. Second strand synthesis was performed by addition of Sequenase enzyme (Affymetrix Santa Clara, CA) and incubated by a ramped increased from 10 to 37°C for 16 min followed by 2 min at 94°C. Subsequently, the 37°C incubation was repeated with the addition of Sequenase and amplified using TaqR mastermix (Clontech/Takara) using the manufacturers' recommendations. The resulting double stranded amplicon was processed to generate the sequencing library using the Illumina Nextera DNA sample preparation kit according to the manufacturers' protocol.

The raw paired end reads obtained from the Miseq sequencing run were trimmed and quality filtered using a custom python script and subsequently assembled using the Burrows–Wheeler Aligner Maximal Exact Match (BWA-MEM) (Li, 2013) and consensus was generated using SAMTOOLS. Assembled RHDV sequences were confirmed using the BLAST function of the National Centre for Biotechnology Information (NCBI) alignment tool. RHDV complete genome sequences were downloaded from the NCBI database. All sequences were aligned using MUSCLE (Edgar, 2004), and visualized with MEGA 7.0.18 software (Kumar et al., 2016).

Aligned sequences were used to establish relationships between the viral strains used in the animal experiment. Phylogenetic trees were inferred using the maximum likelihood method based on the Tamura–Nei model (Tamura & Nei, 1993). All positions containing gaps and missing data were eliminated. The final consensus tree was generated by a bootstrapping approach with 500 replicates. Genbank accession numbers are indicated on the tree for genomes which were used for comparison.

## 2.4 | Experimental design

Five NZWRs and five wild caught ECTs were orally inoculated with 1 ml of RHDV2 homogenate, consisting of 10% weight per volume (w/v) liver in 1 × PBS pH 7.4. In parallel, five NZWRs and five ECTs were orally inoculated with 1 ml of RHDV homogenate, derived from the Indiana 2005 RHDVa outbreak, and consisting of 10% w/v liver in 1 × PBS pH 7.4. Two additional NZWRs and one ECT were orally inoculated with 1 ml of PBS pH 7.4 as control animals. EDTA blood, serum, oral swabs and rectal swabs were collected prior to inoculation and subsequently at 2, 9 and 21 days post-inoculation (DPI), or terminally at the time of necropsy. Fresh and formalin-fixed tissues (liver, lung, spleen, kidney and intestine) and urine (collected by needle aspiration during necropsy) were also collected at the time of necropsy. Rabbits were maintained in three separate animal rooms where RHDV, RHDV2 and control groups were segregated. Animals were individually housed and closely monitored twice daily for clinical signs of disease for the duration of the experiment. Established endpoints included fever (>40.4°C for > 24 h), depression and inappetence. When ani-

mals reached any of these criteria, they were deeply sedated with a ketamine/xylazine/butorphanol cocktail and subsequently euthanized with an overdose of pentobarbital sodium. Body temperature was monitored using microchips (BMDS-IPTT-300, Biomedic Data Systems, Seaford, DE, USA) implanted subcutaneously to minimize animal handling. Animal studies were conducted in a biosafety level 3 agriculture (BSL-3Ag) facility at the Plum Island Animal Disease Centre, Greenport, NY, under the oversight of the Institutional Animal Care and Use Committee (Protocol 255.04-17-P). Standard and BSL-3Ag precautions were observed during this study.

## 2.5 | Real-time RT-PCR

Specific real-time RT-PCR (rRT-PCR) was used to detect either RHDV2 or RHDV in the liver, spleen, intestine, urine, oral and rectal swabs, and blood of both ECTs and NZWRs. Total nucleic acid was extracted from 200 µl of the respective sample or tissue homogenate using a MagMax Pathogen RNA/DNA extraction kit (Thermo Fisher Scientific, Waltham, MA), following the manufacturer's protocol using a KingFisher Flex 96 well magnetic processor (Thermo Fisher Scientific, Waltham, MA). Nucleic acid samples were eluted in 90 µl of elution buffer and stored at –70°C until use. Samples were tested for RHDV2 and RHDV nucleic acids using minor modifications of previously published protocols (Duarte et al., 2015; Gall et al., 2007). Namely, published primer sets were utilized to amplify conserved regions of the RHDV2 and RHDV vp60 gene. Real-time RT-PCR was performed using the TaqMan Fast Virus 1-step Master Mix kit. Reactions for RHDV and RHDV2 were run separately but under identical conditions. Reactions consisted of 1 µM of each primer, 0.2 µM of probe, 6.25 µl of 4× TaqMan Fast Master Mix, 8.25 µl of nuclease-free water, and 2.5 µl of template nucleic acid. The rRT-PCR reactions were run on a 7500 Fast Thermocycler (Applied Biosystems, Foster City, CA) using the following conditions: 5 min for reverse transcription at 50°C, 20 s denaturation at 95°C, followed by 45 cycles of 3 s at 95°C and 30 s at 60°C. Results were analyzed using the automatic threshold and baseline settings of the thermocycler software (v 2.3).

## 2.6 | Antigen and antibody ELISAs

Antigen and antibody enzyme-linked immunosorbent assays (ELISAs) were conducted on liver homogenates and serum samples, respectively using ELISA kits from the OIE Reference Laboratory for Rabbit Hemorrhagic Disease following the kit's instructions. Two different RHD serological kits RHDV/RHDVa and RHDV2 were used to assess IgG antibodies.

## 2.7 | Electron microscopy

Ten-percent liver homogenates were clarified by centrifugation at 1500 × g for 10 min at 4°C. Virus was concentrated from the

**TABLE 1** Case fatality of New Zealand white rabbits (*Oryctolagus cuniculus*) and eastern cottontails (*Sylvilagus floridanus*) due to rabbit hemorrhagic disease virus (RHDV and RHDV2) experimental inoculations

Virus	New Zealand white rabbits			Eastern cottontails				
	ID <sup>1</sup>	2 DPI <sup>2</sup>	21 DPI	ID	2 DPI	4 DPI	6 DPI	21 DPI
RHDV2	1	D <sup>3</sup>		13				E <sup>5</sup>
	2	D <sup>3</sup>		14		D <sup>3</sup>		
	3	D <sup>3</sup>		15			D <sup>3</sup>	
	4	D <sup>3</sup>		16				E <sup>5</sup>
	5	D <sup>3</sup>		17		D <sup>3</sup>		
RHDV	6	D <sup>3</sup>		18	E <sup>6</sup>			
	7		E <sup>5</sup>	19				E <sup>5</sup>
	8	D <sup>3</sup>		20				E <sup>5</sup>
	9	D <sup>3</sup>		21				E <sup>5</sup>
	10	E <sup>4</sup>		22				E <sup>5</sup>
Controls <sup>7</sup>	11		E <sup>5</sup>	23				E <sup>5</sup>
	12		E <sup>5</sup>					

<sup>1</sup>ID = Rabbit identification number.

<sup>2</sup>DPI = Days post-inoculation.

<sup>3</sup>D = Died during the experiment.

<sup>4</sup>E = Euthanized due to severe lethargy.

<sup>5</sup>E = Euthanized at the termination of the experiment.

<sup>6</sup>E = Euthanized due to skin injury during 2 DPI.

<sup>7</sup>A single eastern cottontail and two New Zealand white rabbits were used as control animals.

supernatant by ultracentrifugation of 450  $\mu$ l of the supernatant at greater than 100,000  $\times$  g and 24 psi for 30 min using a Beckman air-centrifuge. Virus pellets were re-suspended in 50  $\mu$ l H<sub>2</sub>O applied to formvar-coated, carbon-stabilized grids (Electron Microscopy Sciences) and stained with 2% phosphotungstic acid (PTA). Grids were examined with a H-7600 Hitachi transmission electron microscope operating at 80 kV and images were digitally recorded.

## 2.8 | Histopathology

Tissues (liver, lung, spleen, kidney and intestine) were fixed in 10% neutral-buffered formalin, embedded in paraffin, sectioned at 4  $\mu$ m thickness, stained with haematoxylin and eosin and examined by light microscopy.

## 3 | RESULTS

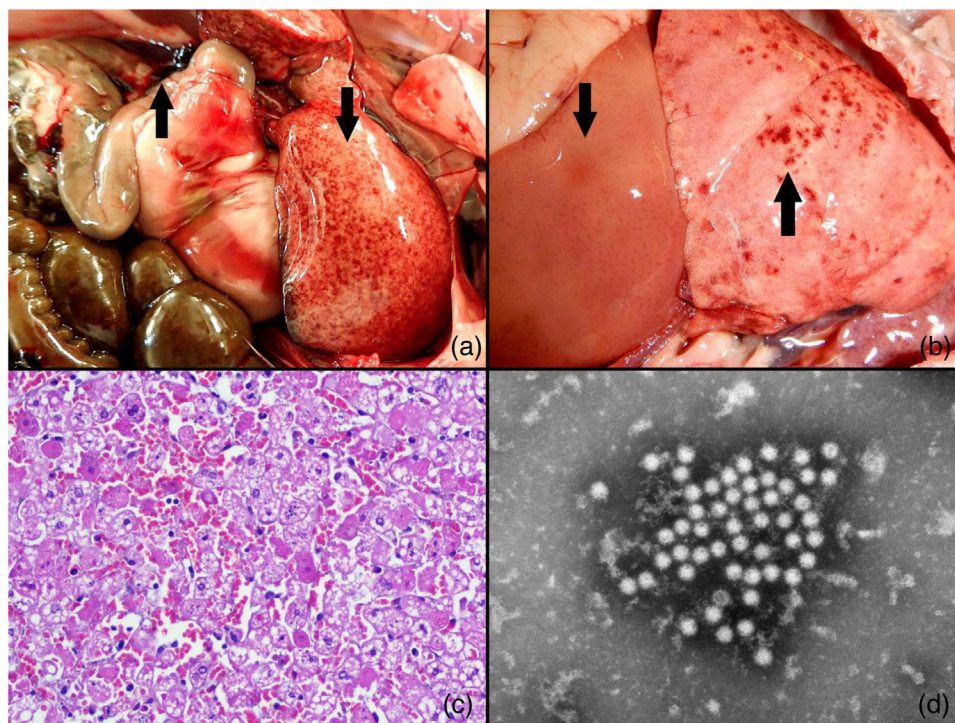
During 1–3 DPI, all RHDV2-inoculated ECTs appeared clinically normal. At 4 DPI, two of five ECTs infected with RHDV2 were found dead and an additional ECT was found dead at 6 DPI. The remaining two RHDV2-inoculated ECTs survived until termination of the experiment at 21 DPI. All ECTs that were inoculated with RHDV survived until the conclusion of the experiment, except ECT #18, which was euthanized at 2 DPI due to an unrelated skin injury (Table 1).

During 2 DPI (approximately 36 h post-inoculation), all five RHDV2-inoculated NZWRs were found dead (Table 1). During the same DPI,

three of five RHDV-inoculated NZWRs were also found dead. An additional RHDV-inoculated NZWR (#10) was markedly lethargic and reluctant to move, resulting in humane euthanasia at 2 DPI. The remaining NZWR (#7) appeared normal and survived until the termination of the experiment at 21 DPI (Table 1).

Due to the acute to peracute nature of this disease, minimal clinical signs (i.e., fever and depression) were observed in ECTs. Bloody nares were occasionally noted at the time of death. Clinical signs in NZWRs were variable and consisted of fever (e.g., 104–106 °F), lethargy, depression and terminally non-responsive to stimuli. Similar to ECTs, bloody nares were also periodically noted for NZWRs at the time of death.

Upon necropsy, ECTs and NZWRs that succumbed to disease from RHDV2 (ECTs) or both viruses tested (NZWRs) showed similar findings consisting of pale, friable livers with multifocal hemorrhages (Figures 1a, b). An additional finding commonly observed in infected animals was a notably enlarged spleen. Variable multifocal petechial and ecchymotic haemorrhages were often noted in the lungs and thymus, and diffusely on the mucosal surface of the trachea. One ECT had un-clotted serosanguinous fluid present in its abdominal cavity (Figure 1a). The most significant histopathological changes noted for both viruses were found in the liver and consisted of acute periportal to mid-zonal hepatic degeneration and necrosis, disassociation of the hepatic cords, hypereosinophilia and vacuolar changes. Pyknosis, karyorrhexis, and karyolysis were evident (Figure 1c). Heterophilic inflammatory cell infiltration was minimal in the NZWRs that died at 2 DPI but were more pronounced in the ECT that died at 6 DPI. Fibrin thrombi were noted in the spleen and renal glomeruli suggestive of disseminated



**FIGURE 1** (a) Swollen, pale liver with multifocal haemorrhages (down arrow) and abdominal haemorrhage (up arrow) in an eastern cottontail infected with rabbit haemorrhagic disease virus type 2 (RHDV2). (b) Pale liver (down arrow) of New Zealand white rabbit infected with rabbit haemorrhagic disease virus (RHDV) with prominent reticular pattern and multifocal haemorrhages in the lungs (up arrow) and thymus. (c) Liver of an eastern cottontail infected with RHDV2 and stained with haematoxylin and eosin and magnified 40x. Note the acute hepatocellular necrosis and haemorrhage. (d) Transmission electron micrograph with negative staining phosphotungstic acid (PTA) of the liver homogenate demonstrating calicivirus particles magnified by 50,000x in a New Zealand white rabbit infected with RHDV

intravascular coagulation. Electron microscopy of liver homogenates using PTA-negative staining revealed numerous viral particles characteristic of caliciviruses with short cup-like projections and a mean diameter of 27 nm (Figure 1d).

The liver samples of three ECTs that succumbed to RHDV2 infections were positive by antigen ELISA at a titre of 1:1080 at 4 and 6 DPI, while the remaining two ECTs that survived until the termination of the experiment (21 DPI) tested negative (Table 2). The liver homogenates of all five ECTs inoculated with RHDV were negative for RHDV by antigen ELISA. All liver samples from NZWRs infected with RHDV2 were positive by antigen ELISA with titres of 1:180 or 1:1080. Four of five NZWRs inoculated with RHDV were positive by antigen ELISA with titres of 1:180 or 1:1080, while the remaining rabbit that survived until the termination of the experiment was negative. The liver samples of the control rabbits of both species were negative by antigen ELISA (Table 2).

The serum samples collected from NZWRs inoculated with RHDV and RHDV2 were negative by antibody ELISAs at 0 and at 2 DPI. The one NZWR (#7) that survived RHDV inoculation was positive with a titre of 1:40 at 9 DPI and a titre of 1:160 at 21 DPI. Control NZWRs remained negative for RHDV and RHDV2 antibodies throughout the course of the experiment.

The RHDV2 antibody ELISAs were negative in ECTs at 0 DPI, with one exception. The one outlier, ECT #13, had an antibody titre of 1:10

at 0 DPI, but was seronegative when tested at 9 and 21 DPI. The low titre at 0 DPI may be due to cross reactivity or a non-specific reaction. As expected early in an infection in mammals, ECTs #14, #15 and #17 were seronegative when they died at 4, 6 and 4 DPI, respectively. In contrast, ECT #16, which survived to the end of the experiment, but showed some evidence of infection (Table 3), had a high antibody titre of 1:2560. Antibody assessments by ELISAs were negative at 0, 2, 9 and 21 DPI in ECTs infected with RHDV with two exceptions. Cottontail #18 had a low titre of 1:10 at 0 DPI and ECT #20 had titres of 1:40, 1:10 and 1:10 at 0, 9 and 21 DPI, respectively. The low titres in these two ECTs were interpreted as antibody cross reactivity and/or 'serological noise' and not as true seroconversions. The control ECT was negative for RHDV antibodies throughout the course of the experiment.

All NZWRs inoculated with either RHDV or RHDV2 had detectable viral RNA in the liver, spleen, intestine and blood (blood from NZWR #7 was not available for testing; Table 3). The relatively high CT values in the liver and spleen of NZWR #7, the only rabbit in this group that survived infection with RHDV, is likely indicative of a low viral load. Four of five ECTs infected with RHDV2 had detectable viral RNA in their livers, spleens and intestines (Table 3). Detection of viral RNA in blood samples was intermittent. Cottontail #13, which survived the experimental period of 21 days, had no detectable RHDV2 viral RNA in any of the organs examined nor in urine, oral/rectal swabs and blood samples (Tables 3 and 5). In contrast to RHDV2, viral RNA was not detected in



**TABLE 2** Rabbit haemorrhagic disease virus antigen ELISA tests of liver samples from New Zealand white rabbits (*Oryctolagus cuniculus*) and eastern cottontails (*Sylvilagus floridanus*) experimentally infected with rabbit haemorrhagic disease viruses (RHDV and RHDV2)

Virus	New Zealand white rabbits			Eastern cottontails		
	ID <sup>1</sup>	DPI <sup>2</sup>	Ag titre 1:X	ID	DPI	Ag titre 1:X
RHDV2	1	2	180	13	21	-
	2	2	1080	14	4	1080
	3	2	1080	15	6	1080
	4	2	1080	16	21	-
	5	2	180	17	4	1080
RHDV	6	2	180	18	2	-
	7	21	- <sup>3</sup>	19	21	-
	8	2	180	20	21	-
	9	2	180	21	21	-
	10	2	1080	22	21	-
Control <sup>4</sup>	11	21	-	23	21	-
	12	21	-			

<sup>1</sup>ID = Rabbit identification number.

<sup>2</sup>DPI = Days post-inoculation when liver samples were obtained. This was the day that animals died or were euthanized.

<sup>3</sup>A dash '-' indicates the sample was negative.

<sup>4</sup>A single eastern cottontail and two New Zealand white rabbits were used as control animals.

**TABLE 3** Distribution of rabbit haemorrhagic disease (RHDV and RHDV2) viral RNA in liver, spleen, intestine and blood as detected by real-time RT-PCR in experimentally infected New Zealand white rabbits (*Oryctolagus cuniculus*) and eastern cottontails (*Sylvilagus floridanus*)

Virus	New Zealand white rabbits					Eastern cottontails								
	ID <sup>1</sup>	Liv <sup>2</sup>	Spl <sup>3</sup>	Int <sup>4</sup>	Blood DPI <sup>5</sup>		ID	Liv	Spl	Int	Blood DPI			
					2	21					2	4	6	21
RHDV2	1 (2)	7 <sup>6</sup>	15	23	14		13 (21)	-	-	-	-	nd	nd	-
	2 (2)	7	17	23	10		14 (4)	10	17	20	nd	10		
	3 (2)	9	17	26	16		15 (6)	7	17	24	26	nd	20	
	4 (2)	5	17	24	20		16 (21)	28	25	15	35	nd	nd	-
	5 (2)	8	17	25	13		17 (4)	9	15	22	18	11		
RHDV	6 (2)	13	15	22	14		18 (2) <sup>7</sup>	-	-	-	-			
	7 (21)	39	35	28	nd <sup>8</sup>	nd	19 (21)	-	-	-	-	nd	nd	-
	8 (2)	14	14	22	16		20 (21)	-	-	-	-	nd	nd	-
	9 (2)	12	15	20	16		21 (21)	-	-	-	-	nd	nd	-
	10 (2)	14	15	19	15		22 (21)	-	-	-	-	nd	nd	-
Control <sup>9</sup>	11 (21)	- <sup>10</sup>	-	-	-	-	23 (21)	-	-	-	-	nd	nd	-
	12 (21)	-	-	-	-	-								

<sup>1</sup>ID = Rabbit identification number. Numbers in parentheses indicated the day the animal was euthanized or died.

<sup>2</sup>Liv = Liver.

<sup>3</sup>Spl = Spleen. All organ samples were collected at day of death or euthanasia (see Table 1).

<sup>4</sup>Int = Intestine.

<sup>5</sup>DPI = Days post-inoculation.

<sup>6</sup>Numbers indicate Ct values.

<sup>7</sup>This cottontail was euthanized due to a skin injury.

<sup>8</sup>nd = Not done.

<sup>9</sup>Control animals were tested for both types of RHD viruses. A single eastern cottontail and two New Zealand white rabbits were used as control animals.

<sup>10</sup>A dash '-' indicates the sample was negative.

\*Dark shading indicates the rabbit had either died or was euthanized prior to this time point. Therefore, a sample could not be collected/tested.

**TABLE 4** Rabbit hemorrhagic disease viral RNA detected from oral swabs, rectal swabs, and urine samples collected from experimentally infected New Zealand white rabbits (*Oryctolagus cuniculus*). Viral RNA shedding was assessed by real-time RT-PCR

Treatment	ID <sup>1</sup>	DoD <sup>2</sup>	Urine <sup>3</sup>	Oral swab DPI <sup>4</sup>				Rectal swab DPI			
				0	2	9	21	0	2	9	21
RHDV2	1	2	27 <sup>5</sup>	- <sup>6</sup>	-			-	23		
	2	2	25	-	36			-	32		
	3	2	22	-	32			-	37		
	4	2	26	-	30			-	30		
	5	2	31	-	29			-	28		
RHDV	6	2	32	-	34			-	29		
	7	21	-	-	-	38	-	-	38	33	39
	8	2	24	-	37			-	30		
	9	2	28	-	29			-	31		
	10	2	27	-	34			-	35		
Control <sup>8</sup>	11	21	-	-	nd <sup>7</sup>	nd	-	-	nd	nd	-
	12	21	-	-	nd	nd	-	-	nd	nd	-

<sup>1</sup>ID = Rabbit identification number.<sup>2</sup>DoD = day of death (died or euthanized).<sup>3</sup>Urine was collected at the time of death or euthanasia (see Table 1).<sup>4</sup>DPI = Days post-inoculation.<sup>5</sup>Numbers indicate Ct values.<sup>6</sup>A dash '-' indicates the sample was negative.<sup>7</sup>nd = Not done.<sup>8</sup>Control animals were tested for both types of RHD viruses.

\*Dark shading indicates the rabbit had either died or was euthanized prior to this time point. Therefore, a sample could not be collected/tested.

**TABLE 5** Rabbit haemorrhagic disease viral RNA detected from oral swabs, rectal swabs, and urine samples collected from experimentally infected eastern cottontails (*Sylvilagus floridanus*). Viral RNA shedding was assessed by real-time RT-PCR

Treatment	ID <sup>1</sup>	DoD <sup>2</sup>	Urine <sup>3</sup>	Oral swab DPI <sup>4</sup>					Rectal swab DPI					
				0	2	4	9	21	0	2	4	6	9	21
RHDV2	13	21	- <sup>5</sup>	-	-	nd <sup>6</sup>	-	-	-	-	nd	nd	-	-
	14	4	23 <sup>7</sup>	-	-	28			-	-	30			
	15	6	28	-	-	nd			-	32	nd	30		
	16	21	-	-	-	nd	-	-	-	-	nd	nd	-	-
	17	4	17	-	-	21			-	33	26			
RHDV	18	2 <sup>8</sup>	-	-	-				-	37				
	19	21	-	-	-	nd	-	-	-	-	nd	nd	-	-
	20	21	-	-	-	nd	-	-	-	-	nd	nd	-	-
	21	21	-	-	-	nd	-	-	-	-	nd	nd	-	-
	22	21	-	-	-	nd	-	-	-	33	nd	nd	-	-
Control <sup>9</sup>	23	21	-	-	nd	nd	nd	-	-	nd	nd	nd	nd	-

<sup>1</sup>ID = Rabbit identification number.<sup>2</sup>DoD = day of death (died or euthanized).<sup>3</sup>Urine was collected at the time of death or euthanasia (see Table 1).<sup>4</sup>DPI = Days post-inoculation.<sup>5</sup>A dash '-' indicates the sample was negative.<sup>6</sup>nd = Not done.<sup>7</sup>Numbers indicate Ct values.<sup>8</sup>This cottontail was euthanized due to a skin injury.<sup>9</sup>The control animal was tested for both types of RHD viruses.

\*Dark shading indicates the rabbit had either died or was euthanized prior to this time point. Therefore, a sample could not be collected.

any of the organs examined or blood of the ECTs inoculated with RHDV (Table 3). Control animals were negative for all samples tested (Tables 3 and 5).

Viral RNA was detected in the urine and oral swabs of NZWRs inoculated with either RHDV or RHDV2 except rabbits #1 and #7, which had no detectable viral RNA in oral swab or urine/oral samples, respectively (Table 4). However, RHDV and RHDV2 RNA was detected in all the rectal swabs of inoculated NZWRs. All control rabbits regardless of species were negative for all sample types collected and tested at 21 DPI (Tables 3–5).

Viral RNA was detected in the urine and rectal swabs of 3 of 5 ECTs and was also detected in the oral swabs in two of five ECTs inoculated with RHDV2. Interestingly, no viral RNA was detected from urine and oral/rectal samples collected from ECTs #13 and #16, which were the two animals of this experimental group that survived to the conclusion of the study. In contrast, ECTs infected with RHDV had no viral RNA shedding in the urine, oral or rectal swabs, except for individuals #18 and #22, which had detectable viral RNA shedding only in rectal swabs collected at 2 DPI (Table 5). Considering the lack of any other type of evidence of viral RNA shedding in these two animals, the apparent rectal shedding likely represents defecation of the original inoculum without replication of the virus. The control ECT did not show any evidence of viral RNA shedding (Table 5).

The phylogenetic analysis supported identification of the viruses used in this study as RHDV and RHDV2 (Figure 2). Phylogenetic analysis of the RHDV sequence showed a close relationship to its parental strain (RHDV Indiana 2005) with a relative minor genetic distance due to a passage of the aforementioned strain in experimental rabbits. The observed RHDV lineage is consistent with previously reported results (McIntosh et al., 2007).

The RHDV2 sequence (Figure 2) showed a close relationship to previously reported recombinant viruses (Almeida et al., 2015; Hall et al., 2015). Similar viruses have been reported to have circulated in the Iberian Peninsula and in Australia (Almeida et al., 2015; Hall et al., 2018). The region of the genome encoding the structural protein VP60 clustered within the RHDV2 genogroup, while the upstream region encoding the non-structural RdRp protein clustered within the RHDV Gl.1b variant (data not shown).

## 4 | DISCUSSION

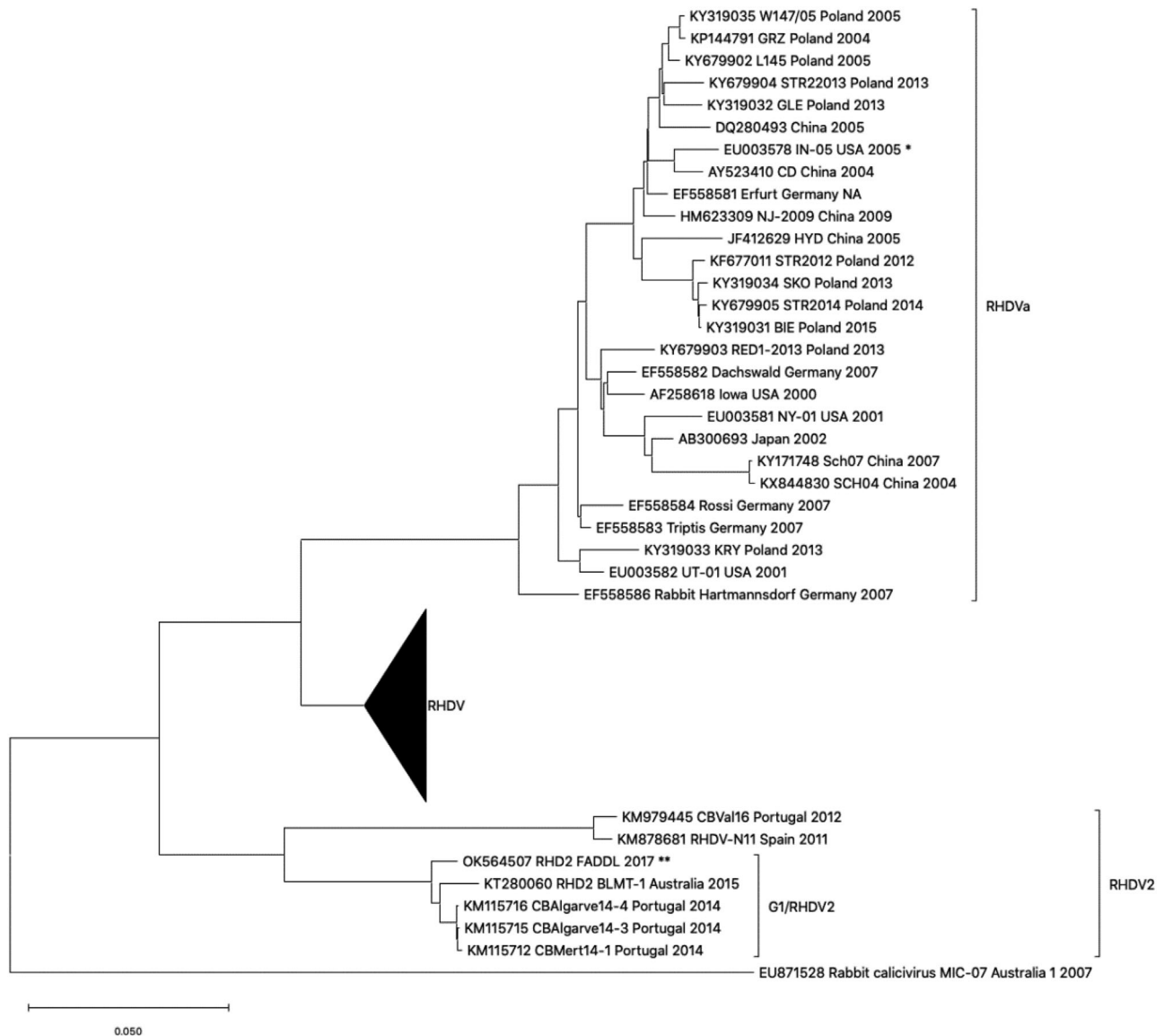
No ECTs inoculated with RHDV succumbed to the disease caused by this virus and did not seroconvert. Thus, these results support earlier studies that ECTs are resistant to the classical RHDV (Gregg et al., 1991; Lavazza et al., 2015). In contrast, three of five ECTs inoculated with RHDV2 exhibited clinical signs consistent with the disease and died at 4 or 6 DPI, thereby indicating that ECTs are susceptible to this virus. One of five ECTs survived to 21 DPI and seroconverted, thereby demonstrating that this ECT did become infected but did not develop fulminant disease. In contrast, the remaining ECT (#13) was consistently negative by antigen ELISA, antibody ELISA, and real-time RT-PCR, which suggests that, for unknown reasons, this rabbit never

became infected. All five NZWRs inoculated with RHDV2 died at 2 DPI supporting previous findings that this virus is highly pathogenic to NZWRs. Although earlier reports have indicated that RHDV2 may have a longer duration of disease and lower mortality rate (Puggioni et al., 2013), our results are more consistent with recent reports, which have suggested increased pathogenicity of this virus in NZWRs (Capucci et al., 2017; Hall et al., 2021). Three of five NZWRs inoculated with RHDV died at 2 DPI, one (#10) was euthanized at 2 DPI because of severe lethargy, and one (#7) survived to the end of the experimental period. Real-time RT-PCR indicated NZWR #7 had a relatively low viral load in the liver and spleen, which may explain its survival until the experiment was terminated at 21 DPI.

RHD viral antigen (VP60) was detected in the livers of all inoculated NZWRs except for the one that survived. The one exception, NZWR #7, had tissue samples positive by rRT-PCR on 21 DPI, albeit with high Ct values (i.e., low viral loads), which may explain the negative antigen ELISA test (Tables 2 and 3). Three of 5 ECTs inoculated with RHDV2 were positive for viral antigen in the liver, while all five ECTs inoculated with RHDV were negative (Table 2). The negative antigen ELISA combined with the negative rRT-PCR results in ECTs infected with RHDV provide further evidence that ECTs are not susceptible to the classical RHDV and that infections were not established. The reason why ECTs were susceptible to RHDV2, but not to the classical RHDV, is an intriguing question that requires further investigation.

RHD viral RNA was detected in most urine and oral swab samples of inoculated NZWRs and in all rectal swab samples indicating that viral RNA can be detected via urine, faeces and saliva, regardless of the tested virus. RHD viral RNA was detected in the urine and rectal swabs in three of five ECTs and in the oral swabs in two of five ECTs inoculated with RHDV2 during at least one sampling timepoint. This suggests that viral RNA can be detected in this species by multiple routes. Viral RNA was not detected in the urine or oral swabs of ECTs inoculated with the classical RHDV but was detected in two of five rectal swabs at 2 DPI. Considering the lack of viral RNA shed by other routes as well as the absence of definitive seroconversions in these animals, the most parsimonious explanation for this observation is that the animals defecated viral RNA from the inoculum without replication of the virus. However, it can be postulated that ECTs may have the capacity to mechanically transmit this virus without becoming infected by transporting the virus on their fur or feet. This has been suggested for mice, which have been reported to act as a potential vehicle in the transmission of this virus (Rocha et al., 2017). It should be noted, however, that the detection of viral RNA does not necessarily equate to the detection of viable virus.

The susceptibility of ECTs to RHDV2, as this study has shown, is a cause of concern, as ECTs are widely distributed in the United States and are often synanthropic, which suggests they could live near commercial rabbit breeding facilities. In addition to the impact this virus can have on wildlife at the individual and population levels, the spillover of this virus into wildlife populations has made outbreaks of this pathogen very difficult to control. A recent RHDV2 outbreak in domestic and wild lagomorphs originated in the southwestern United States and Mexico during early 2020. Wildlife surveillance conducted during this outbreak has indicated that additional cottontail species (e.g., *S. audubonii*



**FIGURE 2** Maximum likelihood phylogenetic tree for rabbit haemorrhagic disease virus (RHDV) full genome sequences. The two challenge strains RHDV and rabbit haemorrhagic disease virus type 2 (RHDV2) were aligned with representative RHDV and Australian rabbit calicivirus sequences from GenBank (accession numbers indicated in taxonomy names). The ‘\*\*’ indicates the source of a virus isolate recovered after one passage in rabbits (data not shown) from the original isolate from an outbreak in the state of Indiana, USA (IN05 USA 2005) (accession number: EU003578). The ‘\*\*\*’ indicates OK564507 RHD2 FADDL 2017, a recombinant RHDV2 strain received from the OIE reference laboratory in Italy

and *S. nuttallii*) and select jackrabbits (*Lepus* spp.) are susceptible to RHDV2. However, the susceptibility of less common lagomorphs of North America to RHDV2 (e.g., American pika [*Ochotona princeps*] and pygmy rabbits [*Brachylagus idahoensis*]) remains to be determined. Notably, many additional rabbit and hare species are widely distributed throughout the continental United States. Importantly, some or perhaps most of these species may play a role in the trafficking and persistence of RHDV2 within North America.

The emergent RHDV2 is an excellent example of a transboundary disease that has potential implications at the wildlife-livestock interface. For example, from 2010 to 2019 alone, RHDV2 has been identified in multiple lagomorph species in both the Old and New Worlds, thereby affecting many countries (Ambagala et al., 2021; Neimanis

et al., 2018; Puggioni et al., 2013; USDA, 2019). Generically speaking, the source of many outbreaks have been considered to be inconclusive (USDA, 2019). Therefore, experimental assessments of additional North American lagomorphs should be considered high priority following the recent incursion of RHDV2 into North America.

#### ACKNOWLEDGEMENTS

We gratefully thank Dr. Kimberly Dodd, Dr. Robin Holland, Stacy Kwasniewski, Dr. Karyn Havas, Dr. Fernando Torres-Velez, Kylie Schumacher, Philip Doucett, Dr. Brenton Sanford, Benjamin Hershey, Benjamin Clark, Kristina Delgado, Kathleen Apicelli and the Animal Care Staff of the Department of Homeland Security, Plum Island Animal Disease Center for their assistance with this study. This research was

supported by the U.S. Department of Agriculture, Animal and Plant Health Inspection Service.

## CONFLICT OF INTEREST

The authors declare that they have no conflict of interest.

## ETHICS STATEMENT

The authors confirm that the ethical policies of the journal, as noted in the journal's author guidelines page, have been adhered to.

## DATA AVAILABILITY STATEMENT

Complete genome sequence of the passaged inoculum virus derived from the TA-14 isolate is available at the National Centers for Biotechnology Information (NCBI) and was submitted with GenBank accession number OK564507.

## ORCID

Fawzi Mohamed  <https://orcid.org/0000-0002-6406-9213>

Charles E. Lewis  <https://orcid.org/0000-0002-2489-0605>

Lorenzo Capucci  <https://orcid.org/0000-0002-1830-3929>

J. Jeffrey Root  <https://orcid.org/0000-0003-4177-1824>

## REFERENCES

- Abrantes, J., Droillard, C., Lopes, A. M., Lemaitre, E., Lucas, P., Blanchard, Y., Marchandeau, S., Esteves, P. J., & Le Gall-Reculé, G. (2020). Recombination at the emergence of the pathogenic rabbit haemorrhagic disease virus *Lagovirus europaeus*/GI.2. *Scientific Reports*, 10(1), 14502. <https://doi.org/10.1038/s41598-020-71303-4>
- Abrantes, J., van der Loo, W., Le Pendu, J., & Esteves, P. J. (2012). Rabbit haemorrhagic disease (RHD) and rabbit haemorrhagic disease virus (RHDV): A review. *Veterinary Research*, 43(1), 12. <https://doi.org/10.1186/1297-9716-43-12>
- Almeida, T., Lopes, A. M., Magalhães, M. J., Neves, F., Pinheiro, A., Gonçalves, D., Leitão, M., Esteves, P. J., & Abrantes, J. (2015). Tracking the evolution of the G1/RHDVb recombinant strains introduced from the Iberian Peninsula to the Azores islands, Portugal. *Infection, Genetics and Evolution*, 34, 307–313. <https://doi.org/10.1016/j.meegid.2015.07.010>
- Ambagala, A., Schwantje, H., Laurendeau, S., Snyman, H., Joseph, T., Pickering, B., Hooper-McGreavy, K., Babiuk, S., Moffat, E., Lamboo, L., Lung, O., Goolia, M., Pinette, M., & Embury-Hyatt, C. (2021). Incursions of rabbit haemorrhagic disease virus 2 in Canada—Clinical, molecular and epidemiological investigation. *Transboundary and Emerging Diseases*, 68(4), 1711–1720.
- Bracht, A. J., O'Hearn, E. S., Fabian, A. W., Barrette, R. W., & Sayed, A. (2016). Real-time reverse transcription PCR assay for detection of senecavirus A in swine vesicular diagnostic specimens. *Plos One*, 11(1). <https://doi.org/10.1371/journal.pone.0146211>
- Capucci, L., Cavadini, P., & Lavazza, A. (2020). Rabbit hemorrhagic disease virus and European brown hare syndrome virus. In D. Bamford & M. Zuckerman (Eds.), *Encyclopedia of virology*. Academic Press.
- Capucci, L., Cavadini, P., Schiavitto, M., Lombardi, G., & Lavazza, A. (2017). Increased pathogenicity in rabbit haemorrhagic disease virus type 2 (RHDV2). *Veterinary Record*, 180(17), 426. <https://doi.org/10.1136/vr.104132>
- D'angelo, A., Cerri, J., Cavadini, P., Lavazza, A., Capucci, L., & Ferretti, M. (2019). The eastern cottontail (*Sylvilagus floridanus*) in Tuscany (central Italy): Weak evidence for its role as a host of EBHSV and RHDV. *Hystrix*, 30(1), 8–11. <https://doi.org/10.4404/hystrix-00146-2019>
- Dalton, K. P., Nicieza, I., Abrantes, J., Esteves, P. J., & Parra, F. (2014). Spread of new variant RHDV in domestic rabbits on the Iberian Peninsula. *Veterinary Microbiology*, 169(1-2), 67–73. <https://doi.org/10.1016/j.vetmic.2013.12.015>
- Dalton, K. P., Nicieza, I., Balseiro, A., Muguerza, M. A., Rosell, J. M., Casais, R., Álvarez, Á., L., & Parra, F. (2012). Variant rabbit hemorrhagic disease virus in young rabbits, Spain. *Emerging Infectious Diseases*, 18(12), 2009–2012. <https://doi.org/10.3201/eid1812.120341>
- Duarte, M. D., Carvalho, C. L., Barros, S. C., Henriques, A. M., Ramos, F., Fagulha, T., Luís, T., Duarte, E. L., & FEVEREIRO, M. (2015). A real time Taqman RT-PCR for the detection of rabbit hemorrhagic disease virus 2 (RHDV2). *Journal of Virological Methods*, 219, 90–95.
- Edgar, R. C. (2004). MUSCLE: Multiple sequence alignment with improved accuracy and speed. In *CSB '04: Proceedings of the 2004 IEEE computational systems bioinformatics conference*. IEEE Computer Society.
- Gall, A., Hoffmann, B., Teifke, J. P., Lange, B., & Schirmer, H. (2007). Persistence of viral RNA in rabbits which overcome an experimental RHDV infection detected by a highly sensitive multiplex real-time RT-PCR. *Veterinary Microbiology*, 120(1-2), 17–32. <https://doi.org/10.1016/j.vetmic.2006.10.006>
- Gregg, D. A., House, C., Meyer, R., & Berninger, M. (1991). Viral haemorrhagic disease of rabbits in Mexico: Epidemiology and viral characterization. *Revue Scientifique et Technique (International Office of Epizootics)*, 10(2), 435–451. <https://doi.org/10.20506/rst.10.2.556>
- Hall, R. N., King, T., O'connor, T., Read, A. J., Arrow, J., Trought, K., Duckworth, J., Piper, M., & Strive, T. (2021). Age and infectious dose significantly affect disease progression after RHDV2 infection in naïve domestic rabbits. *Viruses*, 13(6), 1184. <https://doi.org/10.3390/v13061184>
- Hall, R. N., Mahar, J. E., Haboury, S., Stevens, V., Holmes, E. C., & Strive, T. (2015). Emerging rabbit hemorrhagic disease virus 2 (RHDVb), Australia. *Emerging Infectious Diseases*, 21(12), 2276.
- Hall, R. N., Mahar, J. E., Read, A. J., Mourant, R., Piper, M., Huang, N., & Strive, T. (2018). A strain-specific multiplex RT-PCR for Australian rabbit haemorrhagic disease viruses uncovers a new recombinant virus variant in rabbits and hares. *Transboundary and Emerging Diseases*, 65(2), e444–e456.
- Kumar, S., Stecher, G., & Tamura, K. (2016). MEGA7: Molecular evolutionary genetics analysis version 7.0 for bigger datasets. *Molecular Biology and Evolution*, 33(7), 1870–1874. <https://doi.org/10.1093/molbev/msw054>
- Lavazza, A., Cavadini, P., Barbieri, I., Tizzani, P., Pinheiro, A., Abrantes, J., Esteves, P. J., Grilli, G., Gioia, E., Zanoni, M., Meneguz, P., Guitton, J. S., Marchandeau, S., Chiari, M., & Capucci, L. (2015). Field and experimental data indicate that the eastern cottontail (*Sylvilagus floridanus*) is susceptible to infection with European brown hare syndrome (EBHS) virus and not with rabbit haemorrhagic disease (RHD) virus. *Veterinary Research*, 46, 13. <https://doi.org/10.1186/s13567-015-0149-4>
- Le Gall-Reculé, G., Lavazza, A., Marchandeau, S., Bertagnoli, S., Zwingelstein, F., Cavadini, P., Martinelli, N., Lombardi, G., Guérin, J. L., Lemaitre, E., Decors, A., Boucher, S., Normand, B. L., & Capucci, L. (2013). Emergence of a new lagovirus related to rabbit haemorrhagic disease virus. *Veterinary Research*, 44(1), 81–81. <https://doi.org/10.1186/1297-9716-44-81>
- Le Gall-Reculé, G., Lemaitre, E., Bertagnoli, S., Hubert, C., Top, S., Decors, A., Marchandeau, S., & Guitton, J.-S. (2017). Large-scale lagovirus disease outbreaks in European brown hares (*Lepus europaeus*) in France caused by RHDV2 strains spatially shared with rabbits (*Oryctolagus cuniculus*). *Veterinary Research*, 48(1), 70.
- Le Gall-Reculé, G., Zwingelstein, F., Boucher, S., Le Normand, B., Plassiart, G., Portejoie, Y., Decors, A., Bertagnoli, S., Guérin, J. L., & Marchandeau, S. (2011). Detection of a new variant of rabbit haemorrhagic disease virus in France. *Veterinary Record*, 168(5), 137–138. <https://doi.org/10.1136/vr.d697>
- Le Pendu, J., Abrantes, J., Bertagnoli, S., Guitton, J.-S., Le Gall-Reculé, G., Lopes, A. M., Marchandeau, S., Alda, F., Almeida, T., Célio, A. P., Bárcena, J., Burmakina, G., Blanco, E., Calvete, C., Cavadini, P., Cooke, B., Dalton,

- K., Delibes Mateos, M., Deptula, W., Eden, J. S., ... Esteves, P. (2017). Proposal for a unified classification system and nomenclature of lagoviruses. *Journal of General Virology*, 98(7), 1658–1666. <https://doi.org/10.1099/jgv.0.000840>
- Li, H. (2013). Aligning sequence reads, clone sequences and assembly contigs with BWA-MEM. *arXiv:1303.3997v2 [q-bio.GN]*.
- Lopes, A. M., Breiman, A., Lora, M., Le Moullac-Vaidye, B., Galanina, O., Nyström, K., Marchandeau, S., Gall-Reculé, G. L., Strive, T., Neimanis, A., Bovin, N. V., Ruvoën-Clouet, N., Esteves, P. J., Abrantes, J., & Le Pendu, J. (2018). Host-specific glycans are correlated with susceptibility to infection by lagoviruses, but not with their virulence. *Journal of Virology*, 92(4). <https://doi.org/10.1128/jvi.01759-17>
- Lopes, A. M., Dalton, K. P., Magalhães, M. J., Parra, F., Esteves, P. J., Holmes, E. C., & Abrantes, J. (2015). Full genomic analysis of new variant rabbit hemorrhagic disease virus revealed multiple recombination events. *Journal of General Virology*, 96(6), 1309–1319. <https://doi.org/10.1099/vir.0.000070>
- Mahar, J. E., Read, A. J., Gu, X., Urakova, N., Mourant, R., Piper, M., Haboury, S., Holmes, E. C., Strive, T., & Hall, R. N. (2018). Detection and circulation of a novel rabbit hemorrhagic disease virus in Australia. *Emerging Infectious Diseases*, 24(1), 22–31. <https://doi.org/10.3201/eid2401.170412>
- McIntosh, M. T., Behan, S. C., Mohamed, F. M., Lu, Z., Moran, K. E., Burrage, T. G., Neilan, J. G., Ward, G. B., Botti, G., Capucci, L., & Metwally, S. A. (2007). A pandemic strain of calicivirus threatens rabbit industries in the Americas. *Virology Journal*, 4, 96. <https://doi.org/10.1186/1743-422X-4-96>
- Neimanis, A. S., Ahola, H., Larsson Pettersson, U., Lopes, A. M., Abrantes, J., Zohari, S., Esteves, P. J., & Gavier-Widén, D. (2018). Overcoming species barriers: An outbreak of *Lagovirus europaeus* GI.2/RHDV2 in an isolated population of mountain hares (*Lepus timidus*). *BMC Veterinary Research*, 14(1), 367–367. <https://doi.org/10.1186/s12917-018-1694-7>
- Neimanis, A. S., Ahola, H., Zohari, S., Larsson Pettersson, U., Bröjer, C., Capucci, L., & Gavier-Widén, D. (2018). Arrival of rabbit hemorrhagic disease virus 2 to northern Europe: Emergence and outbreaks in wild and domestic rabbits (*Oryctolagus cuniculus*) in Sweden. *Transboundary and Emerging Diseases*, 65(1), 213–220.
- Puggioni, G., Cavadini, P., Maestrale, C., Scivoli, R., Botti, G., Ligios, C., Gall-Reculé, G. L., Lavazza, A., & Capucci, L. (2013). The new French 2010 rabbit hemorrhagic disease virus causes an RHD-like disease in the Sardinian Cape hare (*Lepus capensis mediterraneus*). *Veterinary Research*, 44(1), 96. <https://doi.org/10.1186/1297-9716-44-96>
- Rocha, G., Alda, F., Pages, A., & Merchan, T. (2017). Experimental transmission of rabbit hemorrhagic disease virus (RHDV) from rabbit to wild mice (*Mus spretus* and *Apodemus sylvaticus*) under laboratory conditions. *Infection, Genetics, and Evolution*, 47, 94–98. <https://doi.org/10.1016/j.meegid.2016.11.016>
- Silvério, D., Lopes, A. M., Melo-Ferreira, J., Magalhães, M. J., Monterroso, P., Serronha, A., Maio, E., Alves, P. C., Esteves, P. J., & Abrantes, J. (2018). Insights into the evolution of the new variant rabbit hemorrhagic disease virus (GI.2) and the identification of novel recombinant strains. *Transboundary and Emerging Diseases*, 65(4), 983–992. <https://doi.org/10.1111/tbed.12830>
- Tamura, K., & Nei, M. (1993). Estimation of the number of nucleotide substitutions in the control region of mitochondrial DNA in humans and chimpanzees. *Molecular Biology and Evolution*, 10(3), 512–526.
- USDA. (2018). IMMEDIATE: APHIS detects rabbit hemorrhagic disease virus 2 (RHDV2) in a domestic Ohio rabbit. USDA Animal and Plant Health Inspection Service Bulletin.
- USDA. (2019). Rabbit hemorrhagic disease in British Columbia, Canada. Emerging Risk Notice-Animal Health. USDA.
- USDA. (2020). Rabbit hemorrhagic disease virus, type 2. USDA, Animal and plant health inspection service. [https://www.aphis.usda.gov/animal\\_health/downloads/rhdv2.pdf](https://www.aphis.usda.gov/animal_health/downloads/rhdv2.pdf)
- Velarde, R., Abrantes, J., Lopes, A. M., Estruch, J., Córte-Real, J. V., Esteves, P. J., García-Bocanegra, I., Ruiz-Olmo, J., & Rouco, C. (2021). Spillover event of recombinant *Lagovirus europaeus*/GI.2 into the Iberian hare (*Lepus granatensis*) in Spain. *Transboundary and Emerging Diseases*. <https://doi.org/10.1111/tbed.14264>
- Velarde, R., Cavadini, P., Neimanis, A., Cabezón, O., Chiari, M., Gaffuri, A., Lavín, S., Grilli, G., Gavier-Widén, D., Lavazza, A., & Capucci, L. (2017). Spillover events of infection of brown hares (*Lepus europaeus*) with rabbit hemorrhagic disease type 2 virus (RHDV2) caused sporadic cases of an European brown hare syndrome-like Disease in Italy and Spain. *Transboundary and Emerging Diseases*, 64(6), 1750–1761. <https://doi.org/10.1111/tbed.12562>
- Wang, D., Urisman, A., Liu, Y. T., Springer, M., Ksiazek, T. G., Erdman, D. D., Mardis, E. R., Hickenbotham, M., Magrini, V., Eldred, J., Latreille, J. P., Wilson, R. K., Ganem, F., & DeRisi, J. L. (2003). Viral discovery and sequence recovery using DNA microarrays. *PLoS Biology*, 1(2), E2. <https://doi.org/10.1371/journal.pbio.0000002>

**How to cite this article:** Mohamed, F., Gidlewski, T., Berninger, M. L., Petrowski, H. M., Bracht, A. J., de Rueda, C. B., Barrette, R. W., Grady, M., O'Hearn, E. S., Lewis, C. E., Moran, K. E., Sturgill, T. L., Capucci, L., & Root, J. J. (2022). Comparative susceptibility of eastern cottontails and New Zealand white rabbits to classical rabbit hemorrhagic disease virus (RHDV) and RHDV2. *Transboundary and Emerging Diseases*, 69, e968–e978. <https://doi.org/10.1111/tbed.14381>