









## ORIGINAL ARTICLE

# Cardiorespiratory nematodes and co-infections with gastrointestinal parasites in new arrivals at dog and cat shelters in north-western Spain

Susana Remesar  | David García-Dios  | Néstor Calabuig  | Alberto Prieto  |  
 Jose Manuel Díaz-Cao  | Gonzalo López-Lorenzo  | Ceferino López  |  
 Gonzalo Fernández  | Patrocinio Morrondo  | Rosario Panadero  | Pablo Díaz 

Investigación en Sanidad Animal: Galicia (Grupo INVESAGA), Facultade de Veterinaria, Universidade de Santiago de Compostela, Lugo, Spain

## Correspondence

David García Dios, Investigación en Sanidad Animal: Galicia (Grupo INVESAGA), Facultade de Veterinaria, Universidade de Santiago de Compostela, Lugo, Spain.  
 Email: [david.garcia.dios@rai.usc.es](mailto:david.garcia.dios@rai.usc.es)

## Funding information

Xunta de Galicia, Grant/Award Number: ED431C 2019/04

## Abstract

Metastrongyloid and trichuroid cardiorespiratory nematodes of dogs and cats are considered emergent in several European countries, and an increase in the number and extent of endemic foci has been described. Since data on their prevalence are limited in this continent, faecal samples from new arrivals (365 dogs and 65 cats) at two animal shelters in North-western Spain were analysed using both floatation and Baermann techniques. In order to confirm the microscopic identification of Metastrongylidae first stage larvae, molecular characterization based on the sequence of the ITS-2 was performed. The possible influence of some variables such as the species, sex and age of the animals and the co-infection with other gastrointestinal parasites on the prevalence of cardiorespiratory nematodes was analysed. The most prevalent metastrongylid was *Aelurostrongylus abstrusus* (15.4%) followed by *Angiostrongylus vasorum* (4.1%) and *Crenosoma vulpis* (1.1%). Regarding trichuroids, *Eucoleus aerophilus* and/or *Eucoleus boehmi* eggs were detected in 28 dogs (7.7%) and four cats (6.2%). Almost all animals positive to cardiorespiratory nematodes (86.8%) were co-infected with gastrointestinal parasites. The prevalence of Metastrongylidae and respiratory trichuroids was significantly higher in dogs co-infected with *Taenia* spp. and *Toxocara canis* or *Giardia duodenalis* and *Sarcocystis* spp., respectively. In cats, a significant higher prevalence of Metastrongylidae nematodes was found in animals co-infected with *Toxocara cati*. Our results reveal that cardiorespiratory nematodes are common in companion animals from north-western Spain, showing higher prevalences than those previously reported from this country. This investigation represents the first report of *C. vulpis*, *E. aerophilus* and *E. boehmi* in dogs from Spain. The identification of a number of zoonotic parasites is of public health concern. Our results indicate that these nematodes should be included in the differential diagnosis of dogs and cats from north-western Spain showing respiratory or cardiac clinical signs.

This is an open access article under the terms of the [Creative Commons Attribution-NonCommercial-NoDerivs](https://creativecommons.org/licenses/by-nc-nd/4.0/) License, which permits use and distribution in any medium, provided the original work is properly cited, the use is non-commercial and no modifications or adaptations are made.

© 2022 The Authors. *Transboundary and Emerging Diseases* published by Wiley-VCH GmbH.

## KEYWORDS

*Aelurostrongylus*, *Angiostrongylus*, *Crenosoma*, *Eucoleus*, companion animals, Spain

## 1 | INTRODUCTION

Cardiorespiratory nematodes of dogs and cats have become a major focus for the parasitologist community due to their emergence and/or re-emergence in a number of European countries and their spread into previously non-endemic regions (Taubert et al., 2009; Traversa et al., 2010). Among them, the metastrongyloids *Angiostrongylus vasorum*, *Crenosoma vulpis*, *Aelurostrongylus abstrusus* and *Troglostrongylus brevior* have been reported as the most important species infecting dogs and cats in Europe (Giannelli et al., 2017; Traversa et al., 2010). Trichuroids affecting the respiratory tract of canids and felids such as *Eucoleus aerophilus* (syn. *Capillaria aerophila*) and *Eucoleus boehmi* (syn. *Capillaria boehmi*) are of increasing concern; however, current data on their prevalence in Europe are limited (Di Cesare et al., 2012; Gillis-Germitsch et al., 2020; Sauda et al., 2018; Traversa et al., 2009).

In general, metastrongyloid nematodes infecting dogs and cats have an indirect life-cycle where snails or slugs act as intermediate hosts; it has been also reported that amphibians, reptiles, birds and small mammals can serve as paratenic hosts (Brianti et al., 2021; Di Cesare & Traversa, 2014). Nevertheless, the spectrum of paratenic hosts for metastrongyloids is not yet completely defined; in this respect, recent experimental studies have suggested that some insects such as cockroaches could also act as a paratenic host of *A. abstrusus* (Falsone et al., 2017). In contrast, life-cycle of trichuroid respiratory nematodes has not been completely unravelled; it has been suggested that it may be direct or involve earthworms as facultative intermediate hosts (Traversa et al., 2009, 2010). Both intermediate and paratenic hosts play an important role in the transmission, maintenance and distribution of these nematodes being affected by several factors such as urbanization of wild environments, global warming and movements in animal populations, among others (Morgan et al., 2021; Traversa et al., 2010).

In Europe, cardiorespiratory nematodes are commonly found in wild canids and felids, which can act as reservoir final hosts (De Liberato et al., 2017; Deak et al., 2020; Gillis-Germitsch et al., 2020). Among wild carnivores, foxes are considered the major reservoir hosts of these pathogens (Lemming et al., 2020; Martínez-Rondán, et al., 2019). Nevertheless, cardiorespiratory nematodes are considered sporadic in companion animals from this continent, with reported prevalences around 2% (Traversa et al., 2010). Some authors suggested that these low prevalences could be related to the fact that these nematodes are considered insidious and fatal infections are unusual (Traversa et al., 2010). *A. abstrusus* and *A. vasorum* endemic areas have been reported throughout Europe with prevalences around 24 and 20%, respectively (Barutzki & Schaper, 2009; Elsheikha et al., 2014; Morgan et al., 2008; Payo-Puente et al., 2008; Sauda et al., 2018).

In Spain, most investigations on the prevalence of cardiorespiratory nematodes are restricted to wild animals from northern regions. Thus, the percentage of wolves positive to *Crenosoma* spp. and *E. aerophilus* was lower than 10%, whereas prevalences up to 22% were reported for *A. vasorum* (Garrido-Castañé et al., 2015; Martínez-Rondán et al., 2019); higher prevalences of *A. vasorum* (3.4–43%) and *Crenosoma* spp. and *E. aerophilus* (30–45%) were found in foxes (Garrido-Castañé et al., 2015; Martínez-Rondán et al., 2019). However, the number of studies carried out in domestic animals is scarce. Only two studies were performed in outdoor cats, showing prevalences of 5 and 3% for *A. abstrusus* and *T. brevior*, respectively (Giannelli et al., 2017) and 1.3% for *Eucoleus* spp. (Miró et al., 2004). In addition, the presence of *A. abstrusus* in a domestic cat was also reported in north-western Spain (López et al., 2005). In dogs, antibodies against *A. vasorum* and antigens of this nematode were detected in the 1.7 and 0.75% of the analysed animals, respectively (Carretón et al., 2020; Morchón et al., 2021). No data on the prevalence of other cardiorespiratory nematodes in domestic animals are currently available from this country. For all these reasons, the main objective of the present study was to assess the prevalence of cardiorespiratory nematodes in new arrivals at two dog and cat shelters from Galicia (north-western Spain). In addition, the possible influence of some variables (species, sex and age of the animals and mixed infections with other gastrointestinal parasites) on the prevalence of cardiorespiratory nematodes was studied. Potential public health implications of the detected parasites were also discussed.

## 2 | MATERIALS AND METHODS

### 2.1 | Faecal samples and data collection

Between October 2019 and September 2021, new arrivals (365 dogs and 65 cats) to two shelters ('Sociedad Protectora de Animales y Plantas de Lugo' and 'Centro de Acolida e Protección de Animais – CAAN') were included in the study. All the animals came from Galicia, an autonomous community from north-western Spain with a surface area of 29,574 km<sup>2</sup>. Faecal samples were taken by the veterinarian supervising the shelter before the administration of an anti-parasitic treatment; they were collected from the floor immediately after defecation, deposited in individually labelled plastic containers and refrigerated until processed. Most faecal samples presented firm or pasty consistency, and only eight dogs were diarrhoeic. Veterinarians also provided some data including the species, sex and age of each animal; the age was estimated based on teeth eruption (Silver, 1969) and animals were classified in four age groups: G1 (up to 6 months), G2 (6–12 months), G3 (1–3 years) and G4 (older than 3 years).

## 2.2 | Parasite detection and morphological identification

Faecal samples were examined using classical copromicroscopic methods. Metastrongyloid first stage larvae (L1) were detected in 10 g of faeces using the Baermann–Wetzel technique (MAFF, 1986). L1 were morphologically identified at 400× magnification following previously described morphometric features (Penagos-Tabares et al., 2018; Traversa & Di Cesare, 2013).

In addition, 3 g of faeces were homogenized in 42 ml of water and filtered using a mesh of 150 µm; two 15 ml tubes were filled and centrifuged at 680×g during 5 min. The supernatant was discarded. Eggs of respiratory trichuroids as well as other gastrointestinal parasitic forms were concentrated from the sediment of a single tube using floatation in Sheather's sucrose solution (specific gravity 1.28 g/ml) and identified at 100–400× magnification. Ten microliters of the sediment of the second tube was placed on a slide, air dried and fixed with methanol for 5 min before processed by a commercial immunofluorescent assay for the detection of both *Giardia* cysts and *Cryptosporidium* oocysts (Aqua-Glo G/C Direct Comprehensive Kit; Waterborne Inc, New Orleans, LA, USA) following the manufacturers' instructions.

## 2.3 | Metastrongyloid larvae DNA extraction and molecular identification

In order to confirm the morphological identification of metastrongylid L1, a representative number of samples testing positive to each nematode species were selected. In each selected sample, six L1 of each species were isolated and DNA was extracted using a commercial kit (High Pure PCR Template Preparation Kit, Roche Diagnostics GmbH®, Mannheim, Germany) following manufacturers' instructions. Previously described primers and PCR protocols amplifying a fragment of the internal transcribed spacer 2 (ITS-2) of parasitic helminths (Gasser et al., 1993) were used to molecularly identify the metastrongylid species involved. Nevertheless, no amplification was observed in those samples positive to *A. vasorum* by Baermann's technique. Previous studies reported a variable sensitivity of this PCR assay for *A. vasorum* detection (Al-Sabi et al., 2010; Jefferies et al., 2009; Schug et al., 2018) especially when using faecal samples due to the low DNA concentration and the presence of PCR inhibitors (Jefferies et al., 2011). In addition, sequence analysis of the available ITS-2 *A. vasorum* sequences deposited in GenBank (EU627592 to EU627598; EU915248; KF270683; MN104952; MN178647) showed one to three mutations at the annealing site of the described forward primer (Gasser et al., 1993). Thus, those larvae identified as *A. vasorum* were subjected to a new PCR assay using a novel forward primer (5'-ACRTCTGGTTCAGGGTTGTT-3') modified from Gasser et al. (1993), and a new designed reverse primer (5'-GCAACATCGATGACGGTAGC-3') targeting a ≈330 bp fragment of the ITS-2 of *A. vasorum*. Reverse primer was designed using the online software Primer-BLAST ([https://www.ncbi.nlm.nih.gov/tools/primer-blast/index.cgi?GROUP\\_TARGET=on](https://www.ncbi.nlm.nih.gov/tools/primer-blast/index.cgi?GROUP_TARGET=on)). PCR conditions and protocols

were identical to those previously described (Gasser et al., 1993) except for the annealing step, using a temperature of 53°C for 1 min.

Selected ITS-2 fragments were purified and sequenced on an ABI 3730xl sequencer (Applied Biosystems, Foster City, CA, USA) at the Sequencing and Fragment Analysis Unit of the Santiago de Compostela University. Sequences were aligned and edited using ChromasPro (Technelysium, Brisbane, Australia) and consensus sequences were then scanned against the GenBank database using BLAST. The single unique sequence identified in this study was deposited in GenBank under accession number OM914984.

## 2.4 | Risk factor analysis

All statistical analyses were performed using the statistical software R 4.0.3 (R Core Team, 2020). A logistic regression was used to determine the influence of different factors (animal species, age, sex and co-infection with other parasites – gastrointestinal protozoa, cestodes and nematodes as well as other cardiorespiratory nematodes) on the prevalence of metastrongyloids and trichuroid respiratory nematodes. Factors were eliminated from the initial model using a backward and forward conditional method based in AIC value (Akaike Information Criterion) until the best model was built. Next, all pairwise interactions were evaluated. Odds ratio values were computed by raising 'e' to the power of the logistic coefficient over the reference category. The logistic analyses and the AIC selection were performed with glm() and step() functions (R Core Team, 2020).

## 3 | RESULTS

### 3.1 | Prevalence and molecular identification of cardiorespiratory nematodes parasitizing dogs and cats

Larvae and eggs of cardiorespiratory nematodes were detected in 53 animals (12.3%; 53 out of 430), being the prevalence similar in dogs (11.5%; 42 out of 365) and cats (16.9%; 11 out of 65) (Table 1).

Metastrongyloid L1 were detected in faeces from 27 animals (6.3%; 27 out of 430); although most positive animals were detected using the Baermann–Wetzel technique (77.8%; 21 out of 27), L1 of these nematodes were only found using the floatation method in six animals (22.2%): five dogs and one cat. The prevalence of metastrongyloid nematodes was lower in dogs than in cats and similar when the sex was considered ( $p > .05$ ), regardless of whether they were dogs or cats (Table 1). The percentage of positive dogs was similar when the age was taken into account, ranging from 2.6 to 5.7%; in contrast, such infections appeared to increase with age in cats, achieving a percentage of infection of 37.5% in animals older than 3 years (Table 1).

Three metastrongyloid species were identified after morphometric analysis (Figure 1). The most prevalent was *A. abstrusus* in cats followed by *A. vasorum* and *C. vulpes* in dogs (Table 1). Sequences obtained from *A. vasorum*-positive samples were identical to *A. vasorum* sequences

**TABLE 1** Prevalence of metastrongyloid and trichuroid cardiorespiratory nematodes in dogs and cats from north-western Spain

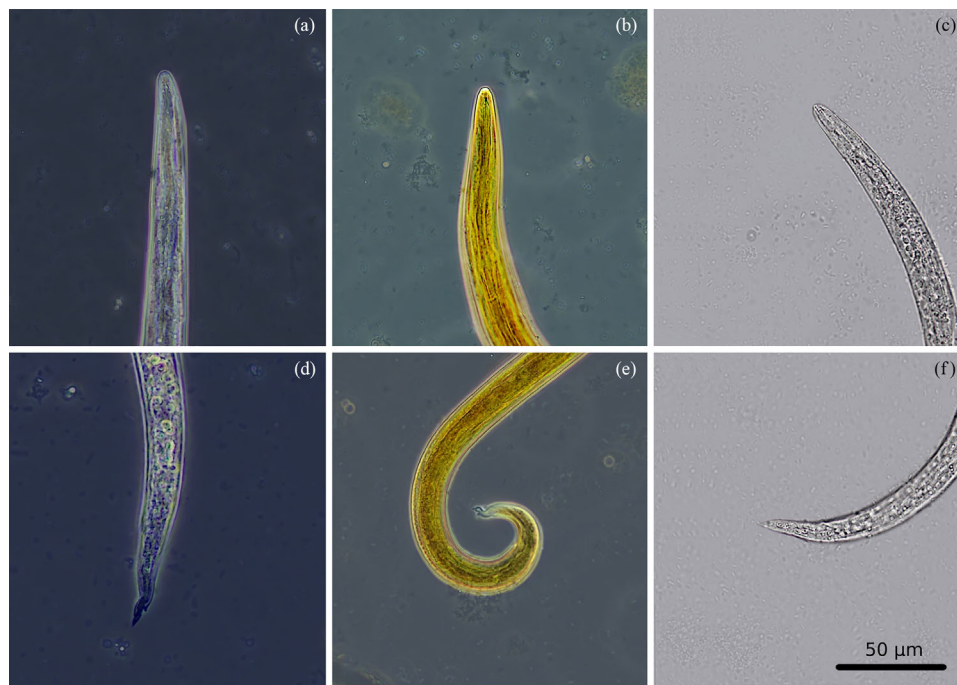	Dog						Cat							
	Sex		Age		Sex		Age		Sex		Age			
	Female Positive/n (%) [CI95%*]	Male Positive/n (%) [CI95%*]	<6 months Positive/n (%) [CI95%*]	6-12 months Positive/n (%) [CI95%*]	1-3 years Positive/n (%) [CI95%*]	>3 years Positive/n (%) [CI95%*]	Total Positive/n (%) [CI95%*]	Female Positive/n (%) [CI95%*]	Male Positive/n (%) [CI95%*]	<6 months Positive/n (%) [CI95%*]	6-12 months Positive/n (%) [CI95%*]	1-3 years Positive/n (%) [CI95%*]	>3 years Positive/n (%) [CI95%*]	Total Positive/n (%) [CI95%*]
<b>Metastrongyloid cardiorespiratory nematodes</b>														
<i>Angiostrongylus vasorum</i>	5/154 (3.2%) [1.2-7.8]	10/211 (4.7%) [2.4-8.8]	3/77 (3.9%) [1.0-11.7]	1/39 (2.6%) [0.1-15.1]	5/126 (4.0%) [1.5-9.5]	6/123 (4.9%) [2.0-10.8]	15/365 (4.1%) [2.4-6.8]	-	-	-	-	-	-	-
<i>Crenosoma vulpis</i>	1/154 (0.6%) [0.0-4.1]	3/211 (1.4%) [0.4-4.4]	2/77 (2.6%) [0.5-9.9]	0/39 (0%) [0.0-11.2]	0/126 (0%) [0.0-3.7]	2/123 (1.6%) [0.3-6.3]	4/365 (1.1%) [0.4-3.0]	-	-	-	-	-	-	-
<i>Aelurostrongylus abstrusus</i>	-	-	-	-	-	-	-	4/24 (16.7%) [5.5-38.2]	6/41 (14.6%) [6.1-29.9]	3/32 (9.4%) [2.5-26.2]	1/4 (25%) [1.3-78.1]	3/21 (14.3%) [3.8-37.3]	3/8 (38.0%) [10.2-740.1]	10/65 (15.4%) [8.0-26.9]
Metastrongyloid Co-infections	0/154 (0.0%) [0.0-3.0]	2/211 (0.9%) [0.2-3.7]	1/77 (1.3%) [0.1-8.0]	0/39 (0%) [0.0-11.2]	0/126 (0%) [0.0-3.7]	1/123 (0.8%) [0.0-5.1]	2/365 (0.5%) [0.0-2.2]	-	-	-	-	-	-	-
Total	6/154 (3.9%) [1.6-8.7]	11/211 (5.2%) [2.8-9.4]	4/77 (5.2%) [1.7-13.5]	1/39 (2.6%) [0.1-15.1]	5/126 (4.0%) [1.5-9.5]	7/123 (5.7%) [4.2-14.8]	17/365 (4.7%) [2.8-7.5]	4/24 (16.7%) [5.5-38.2]	6/41 (14.6%) [6.1-29.9]	3/32 (9.4%) [2.5-26.2]	1/4 (25%) [1.3-78.1]	3/21 (14.3%) [3.8-37.3]	3/8 (37.5%) [10.2-740.1]	10/65 (15.4%) [8.0-26.9]
<b>Trichuroid respiratory nematodes</b>														
<i>Eucoleus aerophilus</i>	15/154 (9.7%) [5.7-15.8]	9/211 (4.3%) [2.1-8.2]	4/77 (5.2%) [1.7-13.5]	4/39 (10.3%) [3.3-25.2]	6/126 (4.8%) [2.0-10.5]	10/123 (8.1%) [4.2-14.8]	24/365 (6.6%) [4.3-9.8]	2/24 (8.3%) [1.5-28.5]	2/41 (4.9%) [0.8-17.8]	2/32 (6.3%) [1.1-22.2]	2/4 (50%) [15-85]	0/21 (0%) [0.0-19.2]	0/8 (0%) [0.0-40.2]	4/65 (6.2%) [1.99-15.8]
<i>Eucoleus boehmi</i>	4/154 (2.6%) [0.8-6.9]	2/211 (0.9%) [0.2-3.7]	0/77 (0%) [0.0-5.9]	1/39 (2.6%) [0.1-15.1]	2/126 (1.6%) [0.3-6.2]	3/123 (2.4%) [0.6-7.5]	6/365 (1.6%) [0.7-3.7]	-	-	-	-	-	-	-

(Continues)

TABLE 1 (Continued)

	Dog						Cat							
	Sex		Age		Age		Sex		Age		Age		Total	
	Female Positive/n (%)	Male Positive/n (%)	<6 months Positive/n (%)	6-12 months Positive/n (%)	1-3 years Positive/n (%)	>3 years Positive/n (%)	Total Positive/n (%)	Female Positive/n (%)	Male Positive/n (%)	<6 months Positive/n (%)	6-12 months Positive/n (%)	1-3 years Positive/n (%)	>3 years Positive/n (%)	Total Positive/n (%)
Trichuroid lungworm	2/154 (1.3%)	0/211 (0%)	0/77 (0%)	1/39 (2.6%)	0/126 (0%)	1/123 (0.8%)	2/365 (0.5%)	-	-	-	-	-	-	-
Co-infections	[0.2-5.1]	[0.0-2.2]	[0.0-5.9]	[0.1-15.1]	[0.0-3.7]	[0.0-5.1]	[0.0-2.2]	-	-	-	-	-	-	-
Total	17/154 (11.0%)	11/211 (5.2%)	4/77 (5.2%)	4/39 (10.3%)	8/126 (6.3%)	12/123 (9.8%)	28/365 (7.7%)	2/24 (8.3%)	2/41 (4.9%)	2/32 (6.3%)	2/4 (50%)	0/21 (0%)	0/8 (0%)	4/65 (6.2%)
	[6.8-17.3]	[2.8-9.4]	[1.7-13.5]	[3.3-25.2]	[3.0-16.8]	[5.4-22.4]	[5.2-11.0]	[1.5-28.5]	[0.8-17.8]	[1.1-22.2]	[15-85]	[0.0-19.2]	[0.0-40.2]	[1.99-15.8]
Total	21/154 (13.6%)	21/211 (10.0%)	7/77 (9.1%)	5/39 (12.8%)	12/126 (9.5%)	18/123 (14.6%)	42/365 (11.5%)	5/24 (20.8%)	6/41 (14.6%)	2/32 (6.3%)	2/4 (50%)	3/21 (14.3%)	3/8 (37.5%)	11/65 (16.9%)
	[8.8-20.3]	[6.4-15.0]	[4.0-18.4]	[4.8-28.2]	[5.2-16.4]	[9.1-22.4]	[8.5-15.3]	[7.9-42.7]	[6.1-29.9]	[1.1-22.2]	[15-85]	[3.8-37.4]	[10.2-740.1]	[9.14-28.7]
Co-infections between metastrongyloid and trichuroid cardiorespiratory nematodes														
<i>A. vasorum</i> + <i>E. aerophilus</i>	2/154 (1.3%)	1/211 (0.5%)	1/77 (1.3%)	-	1/126 (0.8%)	1/123 (0.8%)	3/365 (0.8%)	-	-	-	-	-	-	-
	[0.2-5.1]	[0.0-3.0]	[0.1-8.0]	-	[0.0-5.0]	[0.0-5.1]	[0.2-2.6]	-	-	-	-	-	-	-
<i>A. abstrusus</i> + <i>E. aerophilus</i>	-	-	-	-	-	-	-	1/24 (4.2%)	2/41 (4.9%)	2/32 (6.3%)	1/4 (25%)	-	-	3/65 (4.6%)
	-	-	-	-	-	-	-	[7.9-42.7]	[0.8-17.8]	[1.1-22.2]	[1.3-78.1]	-	-	[1.2-138]

\*CI95%: 95% confidence interval.



**FIGURE 1** Anterior and posterior end of Metastrongilidae first stage larvae detected in dogs and cats from north-western Spain: *Aelurostrongylus abstrusus* (a and d), *Angiostrongylus vasorum* (b and e) and *Crenosoma vulpis* (c and f).

MN104952 and EU627597 obtained in dogs from Italy and the United Kingdom, respectively. Similarly, samples positive to *A. abstrusus* were identical to the *A. abstrusus* sequences DQ372965 and JX948745 obtained in cats from Italy. Finally, sequences obtained from *C. vulpis* positive samples showed a 99.6% similarity when compared to the *C. vulpis* sequence KF836608 from a fox in Germany.

Eggs of respiratory trichuroids were detected in 32 animals (7.4%; 32 out of 430), and the prevalence was similar in dogs and cats (Table 1). Percentage of infections was higher in females than in males in both dogs and cats and the percentage of positive animals was similar for the different age groups (Table 1). Two species of respiratory trichuroids were identified (Figure 2), being *E. aerophilus* more prevalent than *E. boehmi* (Table 1); only *E. aerophilus* was detected in both animal species.

### 3.2 | Detection of mixed infections with gastrointestinal parasites

In addition to cardiorespiratory nematodes, ten digestive parasites (Figures 2 and S1) were also detected (*Cryptosporidium* spp., *Cystoisospora* spp., *Giardia duodenalis*, *Sarcocystis* spp., *Taenia* spp., Ancylostomatidae, *Spirocerca lupi*, *Toxocara* spp., *Toxascaris leonina* and *Trichuris vulpis*). The most prevalent in dogs were Ancylostomatidae nematodes, followed by *Toxocara canis* and *G. duodenalis* (Table 2). In cats, protozoa belonging to the genus *Cystoisospora* and *Giardia* were the most prevalent (Table 2).

Mixed infections with gastrointestinal parasites were found in 37 out of 42 dogs (88.1%) and in nine out of the eleven cats (81.8%) positive to cardiorespiratory nematodes (Table 2). Co-infection with both

families of cardiorespiratory nematodes was uncommon, since it was only detected in three dogs (7.1%; three out of 42) and three cats (27.3%; three out of 11). In animals positive to Metastrongylidae, co-infections with *T. canis* in dogs (58.8%; 10 out of 17) and *T. cati* (80%; eight out of 10) in cats were the most commonly detected (Table 2). The most common co-infection in animals infected with trichuroid respiratory worms was with Ancylostomatidae (39.3%; 11 out of 28) in dogs or with *Cystoisospora* spp. (75%; three out of four) in cats (Table 2).

### 3.3 | Factors influencing the prevalence of cardiorespiratory nematodes

Logistic regression results showed that the prevalence of cardiorespiratory nematodes was only influenced by the presence of co-infections with some gastrointestinal parasites (Table 3). Thus, the prevalence of Metastrongylidae in dogs was significantly higher in those animals co-infected with *Taenia* spp., *T. canis* or *G. duodenalis*. In addition, those dogs positive to *Sarcocystis* spp. had a 4.7-fold probability of being positive to respiratory trichuroid worms (Table 3). In cats, the risk of being infected by Metastrongylidae nematodes was 8.9-fold higher in those animals co-infected with *T. cati* (Table 3).

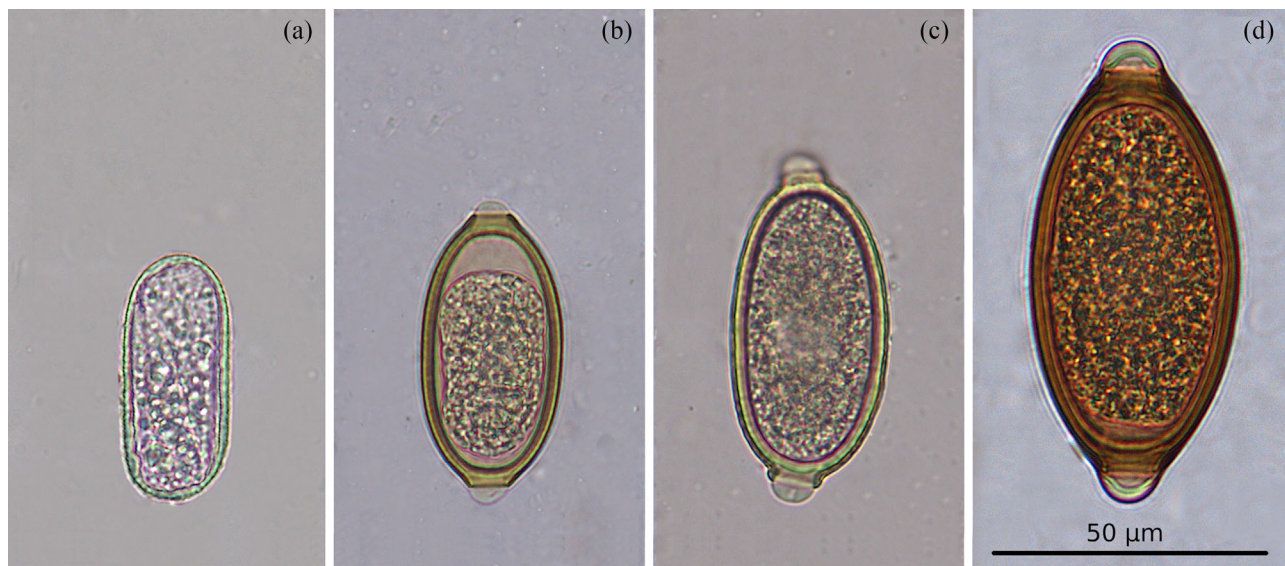
## 4 | DISCUSSION

Our results provide up-to-date information on cardiorespiratory nematodes infecting dogs and cats from Spain including the first report of *C. vulpis*, *E. aerophilus* and *E. boehmi* in dogs from this

**TABLE 2** Percentage of dogs and cats from north-western Spain positive to cardiorespiratory and gastrointestinal parasites and their co-infections

Parasite	Prevalence Positive/n (%) [CI95%*]	Dog (n = 365)		Prevalence Positive/n (%) [CI95%*]	Cat (n = 65)	
		Co-infections			Co-infections	
		Metastrongylidae Positive/n (%) [CI95%*]	Trichuroids Positive/n (%) [CI95%*]		Metastrongylidae Positive/n (%) [CI95%*]	Trichuroids Positive/n (%) [CI95%*]
<b>Protozoa</b>						
<i>Cryptosporidium</i> spp.	7/365 (1.9%) [0.8–4.1]	0/17 (0%) [0.0–22.9]	1/28 (3.6%) [0.2–20.2]	2/65 (3.1%) [0.5–11.6]	0/10 (0%) [0.0–34.5]	0/4 (0%) [0.0–60.4]
<i>Cystoisospora</i> spp.	54/365 (14.8%) [11.4–19.0]	3/17 (17.6%) [4.7–44.2]	5/28 (17.9%) [6.8–37.6]	17/65 (26.2%) [16.4–38.8]	2/10 (20%) [3.5–55.8]	3/4 (75%) [21.9–98.7]
<i>Giardia duodenalis</i>	99/365 (27.1%) [22.7–32.0]	8/17 (47.1%) [23.9–71.5]	8/28 (28.6%) [14.0–48.9]	5/65 (7.7%) [2.9–17.8]	1/10 (10%) [0.5–45.9]	0/4 (0%) [0.0–60.4]
<i>Sarcocystis</i> spp.	20/365 (5.5%) [3.5–8.5]	1/17 (5.9%) [0.3–30.8]	5/28 (17.9%) [6.8–37.6]	0/65 (0%) [0.0–69.5]	–	–
<b>Cestoda</b>						
<i>Taenia</i> spp.	7/365 (1.9%) [0.8–4.1]	2/17 (11.8%) [2.1–37.7]	2/28 (7.1%) [1.2–25.0]	2/65 (3.1%) [0.5–11.6]	1/10 (10%) [0.5–45.9]	1/4 (25%) [1.3–78.1]
<b>Gastrointestinal nematodes</b>						
Ancylostomatidae	114/365 (31.2%) [26.6–36.6]	8/17 (47.1%) [23.9–71.5]	11/28 (39.3%) [22.1–59.3]	3/65 (4.6%) [1.2–13.8]	0/10 (0%) [0.0–34.5]	0/4 (0%) [0.0–60.4]
<i>Toxascaris leonina</i>	4/365 (1.1%) [0.4–3.0]	0/17 (0%) [0.0–22.9]	0/28 (0%) [0.0–15.0]	0/65 (0%) [0.0–7.0]	–	–
<i>Toxocara</i> spp.	101/365 (27.7%) [23.2–32.6]	10/17 (58.8%) [33.5–80.6]	9/28 (32.1%) [16.6–52.4]	25/65 (38.5%) [26.9–51.4]	8/10 (80%) [77.2–96.5]	2/4 (50%) [15.0–85.0]
<i>Trichuris</i> spp.	97/365 (26.6%) [22.2–31.5]	5/17 (29.4%) [11.4–56.0]	10/28 (35.7%) [19.3–55.9]	2/65 (3.1%) [0.5–11.6]	0/10 (0%) [0.0–34.5]	0/4 (0%) [0.0–60.4]
<i>Spirocerca lupi</i>	4/365 (1.1%) [0.4–3.0]	0/17 (0%) [0.0–22.9]	1/28 (3.6%) [0.2–20.2]	–	–	–
<b>Cardiorespiratory nematodes</b>						
<i>Angiostrongylus vasorum</i>	15/365 (4.1%) [2.4–6.8]	15/17 (88.2%) [62.3–98.0]	3/28 (10.7%) [2.8–29.4]	–	–	–
<i>Crenosoma vulpis</i>	4/365 (1.1%) [0.4–3.0]	4/17 (23.5%) [7.8–50.2]	0/28 (0%) [0.0–15.0]	–	–	–
<i>Aelurostrongylus abstrusus</i>	–	–	–	10/65 (15.4%) [8.0–26.9]	–	3/4 (75%) [21.9–98.7]
<i>Eucoleus aerophilus</i>	24/365 (6.6%) [4.3–9.8]	3/17 (17.6%) [4.7–44.2]	24/28 (85.7%) [66.4–95.3]	4/65 (6.2%) [2.0–15.8]	3/10 (30%) [8.1–64.6]	–
<i>Eucoleus boehmi</i>	6/365 (1.6%) [0.7–3.7]	0/17 (0%) [0.0–22.9]	6/28 (21.4%) [9.0–41.5]	–	–	–

\*CI95%: 95% confidence interval.



**FIGURE 2** Eggs of *Spirocerca lupi* (a), *Eucoleus boehmi* (b), *Eucoleus aerophilus* (c) and *Trichuris vulpis* (d) detected in dogs and cats from north-western Spain.

**TABLE 3** GLM model results for the prevalence of metastrongyloid and trichuroid cardiorespiratory nematodes in dogs and cats. Factors were removed following the AIC until the best model was built

Estimate	Z-value	Pr(> t )	OR	CI 95%*	
Dogs					
Metastrongyloids					
(Intercept)	-4.09	-8.56	<0.001	0.017	0.01–0.04
<i>Toxocara canis</i>	1.33	2.58	0.01	3.813	1.39–11.00
<i>Giardia duodenalis</i>	1.07	2.05	0.04	2.935	1.03–8.38
<i>Taenia</i> spp.	2.18	2.37	0.02	8.82	1.13–49.36
Trichuroids					
(Intercept)	-2.64	-12.24	<0.001	0.07	0.05–0.11
<i>Sarcocystis</i> spp.	1.54	2.76	0.001	4.68	1.42–13.34
Cats					
Metastrongyloids					
(Intercept)	-2.94	-4.06	<0.001	0.05	0.01–0.17
<i>Toxocara cati</i>	2.19	2.60	0.01	8.94	1.99–63.59

\*95% confidence interval

country; these data will be very helpful for veterinary practitioners and laboratory technicians. In addition, the *A. vasorum* prevalence was higher than those previously found in Spain (<2%) by immunological techniques (Carretón et al., 2020; Morchón et al., 2021). Prevalence values of dog metastrongyloid nematodes previously reported in other European countries such as Italy, Germany, Denmark and Ireland are usually low and similar to our findings; thus, the percentage of positives to *A. vasorum* and *C. vulpis* ranged from 0.48 to 7.4% and from 0.2 to 6.0%, respectively (Barutzki & Schaper, 2009; De Liberato et al., 2018; Maksimov et al., 2017; Sauda et al., 2018; Taubert

et al., 2009). Prevalence data for *Eucoleus* infections in dogs are limited to a number of investigations carried out in Italy (De Liberato et al., 2018; Sauda et al., 2018; Traversa et al., 2009) also reporting low values for both *E. aerophilus* (1.7–5.5%) and *E. boehmi* (0.8–2.2%) and being similar to those detected in the present study.

The number of investigations on respiratory nematodes in cats from Spain is also scarce (Giannelli et al., 2017; López et al., 2005; Miró et al., 2004) showing lower prevalences for *A. abstrusus* (5%) and *Capillaria* spp. (1.3%) than those found in this study. *A. abstrusus* infection has been reported in domestic cats throughout Europe; noticeable



differences on the prevalence rates can be observed depending on the region (1.7–30.2%), being our results similar to those found in southern countries, where the percentages of infection are generally higher (Barutzki & Schaper, 2009; Diakou et al., 2015; Elsheikha et al., 2019; Genchi et al., 2021; Giannelli et al., 2017; Grandi et al., 2017; Gueldner et al., 2019; Györfi et al., 2020; Hansen et al., 2017; Kiszely et al., 2019; Knaus et al., 2014; Mircean, Titilincu & Vasile, 2010; Payo-Puente et al., 2008; Tonev et al., 2021). It is also worth noting that no positive cats to *T. brevior* were detected in this work although this nematode was previously found in a low number of cats from Spain, Bulgaria, Greece, Italy, Poland and Romania, reaching maximum values close to 15% in some regions (Brianti et al., 2021; Diakou et al., 2015; Genchi et al., 2021; Giannelli et al., 2017). Finally, epidemiological studies reporting the prevalence of respiratory trichuroid nematodes in cats have been performed in Albania, Denmark, Germany, Hungary, Italy, Poland, Portugal, Romania and Spain; our results for *E. aerophilus* (6.2%) are similar to the highest prevalences reported (8.2%) in Europe (Capári et al., 2013; Genchi et al., 2021; Hansen et al., 2017; Krone et al., 2008; Knaus et al., 2014; Mircean et al., 2010; Miró et al., 2004; Tamponi et al., 2017; Traversa et al., 2009; Waap et al., 2014; Wierzbowska et al., 2020). In addition, this parasite has also been identified in domestic cats from other European countries such as France, Hungary, Greece, Belgium and Lithuania (Elhamiani-Khatat, Rosenberg, Benchekroun & Polack, 2016; Haralampides, 1978; Rehbein et al., 2014; Thienpont et al., 1981).

Although veterinarians and pet owners from north-western Spain are usually not concerned about cardiopulmonary nematodes, all the species detected are considered pathogenic for dogs and cats. In this respect, *A. vasorum* infections can be related to respiratory and coagulation disorders or even shock-like reactions in dogs, and *A. abstrusus* can cause respiratory disorders in cats (Conboy, 2009; Deplazes et al., 2016). *Eucoleus* species can cause bronchitis and tracheitis (*E. aerophilus*) or rhinitis (*E. boehmi*) (Conboy, 2009; Deplazes et al., 2016).

It is worth noting that the high prevalences observed may be related to the lifestyle of the sampled animals: all they were new arrivals in the shelter so it is expected that most of them spent some time living outdoors, favouring their contact with intermediate and/or paratenic hosts of cardiorespiratory nematodes (Lemming et al., 2020). In addition, it has been reported that the presence of cardiorespiratory nematodes in companion animals is related to their prevalence in wild carnivores from the same area (Gillis-Germitsch et al., 2020; Lemming et al., 2020; Taylor et al., 2015). In this regard, *A. vasorum* and *C. vulpis* are common parasites of wolves and foxes from Spain since noticeable prevalences (9–44.8%) were reported (Garrido-Castañé et al., 2015; Martínez-Rondán et al., 2019); moreover, *E. aerophilus* has been usually found in wolves and foxes with prevalences ranging from 5 to 33% (Garrido-Castañé et al., 2015; Martínez-Rondán et al., 2019). Our results are consistent with the fact that the study area has the highest density of wolves in Spain (Alonso-Iglesias et al., 2021) as well as one of the highest prevalences of metastrongylid respiratory nematodes in wolves (22%) and foxes (43%) in the country (Martínez-Rondán et al., 2019).

Some investigations have also suggested that climatic conditions can influence the prevalence of cardiorespiratory nematodes. Therefore, a higher percentage of positive wild animals was found in those areas with high average annual rainfall and low average annual temperature; these conditions favour the survival of *A. vasorum* and *C. vulpis* larvae, *E. aerophilus* eggs and their intermediate hosts, which are highly sensitive to desiccation (Tolnai et al., 2015). In addition, these authors also suggested that the prevalence of Metastrongylidae was more influenced by the climatic conditions than that of respiratory trichuroids. This hypothesis also explains the different prevalences found in Europe, suggesting that the prevalence of these parasites is higher in countries with wet and cool climate such as the studied area (average annual rainfall = 1051.9 mm; average annual temperature = 12.0°C). In this respect, higher prevalences of cardiorespiratory nematodes were detected in dogs from northern Spain (1.9–2.7%) than in those from hot and dry southern areas (0.9–1.0%) (Carretón et al., 2020).

The logistic regression indicated that the prevalence of metastrongylid nematodes was significantly related to the prevalence of *Toxocara* spp. in both dogs and cats. In addition, the percentage of dogs positive to metastrongylid nematodes was also associated with *G. duodenalis* and *Taenia* spp. infections. Previous studies indicated that mixed infections of Metastrongylidae and ascarids or *Taenia* spp. are common, suggesting that infected dogs and cats preyed on animals acting as intermediate or paratenic hosts of these parasites (Reperant et al., 2009; Schuster et al., 2016; Waap et al., 2014). The co-infection of Metastrongylidae and *G. duodenalis* may be related to the lifestyle of sampled animals, since dogs and cats living outdoors, in addition of preying, may drink from untreated water contaminated with *G. duodenalis* cysts (Tangtrongsup et al., 2020). In addition, logistic regression results also indicated that the presence of trichuroid respiratory nematodes was significantly associated to *Sarcocystis* spp. infections in dogs, that may be due to the life cycle and epidemiology of both parasites since wildlife are one of their major reservoirs and living outdoors is considered a risk factor for both parasites (Martínez-Rondán et al., 2019; Rudaityte-Lukosiene et al., 2020).

No significant differences in the prevalence of any cardiorespiratory nematode were detected when considering the age or the sex of the animals, agreeing with previous studies (Barutzki & Schaper, 2013; Beugnet et al., 2014; Carretón et al., 2020; Giannelli et al., 2015, 2017). In contrast, some investigations identified young animals as the most susceptible to both *A. vasorum* and *A. abstrusus* infections (Capári et al., 2013; Kiszely et al., 2019; Knaus et al., 2014; Mircean, Titilincu & Vasile, 2010; Morgan & Shaw, 2010).

All the gastrointestinal parasites found in the present study were previously reported in dogs and cats from Spain (Miró et al., 2004; Ortuño et al., 2014) with the exception of *S. lupi* (Figure 2), which was never detected in this country to date. In addition, the number of studies reporting *S. lupi* infections in domestic animals from Europe is low. Although this nematode is pathogenic for dogs causing oesophageal inflammatory nodules, aneurysms, thromboembolism or even sarcomas, its prevalence is unknown in most European countries. Description of autochthonous cases of spirocercosis were reported in

dogs from Italy (Giannelli et al., 2014), Hungary (Psáder et al., 2017) and Romania (Wright et al., 2020); in addition, 10% of dogs from Greece were found to shed *S. lupi* eggs (Mylonakis et al., 2001). The studies carried out in Spain are restricted to foxes, showing prevalences of *Spirocerca vulpis* ranging from 6 to 22.0% (Varcárcel et al., 2018; Martín-Pérez et al., 2020; Sanchis-Monsonís et al. 2019). The detection of *S. lupi* in dogs from the study area suggests that this nematode should be included in the differential diagnosis of dogs with vomiting and/or regurgitation, especially when oesophageal nodules are detected (Mazaki-Tovi et al., 2002).

Although most of the gastrointestinal parasites identified in the present study are commonly detected in free-ranging dogs and cats (Regidor-Cerrillo et al., 2020), weak or moderate infections are usually asymptomatic. However, heavy infections could cause diarrhoea, vomiting, anorexia, apathy and fever; Ancylostomatidae and *Trichuris* spp. infections can also cause anaemia (Deplazes et al., 2016). In addition, in heavy infected puppies, *T. canis* migrating larvae can form disseminated granulomas in liver, lungs, kidney, heart muscle and eyes (Schnieder, Laabs & Welz, 2011). It must also be noted that a number of the gastrointestinal parasites detected in our study are considered zoonotic (Hugh-Jones et al., 1995; Márquez-Navarro et al., 2012); our results have significant public health implications since the most prevalent (*Toxocara* spp., Ancylostomatidae and *T. vulpis*) have been reported to cause human disease. Thus, *Toxocara* species can cause 'larva migrans interna' due to the somatic migration of third instar larvae through different organs (Deplazes et al., 2016). In addition, *Ancylostoma caninum* larvae is one of the causative agents of the 'larva migrans externa' causing cutaneous lesions in humans (Deplazes et al., 2016), and *T. vulpis* can cause gastrointestinal disorders (Bethony et al., 2006). However, further molecular studies are needed for identifying *G. duodenalis* assemblages, *Cryptosporidium* species/genotypes and *Taenia* species involved and thus assessing their zoonotic potential. Regarding cardiorespiratory nematodes, and although its zoonotic potential is less known, *E. aerophilus* has been occasionally identified in humans with respiratory clinical signs (Traversa et al., 2010).

## 5 | CONCLUSIONS

Our results reveal that a number of cardiorespiratory nematodes are present in dogs and cats from north-western Spain. To the authors' best knowledge this investigation represents the first report of *C. vulpis*, *E. aerophilus* and *E. boehmi* in dogs from this country. Our results may reflect the situation in other regions of the country and show the need to perform further and detailed studies in other areas.

In addition to the mild climatic conditions of the study area which may increase the survival rate of the cardiorespiratory nematodes parasitic stages and their intermediate hosts in the environment, the high infection rates detected may be related to the free-living and hunting behaviour of sampled animals. In fact, most of the dogs and cats positive to cardiorespiratory nematodes showed mixed infections with other gastrointestinal parasites, including the first report of *S. lupi* in dogs from Spain.

The emergence and the establishment of endemic foci of cardiorespiratory nematodes in Europe have a special interest for veterinary practitioners and diagnostic laboratories. Our results indicate that, in north-western Spain, these parasites should be included in laboratory diagnostic routine panels as well as in the differential diagnosis of dogs and cats with outdoor access showing respiratory or cardiac clinical signs, leading to the implementation of the most suitable control measures including the effective treatment of affected animals.

## ACKNOWLEDGEMENTS

We would like to thank the veterinarians responsible of the "Sociedad Protectora de Animales y Plantas de Lugo" and "Centro de Acollida e Protección de Animais - CAAN" for their invaluable help in collecting the samples. This research was funded by the Program for consolidating and structuring competitive research groups (ED431C 2019/04, Xunta de Galicia, Spain).

## ETHICS STATEMENT

The authors confirm that the ethical policies of the journal, as noted on the journal's author guidelines page, have been adhered to. According to the legislation for the protection of animals used for scientific purposes, national decree-law RD53/2013(2010/63/EU Directive), ethical review and approval were waived from the USC Ethics Committee for this study since all samples were taken for external practitioners and no invasive methods were used with the included animals.

## CONFLICT OF INTEREST

The authors declare no conflict of interest. The funders had no role in the design of the study; in the collection, analyses, or interpretation of data; in the writing of the manuscript, or in the decision to publish the results.

## DATA AVAILABILITY STATEMENT

The data that support the findings of this study are available from the corresponding author upon reasonable request.

## ORCID

Susana Remesar  <https://orcid.org/0000-0002-8071-3806>

David García-Dios  <https://orcid.org/0000-0001-6364-766X>

Néstor Calabuig  <https://orcid.org/0000-0003-0524-8040>

Alberto Prieto  <https://orcid.org/0000-0002-3211-3494>

Jose Manuel Díaz-Cao  <https://orcid.org/0000-0002-8119-7057>

Gonzalo López-Lorenzo  <https://orcid.org/0000-0001-8047-0413>

Ceferino López  <https://orcid.org/0000-0002-9151-3180>

Gonzalo Fernández  <https://orcid.org/0000-0002-7902-2995>

Patrocinio Morrondo  <https://orcid.org/0000-0001-7171-7162>

Rosario Panadero  <https://orcid.org/0000-0002-3588-7807>

Pablo Díaz  <https://orcid.org/0000-0003-2445-1095>

## REFERENCES

Alonso-Iglesias, P., Martínez-Lago, D., & Hevia-Barcón, M. (2021). Censo da poboación de lobos (*Canis lupus*) do norte de Galicia e estimativa da densidade. *IBADER-Recursos Rurais*, 17, 39–54.

- Al-Sabi, M. N. S., Deplazes, P., Webster, P., Willeßen, J. L., Davidson, R. K., & Kapel, C. M. O. (2010). PCR detection of *Angiostrongylus vasorum* in faecal samples of dogs and foxes. *Parasitology Research*, 107(1), 135–140. <https://doi.org/10.1007/s00436-010-1847-5>
- Ballweber, L. R., Beugnet, F., Marchiondo, A. A., & Payne, P. A. (2014). American Association of Veterinary Parasitologists' review of veterinary fecal flotation methods and factors influencing their accuracy and use—Is there really one best technique? *Veterinary Parasitology*, 204(1–2), 73–80. <https://doi.org/10.1016/j.vetpar.2014.05.009>
- Barutzki, D., & Schaper, R. (2009). Natural Infections of *Angiostrongylus vasorum* and *Crenosoma vulpis* in dogs in Germany (2007–2009). *Parasitology Research*, 105, S39–S48. <https://doi.org/10.1007/s00436-009-1494-x>
- Barutzki, D., & Schaper, R. (2013). Occurrence and regional distribution of *Aelurostrongylus abstrusus* in cats in Germany. *Parasitology Research*, 112(2), 855–861. <https://doi.org/10.1007/s00436-012-3207-0>
- Bethony, J., Brooker, S., Albonico, M., Geiger, S. M., Loukas, A., Diemert, D., & Hotez, P. J. (2006). Soil-transmitted helminth infections: ascariasis, trichuriasis, and hookworm. *Lancet*, 367(9521), 1521–1532. [https://doi.org/10.1016/S0140-6736\(06\)68653-4](https://doi.org/10.1016/S0140-6736(06)68653-4)
- Beugnet, F., Bourdeau, P., Chalvet-Monfray, K., Cozma, V., Farkas, R., Guillot, J., Halos, L., Joachim, A., Losson, B., Miró, G., Otranto, D., Renaud, M., & Rinaldi, L. (2014). Parasites of domestic owned cats in Europe: co-infections and risk factors. *Parasites & Vectors*, 7, 291. <https://doi.org/10.1186/1756-3305-7-291>
- Brianti, E., Varcasia, A., & Otranto, D. (2021). *Troglostrongylus brevior*. *Trends in Parasitology*, 37(6), 569–570. <https://doi.org/10.1016/j.pt.2020.11.006>
- Capári, B., Hamel, D., Visser, M., Winter, R., Pfister, K., & Rehbein, S. (2013). Parasitic infections of domestic cats, *Felis catus*, in western Hungary. *Veterinary Parasitology*, 192(1–3), 33–42. <https://doi.org/10.1016/j.vetpar.2012.11.011>
- Carretón, E., Morchón, R., Falcón-Cordón, Y., Matos, J., Costa-Rodríguez, N., & Montoya-Alonso, J. A. (2020). First epidemiological survey of *Angiostrongylus vasorum* in domestic dogs from Spain. *Parasites & Vectors*, 13(1), . <https://doi.org/10.1186/s13071-020-04180-5>
- Conboy, G. (2009). Helminth parasites of the canine and feline respiratory tract. *Veterinary Clinics of North America—Small Animal Practice*, 39(6), 1109. <https://doi.org/10.1016/j.cvsm.2009.06.006>
- Deak, G., Gherman, C. M., Ionica, A. M., Peter, A., Sandor, D. A., & Mihalca, A. D. (2020). Biotic and abiotic factors influencing the prevalence, intensity and distribution of *Eucoleus aerophilus* and *Crenosoma vulpis* in red foxes, *Vulpes vulpes* from Romania. *International Journal for Parasitology—Parasites and Wildlife*, 12, 121–125. <https://doi.org/10.1016/j.ijppaw.2020.05.009>
- Di Cesare, A., Castagna, G., Otranto, D., Meloni, S., Milillo, P., Latrofa, M. S., Paoletti, B., Bartolini, R., & Traversa, D. (2012). Molecular detection of *Capillaria aerophila*, an agent of canine and feline pulmonary capillariasis. *Journal of Clinical Microbiology*, 50(6), 1958–1963. <https://doi.org/10.1128/JCM.00103-12>
- De Liberato, C., Grifoni, G., Lorenzetti, R., Meoli, R., Cocumelli, C., Mastromattei, A., Scholl, F., Rombolà, P., Calderini, P., Bruni, G., & Eleni, C. (2017). *Angiostrongylus vasorum* in wolves in Italy: prevalence and pathological findings. *Parasites & Vectors*, 10. <https://doi.org/10.1186/s13071-017-2307-1>
- De Liberato, C., Berrilli, F., Odorizi, L., Scarcella, R., Barni, M., Amoroso, C., Scarito, A., Filippo, M., Carvelli, A., Iacoponi, F., & Scaramozzino, P. (2018). Parasites in stray dogs from Italy: Prevalence, risk factors and management concerns. *Acta Parasitologica*, 63(1), 27–32. <https://doi.org/10.1515/ap-2018-0003>
- Deplazes, P., Eckert, J., Mathis, A., von Samson-Himmelstjerna, G., & Zahner, H., (2016). *Parasitology in veterinary medicine*. Wageningen Academic Publishers, Wageningen, The Netherlands. pp. 650.
- Di Cesare, A., & Traversa, D. (2014). Canine angiostrongylosis: recent advances in diagnosis, prevention, and treatment. *Veterinary Medicine (Auckland, N.Z.)*, 5, 181–192. <https://doi.org/10.2147/vmr.s53641>
- Diakou, A., Di Cesare, A., Barros, L. A., Morelli, S., Halos, L., Beugnet, F., & Traversa, D. (2015). Occurrence of *Aelurostrongylus abstrusus* and *Troglostrongylus brevior* in domestic cats in Greece. *Parasites & Vectors*, 8. <https://doi.org/10.1186/s13071-015-1200-z>
- Elhamiani-Khatat, S., Rosenberg, D., Benchekroun, G., & Polack, B. (2016). Lungworm *Eucoleus aerophilus* (*Capillaria aerophila*) infection in a feline immunodeficiency virus-positive cat in France. *Journal of Feline Medicine and Surgery Open Reports*, 2(1), 2055116916651649. <https://doi.org/10.1177/2055116916651649>
- Elsheikha, H. M., Holmes, S. A., Wright, I., Morgan, E. R., & Lacher, D. W. (2014). Recent advances in the epidemiology, clinical and diagnostic features, and control of canine cardio-pulmonary angiostrongylosis. *Veterinary Research*, 45(1), 92. <https://doi.org/10.1186/s13567-014-0092-9>
- Elsheikha, H. M., Wright, I., Wang, B., & Schaper, R. (2019). Prevalence of feline lungworm *Aelurostrongylus abstrusus* in England. *Veterinary Parasitology—Regional Studies and Reports*, 16. <https://doi.org/10.1016/j.vprsr.2019.100271>
- Falsone, L., Colella, V., Napoli, E., Brianti, E., & Otranto, D. (2017). The cockroach *Periplaneta americana* as a potential paratenic host of the lungworm *Aelurostrongylus abstrusus*. *Experimental Parasitology*, 182, 54–57. <https://doi.org/10.1016/j.exppara.2017.09.023>
- Garrido-Castañé, I., Ortuno, A., Marco, I., & Castella, J. (2015). Cardiopulmonary helminths in foxes from the Pyrenees. *Acta Parasitologica*, 60(4), 712–715. <https://doi.org/10.1515/ap-2015-0101>
- Gasser, R. B., Chilton, N. B., Hoste, H., & Beveridge, I. (1993). Rapid sequencing of rDNA from single worms and eggs of parasitic helminths. *Nucleic Acids Research*, 21(10), 2525–2526. <https://doi.org/10.1093/nar/21.10.2525>
- Genchi, M., Vismarra, A., Zanet, S., Morelli, S., Galuppi, R., Cringoli, G., Lia, R., Diaferia, M., Frangipane di Regalbono, A., Venegoni, G., Solari-Basano, F., Varcasia, A., Perrucci, S., Musella, V., Brianti, E., Gazzonis, A., Drigo, M., Colombo, L., & Kramer, L. (2021). Prevalence and risk factors associated with cat parasites in Italy: a multicenter study. *Parasites & Vectors*, 14(1). <https://doi.org/10.1186/s13071-021-04981-2>
- Giannelli, A., Ramos, R. A., Annoscia, G., Di Cesare, A., Colella, V., Brianti, E., Dantas-Torres, F., Mutafchiev, Y., & Otranto, D. (2014). Development of the feline lungworms *Aelurostrongylus abstrusus* and *Troglostrongylus brevior* in *Helix aspersa* snails. *Parasitology*, 141(4), 563–569. <https://doi.org/10.1017/s003118201300187x>
- Giannelli, A., Brianti, E., Varcasia, A., Colella, V., Tamponi, C., Di Paola, G., Knaus, M., Halos, L., Beugnet, F., & Otranto, D. (2015). Efficacy of Broadline (R) spot-on against *Aelurostrongylus abstrusus* and *Troglostrongylus brevior* lungworms in naturally infected cats from Italy. *Veterinary Parasitology*, 209(3–4), 273–277. <https://doi.org/10.1016/j.vetpar.2015.02.037>
- Giannelli, A., Capelli, G., Joachim, A., Hinney, B., Losson, B., Kirkova, Z., René-Martellet, M., Papadopoulos, E., Farkas, R., Napoli, E., Brianti, E., Tamponi, C., Varcasia, A., Margarida Alho, A., Madeira de Carvalho, L., Cardoso, L., Maia, C., Mircean, V., Mihalca, A. D., ... Otranto, D. (2017). Lungworms and gastrointestinal parasites of domestic cats: a European perspective. *International Journal for Parasitology*, 47(9), 517–528. <https://doi.org/10.1016/j.ijpara.2017.02.003>
- Gillis-Germitsch, N., Muller, S., Gori, F., & Schnyder, M. (2020). *Capillaria boehmi* (syn. *Eucoleus boehmi*): Challenging treatment of a rarely diagnosed nasal nematode in dogs and high prevalence in Swiss foxes. *Veterinary Parasitology*, 281. <https://doi.org/10.1016/j.vetpar.2020.109103>
- Grandi, G., Comin, A., Ibrahim, O., Schaper, R., Forshell, U., & Lind, E. O. (2017). Prevalence of helminth and coccidian parasites in Swedish outdoor cats and the first report of *Aelurostrongylus abstrusus* in Sweden: a coprological investigation. *Acta Veterinaria Scandinavica*, 59(1), 19. <https://doi.org/10.1186/s13028-017-0287-y>
- Gueldner, E. K., Schuppisser, C., Borel, N., Hilbe, M., & Schnyder, M. (2019). First case of a natural infection in a domestic cat (*Felis catus*) with the canid heart worm *Angiostrongylus vasorum*. *Veterinary Parasitology*,

- Regional Studies and Reports*, 18, 100342. <https://doi.org/10.1016/j.vprsr.2019.100342>
- Gyö rke, A., Dumitrache, M. O., Kalmár, Z., Paştiu, A. I., & Mircean, V. (2020). Molecular survey of metastrongyloid lungworms in domestic cats (*Felis silvestris catus*) from Romania: a retrospective study (2008–2011). *Pathogens (Basel, Switzerland)*, 9(2), 80. <https://doi.org/10.3390/pathogens9020080>
- Hansen, A. P., Skarbye, L. K., Vinther, L. M., Willesen, J. L., Pipper, C. B., Olsen, C. S., & Mejer, H. (2017). Occurrence and clinical significance of *Aelurostrongylus abstrusus* and other endoparasites in Danish cats. *Veterinary Parasitology*, 234, 31–39. <https://doi.org/10.1016/j.vetpar.2016.12.015>
- Haralampides, S. T. (1978). Contribution to the study of cat's parasites and their public health importance. *Journal of the Hellenic Veterinary Medical Society*, 21, 117–119.
- Hugh-Jones, M. E., Hubbert, W. T., & Hagstad, H. V. (1995). *Zoonoses. Recognition, Control, and Prevention*. 1st ed. Iowa State University Press.
- Jefferies, R., Shaw, S. E., Viney, M. E., & Morgan, E. R. (2009). *Angiostrongylus vasorum* from South America and Europe represent distinct lineages. *Parasitology*, 136(1), 107–115. <https://doi.org/10.1017/S0031182008005258>
- Jefferies, R., Morgan, E. R., Helm, J., Robinson, M., & Shaw, S. E. (2011). Improved detection of canine *Angiostrongylus vasorum* infection using real-time PCR and indirect ELISA. *Parasitology Research*, 109(6), 1577–1583. <https://doi.org/10.1007/s00436-011-2414-4>
- Knaus, M., Rapti, D., Shukullari, E., Kusi, I., Postoli, R., Xhaxhiu, D., Silaghi, C., Hamel, D., Visser, M., Winter, R., & Rehbein, S. (2014). Characterisation of ecto- and endoparasites in domestic cats from Tirana, Albania. *Parasitology Research*, 113(9), 3361–3371. <https://doi.org/10.1007/s00436-014-3999-1>
- Kiszely, S., Gyurkovszky, M., Solymosi, N., & Farkas, R. (2019). Survey of lungworm infection of domestic cats in Hungary. *Acta Veterinaria Hungarica*, 67(3), 407–417. <https://doi.org/10.1556/004.2019.041>
- Krone, O., Guminsky, O., Meinig, H., Herrmann, M., Trinzen, M., & Wibbelt, G. (2008). Endoparasite spectrum of wild cats (*Felis silvestris* Schreber, 1777) and domestic cats (*Felis catus* L.) from the Eifel, Pfalz region and Saarland, Germany. *European Journal of Wildlife Research*, 54, 95–100.
- Lemming, L., Jorgensen, A. C., Nielsen, L. B., Nielsen, S. T., Mejer, H., Chriell, M., & Petersen, H. H. (2020). Cardiopulmonary nematodes of wild carnivores from Denmark: Do they serve as reservoir hosts for infections in domestic animals? *International Journal for Parasitology-Parasites and Wildlife*, 13, 90–97. <https://doi.org/10.1016/j.ijppaw.2020.08.001>
- López, C., Panadero, R., Paz, A., Sánchez-Andrade, R., Díaz, P., Díez-Baños, P., & Morondo, P. (2005). Larval development of *Aelurostrongylus abstrusus* (Nematoda, Angiostrongylidae) in experimentally infected *Ceruellia (Ceruellia) virgata* (Mollusca, Helicidae). *Parasitology research*, 95(1), 13–16. <https://doi.org/10.1007/s00436-004-1244-z>
- MAFF. (1986). *Manual of veterinary parasitological laboratory techniques*. London, Her Majesty's Stationery Office.
- Maksimov, P., Hermosilla, C., Taubert, A., Staubach, C., Sauter-Louis, C., Conraths, F. J., Vrhovec, M. G., & Pantchev, N. (2017). GIS-supported epidemiological analysis on canine *Angiostrongylus vasorum* and *Crenosoma vulpis* infections in Germany. *Parasites & Vectors*, 10, <https://doi.org/10.1186/s13071-017-2054-3>
- Márquez-Navarro, A., García-Bracamontes, G., Alvarez-Fernández, B. E., Ávila-Caballero, L. P., Santos-Aranda, I., Díaz-Chiguer, D. L., Sánchez-Manzano, R. M., Rodríguez-Bataz, E., & Nogueada-Torres, B. (2012). *Trichuris vulpis* (Froelich, 1789) infection in a child: a case report. *The Korean Journal of Parasitology*, 50(1), 69–71. <https://doi.org/10.3347/kjp.2012.50.1.69>
- Martín-Pérez, M., Lobo, J. M., Pérez-Martín, J. E., Bravo-Barriga, D., Galapero, J., & Frontera, E. (2020). Occurrence, prevalence, and explanatory environmental variables of *Spirocerca vulpis* infestation in the foxes of western Spain. *Parasitology Research*, 119(3), 973–983. <https://doi.org/10.1007/s00436-019-06590-6>
- Martínez-Rondán, F. J., Ruiz de Ybáñez, M. R., López-Beceiro, A. M., Fidalgo, L. E., Berriatua, E., Lahat, L., Sacristán, I., Oleaga, Á., & Martínez-Carrasco, C. (2019). Cardiopulmonary nematode infections in wild canids: Does the key lie on host-prey-parasite evolution? *Research in Veterinary Science*, 126, 51–58. <https://doi.org/10.1016/j.rvsc.2019.08.008>
- Mazaki-Tovi, M., Baneth, G., Aroch, I., Harrus, S., Kass, P. H., Ben-Ari, T., Zur, G., Aizenberg, I., Bark, H., & Lavy, E. (2002). Canine spirocercosis: clinical, diagnostic, pathologic, and epidemiologic characteristics. *Veterinary Parasitology*, 107(3), 235–250. [https://doi.org/10.1016/S0304-4017\(02\)00118-8](https://doi.org/10.1016/S0304-4017(02)00118-8)
- Mircean, V., Titilincu, A., & Vasile, C. (2010). Prevalence of endoparasites in household cat (*Felis catus*) populations from Transylvania (Romania) and association with risk factors. *Veterinary Parasitology*, 171(1–2), 163–166. <https://doi.org/10.1016/j.vetpar.2010.03.005>
- Miró, G., Montoya, A., Jiménez, S., Frisuelos, C., Mateo, M., & Fuentes, I. (2004). Prevalence of antibodies to *Toxoplasma gondii* and intestinal parasites in stray, farm and household cats in Spain. *Veterinary Parasitology*, 126(3), 249–255. <https://doi.org/10.1016/j.vetpar.2004.08.015>
- Morchón, R., Montoya-Alonso, J. A., Sánchez-Agudo, J. Á., de Vicente-Bengochea, J., Murcia-Martínez, X., & Carretón, E. (2021). *Angiostrongylus vasorum* in domestic dogs in Castilla y León, Iberian Peninsula, Spain. *Animals*, 11, 1513. <https://doi.org/10.3390/ani11061513>
- Morgan, E. R., Tomlinson, A., Hunter, S., Nichols, T., Roberts, E., Fox, M. T., & Taylor, M. A. (2008). *Angiostrongylus vasorum* and *Euclolea aerophilus* in foxes (*Vulpes vulpes*) in Great Britain. *Veterinary Parasitology*, 154(1–2), 48–57. <https://doi.org/10.1016/j.vetpar.2008.02.030>
- Morgan, E., & Shaw, S. (2010). *Angiostrongylus vasorum* infection in dogs: continuing spread and developments in diagnosis and treatment. *Journal of Small Animal Practice*, 51(12), 616–621. <https://doi.org/10.1111/j.1748-5827.2010.01000.x>
- Morgan, E. R., Modry, D., Paredes-Esquivel, C., Foronda, P., & Traversa, D. (2021). Angiostrongylosis in animals and humans in Europe. *Pathogens (Basel, Switzerland)*, 10(10), 1236. <https://doi.org/10.3390/pathogens10101236>
- Mylonakis, M. E., Koutinas, A. F., Liapi, M. V., Saridomichelakis, M. N., & Rallis, T. S. (2001). A comparison of the prevalence of *Spirocerca lupi* in three groups of dogs with different life and hunting styles. *Journal of Helminthology*, 75(4), 359–361. <https://doi.org/10.1017/S0022149X01000555>
- Ortuño, A., Scorza, V., Castellà, J., & Lappin, M. (2014). Prevalence of intestinal parasites in shelter and hunting dogs in Catalonia, Northeastern Spain. *Veterinary Journal (London, England : 1997)*, 199(3), 465–467. <https://doi.org/10.1016/j.tvjl.2013.11.022>
- Payo-Puente, P., Botelho-DiniS, M., Uruena, A. M. C., Payo-Puente, M., Gonzalo-Orden, J. M., & Rojo-Vazquez, F. A. (2008). Prevalence study of the lungworm *Aelurostrongylus abstrusus* in stray cats of Portugal. *Journal of Feline Medicine and Surgery*, 10(3), 242–246. <https://doi.org/10.1016/j.jfms.2007.12.002>
- Penagos-Tabares, F., Lange, M. K., Chaparro-Gutierrez, J. J., Taubert, A., & Hermosilla, C. (2018). *Angiostrongylus vasorum* and *Aelurostrongylus abstrusus*: Neglected and underestimated parasites in South America. *Parasites & Vectors*, 11, <https://doi.org/10.1186/s13071-018-2765-0>
- Psáder, R., Balogh, M., Papa, K., Sterczar, A., Lukacs, Z., & Harnos, A. (2017). Occurrence of *Spirocerca lupi* infection in Hungarian dogs referred for gastroscopy. *Parasitology Research*, 116, S99–S107. <https://doi.org/10.1007/s00436-017-5496-9>
- Regidor-Cerrillo, J., Arranz-Solis, D., Moreno-Gonzalo, J., Pedraza-Díaz, S., Gomez-Bautista, M., Ortega-Mora, L. M., & Collantes-Fernández, E. (2020). Prevalence of intestinal parasite infections in stray and farm dogs from Spain. *Brazilian Journal of Veterinary Parasitology*, 29(3), e014920. <https://doi.org/10.1590/S1984-296120200063>
- Rehbein, S., Capári, B., Duscher, G., Keidane, D., Kirkova, Z., Petkevicius, S., Rapti, D., Wagner, A., Wagner, T., Chester, S. T., Rosentel, J., Tielemans, E., Visser, M., Winter, R., Kley, K., & Knaus, M. (2014). Efficacy against nematode and cestode infections and safety of a novel topical fipronil,

- (S)-methoprene, eprinomectin and praziquantel combination product in domestic cats under field conditions in Europe. *Veterinary Parasitology*, 202(1-2), 10–17. <https://doi.org/10.1016/j.vetpar.2014.02.032>
- Reperant, L. A., Hegglin, D., Tanner, I., Fischer, C., & Deplazes, P. (2009). Rodents as shared indicators for zoonotic parasites of carnivores in urban environments. *Parasitology*, 136(3), 329–337. <https://doi.org/10.1017/S0031182008005428>
- Rudaityte-Lukosiene, E., Prakas, P., Strazdaite-Zieliene, Z., Serviene, E., Januskevicius, V., & Butkauskas, D. (2020). Molecular identification of two *Sarcocystis* species in fallow deer (*Dama dama*) from Lithuania. *Parasitology International*, 75, <https://doi.org/10.1016/j.parint.2019.102044>
- Sanchis-Monsonís, G., Fanelli, A., Tizzani, P., & Martínez-Carrasco, C. (2019). First epidemiological data on *Spirocerca vulpis* in the red fox: A parasite of clustered geographical distribution. *Veterinary Parasitology, Regional Studies and Reports*, 18, 100338. <https://doi.org/10.1016/j.vprsr.2019.100338>
- Sauda, F., Malandrucchio, L., Macrì, G., Scarpulla, M., De Liberato, C., Terracciano, G., Fichi, G., Berrilli, F., & Perrucci, S. (2018). *Leishmania infantum*, *Dirofilaria* spp. and other endoparasite infections in kennel dogs in central Italy. *Parasite*, 25, <https://doi.org/10.1051/parasite/2018001>
- Schnieder, T., Laabs, E. M., & Welz, C. (2011). Larval development of *Toxocara canis* in dogs. *Veterinary Parasitology*, 175(3-4), 193–206. <https://doi.org/10.1016/j.vetpar.2010.10.027>
- Schug, K., Kraemer, F., Schaper, R., Hirzmann, J., Failing, K., Hermsilla, C., & Taubert, A. (2018). Prevalence survey on lungworm (*Angiostrongylus vasorum*, *Crenosoma vulpis*, *Eucoleus aerophilus*) infections of wild red foxes (*Vulpes vulpes*) in central Germany. *Parasites & Vectors*, 11, <https://doi.org/10.1186/s13071-018-2672-4>
- Schuster, R. K., Sivakumar, S., & Kinne, J. (2016). Life cycle and morphology of development stages of *Physoccephalus dromedarii* (Nematoda: Spirocercaidae). *Asian Pacific Journal of Tropical Biomedicine*, 6(10), 825–829. <https://doi.org/10.1016/j.apjtb.2016.08.001>
- Silver, I. A. (1969). The ageing of domestic animals. In: Brothwell, D., Higgs, E.S. (Eds.), *Science in Archaeology. Thames and Hudson*, London, pp. 283e302.
- Tamponi, C., Varcasia, A., Pinna, S., Melis, E., Melosu, V., Zidda, A., Sanna, G., Pipia, A. P., Zedda, M. T., Pau, S., Brianti, E., & Scala, A. (2017). Endoparasites detected in faecal samples from dogs and cats referred for routine clinical visit in Sardinia, Italy. *Veterinary Parasitology, Regional Studies and Reports*, 10, 13–17. <https://doi.org/10.1016/j.vprsr.2017.07.001>
- Tangtrongsup, S., Scorza, A. V., Reif, J. S., Ballweber, L. R., Lappin, M. R., & Salman, M. D. (2020). Seasonal distributions and other risk factors for *Giardia duodenalis* and *Cryptosporidium* spp. infections in dogs and cats in Chiang Mai, Thailand. *Preventive Veterinary Medicine*, 174, <https://doi.org/10.1016/j.prevetmed.2019.104820>
- Taubert, A., Pantchev, N., Vrhovec, M. G., Bauer, C., & Hermsilla, C. (2009). Lungworm infections (*Angiostrongylus vasorum*, *Crenosoma vulpis*, *Aelurostrongylus abstrusus*) in dogs and cats in Germany and Denmark in 2003–2007. *Veterinary Parasitology*, 159(2), 175–180. <https://doi.org/10.1016/j.vetpar.2008.10.005>
- Taylor, C. S., Garcia Gato, R., Learmount, J., Aziz, N. A., Montgomery, C., Rose, H., Coulthwaite, C. L., McGarry, J. W., Forman, D. W., Allen, S., Wall, R., & Morgan, E. R. (2015). Increased prevalence and geographic spread of the cardiopulmonary nematode *Angiostrongylus vasorum* in fox populations in Great Britain. *Parasitology*, 142(9), 1190–1195. <https://doi.org/10.1017/S0031182015000463>
- Thienpont, D., Vanparijs, O., & Hermans, L. (1981). Epidemiology of helminths of cats in Belgium. Prevalence of *Ollulanus tricuspis*. *Recueil de Médecine Veterinaire*, 157(7-8), 591–595.
- Tolnai, Z., Szell, Z., & Sreter, T. (2015). Environmental determinants of the spatial distribution of *Angiostrongylus vasorum*, *Crenosoma vulpis* and *Eucoleus aerophilus* in Hungary. *Veterinary Parasitology*, 207(3-4), 355–358. <https://doi.org/10.1016/j.vetpar.2014.12.008>
- Tonev, A. S., Kirkova, Z., Iliev, P. T., Roussenov, A., Chaprazov, T., Roydev, R., & Pirovski, N. (2021). Clinical case of life-threatening co-infection due to *Dirofilaria immitis* and *Aelurostrongylus abstrusus* in a cat: first report of feline heartworm disease in Bulgaria. *Helminthologia*, 58(1), 106–114. <https://doi.org/10.2478/helm-2021-0005>
- Traversa, D., Di Cesare, A., Milillo, P., Iorio, R., & Otranto, D. (2009). Infection by *Eucoleus aerophilus* in dogs and cats: Is another extra-intestinal parasitic nematode of pets emerging in Italy? *Research in Veterinary Science*, 87(2), 270–272. <https://doi.org/10.1016/j.rvsc.2009.02.006>
- Traversa, D., Di Cesare, A., & Conboy, G. (2010). Canine and feline cardiopulmonary parasitic nematodes in Europe: emerging and underestimated. *Parasites & Vectors*, 3, <https://doi.org/10.1186/1756-3305-3-62>
- Traversa, D., & Di Cesare, A. (2013). Feline lungworms: what a dilemma. *Trends in Parasitology*, 29(9), 423–430. <https://doi.org/10.1016/j.pt.2013.07.004>
- Waap, H., Gomes, J., & Nunes, T. (2014). Parasite communities in stray cat populations from Lisbon, Portugal. *Journal of Helminthology*, 88(4), 389–395. <https://doi.org/10.1017/S0022149X1300031x>
- Wierzbowska, I. A., Kornaś, S., Piontek, A. M., & Rola, K. (2020). The prevalence of endoparasites of free ranging cats (*Felis catus*) from urban habitats in Southern Poland. *Animals*, 10(4), 748. <https://doi.org/10.3390/ani10040748>
- Wright, I., Collins, M., McGarry, J., Teodoru, S., Constantin, S. A., Corfield, E. L., & Harding, I. (2020). Threat of exotic worms in dogs imported from Romania. *The Veterinary Record*, 187(9), 348–349. <https://doi.org/10.1136/vr.m4207>

## SUPPORTING INFORMATION

Additional supporting information can be found online in the Supporting Information section at the end of this article.

**How to cite this article:** Remesar, S., García-Dios, D., Calabuig, N., Prieto, A., Díaz-Cao, J. M., López-Lorenzo, G., López, C., Fernández, G., Morrondo, P., Panadero, R., & Díaz, P. (2022). Cardiorespiratory nematodes and co-infections with gastrointestinal parasites in new arrivals at dog and cat shelters in north-western Spain. *Transboundary and Emerging Diseases*, 1–13. <https://doi.org/10.1111/tbed.14670>