



Hilfiker, R., Egger, M. E., Hunkeler, M., Limacher, A., Leunig, M., & Reichenbach, S. (2022). Is Internal Rotation Measurement of the Hip Useful for Ruling in Cam or Pincer Morphology in Asymptomatic Males? A Diagnostic Accuracy Study. *Clinical Orthopaedics and Related Research*, 480(10), 1989-1998.
<https://doi.org/10.1097/CORR.0000000000002244>

Publisher's PDF, also known as Version of record

License (if available):
CC BY-NC-ND

Link to published version (if available):
[10.1097/CORR.0000000000002244](https://doi.org/10.1097/CORR.0000000000002244)

[Link to publication record in Explore Bristol Research](#)
PDF-document


This is the final published version of the article (version of record). It first appeared online via Lippincott, Williams & Wilkins at [10.1097/CORR.0000000000002244](https://doi.org/10.1097/CORR.0000000000002244). Please refer to any applicable terms of use of the publisher

University of Bristol - Explore Bristol Research

General rights

This document is made available in accordance with publisher policies. Please cite only the published version using the reference above. Full terms of use are available:
<http://www.bristol.ac.uk/red/research-policy/pure/user-guides/ebr-terms/>

Is Internal Rotation Measurement of the Hip Useful for Ruling in Cam or Pincer Morphology in Asymptomatic Males? A Diagnostic Accuracy Study

Roger Hilfiker PhD^{1,2} , Marc Hunkeler Dr med¹, Andreas Limacher PhD³, Michael Leunig Dr med⁴, Harald Bonel Dr med^{5,6}, Matthias Egger Dr med^{1,7}, Peter Jüni Dr med⁸, Stephan Reichenbach Dr med^{1,9}

Received: 5 October 2021 / Revised: 14 March 2022 / Accepted: 21 April 2022 / Published online: 13 June 2022
Copyright © 2022 The Author(s). Published by Wolters Kluwer Health, Inc. on behalf of the Association of Bone and Joint Surgeons

Abstract

Background Cam and pincer morphologies are associated with limited internal rotation. However, the routine clinical examination for hip rotation has limited reliability. A more standardized method of measuring hip rotation might increase test-retest and interobserver reliability and might be useful as a screening test to detect different hip morphologies without the need for imaging. We developed an examination chair to standardize the measurement of internal hip rotation, which improved interobserver reliability. However, the diagnostic test accuracy for this test is unknown.

Question/purpose Is a standardized method of determining internal hip rotation using an examination chair useful in detecting cam and pincer morphology with MRI as a reference standard?

Methods A diagnostic test accuracy study was conducted in a sample of asymptomatic males. Using an examination chair with a standardized seated position, internal rotation was measured in 1080 men aged 18 to 21 years who had been conscripted for the Swiss army. The chair prevents compensatory movement by stabilizing the pelvis and the thighs with belts. The force to produce the internal rotation was standardized with a pulley system. Previous results showed that the measurements with the examination chair are similar to clinical assessment but with higher interobserver agreement. A random sample of 430 asymptomatic males was invited to undergo hip MRI. Of those, 244 White European males responded to the invitation and had a mean age of 20 ± 0.7 years and a mean internal rotation of the hip of $33^\circ \pm 8.5^\circ$. Using MRI as the reference standard, 69% (169 of 244) had a normal hip, 24% (59 of 244) a definite cam morphology (Grades 2 and 3), 3% (8 of 244) an increased acetabular depth, and 3% (8 of 244) a combination of both. One experienced radiologist graded cam morphology as follows: 0 = normal, 1 = mild, 2 = moderate, and 3 = severe. Pincer morphology was defined by increased acetabular depth (≤ 3 mm distance between the center of the femoral neck and the line connecting the anterior and posterior acetabular rims). The intraobserver agreement was substantial (weighted κ of 0.65). A receiver operating characteristic (ROC) curve was fitted, and sensitivity, specificity, and likelihood ratios were estimated for different internal rotation cutoffs.

Results For cam morphology, the area under the ROC curve was 0.75 (95% CI 0.67 to 0.82). Internal hip rotation of less than 20° yielded a positive likelihood ratio of 9.57 (sensitivity 0.13, specificity 0.99), and a value of 40° or more resulted in a negative likelihood ratio of 0.36

The institution of one or more of the authors (ML, PJ) has received, during the study period, funding from the Swiss National Science Foundation's National Research Program 53 on musculoskeletal health (grant no. 405340-104778). One author (ME) certifies receipt of support through special project funding (grant No.189498) from the Swiss National Science Foundation. One of the author (ML) certifies having held the patent for the device used to measure internal hip rotation in this study.

All ICMJE Conflict of Interest Forms for authors and *Clinical Orthopaedics and Related Research*® editors and board members are on file with the publication and can be viewed on request. *Clinical Orthopaedics and Related Research*® neither advocates nor endorses the use of any treatment, drug, or device. Readers are encouraged to always seek additional information, including FDA approval status, of any drug or device before clinical use.

Ethical approval for this study was obtained from the Ethics Committee of the Canton of Bern (Nr 05105).

This work was performed at Bern University, Bern, Switzerland.

(sensitivity 0.93, specificity 0.20). The area under the curve for detecting the combination of cam and pincer morphologies was 0.87 (95% CI 0.74 to 1.0). A cutoff of 20° yielded a positive likelihood ratio of 9.03 (sensitivity 0.33, specificity 0.96).

Conclusion This examination chair showed moderate-to-good diagnostic value to rule in hip cam morphology in White European males. However, at the extremes of the 95% confidence intervals, diagnostic performance would be poor. Nonetheless, we believe this test can contribute to identifying cam morphologies, and we hope that future, larger studies—ideally in more diverse patient populations—will seek to validate this to arrive at more precise estimates of the diagnostic performance of this test.

Level of Evidence Level III, diagnostic study.

Introduction

Different hip morphologies are potentially associated with the development of osteoarthritis [2, 4, 9] and total hip replacement [1, 25, 34]. Two common morphological variants that sometimes have been associated with an increased risk of osteoarthritis are cam and pincer; the former is a prominence on the proximal anterior femur, and the latter an acetabular overcoverage [12, 15]. High-intensity physical activity during adolescence increases the cam morphology risk [26]. This morphology leads to impingement during hip flexion and internal rotation (cam impingement), which can damage the acetabular labrum and the articular cartilage and lead the acetabular cartilage to detach from the subchondral bone. Pincer morphology

results in impingement between the femoral neck and the acetabular rim (pincer impingement), potentially causing circumferential cartilage damage. The prevalence of cam and pincer morphologies varies among studies [8, 29]. Cam-related radiographic features were found in 35% of male participants and in 10.2% of female participants in a population-based cohort study of healthy young adults [19]. Cam morphology was a predictor of hip pain in a prospective cohort study of 200 asymptomatic adults [17]. However, both cam and pincer morphologies can exist for years without pain, and therefore their detection might allow clinicians to counsel people, especially athletes, to try to minimize those activities that might increase the likelihood they may develop symptoms so that they can introduce more variability in training. For example, high-velocity movements involving flexion and internal rotation might damage the cartilage, labrum, and subchondral bone [5].

Because both cam and pincer morphologies are associated with limited internal rotation [24, 37], the combination of flexion and internal rotation might be used as a screening test to detect hip morphologies that are associated with femoroacetabular impingement without the need for imaging. We developed an examination chair (Fig. 1) that allows standardized testing of hip internal rotation with high interobserver reliability [30]. The chair is not commercially available, but can easily be built (Appendix 1; <http://links.lww.com/CORR/A801>). Internal hip rotation measurements with the chair were similar compared with clinical examination (difference 1.1° [95% confidence interval (CI) -0.7 to 2.8°]) but with a higher interobserver agreement. This is of particular importance when individuals are measured by different clinicians over time or when less-experienced

¹Institute of Social and Preventive Medicine (ISPM), University of Bern, Bern, Switzerland

²Graduate School for Health Sciences, University of Bern, Bern, Switzerland

³CTU Bern, University of Bern, Bern, Switzerland

⁴Schulthess Clinic, Zürich, Switzerland

⁵Department of Diagnostic, Interventional and Pediatric Radiology (DIPR), Bern University Hospital, University of Bern, Switzerland

⁶Campus Stiftung Lindenhof, Bern, Switzerland

⁷Population Health Sciences, Bristol Medical School, University of Bristol, Bristol, UK

⁸Applied Health Research Centre (AHRC), Li Ka Shing Knowledge Institute of St. Michael's Hospital, and Department of Medicine, University of Toronto, Canada

⁹Department of Rheumatology, Immunology and Allergology, Inselspital, Bern University Hospital, University of Bern, Bern, Switzerland

S. Reichenbach ✉, Institute of Social and Preventive Medicine (ISPM), and Department of Rheumatology, Immunology and Allergology, Inselspital, Bern University Hospital, University of Bern, Bern, Switzerland, Email: stephan.reichenbach@ispm.unibe.ch

clinicians are evaluating hip internal rotation. However, no data are available on the diagnostic accuracy of limited internal hip rotation measured with this examination chair. If the test has high specificity, it might be used in asymptomatic young adults to rule in a cam morphology [27], and information could be provided about managing future symptomatic episodes or avoiding certain activities. We wished to evaluate the sensitivity, specificity, and positive and negative likelihood ratios of a simple test of hip internal rotation in an asymptomatic cohort of young men.

Therefore, we asked: Is a standardized method of determining internal hip rotation using an examination chair useful in detecting cam and pincer morphology with MRI as a reference standard?

Patients and Methods

Study Design and Setting

This diagnostic test accuracy study included 244 asymptomatic participants from the Sumiswald cohort [31, 32], which consisted of consecutively recruited men presenting at a single Swiss Army recruiting center. At the time of the study, 97.5% of the men with Swiss nationality were required by the army to attend the recruitment session at specialized centers, regardless of their health status. Based on a computer-generated random schedule, 430 men were invited to undergo MRI. A total of 186 declined to participate and 244 were examined (Fig. 2). The sampling was stratified by degree of internal hip rotation and was oversampled for the lowest ($< 30^\circ$) and highest ($\geq 40^\circ$) degrees of internal rotation (measured with a dedicated examination chair, see below). There were no differences in age, height, weight, BMI, WOMAC, EuroQol health state index, or EuroQol VAS between those who attended the MRI and those who did not.

Participants

The source population for the Sumiswald cohort includes the rural and urban regions of the canton of Bern, Switzerland. Participants were excluded if they had experienced hip pain during the past 3 months with an intensity of 3 or more on a Likert scale that was graded from 1 (no pain) to 5 (extreme pain); this scale employed a modified version of the question used in the first National Health and Nutrition Examination Survey [3]: “During the past 3 months, have you had pain in or around either of your hips?” Other exclusion criteria were previous surgery in either hip, metabolic or inflammatory rheumatic disease, and a history of hemophilia. Participants had to be older than 18 years and had to provide written informed consent.

Demographics and Description of Study Population

A total of 57% (244 of 430) of the asymptomatic men with a mean age of 20 ± 1 years and a mean BMI of 23 ± 4 kg/m² underwent imaging. Of the 244 imaged hips, 54% (131) were right hips. The 244 men were all White European men. The mean internal rotation of the hip was $33^\circ \pm 8.5^\circ$. Men without signs of cam- or pincer-type morphology had larger internal hip rotation compared with those with cam or pincer morphology (Table 1).

Accounting for All Patients

Of the 1141 eligible men, 95% (1080) consented to be tested for internal rotation (index test). A random sample of 430 participants was selected to undergo MRI; of these, 43% (186) declined to participate (Fig. 2).

Description of Experiment

The examination chair for the reference test (Fig. 1) consists of a seating surface with a chair-like positioning aid and a backrest. The chair allows the fixation of the thighs on the seating surface to resist translational motions while still ensuring that a rotation of the thigh around its longitudinal axis is still possible. Previous results in a subgroup of the cohort showed that the measurements with the examination chair were similar to those obtained clinically (difference 1.1° [95% CI -0.7 to 2.8°]). However, the interobserver agreement for measurement of internal hip rotation was higher for the chair assessments; specifically, the intraclass correlation coefficients (ICCs) for the chair and clinical evaluations were 0.90 and 0.69, respectively. Therefore, we used the examination chair to measure internal hip rotation in the cohort. For the index test (measurement of internal rotation in the examination chair), we measured internal hip rotation in a sitting position with the hips and knees in a 90° flexion position and the lower legs hanging unsupported using a dedicated examination chair [30]. The pelvis was fixed to the chair with a belt. The thighs were fixed in a parallel position using a belt strapped around both legs and above the knees. Using a pulley system, a standardized 5-kg load was applied to both ankles. After giving each study participant 30 seconds to relax and to achieve the maximum ROM, internal rotation was measured (Fig. 1) [30]. Measurements of internal hip rotation on this chair were shown to have excellent interobserver reliability (ICC right hip 0.92 [95% CI 0.89 to 0.95]; ICC left hip 0.90 [95% CI 0.86 to 0.94]) [30]. The observer who assessed the internal rotation was unaware of the MRI results because the MRI was performed afterward.

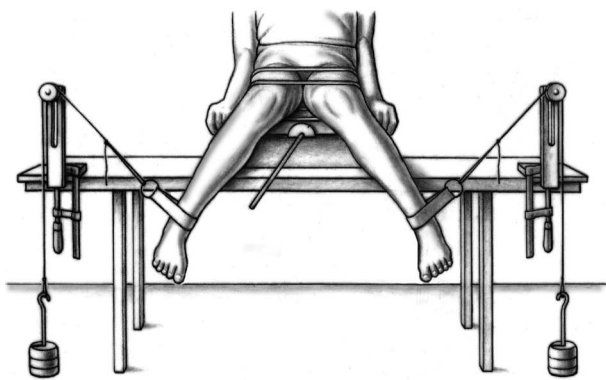


Fig. 1. Examination chair to measure internal hip rotation.

Variables, Outcome Measures, Data Sources, and Bias

Reference Test: MRI

A random sample of 244 participants underwent an MRI scan. The median time between the measurement of internal rotation and MRI was 6.5 months (interquartile range

[IQR] 4.2 to 14.1). We selected the hip with less internal rotation for examination by MRI. If both hips had similar internal rotation, specifically within 1°, we selected the hip using a concealed central computer-generated randomization list. We used a 1.5-T high-field system (Magnetom Avanto, Siemens Healthcare) with a flexible surface coil and a high spatial resolution protocol. Patients lay supine with the hip in a neutral position [32]. We acquired radial proton density-weighted sequences, and all slices were oriented parallel to the femoral neck axis, which was used as the axis of rotation. Neither intraarticular nor intravenous contrast was injected [32].

Description of Hip Morphologies

All ratings were performed by one experienced radiologist (not a study author) who was blinded to the results of the index test. Of the 244 men, 69% (169) had a normal hip, 24% (59) showed definite cam morphology (Grades 2 and 3), 3% (8) pincer morphology, and 3% (8) had a combination of both a cam and pincer morphology. The




Fig. 2. Flow chart of the inclusion and exclusion of participants.

Table 1. Characteristics among groups with different hip morphologies^a

	No signs of Cam or pincer morphology (n = 169)	Cam only (n = 59)	Pincer only (n = 8)	Both morphological variants (n = 8)	p value
Age in years	20 ± 1	20 ± 1	20 ± 1	20 ± 1	0.54
Height in cm	178 ± 7	179 ± 8	82 ± 6	180 ± 7	0.40
Weight in kg	72 ± 12	77 ± 14	75 ± 14	82 ± 13	0.009
BMI in kg/cm ²	23 ± 3	24 ± 4	23 ± 4	26 ± 4	0.02
Internal rotation, continuous	35 ± 8	29 ± 9	37 ± 7	22 ± 7	< 0.001
Internal rotation, categorized					< 0.001
< 30°	25 (42)	56 (33)	13 (1)	88 (7)	
≥ 30° and < 40°	36 (60)	27 (16)	50 (4)	13 (1)	
≥ 40°	40 (67)	17 (10)	38 (3)	0 (0)	
Health state index	9.3 ± 1.4	9.3 ± 1.2	9.1 (1.2)	9.7 ± 0.8	0.81
EuroQol VAS	85 ± 12	84 ± 12	85 ± 10	13 ± 77	0.24

Data presented as mean ± SD or % (n); p values were calculated using an F-test or chi-square test.

^aAll participants in this study were males.

intraobserver agreement for the cam-type morphology showed a weighted κ value of 0.65. The interobserver agreement was moderate for cam-type morphology (weighted κ 0.52) and good for the pincer morphology (ICC 0.82) [31, 21].

Cam Morphology

Cam morphology was assumed if the maximal offset at the head-neck junction on radial sequences was Grade 2 or 3 based on a semiquantitative scoring system (0 = normal, no evidence of a nonspherical femoral shape on any sequence; 1 = possible cam morphology with cortical irregularity and a possible mild decrease in the anterior head-neck offset; 2 = definite cam morphology with an established decrease in the anterior head-neck offset; and 3 = severe cam morphology with a large decrease in the anterior head-neck offset) [31]. These criteria were defined a priori in the protocol.

Pincer Morphology

Pincer morphology was defined by increased acetabular depth, specified as the distance (in mm) between the center of the femoral neck and the line connecting the anterior and posterior acetabular rims. The value was positive if the center of the femoral neck was lateral to the line connecting the acetabular rim. Values of 3 mm or less were considered to represent increased acetabular depth. In sensitivity analyses, we used 2 mm or less and 4 mm or less as alternative cutoffs.

Measuring Symptoms

To quantify hip-related symptoms within the previous 48 hours, we used version 3.1 of the WOMAC [6]. We assessed health-related quality of life with the EuroQol 5-domain questionnaire [14].

Ethical Approval

The study was approved by the Ethics Committee of the Canton of Bern.

Statistical Analysis, Study Size

We analyzed the diagnostic value of internal rotation for the presence of cam morphology, with or without pincer morphology, as well as for the combination of both [31].

We compared baseline characteristics of the participants based on the presence or absence of cam morphology, pincer morphology, or a combination of both using one-way ANOVA for continuous data and chi-square tests for categorical data. We standardized the WOMAC scores to range from 0 to 10, with higher values indicating more severe symptoms. The health status index from the EuroQol, based on the European value set, was standardized to range from 0 to 10 [11], with higher values indicating better health-related quality of life. All p values were two-sided.

We first estimated the association of the different morphological variants with internal rotation using a

multivariable regression model that included cam morphology only, pincer morphology only, or a combination of both. We separately analyzed the diagnostic value of internal rotation for the presence of cam morphology, with or without pincer morphology, as well as for the combination of both morphologies. To determine the test accuracy of the internal rotation measurement, we first constructed 2 x 2 contingency tables using cutoffs in 5° increments from 10° to 50° internal rotation. Second, we used logistic regression to fit a receiver operating characteristic (ROC) curve. Based on the observed sensitivities and specificities, we calculated likelihood ratios for negative and positive test results for each cutoff.

We derived predicted probabilities for cam morphology from a logistic model with cam morphology as the outcome and internal rotation as the predictor. The ROC curve analysis, accuracy measures, and regression models were weighted according to the oversampling in the strata with high and low internal rotation. The area under the ROC curve can be calculated and serves as an indicator of diagnostic performance (discrimination). A value of 0.5 indicates a useless test and a value of 1 indicates a perfect test. Given the low cost and ease of use of the presented examination chair, a value for the area under the ROC curve of 0.7 can be considered as clinically useful.

Because the prevalence of a cam morphology influences the posttest probabilities for a cam morphology, the application of the test leads to different results (that is, posttest probabilities) in different populations. Therefore, based on the available evidence, we approximated pretest probabilities (that is, prevalence) for cam-type morphologies in different populations, specifically asymptomatic females [10], asymptomatic males [10], symptomatic individuals [22], and athletes from sports such as hockey [22], with two cutoffs: one with a high likelihood ratio for a positive test and one with a low likelihood ratio for a negative test. All analyses were performed using Stata version 14 (StataCorp).

Results

Cam Morphology

The area under the ROC curve for the diagnosis of definite cam morphology (Grades 2 and 3, with or without pincer morphology versus hips without cam morphology) was 0.75 (95% CI 0.67 to 0.82) (Fig. 3). A cutoff of 40° yielded a sensitivity of 0.93 and a specificity of 0.20 and showed a likelihood ratio for a negative test of 0.36. A cutoff of 20° yielded a sensitivity of 0.13 and a specificity of 0.99 and had high power to rule in a cam morphology, with a likelihood ratio for a positive test of 9.57 (Table 2).

Combined Pincer and Cam Morphology

The area under the curve for detecting the combination of cam and pincer morphologies was 0.87 (95% CI 0.74 to 1.0). The low number of combined morphologies precluded the selection of the best cutoff for ruling out the morphologies (low statistical precision). A cutoff of 20° yielded a positive likelihood ratio of 9.03 (sensitivity 0.33, specificity 0.96), which might suggest its ability to rule in the morphology; the cutoff to rule out a combined morphology is unclear (Table 3).

Posttest Probabilities

The predicted probabilities of a cam (with or without pincer) morphology ranged from 7% for a maximal internal rotation angle of 45° to 73% for an angle of 15° (Table 4). Based on this study and others, we provide estimated pretest probabilities (prevalences) for asymptomatic females, asymptomatic males, a symptomatic population, and athletes. A positive test, defined as internal rotation less than 20°, resulted in a posttest probability of 95% in athletes (pretest probability or prevalence estimated 66%) and of 91% in symptomatic individuals (pretest probability or prevalence estimated as 50%). Positive tests in asymptomatic men or symptomatic individuals, as well as negative tests in general, resulted in intermediate posttest probabilities that require additional testing (Fig. 4).

Males with cam morphologies had lower internal rotation than those with normal hips and those with pincer morphologies only (Table 5). The adjusted, weighted linear

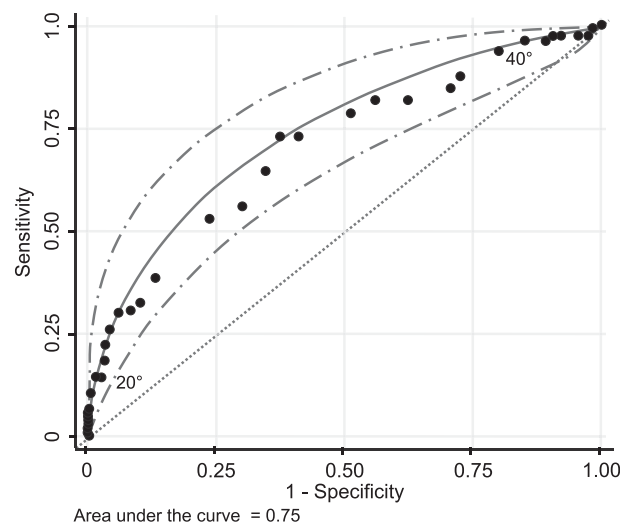


Fig. 3. Fitted ROC curve (solid line) with 95% CIs (broken lines). The dotted diagonal line represents a nondiscriminatory test.

Table 2. Accuracy of internal rotation for cam morphology with or without pincer morphology

Internal rotation, degrees	Test positive, % of men	Sensitivity, fitted	Specificity, fitted	PPV, fitted	NPV, fitted	Positive LR, fitted	Negative LR, fitted
45°	96%	0.99	0.04	0.25	0.91	1.03	0.32
40°	83%	0.93	0.20	0.27	0.90	1.16	0.36
35°	58%	0.77	0.50	0.33	0.87	1.55	0.46
30°	30%	0.54	0.78	0.44	0.84	2.44	0.59
25°	11%	0.28	0.94	0.61	0.80	4.91	0.77
20°	5%	0.13	0.99	0.75	0.78	9.57	0.88
15°	1%	0.05	1.00	0.88	0.77	22.11	0.95

Analysis based on 244 men, including 59 men with cam morphologies and eight men with both cam and pincer morphologies; PPV = positive predictive value; NPV = negative predictive value; LR = likelihood ratio; all measures are weighted for oversampling.

regression models showed that cam morphology only or in combination with pincer morphology was associated with reduced maximal internal rotation compared with males without any morphological variant (coefficients adjusted for age and BMI: -4.1° [95% CI -6.1° to -2.1°] for cam only; -10.1° [95% CI -14.0° to -6.2°] for cam and pincer combined). In contrast, rotation in the eight men with pincer morphology was similar to that in males without this morphology (difference 0.8° [95% CI -2.7° to 4.4°]).

Discussion

Diagnosing hip morphologies associated with femoroacetabular impingement is challenging without using advanced imaging such as MRI, but advanced imaging is impractical as a screening tool. Measuring internal rotation may be useful as a screening tool, but measuring it goniometrically or visually on a standard examination table is unreliable. We believe that the standardization of the measurement of internal hip rotation increases interrater reliability. With that in mind, one of the authors (ML) developed an examination chair that allows standardized testing of internal hip rotation with high reliability [30]. However, no

data were available on the diagnostic accuracy of this test for detecting cam or pincer morphologies in asymptomatic persons. The current diagnostic test accuracy study evaluated the ability of a simple standardized test of internal hip rotation to detect cam and pincer morphologies in 244 asymptomatic young men. There were three main findings: first, the internal rotation test was more than three times more powerful for ruling in than for ruling out a cam morphology; second, the proposed cutoff for ruling in a cam morphology was internal hip rotation less than 20°; third, the optimal cutoff for ruling out a cam morphology was internal hip rotation of at least 40°. Because few participants had pincer morphologies, no firm conclusions could be made regarding cutoffs for detecting this type of morphology. The use of this chair might be useful in situations in which different clinicians evaluate internal rotation (as the interobserver reliability is high), and those in which the aim of the examination is to rule in cam-type morphologies (high specificity).

Limitations

Our study has several limitations. Since only eight participants had a pincer morphology and eight had a combination

Table 3. Accuracy of internal rotation for detecting both cam- and pincer-type deformity

Internal rotation, degrees	Test positive, % of men	Sensitivity, fitted	Specificity, fitted	PPV, fitted	NPV, fitted	Positive LR, fitted	Negative LR, fitted
45°	96%	1.00	0.04	0.02	1.00	1.04	0.00
40°	83%	1.00	0.17	0.03	1.00	1.21	0.01
35°	58%	0.97	0.44	0.04	1.00	1.75	0.06
30°	30%	0.85	0.73	0.07	1.00	3.09	0.21
25°	11%	0.59	0.90	0.12	0.99	5.62	0.46
20°	5%	0.33	0.96	0.18	0.98	9.03	0.70
15°	1%	0.10	0.99	0.27	0.98	15.18	0.91

Analysis based on 244 men, including eight men with both cam- and pincer-type deformities; all measures are weighted for oversampling; PPV = positive predictive value; NPV = negative predictive value; LR = likelihood ratio.

Table 4. Weighted predicted probability of cam-type deformity stratified by degree of internal rotation

Internal rotation, degrees	Probability (95% CI)
45°	0.07 (0.02-0.11)
40°	0.12 (0.06-0.17)
35°	0.19 (0.13-0.26)
30°	0.31 (0.23-0.38)
25°	0.45 (0.35-0.55)
20°	0.60 (0.47-0.73)
15°	0.73 (0.59-0.87)

Probabilities predicted from a logistic model with cam-type deformity as the outcome and internal rotation as the predictor, weighted for oversampling; analysis based on 244 men, including 59 men with cam-type deformities and eight men with cam- and pincer-type deformities.

of cam- and pincer-type morphologies, we could not draw strong conclusions about the detection of these morphologies. The proportion of patients who declined to undergo MRI might have introduced selection bias, thus limiting the generalizability of our results. However, when we compared participants to nonparticipants, we found no differences

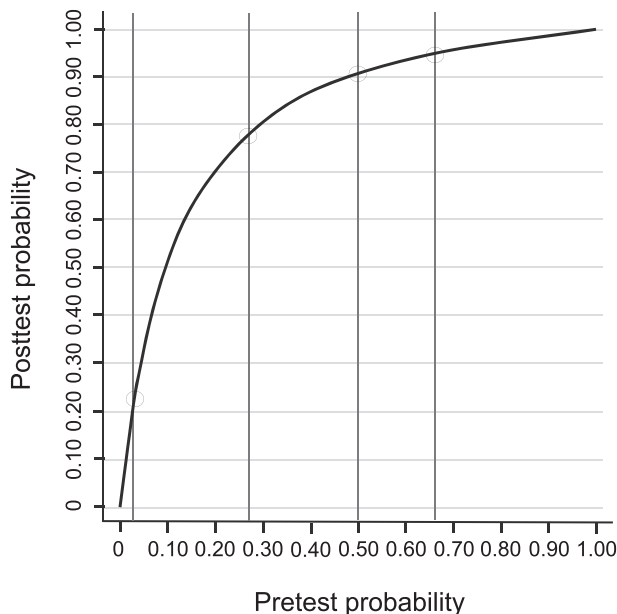


Fig. 4. Relationship between pretest and posttest probabilities for a positive test at a cutoff of 20° or less of internal rotation for the detection of a cam morphology. Based on this study and others, we provide estimated pretest probabilities (prevalence): asymptomatic females (3%), asymptomatic males (27%), a symptomatic population (50%), and athletes (66%). A positive test, defined as internal rotation of 20° or less, resulted in a posttest probability (positive predictive value) of 23% in asymptomatic females, 78% in asymptomatic males, 91% in symptomatic individuals, and 95% in athletes.

regarding age, height, weight, WOMAC, or self-reported health state (EuroQol) [6, 14, 31]. Since we only included men, it is unclear if our results apply to women. The ROM of internal hip rotation differs between females and males [21], so although our approach might still have diagnostic validity, the cutoffs may differ. Furthermore, the prevalence of pincer-type morphology might be different in females compared with males, although there is conflicting evidence whether females have a higher or a lower prevalence of pincer morphology [1, 23]. Because the prevalences of cam- and pincer-type morphologies increase with age, and because hip mobility decreases with age, the extrapolation of our results—which were generated in a group of 20-year-old men—to older people should be done only with caution. The same caution should be applied when using the test in other populations such as those with a higher proportion of obese persons or those who may have other reasons for having limited internal hip rotation. We included only asymptomatic individuals, and it is unclear whether the positive likelihood ratio would remain the same in symptomatic people. Symptomatic individuals may also have decreased internal hip rotation without femoroacetabular impingement [33]. In a systematic review, we earlier identified only one study that evaluated flexion combined with internal rotation in symptomatic people [7]. In another study, the authors found a low sensitivity of 0.22 for the detection of femoroacetabular impingement and pain, with a specificity of 0.91 [28].

Another limitation of our study is that the test cannot differentiate between restricted internal rotation caused by femoral retroversion (retrotorsion), acetabular retroversion, or cam morphology. Femoral retroversion may have a larger effect on internal rotation than cam morphology [18]. Furthermore, the test might produce a false negative in patients with concomitant hip dysplasia and cam morphology, where large femoral antetorsion and insufficient femoral coverage allow for high internal rotation despite the cam morphology. In addition, cutoffs based on our data may

Table 5. Internal rotation results by type of morphology

Morphology type	Participants with MRI (n = 244)	Internal rotation in °, weighted
No signs of cam or pincer morphology	69% (169)	35 ± 6
Cam only (Grade 2 or 3)	24% (59)	30 ± 8
Cam only (Grade 2)	19% (47)	32 ± 7
Cam only (Grade 3)	5% (12)	25 ± 8
Pincer only	3% (8)	36 ± 5
Both morphological variants	3% (8)	24 ± 6

Data presented as % (n) or mean ± SD; the values are weighted to adjust for oversampling.

overestimate the test performance, and the specificity and sensitivity might be lower in an independent sample [20]. Finally, one limitation is that the chair is not commercially available, although it is easy to build (Appendix 1).

Discussion of Key Findings

We are unaware of other studies that evaluated the same standardized tool to measure internal hip rotation. Only a few studies have evaluated sensitivity and specificity for the measurement of internal rotation to detect cam morphologies. In a study with a cohort of 200 asymptomatic participants without prior hip surgery or childhood hip problems, the sensitivity to detect a cam morphology was 0.36 and the specificity was 0.83 for a cutoff of at most 20° internal rotation (cam morphology was defined as an alpha angle of more than 50.5°), for a positive likelihood ratio of only 2.10 [13]. Among 65 male American football players, in one subset (rater 1) the sensitivity to detect a cam morphology (alpha angle > 50°) was 0.88 and the specificity was 0.47, for a threshold of 41° internal rotation of the hip, and in a second subset (rater 2) sensitivity was 0.81 and specificity was 0.51, for a threshold of 38° [16]. These values yielded negative likelihood ratios of 0.26 and 0.37, respectively, similar to those in our study.

We believe our results have a number of practical implications. As a rule of thumb, a positive test should have a likelihood ratio over 10 to be considered accurate; however, the utility depends on the pretest probability of the disease [27]. With the likelihood ratio of 9.57 for a positive test for cam morphology (with or without pincer morphology), a sufficiently high posttest probability is achieved in populations with a relatively high prevalence of cam morphology (high pretest probability), for example, in symptomatic men or athletes in sports such as hockey. In the case of a positive test result, general practitioners could discuss the influence of physical activity on symptoms [35] because decreased internal rotation and a cam morphology were risk factors for degenerative changes in adolescent athletes who were followed for 5 years [36]. Although people with a cam morphology are at increased risk of developing osteoarthritis, it is unclear whether young asymptomatic males with a positive test should be referred for radiological assessment and whether an intervention (such as, exercise therapy, reduction of risky activities, or preventive surgery) would reduce the osteoarthritis risk.

Given the low cost of the test, in terms of both materials and personal resources, further studies should be performed to establish its diagnostic accuracy in males and females with hip symptoms as well as in men and women athletes. If these studies are promising, then larger, longitudinal studies would be warranted to evaluate the prognostic value of limited internal rotation for hip problems such as symptoms

or osteoarthritis. Future research should also seek to establish a consensus on the most appropriate approach to young asymptomatic adults with a limited internal ROM.

Conclusion

The standardized measurement of internal hip rotation with an examination chair can be used to rule in cam-type morphologies. However, at the extremes of the 95% confidence intervals, the performance would be poor. We believe use of this chair might be useful in situations in which different clinicians evaluate internal rotation such as screening settings (as the interobserver reliability is high), and those in which the aim of the examination is to rule in cam-type morphologies (high specificity). However, measurement of internal hip rotation is less effective for ruling out cam-type morphologies. To increase statistical precision, future studies should evaluate the diagnostic accuracy of internal hip rotation for detecting pincer-type morphologies in larger cohorts.

This is an open-access article distributed under the terms of the [Creative Commons Attribution-Non Commercial-No Derivatives License 4.0 \(CCBY-NC-ND\)](https://creativecommons.org/licenses/by-nc-nd/4.0/), where it is permissible to download and share the work provided it is properly cited. The work cannot be changed in any way or used commercially without permission from the journal.

Acknowledgments We thank Kathrin Beer for her help in measuring internal rotation, Madeleine Dähler for coordination, Malcom Sturdy for database development, and Nicola Maffioletti for helpful comments.

References

1. Agricola R, Reijman M, Bierma-Zeinstra SM, Verhaar JA, Weinans H, Waarsing JH. Total hip replacement but not clinical osteoarthritis can be predicted by the shape of the hip: a prospective cohort study (CHECK). *Osteoarthritis Cartilage*. 2013;21:559-564.
2. Ahedi HG, Aspden RM, Blizzard LC, et al. Hip shape as a predictor of osteoarthritis progression in a prospective population cohort. *Arthritis Care Res (Hoboken)*. 2017;69:1566-1573.
3. Anderson JJ, Felson DT. Factors associated with osteoarthritis of the knee in the first national Health and Nutrition Examination Survey (HANES I). Evidence for an association with overweight, race, and physical demands of work. *Am J Epidemiol*. 1988;128:179-189.
4. Baker-LePain JC, Lane NE. Relationship between joint shape and the development of osteoarthritis. *Curr Opin Rheumatol*. 2010;22:538-543.
5. Beck M, Kalthor M, Leunig M, Ganz R. Hip morphology influences the pattern of damage to the acetabular cartilage: femoroacetabular impingement as a cause of early osteoarthritis of the hip. *J Bone Joint Surg Br*. 2005;87:1012-1018.
6. Bellamy N, Buchanan WW, Goldsmith CH, Campbell J, Stitt LW. Validation study of WOMAC: a health status instrument for measuring clinically important patient relevant outcomes to antirheumatic drug therapy in patients with osteoarthritis of the hip or knee. *J Rheumatol*. 1988;15:1833-1840.

7. Caliesch R, Sattelmayer M, Reichenbach S, Zwahlen M, Hilfiker R. Diagnostic accuracy of clinical tests for cam or pincer morphology in individuals with suspected FAI syndrome: a systematic review. *BMJ Open Sport Exerc Med.* 2020;6:e000772.
8. Dickenson E, Wall PD, Robinson B, et al. Prevalence of cam hip shape morphology: a systematic review. *Osteoarthritis Cartilage.* 2016;24:949-961.
9. Ganz R, Parvizi J, Beck M, Leunig M, Notzli H, Siebenrock KA. Femoroacetabular impingement: a cause for osteoarthritis of the hip. *Clin Orthop Relat Res.* 2003;417:112-120.
10. Gosvig KK, Jacobsen S, Sonne-Holm S, Gebuhr P. The prevalence of cam-type deformity of the hip joint: a survey of 4151 subjects of the Copenhagen Osteoarthritis Study. *Acta Radiol.* 2008;49:436-441.
11. Greiner W, Weijnen T, Nieuwenhuizen M, et al. A single European currency for EQ-5D health states. Results from a six-country study. *Eur J Health Econ.* 2003;4:222-231.
12. Griffin DR, Dickenson EJ, O'Donnell J, et al. The Warwick Agreement on femoroacetabular impingement syndrome (FAI syndrome): an international consensus statement. *Br J Sports Med.* 2016;50:1169-1176.
13. Hack K, Di Primio G, Rakhra K, Beaulé PE. Prevalence of cam-type femoroacetabular impingement morphology in asymptomatic volunteers. *J Bone Joint Surg Am.* 2010;92:2436-2444.
14. Hurst NP, Kind P, Ruta D, Hunter M, Stubbings A. Measuring health-related quality of life in rheumatoid arthritis: validity, responsiveness and reliability of EuroQol (EQ-5D). *Br J Rheumatol.* 1997;36:551-559.
15. Ito K, Minka MA 2nd, Leunig M, Werlen S, Ganz R. Femoroacetabular impingement and the cam-effect. A MRI-based quantitative anatomical study of the femoral head-neck offset. *J Bone Joint Surg Br.* 2001;83:171-176.
16. Kapron AL, Anderson AE, Peters CL, et al. Hip internal rotation is correlated to radiographic findings of cam femoroacetabular impingement in collegiate football players. *Arthroscopy.* 2012;28:1661-1670.
17. Khanna V, Caragianis A, Diprimio G, Rakhra K, Beaulé PE. Incidence of hip pain in a prospective cohort of asymptomatic volunteers: is the cam deformity a risk factor for hip pain? *Am J Sports Med.* 2014;42:793-797.
18. Kraeutler MJ, Chadayammuri V, Garabekyan T, Mei-Dan O. Femoral version abnormalities significantly outweigh effect of cam impingement on hip internal rotation. *J Bone Joint Surg Am.* 2018;100:205-210.
19. Laborie LB, Lehmann TG, Engesaeter IO, Eastwood DM, Engesaeter LB, Rosendahl K. Prevalence of radiographic findings thought to be associated with femoroacetabular impingement in a population-based cohort of 2081 healthy young adults. *Radiology.* 2011;260:494-502.
20. Leeflang MM, Moons KG, Reitsma JB, Zwinderman AH. Bias in sensitivity and specificity caused by data-driven selection of optimal cutoff values: mechanisms, magnitude, and solutions. *Clin Chem.* 2008;54:729-737.
21. Leunig M, Juni P, Werlen S, et al. Prevalence of cam and pincer-type deformities on hip MRI in an asymptomatic young Swiss female population: a cross-sectional study. *Osteoarthritis Cartilage.* 2013;21:544-550.
22. Mascarenhas VV, Rego P, Dantas P, et al. Imaging prevalence of femoroacetabular impingement in symptomatic patients, athletes, and asymptomatic individuals: a systematic review. *Eur J Radiol.* 2016;85:73-95.
23. Morales-Avalos R, Tapia-Náñez A, Simental-Mendía M, et al. Prevalence of morphological variations associated with femoroacetabular impingement according to age and sex: a study of 1878 asymptomatic hips in nonprofessional athletes. *Orthop J Sports Med.* 2021;9:10.1177/2325967120977892.
24. Ng KCG, Lamontagne M, Beaulé PE. Differences in anatomical parameters between the affected and unaffected hip in patients with bilateral cam-type deformities. *Clin Biomech (Bristol, Avon).* 2016;33:13-19.
25. Nicholls AS, Kiran A, Pollard TC, et al. The association between hip morphology parameters and nineteen-year risk of end-stage osteoarthritis of the hip: a nested case-control study. *Arthritis Rheum.* 2011;63:3392-3400.
26. Palmer A, Fernquest S, Gimpel M, et al. Physical activity during adolescence and the development of cam morphology: a cross-sectional cohort study of 210 individuals. *Br J Sports Med.* 2018;52:601-610.
27. Pewsner D, Battaglia M, Minder C, Marx A, Bucher HC, Egger M. Ruling a diagnosis in or out with SpPin and SnNOut: a note of caution. *BMJ.* 2004;329:209-213.
28. Ratzlaff C, Li L, Wong H, et al. The prevalence and diagnostic accuracy of clinical exam tests in identifying radiographic femoroacetabular impingement (FAI): a prospective population-based study. *Osteoarthritis Cartilage.* 2015;23:A170-A171.
29. Raveendran R, Stiller JL, Alvarez C, et al. Population-based prevalence of multiple radiographically-defined hip morphologies: the Johnston County Osteoarthritis Project. *Osteoarthritis Cartilage.* 2018;26:54-61.
30. Reichenbach S, Juni P, Nuesch E, Frey F, Ganz R, Leunig M. An examination chair to measure internal rotation of the hip in routine settings: a validation study. *Osteoarthritis Cartilage.* 2010;18:365-371.
31. Reichenbach S, Juni P, Werlen S, et al. Prevalence of cam-type deformity on hip magnetic resonance imaging in young males: a cross-sectional study. *Arthritis Care Res (Hoboken).* 2010;62:1319-1327.
32. Reichenbach S, Leunig M, Werlen S, et al. Association between cam-type deformities and magnetic resonance imaging-detected structural hip damage: a cross-sectional study in young men. *Arthritis Rheum.* 2011;63:4023-4030.
33. Retchford TH, Tucker KJ, Weinrauch P, et al. Clinical features of people with hip-related pain, but no clinical signs of femoroacetabular impingement syndrome. *Phys Ther Sport.* 2018;34:201-207.
34. Thomas G, Palmer A, Batra R, et al. Subclinical deformities of the hip are significant predictors of radiographic osteoarthritis and joint replacement in women. A 20 year longitudinal cohort study. *Osteoarthritis Cartilage.* 2014;22:1504-1510.
35. Westermann RW, Lynch TS, Jones MH, et al. Predictors of hip pain and function in femoroacetabular impingement: a prospective cohort analysis. *Orthop J Sports Med.* 2017;5:10.1177/2325967117726521.
36. Wyles CC, Norambuena GA, Howe BM, et al. Cam deformities and limited hip range of motion are associated with early osteoarthritic changes in adolescent athletes: a prospective matched cohort study. *Am J Sports Med.* 2017;45:3036-3043.
37. Wyss TF, Clark JM, Weishaupt D, Notzli HP. Correlation between internal rotation and bony anatomy in the hip. *Clin Orthop Relat Res.* 2007;460:152-158.