

Provided for non-commercial research and education use.  
Not for reproduction, distribution or commercial use.



This article appeared in a journal published by Elsevier. The attached copy is furnished to the author for internal non-commercial research and education use, including for instruction at the author's institution and sharing with colleagues.

Other uses, including reproduction and distribution, or selling or licensing copies, or posting to personal, institutional or third party websites are prohibited.

In most cases authors are permitted to post their version of the article (e.g. in Word or Tex form) to their personal website or institutional repository. Authors requiring further information regarding Elsevier's archiving and manuscript policies are encouraged to visit:

<http://www.elsevier.com/authorsrights>



# The Gore Hybrid Vascular Graft in renovisceral debranching for complex aortic aneurysm repair

Francesco Setacci, MD,<sup>a,b</sup> Felice Pecoraro, MD,<sup>a,c</sup> Lyubov Chaykovska, MD,<sup>a</sup> Nicola Mangialardi, MD,<sup>d</sup> Masami Shingaki, MD,<sup>e</sup> Frank J. Veith, MD,<sup>a,f,g</sup> Zoran Rancic, PhD, MD,<sup>a</sup> and Mario Lachat, MD,<sup>a</sup> *Zurich, Switzerland; Rome and Palermo, Italy; Uji, Japan; Cleveland, Ohio; and New York, NY*

**Objective:** This study reports our initial experience with the Gore Hybrid Vascular Graft (GHVG; W. L. Gore & Associates, Flagstaff, Ariz) for staged hybrid open renovisceral debranching and endovascular aneurysm repair in patients affected by thoracoabdominal aortic aneurysms and pararenal abdominal aortic aneurysms (PAAAs).

**Methods:** Between December 2012 and December 2013, we analyzed outcomes of 13 patients who underwent open surgical debranching of renovisceral vessels for thoracoabdominal aortic aneurysm and PAAAs. All patients were considered at high risk for conventional surgery. Inclusion criterion was treatment by open surgical debranching of at least one visceral artery (renal artery, superior mesenteric artery [SMA], or celiac trunk [CT]) using the GHVG. In a second step, the aortic stent graft was implanted to exclude the aneurysm. If required, parallel grafts to the remaining visceral arteries were deployed in the same procedure. One patient had a symptomatic descending thoracic aortic aneurysm and another had a ruptured PAAA. Perioperative measured outcomes were immediate technical success rate, mortality, and morbidity. Median follow-up was 24.8 months (range, 0-15; mean, 8.2; standard deviation, 4 months).

**Results:** All open surgical debranching of renovisceral vessels were completed as intended. GHVG was used to revascularize 20 visceral vessels in 13 patients with a mean of 1.54 vessels per patient. Six renal arteries (30%; 2 right and 4 left), 9 SMAs (45%), and 5 CTs (25%) were debranched. In nine of 13 (66%) patients, other renovisceral arteries were addressed with chimney/periscope, Viabahn Open Revascularization Technique, and end-to-side anastomosis. Two of 13 patients (15%) died of bowel ischemia. Neither patient had GHVG revascularization to the SMA or CT. Perioperative complications occurred in three patients (23%; 1 renal hematoma, 1 respiratory insufficiency, and 1 small-bowel ischemia related to a SMA GHVG thrombosis). At 24 months, estimated survival was 85%, and estimated primary and secondary patency were 94% and 100%, respectively.

**Conclusions:** This limited series extracted from a more consistent hybrid procedure experience showed a mortality rate similar to most recent reports. Technical feasibility and the short-term patency rate of the GHVG for renovisceral debranching during staged hybrid open and endovascular procedures were satisfactory. Use of GHVGs may represent a useful revascularization adjunct to minimize visceral ischemia in these challenging patients. (*J Vasc Surg* 2016;64:33-8.)

The total endovascular repair of thoracoabdominal aortic aneurysm (TAAAs) and pararenal AAA (PAAAs) represents a hugely appealing less invasive approach. Major restrictions limiting its use are the anatomic requirements, the need for customized devices resulting in treatment delay, and the complex device sizing and procedural planning.<sup>1-3</sup> Therefore, there are subsets of patients that are considered unfit for traditional open aortic repair due to aortic cross-clamping and hemodynamic stress. In these

patients, the hybrid approach, combining the surgical renovisceral debranching and the endovascular aneurysm exclusion, can bridge the gap between these two options, being readily available and reproducible.<sup>4,5</sup>

Despite the initial enthusiasm for the hybrid repair (HR),<sup>6,7</sup> several series reported a 30-day mortality rates of 13% to 23%, which are similar to the outcomes after traditional open surgical repair.<sup>8,9</sup> Most of the HR mortality was related to renovisceral dysfunctions. Although several factors are supposed to be involved in such dysfunction, the most important is definitely the ischemia time during the arterial anastomosis.<sup>10</sup>

To reduce the renovisceral ischemia during multiple bypasses, a novel tool with sutureless endovascular anastomosis<sup>11</sup> was developed to allow a decreasing ischemic time during sequential bypass. Subsequently, with the same rationale grew up the Gore Hybrid Vascular Graft (GHVG; W. L. Gore and Associates, Flagstaff, Ariz), which is a novel expanded polytetrafluoroethylene (ePTFE) vascular prosthesis that includes a nitinol reinforced self-expanding section at one extremity that allows a “sutureless” endovascular anastomosis. The present study reports our initial experience with the GHVG used during renovisceral debranching in patients affected by TAAAs and PAAAs.

From the Clinic for Cardiovascular Surgery, University Hospital, Zurich<sup>a</sup>; Department of Surgery “P. Valdoni,” Università degli Studi di Roma La Sapienza, Rome<sup>b</sup>; Vascular Surgery Unit, University of Palermo, AOUP “P. Giaccone,” Palermo<sup>c</sup>; Department of Vascular Surgery, San Filippo Neri Hospital, Rome<sup>d</sup>; Department of Cardiovascular Surgery, Uji Tokushukai Hospital, Uji<sup>e</sup>; and the Cleveland Clinic, Cleveland<sup>f</sup>; and the New York University Medical Center, New York.<sup>g</sup>

Author conflict of interest: none.

Correspondence: Felice Pecoraro, MD, Via L. Giuffrè 5, 90100 Palermo, Italy (e-mail: felice.pecoraro@unipa.it).

The editors and reviewers of this article have no relevant financial relationships to disclose per the JVS policy that requires reviewers to decline review of any manuscript for which they may have a conflict of interest.

0741-5214

Copyright © 2016 by the Society for Vascular Surgery. Published by Elsevier Inc.

<http://dx.doi.org/10.1016/j.jvs.2015.12.059>

## METHODS

Data from patients affected by TAAAs and PAAAs, treated with staged hybrid open and endovascular renovisceral debranching and endovascular aneurysm repair (EVAR), were prospectively collected from January 2013 to March 2014, into the clinical information system (Dendrite and KISIM 4.901; Dendrite Clinical Systems, Ltd, Henley-on-Thames, United Kingdom) of our institution. Informed consent for the procedure itself and for the anonymous data collection and analysis was obtained from all patients. The Institutional Review Board approved the retrospective study.

All included patients were considered at high risk for conventional surgery. Inclusion criterion was the treatment by open surgical debranching of at least one visceral artery (renal artery [RA], superior mesenteric artery [SMA], or celiac trunk [CT]) using the GHVC. Patients who required debranching of the internal iliac arteries and supra-aortic vessels were excluded, as were patients with obstructive aortic pathologies. Aneurysmatic aortic pathology was defined according reporting standards.<sup>12,13</sup>

The perioperative outcomes were immediate technical success rate, morbidity, and mortality. Immediate technical success was defined as the procedure being completed as intended. Intensive care unit length of stay (LOS), intubation duration, in-hospital LOS were also analyzed. Survival, primary patency, and secondary patency were estimated.

Adjunctive procedures related to visceral debranching during follow-up were recorded with their related outcomes (immediate technical success rate, perioperative mortality, and morbidity). Follow-up was calculated from the visceral debranching intervention. The follow-up protocol consisted of computed tomography angiography, laboratory testing, and clinical examination at 6 weeks, 3 and 6 months later, and yearly thereafter. Patients presenting with renal function impairment were monitored by native computed tomography and duplex ultrasound imaging of the aorta and target vessels.

Data analysis was performed using SPSS 16.0 software (IBM Corp, Armonk, NY). Mean and standard deviations (SDs) are reported for parametric data and absolute values and range for nonparametric data. Statistical significance was assigned at a two-sided *P* of <.05. Kaplan-Meier curves were used to estimate survival and patency. Median follow-up was 24.8 months (range, 0-15; mean, 8.2; SD, 4 months).

## RESULTS

A total of 13 patients meet the inclusion criteria and were included in the study. Demographic and comorbidities are reported in the Table. Procedures were elective in 11 patients (85%) and nonelective in two (15%). One of these patients had a symptomatic descending thoracic aortic aneurysm and the remaining was a ruptured PAAA. The GHVG was used for 20 visceral vessels, with a mean of 1.54 vessels per patients. Six RAs (30%; 2 right and 4 left), 9 SMAs (45%), and 5 CTs (25%) were debranched.

**Table.** Demographics and comorbidities

Variable	Mean $\pm$ SD or No. (N = 13)
Age, years	70 $\pm$ 8
Male gender	8
Hypertension	13
Diabetes	2
Lipid disorder	9
COPD	5
Renal function impairment	5
Coronary disease	4
ASA class 3 or 4	12
Peripheral arterial disease	4
Hostile chest	5
Hostile abdomen	5
PAAA	5
TAAA (Crawford I)	4
DTAA	1
Arch to visceral AA	3

AA, Aortic aneurysm; ASA, American Society of Anesthesiologists; COPD, chronic obstructive pulmonary disease; DTAA, descending thoracic aortic aneurysm; PAAA, pararenal abdominal aortic aneurysm; SD, standard deviation; TAAA, thoracoabdominal aortic aneurysm.

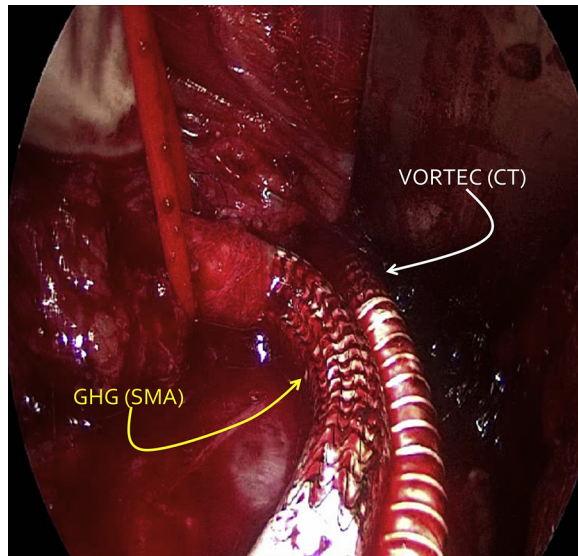
Additional visceral vessels were addressed in nine (69%) of these patients with chimney/periscope graft<sup>14,15</sup> (13 vessels), Viabahn Open Revascularization Technique<sup>16</sup> (2 vessels), and end-to-side anastomosis (2 vessels; Fig 1).

Immediate technical success was achieved in all cases. Perioperative mortality was 15% (2 patients). One death occurred on postoperative day (POD) 2 caused by bowel ischemia and multiorgan failure secondary to multiple embolization. The SMA and CT were not debranched in this patient. The other perioperative death, on POD 18, was caused by bowel ischemia due to acute SMA occlusion. The SMA in this patient was addressed with an end-to-side anastomosis.

Perioperative complications occurred in three patients (23%), consisting in one patient each of renal hematoma (chimney/periscope related), respiratory insufficiency requiring prolonged intubation, and small bowel ischemia due to a GHVG thrombosis in the SMA. Mean intensive care unit LOS was 2.5 days (range, 0-9; SD, 3 days), intubation duration was 1.4 days (range, 0-6; SD, 2 days), and in-hospital LOS was 12 days (range, 2-35; SD, 10 days).

One adjunctive maneuver was performed in the patient who presented with small bowel ischemia caused by SMA-GHVG occlusion. The GHVG bypass occlusion was managed successfully by endovascular locoregional lysis. Estimated survival at 6 months was 85%. The estimated primary and secondary patency was 95% and 100%, respectively. Survival and patency curves are depicted in Figs 2 and 3, respectively.

Debranching in 11 patients (85%) was followed by EVAR. EVAR was not performed in the remaining two patients due to death on PODs 2 and 18. The mean interval from visceral debranching with GHVG to aneurysm exclusion with EVAR was 2.5 months (range, 0-5; SD, 2 months). Both nonelective procedures were performed consecutively.



**Fig 1.** Intraoperative picture shows the proximal anastomosis of the Gore Hybrid Vascular Graft (GHG; W. L. Gore and Associates, Flagstaff, Ariz) to the superior mesenteric artery (SMA) and the Viabahn Open Revascularization Technique (VORTEC) anastomosis to the celiac trunk (CT).

## DISCUSSION

Conflicting results of hybrid debranching strategy for TAAA and PAAA treatment led to criticism and ambiguity of this approach, despite initial enthusiasm.<sup>17,18</sup> The systematic review by Moulakakis et al<sup>19</sup> analyzed 19 publications comprising 507 patients who underwent HR. This review reported a primary technical success of 96.2% (95% confidence interval [CI], 93.5%-98.2%) and visceral graft patency of 96.5% (95% CI, 95.2%-97.8%). The same report observed a pooled rate of 7.5% (95% CI, 5.0%-11.0%) for overall spinal cord ischemia symptoms, with an irreversible paraplegia rate of 4.5% (95% CI, 2.5%-7.0%). The pooled 30-day/in-hospital mortality rate was 12.8% (95% CI, 8.6%-17.0%). Despite these reported outcomes, the HR has demonstrated better results in some centers.<sup>20</sup>

One of the most important issues related to the high mortality rate of the HR technique is that this operation remains technically demanding because of the extensive aortic exposure and prolonged interruption of aortic flow to the visceral branches. During the last decades, several new technical improvements focused attention on the reduction of ischemic time during the renovisceral anastomosis to reduce the risk of bowel ischemia and the global procedure time.

In our experience, since 2007, covered self-expanding stents are being used to perform “sutureless anastomoses” on renovisceral aortic branches during debranching procedures. This tool obviated the need for technically demanding vessel exposure and anastomoses, thereby reducing the duration of flow interruption and simplifying the performance of complex aortic repair.

During this time, the original Viabahn Open Revascularization Technique, with the transection of the target vessel, has been modified. The novel technique consists of placement of the Viabahn self-expanding stent graft (W. L. Gore and Associates) in a Seldinger technique into the visceral arteries after surgical identification of the origin of these arteries.<sup>21</sup> Briefly, the Viabahn stent graft is passed through an ePTFE vascular graft, the visceral arterial wall is punctured, and a standard wire is placed. The Viabahn is then advanced (~2.5 cm) over the wire into the visceral artery, the vascular graft is placed against the arterial wall, and the stent graft is deployed. A balloon is inflated corresponding to the Viabahn that is positioned for half-length inside the artery and half-length inside the vascular graft. Finally, the arterial wall, the stent graft, and the vascular graft are fixed with a couple of stitches with Prolene (Ethicon, Somerville, NJ).

This modification already determined a reduced ischemic time from 11 minutes to <1 minute to perform a visceral anastomosis. The GHVG represents the natural evolution of this procedure, allowing a significant reduction of the global procedural time by using a single graft. The tubular heparin-bonded ePTFE graft is preconnected to the nitinol stent-reinforced section, guaranteeing in-line flow and avoiding flow turbulence. The device was released by Gore in 2012 in the European market and approved for hemodialysis access, lower limb bypass grafting, aortic arch debranching, and visceral revascularization.<sup>22</sup>

Bornak et al<sup>23</sup> reported the first case of sutureless visceral artery revascularization using the GHVG in 2012. They described the treatment of a symptomatic TAAA involving the visceral segment and an infrarenal AAA. The patient was treated in a two-staged hybrid approach combining an endovascular repair of the infrarenal segment, followed by an open thoracic aortic aneurysm repair. The large visceral arteries were revascularized using GHVG and a gradual funneling technique with Dacron (DuPont, Wilmington, Del).

After this first reported patient, excluding the literature regarding hemodialysis access, two authors reported patients treated with GHVG in different aortic segments<sup>24,25</sup> or in other districts.<sup>26-28</sup> The first large experience with the use of GHVG was recently reported by Chiesa et al<sup>29</sup> to address RAs during open TAAA repair. Their experience with 25 patients reported satisfactory results that are at least comparable to those of standard renal revascularization. This was the first study reporting GHVG outcomes in renovisceral debranching during TAAAs and PAAAs HR.

More recently Tsilimparis et al<sup>30</sup> reported their experience in 12 patients presenting challenging aortic disease and addressed with the GHVG in renovisceral arteries. In this series, with a median follow-up of 12 months, GHVG patency was 96%; moreover, using the GHVG resulted in a significant reduction of the time to perform the anastomosis compared with the standard anastomosis.

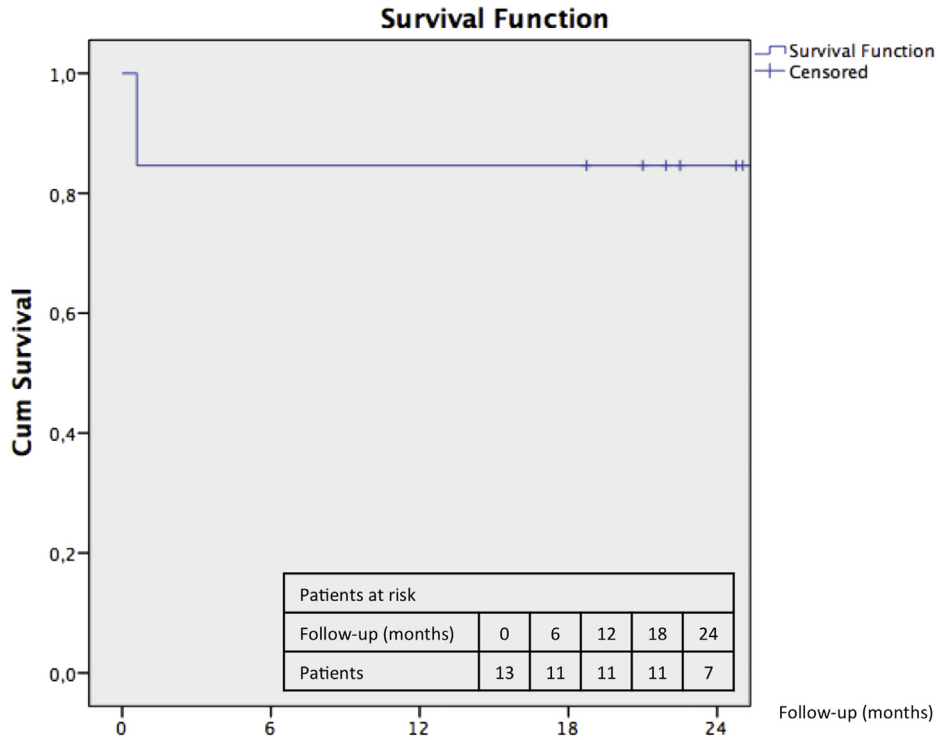


Fig 2. Estimated survival. The standard error is >10% at 1 month.

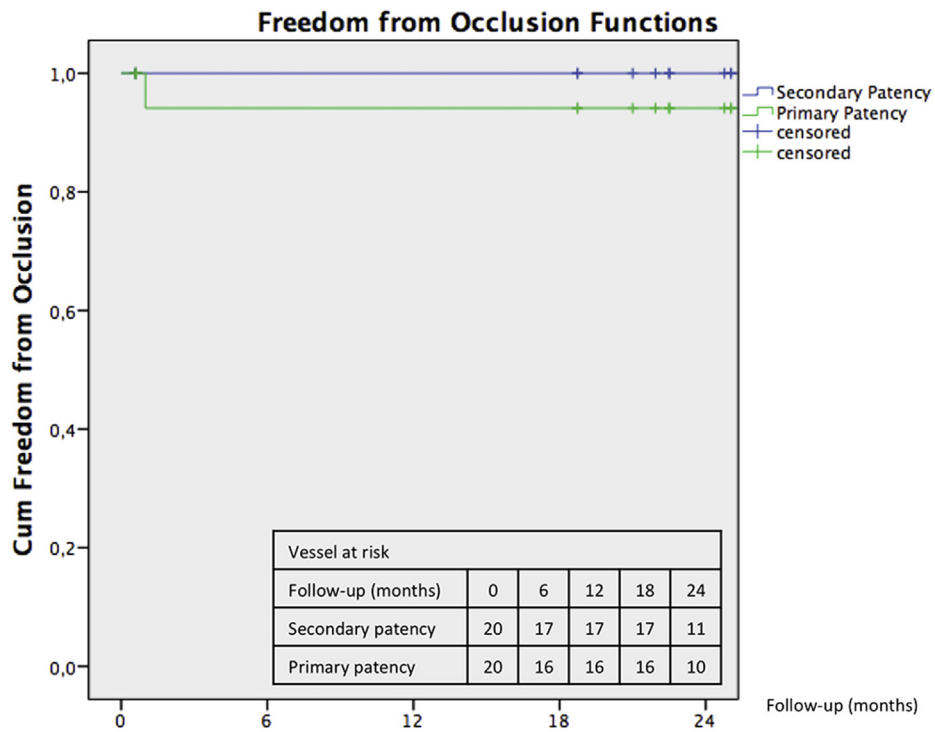


Fig 3. Estimated primary and secondary patency. The standard error is <10% at 24 month for primary and secondary patency.



Our limited experience of 13 patients showed that this technique was technically feasible in all the planned procedures, irrespective of renovisceral vessels anatomic location and quality, with good midterm results. In our reported experience, two patients died of bowel ischemia. The causes of death were due to multiple embolization in the first patient and to acute SMA occlusion in the second. It is important to note that only one RA was addressed in the first patient, and the SMA was revascularized in the second patient without GHVG but with end-to-side anastomosis.

At a median follow-up of 24.77 months, we reported one adjunctive procedure due to a GHVG-to-SMA occlusion that was successfully managed with locoregional lysis.

## CONCLUSIONS

This limited series has to be considered, together with important limitations related to the small number of cases. However, technical feasibility and short-term patency rate of the GHVG for renovisceral debranching during staged hybrid open and endovascular procedures were satisfactory. This novel graft will represent an additional step forward in the challenge of perioperative visceral ischemia, allowing faster procedures. The midterm results are very promising, especially considering that this treatment option is chosen in patients considered unfit or at high-risk for conventional surgery or inappropriate for fenestrated/branched EVAR. If long-term results remain good, this method could be an attractive alternative to open surgery or fenestrated/branched EVAR in selected patients.

## AUTHOR CONTRIBUTIONS

Conception and design: FS, FP, ML  
Analysis and interpretation: FS, FP, LC, NM, MS, FV, ZR  
Data collection: FS, FP, LC, MS  
Writing the article: FS, FP, FV, ML  
Critical revision of the article: FS, FP, NM, FV, ZR, ML  
Final approval of the article: FS, FP, LC, NM, MS, FV, ZR, ML  
Statistical analysis: FP  
Obtained funding: Not applicable  
Overall responsibility: FP

## REFERENCES

- Sveinsson M, Sobocinski J, Resch T, Sonesson B, Dias N, Haulon S, et al. Early versus late experience in fenestrated endovascular repair for abdominal aortic aneurysm. *J Vasc Surg* 2015;61:895-901.
- Pecoraro F, Pfammatter T, Mayer D, Frauenfelder T, Papadimitriou D, Hechelhammer L, et al. Multiple periscope and chimney grafts to treat ruptured thoracoabdominal and pararenal aortic aneurysms. *J Endovasc Ther* 2011;18:642-9.
- Ronchey S, Serrao E, Kasemi H, Pecoraro F, Fazzini S, Alberti V, et al. Endovascular treatment options for complex abdominal aortic aneurysms. *J Vasc Interv Radiol* 2015;26:842-54.
- Flye MW, Choi ET, Sanchez LA, Curci JA, Thompson RW, Rubin BG, et al. Retrograde visceral vessel revascularization followed by endovascular aneurysm exclusion as an alternative to open surgical repair of thoracoabdominal aortic aneurysm. *J Vasc Surg* 2004;39:454-8.
- Chiesa R, Tshomba Y, Melissano G, Marone EM, Bertoglio L, Setacci F, et al. Hybrid approach to thoracoabdominal aortic aneurysms in patients with prior aortic surgery. *J Vasc Surg* 2007;45:1128-35.
- Hughes GC, Andersen ND, Hanna JM, McCann RL. Thoracoabdominal aortic aneurysm: hybrid repair outcomes. *Ann Cardiothorac Surg* 2012;1:311-9.
- Hughes GC, Barfield ME, Shah AA, Williams JB, Kuchibhatla M, Hanna JM, et al. Staged total abdominal debranching and thoracic endovascular aortic repair for thoracoabdominal aneurysm. *J Vasc Surg* 2012;56:621-9.
- Black SA, Wolfe JH, Clark M, Hamady M, Cheshire NJ, Jenkins MP. Complex thoracoabdominal aortic aneurysms: endovascular exclusion with visceral revascularization. *J Vasc Surg* 2006;43:1081-9; discussion: 1089.
- Resch TA, Greenberg RK, Lyden SP, Clair DG, Krajewski L, Kashyap VS, et al. Combined staged procedures for the treatment of thoracoabdominal aneurysms. *J Endovasc Ther* 2006;13:481-9.
- Lin PH, Kougiyas P, Bechara CF, Weakley SM, Bakaeen FG, Lemaire SA, et al. Clinical outcome of staged versus combined treatment approach of hybrid repair of thoracoabdominal aortic aneurysm with visceral vessel debranching and aortic endograft exclusion. *Perspect Vasc Surg Endovasc Ther* 2012;24:5-13.
- Lachat M, Mayer D, Criado FJ, Pfammatter T, Rancic Z, Genoni M, et al. New technique to facilitate renal revascularization with use of telescoping self-expanding stent grafts: VORTEC. *Vascular* 2008;16:69-72.
- Chaikof EL, Brewster DC, Dalman RL, Makaroun MS, Illig KA, Sicard GA, et al. SVS practice guidelines for the care of patients with an abdominal aortic aneurysm: executive summary. *J Vasc Surg* 2009;50:880-96.
- Fillinger MF, Greenberg RK, McKinsey JF, Chaikof EL. Society for Vascular Surgery Ad Hoc Committee on TRS. Reporting standards for thoracic endovascular aortic repair (TEVAR). *J Vasc Surg* 2010;52:1022-33.
- Lachat M, Veith FJ, Pfammatter T, Glenck M, Bettex D, Mayer D, et al. Chimney and periscope grafts observed over 2 years after their use to revascularize 169 renovisceral branches in 77 patients with complex aortic aneurysms. *J Endovasc Ther* 2013;20:597-605.
- Lachat M, Bisdas T, Rancic Z, Torsello G, Mayer D, Gil-Sales J, et al. Chimney endografting for pararenal aortic pathologies using transfemoral access and the lift technique. *J Endovasc Ther* 2013;20:492-7.
- Rancic Z, Pecoraro F, Pfammatter T, Mayer D, Veith FJ, Lachat M. Less invasive (common) femoral artery aneurysm repair using endografts and limited dissection. *Eur J Vasc Endovasc Surg* 2013;45:481-7.
- van de Mortel RH, Vahl AC, Balm R, Buth J, Hamming JF, Schurink GW, et al. Collective experience with hybrid procedures for suprarenal and thoracoabdominal aneurysms. *Vascular* 2008;16:140-6.
- Da Rocha MF, Miranda S, Adriani D, Urganli F, Riambau VA, Mulet J. Hybrid procedures for complex aortic pathology: initial experience at a single center. *Rev Esp Cardiol* 2009;62:896-902.
- Moulakakis KG, Mylonas SN, Avgerinos ED, Kakisis JD, Brunkwall J, Liapis CD. Hybrid open endovascular technique for aortic thoracoabdominal pathologies. *Circulation* 2011;124:2670-80.
- Quinones-Baldrich W, Jimenez JC, DeRubertis B, Moore WS. Combined endovascular and surgical approach (CESA) to thoracoabdominal aortic pathology: a 10-year experience. *J Vasc Surg* 2009;49:1125-34.
- Donas KP, Lachat M, Rancic Z, Oberkofler C, Pfammatter T, Guber I, et al. Early and midterm outcome of a novel technique to simplify the hybrid procedures in the treatment of thoracoabdominal and pararenal aortic aneurysms. *J Vasc Surg* 2009;50:1280-4.
- W. L. Gores & Associates. Instructions for use for Gore Hybrid Vascular Graft. Available at: [http://www.goremedical.com/resources/dam/assets/AP3350ML3.HYVG.US\\_IFU.pdf](http://www.goremedical.com/resources/dam/assets/AP3350ML3.HYVG.US_IFU.pdf). Accessed August 20, 2015.
- Bornak A, Goldstein LJ, Rey J, Medina A, Yang JK, Velazquez OC, et al. Aortic aneurysmal repair with sutureless visceral revascularization using novel hybrid vascular graft and a gradual funneling technique. *Vasc Endovascular Surg* 2012;46:258-61.
- Levack MM, Bavaria JE, Gorman RC, Gorman JH 3rd, Ryan LP. Rapid aortic arch debranching using the Gore hybrid vascular graft. *Ann Thorac Surg* 2013;95:e163-5.
- Papadimitriou D, Mayer D, Lachat M, Pecoraro F, Frauenfelder T, Pfammatter T, et al. A clampless and sutureless aortic anastomosis technique using an endograft connector for aortoiliac occlusive disease in which the aorta cannot be clamped or sewn due to calcification or scarring. *Vascular* 2012;20:262-7.

- 26. Wipper S, Ahlbrecht O, Kolbel T, Pflugradt A, von Kodolitsch Y, Debus ES. First implantation of Gore Hybrid Vascular Graft in the right vertebral artery for cerebral debranching in a patient with Loeys-Dietz syndrome. *J Vasc Surg* 2015;61:793-5.
- 27. Nigro G, Gatta E, Pagliariccio G, Grilli C, Carbonari L. Use of the Gore Hybrid Vascular Graft in a challenging high-lying extracranial carotid artery aneurysm. *J Vasc Surg* 2014;59:817-20.
- 28. Pecoraro F, Bajardi G, Dinoto E, Vitale G, Bellisi M, Bracale UM. Endograft connector technique to treat popliteal artery aneurysm in a morbid obese patient. *Vascular* 2015;23:165-9.
- 29. Chiesa R, Kahlberg A, Mascia D, Tshomba Y, Civilini E, Melissano G. Use of a novel hybrid vascular graft for sutureless revascularization of the renal arteries during open thoracoabdominal aortic aneurysm repair. *J Vasc Surg* 2014;60:622-30.
- 30. Tsilimparis N, Larena-Avellaneda A, Krause B, Wipper S, Diener H, Kolbel T, et al. Results of the Gore Hybrid Vascular Graft in challenging aortic branch revascularization during complex aneurysm repair. *Ann Vasc Surg* 2015;29:1426-33.

Submitted Aug 20, 2015; accepted Dec 30, 2015.

Access to *Journal of Vascular Surgery Online* is reserved for print subscribers!

Full-text access to *Journal of Vascular Surgery Online* is available for all print subscribers. To activate your individual online subscription, please visit *Journal of Vascular Surgery Online*, point your browser to <http://www.jvascsurg.org>, follow the prompts to **activate your online access**, and follow the instructions. To activate your account, you will need your subscriber account number, which you can find on your mailing label (*note*: the number of digits in your subscriber account number varies from 6 to 10). See the example below in which the subscriber account number has been circled:

Sample mailing label

This is your subscription  
account number

*****3-DIGIT 001
SJ P1
FEB00 J024 C: 1 (1234567-89) U 05/00 Q: 1
J. H. DOE, MD
531 MAIN ST
CENTER CITY, NY 10001-001

Personal subscriptions to *Journal of Vascular Surgery Online* are for individual use only and may not be transferred. Use of *Journal of Vascular Surgery Online* is subject to agreement to the terms and conditions as indicated online.