

## Review

**Euromediterranean Biomedical Journal**  
*for young doctors*  
(formerly: Capsula Eburnea)

### PEDICLED PERFORATOR FLAPS IN NASAL RECONSTRUCTION: A REVIEW

Carlo Melloni, Francesca Toia, Salvatore D'Arpa,  
Matteo Rossi, Francesco Moschella, Adriana Cordova

#### SUMMARY

The use of perforator flaps in face reconstruction is becoming increasingly common. They are particularly useful in nose reconstruction, where they can be tailored to match the complex three-dimensional structure of the nasal concave and convex subunits. In this paper, we present a review of the literature on the use of pedicled perforator flaps in nose reconstruction, discussing current indications and outcomes. Literature on this topic is still limited, with only 12 studies reporting data on 129 reconstructions. Reconstruction of nasal defects with pedicled perforator flaps is a novel and expanding field. It allows for the achievement of good aesthetic results, with a single operation and low donor site morbidity. Temporary venous congestion frequently occurs, but resolves spontaneously without leaving sequelae. Also, perforator flaps have precipitated a novel approach to nose reconstruction, allowing for the modification of both random and axial flaps according to a "perforator-like technique".

#### Introduction

Multiple factors must be considered in the reconstruction of nasal defects. These include size and location of the defect, previous surgical treatments and patient's general health status. The patient's and surgeon's aesthetic aims should also be included in the decision making process.

Among the numerous options available, from simple skin grafts to free flaps, local flaps are still the preferred method for reconstruction of nasal defects, because they provide matching color and texture, resulting in a far superior aesthetic outcome.

Classical flaps for nasal defect reconstruction, such as forehead or nasolabial flaps, have some disadvantages with regard to limitations in their arc of rotation and the multiple stages of surgery necessary.

Perforator flaps have greatly expanded our reconstructive tools in all body regions and often allow us to overcome these limits. Since their first description by Koshima and Soeda (1) in 1989, these flaps have become popular in many areas of reconstructive surgery, because they provide design freedom, reduce donor site morbidity and allow thinner flaps to be tailored for more accurate reconstruction in single stage surgery.

#### Address of the authors

*Plastic and Reconstructive Surgery. Department of Surgical, Oncological and Oral Sciences. University of Palermo, Palermo, Italy*

**Send correspondence to:** *Francesca Toia, francescatoia@gmail.com*

**Received:** October 24th, 2014 — **Revised:** November 20th, 2014 — **Accepted:** December 2nd 2014

Perforator flaps are now increasingly indicated in face reconstruction, where the rich vascular network allows for greater flap versatility compared to other anatomic regions (2). They are particularly useful in nose reconstruction, where they can be tailored to match the complex three-dimensional structure of concave and convex subunits.

In this paper, we present a review of the literature on the use of pedicled perforator flaps in nose reconstruction, discussing current indications and outcomes.

### **Material and Methods**

A literature review of the studies on nose reconstruction with pedicled perforator flaps was performed on the PubMed electronic database using the keywords “perforator flap” and “nose” or “nasal reconstruction”. References of selected articles were evaluated to identify further relevant articles. Twelve papers were eventually included in this review.

Data on the number of treated patients, defect location, type of flap, and complications were extrapolated from each study (see table 1). Indications, surgical technique and outcomes of reconstruction of the different nasal sub-units are presented and discussed.

### **Results**

Perforator flaps offer a novel reconstructive strategy for nasal defects. However, literature on this topic is still limited, with 12 studies reporting data on 129 reconstructions. Nevertheless, considering that the first report was published in 2009 (3), these flaps have in fact generated a great deal of enthusiasm in the surgical community, due to their versatility and good results. Different perforator flaps have been reported for reconstruction of the different sub-units and for total nose reconstruction, as summarized and discussed below.

#### ***Nasal ala***

Since its first description in 1840 (4), the nasolabial flap has become the workhorse flap for nostrils and columellar reconstruction. The nasolabial sulcus is an ideal donor site for nasal reconstruction because it provides a good match in texture and color of the skin flap, and allows for the concealment of the donor scar. Cheek tissues present good laxity and permit the har-

vesting of enough tissue to reconstruct wide defects while achieving primary closure. However, it requires two surgical stages for delay and pedicle remodeling.

In 2009, we (3) reported a modification of the flap that eliminates the need for two surgical stages, overcoming the main limitation of the nasolabial flap. Our free-style facial artery perforator flap is raised from the same area as the nasolabial flap, but it is pedicled only on perforator vessels of the facial artery, and is indicated for subtotal/total reconstruction of the nasal ala.

The flap is drawn with its medial margin lying in the nasolabial sulcus. The medial margin of the flap is raised first to look for the perforators, which usually lie in a row underneath the nasolabial sulcus. This exploratory incision allows for the maintenance of the classical random nasolabial flap as a plan B in case of damage to the perforators. Once the artery is identified, the flap is incised circumferentially to identify the vein, which usually lies laterally. Both arterial and venous branches should be freed as far as required to mobilize the flap, taking care to avoid torsion or kinking of the pedicle. The flap is then transferred to the defect and the donor site is closed, thus, achieving reconstruction with a single operation. There is no additional bulk related to a skin or subcutaneous pedicle of the nasolabial flap, only the desired amount of skin and subcutaneous fat is transferred and the vascular pedicle (artery + vein +/- nerve) gives no additional bulk (3, 5).

Since its description, this flap has rapidly shown its reliability and reproducibility, as demonstrated by several reports by different authors published over the last few years (5-9). All of them reported its use for reconstruction of the nasal ala, which is the main indication for this flap. Also, similar but slightly different perforator flaps have been recently described: Karsidag et al. (10) reported their experience with a lateral nasal artery perforator flap, while Kovacevic et al. (11) described a turn in infraorbital artery perforator flap for reconstruction of the internal lining of the nostrils.

#### ***Nasal sidewall/dorsum***

Random cheek flaps have been traditionally used for reconstruction of small nasal sidewall defects up to 2.5 cm in size or in

Reference	N° Patients	Defect location	Flap	Source Vessel	Flap movement	Complications
Gunnarsson et al. (2014)	12	Nasal ala (4) Nose (not specified, 8)	Nasolabial Flap Supratrochlear propeller flap	Facial artery Supratrochlear artery	Rotation (150° - 180°)	Partial flap loss (1) Venous congestion (1) Minor revision surgery (3)
D'Arpa et al. (2014)	21	Nasal ala	Nasolabial perforator flap	Facial artery	Rotation (180°) Transposition V-Y advancement	Slight distal necrosis due to venous congestion (1)
Cordova et al. (2014)	25	Dorsum (8) Nasal ala and sidewall (10) Tip and Ala (5) Entire surface (2)	Supratrochlear artery axial propeller flap	Supratrochlear artery	Rotation (180°)	Partial flap loss (1)
Yoon et al (2013)	10	Nasal ala (5) Nasal sidewall (2) Nasal floor and vestibule (4)	Nasolabial Flap	Facial artery	Rotation (120° - 180°)	Temporary venous congestion (2)
Duzgun et al. (2013)	9	Nasal ala	Medial cheek flap + conchal cartilage graft	Facial artery	Rotation	Venous congestion (1)
Karsidag et al (2013)	8	Nasal ala (8)	Nasolabial Flap	Lateral nasal artery	Rotation (90°-180°) Transposition Advancement	Temporary venous congestion (2)
Kovacevic et al. (2013)	15	Nasal ala	Perforator Infraorbital Artery Island Flap (for internal lining)	Infraorbital artery	"Turn-in"	Skin graft loss (1), Wound dehiscence (1), Delayed nasal obstruction (2)
Rossi et al. (2013)	16	Nasal sidewall including the dorsum in 4 cases	Advancement perforator cheek flap	Transverse facial branch of the superficial temporal artery	Advancement	None
Brunetti et al (2012)	5	Nasal sidewall and/or medial canthal subunits	Angular artery perforator flap	Angular artery	Advancement	Temporary venous insufficiency
Sohn et al (2012)	8	Nasal ala	Nasolabial perforator flap	Facial artery	Rotation (up to 180°) Advancement	Temporary venous insufficiency (2)
Cordova et al. (2012)	15	Nose (not specified)	Forehead perforator flap	Supratrochlear artery	Rotation (180°)	
D'Arpa et al (2009)	8	Whole/partial ala including lateral wall in 2 cases	Nasolabial perforator flap	Facial artery	Rotation (180°) Transposition V-Y advancement	Slight distal necrosis due to venous congestion (1)

**Table 1.** Studies on nasal reconstruction with perforator flaps. For each study, the number of patients, the defect location, the flap used, its source vessel and movement, and complications are reported.

combination with other local flaps if the defects are wider or involve the infraorbital unit (12-16).

As for nasal ala defects, the popularity gained by perforator flaps has expanded the reconstructive potential of local flaps for nasal sidewall and dorsum.

Facial artery perforator flaps from the nasolabial fold have also been used for reconstruction of bigger defects involving not only the nasal ala, but also the nasal sidewall (7). Brunetti et al. (17) also reported the reconstruction of nasal sidewall defects with an angular artery perforator flap harvested from the nasolabial fold.

Another interesting perforator based flap for nasal sidewall/dorsum reconstruction was described by Rossi et al. (18) in 2013. This advancement perforator cheek flap has a lateral pedicle and the majority of its vascular supply derives from the transverse facial branch of the superficial temporal artery. Despite not being a true "perforator flap", dissection of the flap is undertaken with a perforator-sparing technique, and only those vessels that restrict flap movement are sacrificed. The flap is indicated for reconstruction of defects of the nasal sidewall, also in cases extending to nasal dorsum, medial canthal, and infraorbital units. Its perforator sparing harvesting technique allows for an increased mobility and versatility, and thus for reconstruction of moderate sized defects involving different nasal subunits, with a single donor site, without distorting surrounding functional and aesthetic structures. It is especially useful in older patients with skin excess in the cheek region.

#### ***Subtotal/full thickness defects***

If more than two nasal subunits are involved, flaps harvested from the forehead are the classical first choice for reconstruction (14). Several forehead flaps have been described based on the supraorbital and supratrochlear arteries (the paramedian forehead flap being the most popular), as the extensive skin redundancy and the colour and texture match make the forehead a perfect donor site for nasal reconstruction. Despite achieving excellent aesthetic results, the main drawback of these flaps is the need for multiple surgical steps.

Based on the same principles of nasal ala reconstruction, our group described a

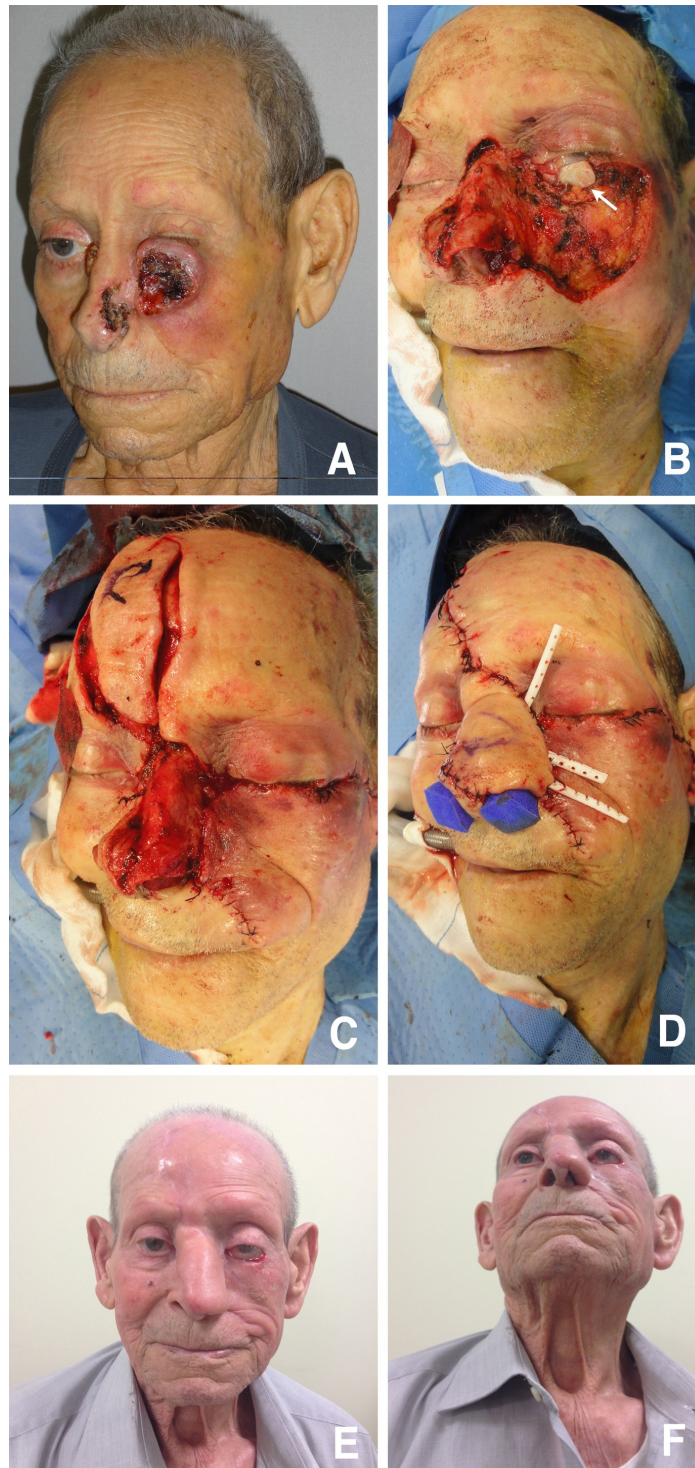
modification of the paramedian forehead flap that permits one stage reconstruction (19): we introduced a propeller flap based on the supratrochlear artery that we first defined as a perforator flap. Exact definition of a perforator flap in the face can be challenging. According to the Gent Consensus Conference (20), a perforator should pierce the deep fascia before reaching the skin. As there is no deep fascia layer in the face and the vessels pierce the superficial muscular aponeurotic system (SMAS) layer before reaching the skin, flaps based on vessels piercing the SMAS are also referred to as perforator flaps (3). Thus, this one stage paramedian forehead flap is better defined as supratrochlear artery axial propeller flap (STAAP flap) (21). The STAAP flap is pedicled on the supratrochlear artery, which, with its concomitant veins and nerve, emerges from the medial canthus, perforates the procerus muscle and corrugator supercilii muscle, and runs within the frontalis muscle to nourish the paramedian forehead skin (22). The STAAP flap has the same pedicle as a classical forehead flap but, despite not being a true "perforator flap", its pedicle is dissected in a "perforator like" way, allowing the flap to gain increased mobility and to rotate 180 degrees (2, 21, 23). Dissection of the flap is performed distally in a supramuscular plane, then in the suprapariosteal plane, like in a conventional forehead flap. The pedicle is then freed from any attachment to the surrounding tissues with the aid of loupe magnification. If some nervous branches are identified at this point, they must be cauterized and cut to allow pedicle rotation. The flap is then rotated: the frontal pad covers the nasal defect while; if necessary, the remaining nasal skin is used to cover a part of the donor site defect. This flap permits a single stage reconstruction of big defects involving more nasal subunits, and can be folded into itself to reconstruct even full-thickness defects (figure 1).

#### **Discussion**

Reconstruction of nasal defects with pedicled perforator flaps is a novel and expanding field. It allows for the achievement of good aesthetic results with a single operation and a low donor site morbidity. Numerous techniques, such as full thickness skin grafts, V-Y flaps, nasolabial flaps,

paramedian forehead flap, and even free flap have been described for nose recon-

struction, but achieving good aesthetic results in a single stage is still challenging



**Figure 1.** Eighty eight year old man with a squamous cell carcinoma involving the nose and the lower lid. A. Preoperative view. B. Resection included the nasal dorsum, the left nasal sidewall and the left nasal ala (full thickness defect), the lower lid (full thickness) and the cheek. The lower lid was reconstructed with a condromucosal graft harvested from the nasal septum (arrow). C. The lower lid and the cheek were reconstructed with an advancement cheek flap, and a right STAAP flap was raised. D. The STAAP was rotated clockwise and folded into itself to reconstruct the nose. E-F: three month postoperative view.

(12-14). Full thickness skin grafts, although requiring a single surgical step, have a typical “patch” appearance caused by color mismatch and contour defects; local flaps are aesthetically superior, but often require a second procedure to recreate the convex and concave nasal subunits and to avoid disruption of important aesthetic landmarks such as the alar groove, the nasofacial sulcus, or the melolabial crease (5, 24).

In the era of perforator flaps, thorough knowledge of skin vascularization allows us to modify known random or axial flaps to combine the advantages of a safe and reliable flap with high versatility and freedom of design. Perforator flaps for nose reconstruction are often the modification of existing flaps which achieve good results with one procedure.

Compared to other anatomical districts, perforator flaps in the face show a safer blood supply (2). They can be safely harvested both on a known pedicle, and as free style perforator flaps. Temporary venous congestion frequently occurs (25), but unlike other body regions, it frequently resolves spontaneously without leaving sequelae. Of the 129 nose reconstructions reviewed, venous congestion was reported in about 10% of cases, slight secondary distal necrosis was reported in only two cases (1.6%), and this did not require revision surgery.

Also, perforator flaps have precipitated a novel approach to nose reconstruction, allowing for the modification of both random and axial flaps according to a “perforator-like technique”: The STAAP flap (19, 21), despite being an axial propeller flap, can result in good aesthetic reconstruction in single stage surgery, overcoming the main drawback of the classical forehead flap. The advancement cheek perforator flap (18), despite being a random flap, has increased mobility (can even reach the dorsum of the nose) and a safer blood supply. This new approach has also stimulated the development of flaps based on a “perforator-like” dissection technique, such as the deep lingual artery axial propeller flap for intraoral reconstruction (26). Perforator flaps for nose reconstruction are safe, minimally invasive, can be performed under local anesthesia and do not require routine antibiotic therapy (27). Also, as shown by their increasing popular-

ity, they are easily reproducible and simple to perform. Consequently, they are likely to be used even more widely in the near future.

## References

1. Koshima I, Soeda S: Inferior epigastric artery skin flaps without rectus abdominis muscle. *Br J Plast Surg* 1989; 42:645-8.
2. D'Arpa S, Toia F, Pirrello R, Moschella F, Cordova A: Propeller flaps: a review of indications, technique, and results. *Biomed Res Int* 2014; 2014:986829. doi: 10.1155/2014/986829. Epub 2014 May 26.
3. D'Arpa S, Cordova A, Pirrello R, et al: Free style facial artery perforator flap for one stage reconstruction of the nasal ala. *J Plast Reconstr Aesthet Surg* 2009; 62:36-42.
4. Wesser DR, Burt Jr GB: Nasolabial flap for losses of the nasal ala and columella. Case report. *Plast Reconstr Surg* 1969; 44: 300e2.
5. D'Arpa S, Pirrello R, Toia F, Moschella F, Cordova A: Reconstruction of nasal alar defects with freestyle facial artery perforator flaps. *Facial Plast Surg* 2014; 30(3):277-86.
6. Gunnarsson GL, Jackson IT, Thomsen JB: Freestyle facial perforator flaps-a safe reconstructive option for moderate-sized facial defects. *Eur J Plast Surg.* 2014; 37:315-318.
7. Yoon TH, Yun IS, Rha DK, Lee WJ: Reconstruction of various perinasal defects using facial artery perforator-based nasolabial island flaps. *Arch Plast Surg.* 2013; 40 (6):754-60.
8. Duzgun S, Unlu E, Bali Y: A new facial artery free-style perforator flap and conchal cartilage graft for one-step reconstruction of the alar defects. *J Craniofac Surg.* 2013; 24(6):2053-5.
9. Yoon TH1, Yun IS, Rha DK, Lee WJ: Reconstruction of various perinasal defects using facial artery perforator-based nasolabial island flaps. *Arch Plast Surg.* 2013; 40(6):754-60.
10. Karsidag S, Ozcan A, Sumer O, Ugurlu K: Single-stage ala nasi reconstruction: lateral nasal artery perforator flap. *J Craniofac Surg* 2010; 21(6):1887-9.

- 11.Kovavevic P, Hrgovic I, Kovacevic T, Hrgovic Z: Single stage turn in perforator infraorbital artery island flap for nasal ala reconstruction. *Med Arh* 2013; 67(6): 450-453.
- 12.Turan A, Kul Z, Türkaslan T, Ozyiğit T, Ozsoy Z: Reconstruction of lower half defects of the nose with the lateral nasal artery pedicle nasolabial island flap. *Plast Reconstr Surg* 2007; 119(6):1767-1772.
- 13.Menick FJ: Nasal Reconstruction. *Plast Reconstr Surg* 2010; 125:138e-150e.
- 14.Burget GC and Menick FJ: The subunit principle in nasal reconstruction. *Plast Reconstr Surg* 1985; 76(2):239-247.
- 15.Redondo P: Advancement flap in the reconstruction of lateral nasal sidewall defect. *Dermatol Surg* 2006; 32(6):855-857.
- 16.Redondo P: Reconstruction of the anterior cheek, upper nasal ala, and lateral nasal sidewall. *Dermatol Surg* 2010;36(1):123-127.
- 17.Brunetti B, Tenna S, Aveta A, Segreto F, Persichetti P: Angular artery perforator flap for reconstruction of nasal sidewall and medial canthal defects. *Plast Reconstr Surg* 2012;130(4):627e-628e.
- 18.Rossi M, Milia A, Carmisciano M, D'Arpa S, Cordova A, Moschella F: Advancement perforator cheek flap for aesthetic one-stage reconstruction of postoncological extended split-thickness defects of the nasal sidewall. *ScientificWorldJournal* 2013; 27;2013:169208. doi: 10.1155/2013/169208.
- 19.Cordova A, D'Arpa S, Moschella F: A new one-stage method for nose reconstruction: the supratrochlear artery perforator propeller flap. *Plast Reconstr Surg* 2012; 129(3):571e-573e.
- 20.Blondeel PN, Van Landuyt KH, Monstrey SJ, Hamdi M, Matton GE, Allen RJ, Dupin C, Feller AM, Koshima I, Kostakoglu N, Wei FC: The "Gent" consensus on perforator flap terminology: preliminary definitions. *Plast Reconstr Surg* 2003;112:1378-83.
- 21.Cordova A, D'Arpa S, Tripoli M, Toia F, Moschella F: A propeller flap for single-stage nose reconstruction in selected patients: supratrochlear artery axial propeller flap. *Facial Plast Surg* 2014;30:332-341.
- 22.Yang D, Tang M, Geddes CR, Morris SF: Vascular anatomy of the integument of the head and Neck. In: Blondeel PN, Morris SF, Hallock GG, Neligan PC, eds. *Perforator Flaps Anatomy, Technique and Clinical Applications*. St. Louis, MO: QMP; 2006:134-160.
- 23.Hyakusoku H, Yamamoto T, Fumiiri M: The propeller flap method. *Br J Plast Surg* 1991;44:53-54.
- 24.Siddiqui A, Ditmars DM Jr: Island rotation flap for nasal reconstruction. *Plast Reconstr Surg* 2005; 116(6):1604-1609.
- 25.Montesano L, Corradino B, Giunta G, Mariolo A, D'Arpa S: Venous thrombosis in free flaps: a study on the phenomenology, history and clinical signs in an experimental model of rats. *Euromediterranean Biomedical Journal* 2013; 8(18):91-98.
- 26.Cordova A, Toia F, D'Arpa S, Giunta G, Moschella F: A new mucosal propeller flap (DLAAP): the renaissance of lingual flaps. *Plast Reconstr Surg* 2015; March, in press.
- 27.Toia F, D'Arpa S, Massenti MF, Amodio E, Pirrello R, Moschella F: Perioperative antibiotic prophylaxis in plastic surgery: a prospective study of 1,100 adult patients. *J Plast Reconstr Aesthet Surg* 2012; 65(5):601-9.