

Validation of a modified model of TNBS-induced colitis in rats. How to induce a chemical colitis in rats

Giovanni Tomasello^{2,6}, Emanuele Sinagra^{1,5,6}, Dario Raimondo⁵, Vincenzo Davide Palumbo^{1,2,6}, Roberto Puleio³, Mario Cottone⁴, Provvidenza Damiani⁷, Giovanna Traina⁸, Alida Abruzzo¹, Francesco Damiani¹, Salvatore Buscemi^{1,2}, Marcello Noto⁷, Attilio Ignazio Lo Monte^{2,7}

¹ PhD course on Surgical Biotechnology and Regenerative Medicine, University of Palermo, Italy; ² "DICHIRONS", Department of Surgical, Oncological and Stomatological Disciplines, University of Palermo, Italy; ³ Istituto Sperimentale Zooprofilattico Sperimentale della Sicilia, Palermo, Italy; ⁴ "DIBIMIS", Ospedali Riuniti Villa Sofia - V. Cervello, Internal Medicine Unit, University of Palermo, Italy; ⁵ Fondazione Istituto S. Raffaele - G. Giglio, Gastroenterology and Endoscopy Unit, Cefalù, Italy; ⁶ Euro-Mediterranean Institute of Science and Technology (IEMEST), Palermo, Italy; ⁷ School of Medicine and Surgery, University of Palermo, Italy; ⁸ Dipartimento di Scienze Farmaceutiche, Università degli Studi di Perugia, Perugia, Italy

Summary. *Background:* There is no standard practice in the induction of colitis by 2,4,6-trinitrobenzene sulfonic (TNBS) acid. Usually, the repeated administration of TNBS is preferred, because it will result in a local Th1 response that has the characteristics of Crohn's disease. *Materials and Methods:* A total of 30 rats were randomized into two groups, consisting of a saline control group of ten rats and a TNBS groups of 20 rats. After the animals were anesthetized, 0.5 ml of either 0.9% saline (controls) or TNBS 50 mg/kg dissolved in 50% ethanol were instilled into the colon through a rubber catheter. The experiment was repeated weekly for four weeks, then, the rats were killed at day 40, and the distal colon removed. *Results:* At day 40, the bowel wall was basically normal in the control group. In the TNBS group, the bowel lumen became narrow with thickened wall, and the mucosal surface presented adherent membrane with brown black, linear ulcers, proliferous lymphocyte tissue, inflammatory granulomas and submucosal neutrophil infiltration. The median score of the severity of the colonic damage was 0 in the control group, and 4,75 (range 4-5) in the TNBS group; the mean weight of the rats was 180+35 g in the TNBS group, while it was 215+25 in the control group. *Conclusions:* The presented experiment is a cost-effective and safe method to induce Crohn-like colonic damage using a lower dose of TNBS, thus avoiding the risk of a massive loss of rats. This model is rather suitable for the assessment of the effects of potential therapeutic agents. (www.actabiomedica.it)

Key words: inflammatory bowel diseases, colitis, rats, trinitrobenzene sulfonic, stem cell therapy

Introduction

There is no standard practice in the induction of colitis by 2,4,6-trinitrobenzene sulfonic (TNBS) acid (1). The TNBS-induced colitis can be evaluated developing three different models: acute, established and chronic colitis. These forms are not well documented

in current practice, and the absence of a standardized terminology leads to confusion (1, 2).

Usually, the repeated administration of TNBS is preferred, resulting in a local Th1 response that has the characteristics of Crohn's disease (3, 4). The chronic administration of TNBS should result in chronic colitis resembling Crohn's disease too, but, to date, there is

not yet much experience with this model. The chronic TNBS-induced colitis (induced by seven weekly intrarectal administrations of TNBS in ethanol) most likely reflects the chronic phase of Crohn's disease and it is accompanied by the production of IL-23 and IL-17 by isolated lamina propria mononuclear cells, 49 days after initial administration. Recently, this was clearly demonstrated by Fichtner-Feigh et al. (2). In this model, TNBS needed to be dosed very carefully to avoid a massive loss of mice (4, 5). The aim of our study is to evaluate the effects of repeated administration of TNBS in a sample of Wistar rats (5-7).

Materials and Methods

For this study, Wistar male rats weighing $235 \text{ g} \pm 25 \text{ g}$ were employed. The animals were housed in rack-mounted cages with a maximum of 2 rats, and were fasted for 12 hours with access to water ad libitum before the experiment. In this period, together with fasting, they underwent bowel cleansing through the administration of Polyethylene Glycole 1 g/kg, and, one hour before the experiment, through an evacuative enema with 0.9% saline solution. A total of 30 rats were randomized into two groups, consisting of a saline control group of 10 rats and a TNBS groups of 20 rats. The animals were anesthetized with 20% ethyl carbamate (6 ml/kg), and 0.5 ml of either 0.9% saline (controls) or TNBS 50 mg/kg dissolved in 50% ethanol were instilled into the colon through a rubber catheter (12 cm long, external diameter 2 mm). After instillation, the rats were held upside down by their tails for 60 seconds and then returned to their cages. The experiment was repeated weekly for four weeks, then the rats were killed at day 40, and the distal colon (8 cm) removed, opened longitudinally and washed to remove luminal contents (Fig. 1). The rats were sacrificed by cervical dislocation. The abdominal cavity was opened and a gross evaluation of the digestive tract was made, following an already consolidated protocol (8). The liver and the gastrointestinal tract, intact from anus to stomach, were immediately excised. The large intestine was subdivided into colon and rectum, and then opened longitudinally and cleaned with saline. Several samples were collected for the histological evaluation

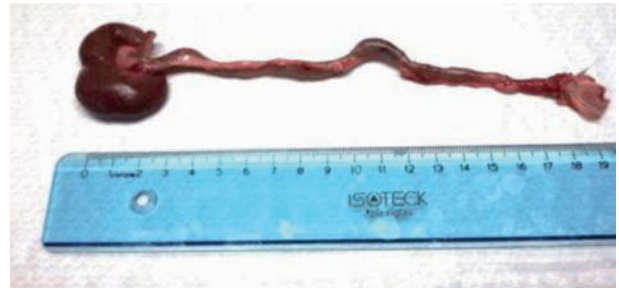

Figure 1. Sample of a portion of about 15 cm comprising the rectum and colon. Macroscopically areas of the inflammation site are observed, with increased volume of the lymph nodes (circles indicate the lymph nodes, and arrows the areas involved by inflammation)

and fixed in a solution of 10% of formalin. The excised colon was pinned out on a wax block washed with 0.9% saline and assigned to a code number (weight of colon segment 8-10 g). The colon was immediately examined under a stereomicroscope and any visible damage was scored on a 0-5 scale (Table 1), previously evaluated in another model. Small sections of colon were taken from two distinct areas from each colon and placed in 10% formalin for histological examination. Each sample was fixed in formalin and embedded in paraffin. Sections with a thickness of $5 \mu\text{m}$ were obtained from paraffin blocks, and were deparaffinised with xylene for 10 min at 60°C and hydrated with a decreasing ethanol gradient. They were stained with haematoxylin for 4 min (Merck KGaA, Darmstadt, Germany), blocked for 15 min in tap water, treated with eosin (Merck GgaA) for 1 min and rinsed in water. The sections were dehydrated and mounted with a coverslip for histological examination using an automated Leica DM5000 B microscope (Leica, Milan, Italy) connected to a Leica DC300 F high-resolution camera (Leica, Milan, Italy). All histological evaluations were carried out by

Table 1. Criteria for scoring the gross morphologic damage

Score	Gross morphology:
0	No damage
1	Localized hyperemia with no ulcers
2	Linear ulcers with no significant inflammation
3	Linear ulcers with inflammation at one site
4	Multiple sites of ulcers and inflammation, the size of ulcers <1 cm
5	Multiple inflammations and ulcers, the size of ulcers >1 cm

two different histopathologists on ten random fields at 200X magnification.

Myeloperoxidase activity was not evaluated. Furthermore, to examine the severity of the colitis, the body weight of the treated rats was measured every other day, and clinical findings such as area of ulcers (measured using NIH imaging software on the colon pictures), length (colocaecal junction to anal verge), and weight of the colon 10 days after the last TNBS injection were also assessed.

During the experimental period the weight of treated rats was decreased due to onset of diarrhea that led to intestinal malabsorption while the weight of control group remained stable.

Results

Forty days after TNBS/ethanol administration, the bowel wall was basically normal in the control group (Table 2). In the TNBS group, the bowel lumen became narrow with thickened wall (2-3 mm), while on the bowel mucosal surface there was an adherent membrane with brown black, linear ulcers (1-6 mm), proliferating lymphocyte tissue, inflammatory granulomas and submucosal neutrophilic infiltration. Macrophages, lymphocytes, fibroblasts, and cryptoabscesses were also observed. This group also presented noticeable ulcers and inflammatory granulomas in the colon; neutrophil infiltration was clearly observed in mucosa and sub-mucosa, and extensive necrosis of the colonic mucosa with exfoliation of the epithelia were found in the other rats with intact muscularis. In the case of severe ulcers, the colon often adhered to the surrounding intestinal tissues and abdominal wall (Fig. 1-4). 2 rats of TNBS groups died for diarrheal syndrome and cachexia after the second and the fourth day of treatment.

Table 2

T	T0	T1 (after 3 days)	T2 (after 7 days)	T3 (after 30 days)
Clinical features	absent	Diarrhea*	Bloody mucus diarrhea and weight loss	Bloody mucus diarrhea and weight loss

*Death of one rat on the second and fourth day of treatment

At the end of the experiment, the median score of the severity of the colonic damage was 0 in the control group, and 4.75 (range 4-5) in the TNBS group; the mean weight of the rats was 180+35 g in the TNBS group, while it was 215+25 in the control group.

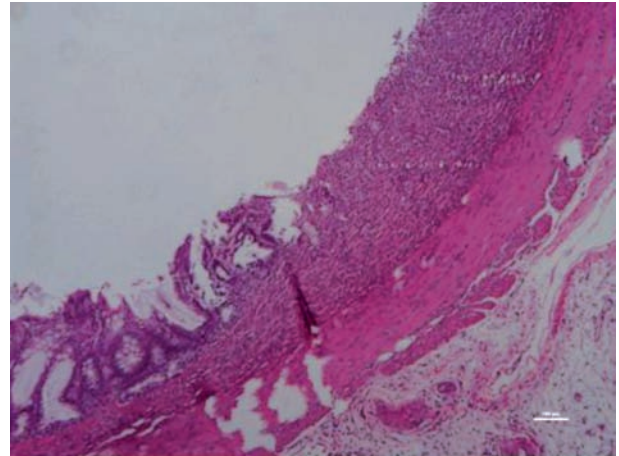


Figure 2. Histologically, in the tract of the rectum examined an inflammatory infiltrate is observed, consisting of monocyte cells (lymphocytes, macrophages, plasma cells) and some neutrophils, involving the mucosa and submucosa up to the tunica muscularis. Furthermore, there are observed areas of loss of the epithelial lining that reaches the muscularis (ulcers), in which the inflammatory infiltrate is more pronounced

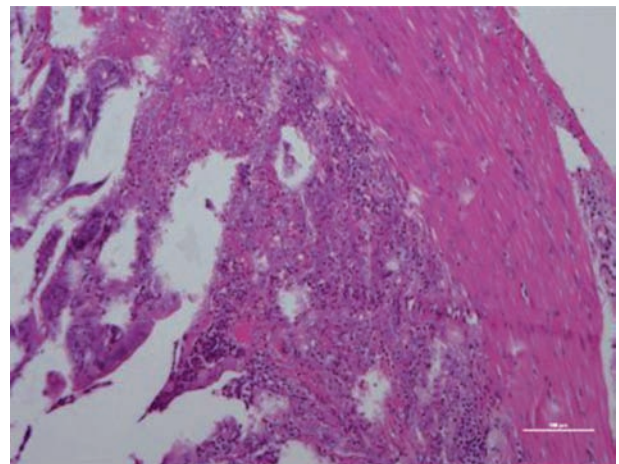


Figure 3. Histologically, in the tract of the rectum examined an inflammatory infiltrate is observed, consisting of monocyte cells (lymphocytes, macrophages, plasma cells) and some neutrophils, involving the mucosa and submucosa up to the tunica muscularis. Furthermore, there are observed areas of loss of the epithelial lining that reaches the muscularis (ulcers), in which the inflammatory infiltrate is more pronounced

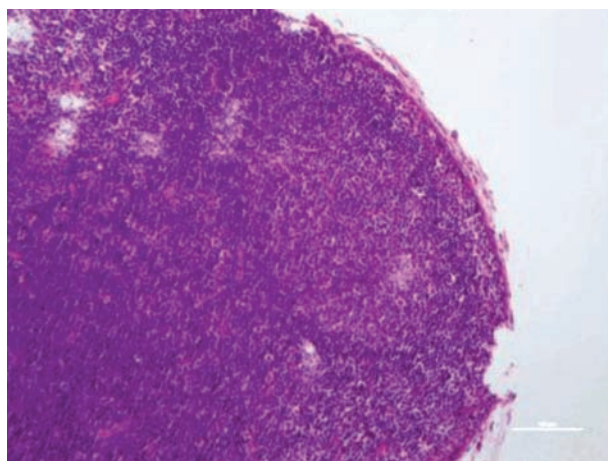


Figure 4. In the lymph node there is a hyperplastic lymphadenitis, with evidence of lymph corpuscles, the outcome of the insult to the rectum

Discussion

Our method for the induction of colitis in rats involves the use of 50 mg TNBS dissolved in 50% ethanol, a low dose which has proven to be able of causing a diffuse colonic inflammation, characterized by increased leukocyte infiltration, edema, and ulceration. This method based on a repeated administration of TNBS is developed because it will result in a local Th1 response that has characteristics of Crohn's disease. Furthermore, this dosage is chosen to avoid massive loss of rats as published also by other researchers reporting the use of similar doses (9, 10).

The experimental model used is a well-validated animal model, simple, reproducible, and adaptable to small animals. Over years, the development of the model of colitis by TNBS (as well as the development of other experimental models of intestinal inflammation) has allowed a very close study of early events, the analysis of the interactions between the different components and the identification of the immunological and genetic processes that determine susceptibility (3, 4). This model has provided important informations about the mechanisms underlying inflammation and pathogenesis as well as the treatment of inflammatory bowel diseases. The main objective of our study was to develop a model of chronic colitis by TNBS in the rat, to reproduce the clinical course of human chronic inflammatory bowel diseases, usually characterized by

periods of active inflammation interspersed with more or less long remissions, and subsequently, in a second step, to evaluate the therapeutic effect of fat-derived mesenchymal stem cells (FD-MSC) on the reactivation of colitis (11-13). To develop this model of TNBS-induced chronic colitis, we studied the effect of repeated instillation of the hapten on reactivation of the inflammatory process and the course of inflammation during the four-week duration of the experiment. The results showed that the repeated dose of TNBS induces a recurrence of the phenomenon inflammatory, with the appearance of ulcers in the colon, infiltration of granulocytes in the mucosa and submucosa and diarrhea in the treated group. 2 rats of this group died for diarrheal syndrome and cachexia after the second and the fourth day of treatment. The administration of TNBS in the model determines an increase in tissue levels of TNF- α and myeloperoxidase activity, and, consequently, is characterized by the presence of a significant inflammatory infiltrate (5), as demonstrated by histological analysis.

Conclusions

TNBS is a hapten which, when it is bound with tissue proteins, will turn into a antigen. It has been shown that it can elicit immunological responses, thus inducing generation of colitis (6, 7).

The TBNS model is widely used for the study of the immunological mechanism that have a role in the pathogenesis of IBD since it is easily induced and highly reproducible.

This model is characterized by a simple process, reproducibility of the colonic damage, and inexpensive and short duration of the experiment, thus obtaining long-lasting damage with inflammatory cell infiltration and ulcers. Thus the model is rather suitable for the assessment of the effects of potential therapeutic agents and it would be suitable for new regenerative therapies with adult stem cell.

In the present study, the dose of TNBS producing a moderate colonic inflammation and ulcers was about 50 mg/kg. The advantage of this model is that Crohn-like colonic damage was obtained using a lower dose of TNBS, thus avoiding the risk of a massive loss of

rats. Forthcoming studies are needed to evaluate the cytokine profile in this model.

References

1. te Velde A, Verstege MI, Hommes DW. Critical Appraisal of the Current Practice in Murine TNBS-induced Colitis. *Inflamm Bowel Dis* 2006; 12: 995-9.
2. Fichtner-Feigl S, Fuss IJ, Preiss JC, et al. Treatment of murine Th1- and Th2-mediated inflammatory bowel disease with NK-kappa B decoy oligonucleotides. *J Clin Invest* 2005; 115: 3057Y3071.
3. Zheng L, Gao QG, Wang SX. A chronic ulcerative colitis model in rats. *World J Gastroenterol* 2000; 6: 150-2.
4. Elson CO, Sartor RB, Tennyson GS, Riddell RH. Experimental models of inflammatory bowel disease. *Gastroenterology* 1995; 109: 1344-67.
5. Boughton-Smith NK, Wallace JL, Whittle BJ. Relationship between arachidonic acid metabolism, myeloperoxidase activity and leukocyte infiltration in a rat model of inflammatory bowel disease. *Agents Actions* 1988; 25: 115-23.
6. Little JR, Eisen HN. Preparation and characterization of antibodies specific for the 2, 4, 6 trinitrophenyl group. *Biochemistry* 1966; 5: 3385-95.
7. Fidler JM. Induction of hapten-specific immunological tolerance and immunity in B lymphocytes. Correlation between trinitrobenzenesulfonic acid administration, serum trinitrophenyl content, and level of tolerance. *Cell Immunol* 1985; 94: 285-91.
8. Bellavia M, Rappa F, Lo Bello M, Brecchia G, Tomasello G, Leone A, Spatola G, Uzzo ML, Bonaventura G, David S, Damiani P, Hajj Hussein I, Zeenny MN, Jurjus A, Schembri-Wismayer P, Cocchi M, Zummo G, Farina F, Gerbino A, Cappello F, Traina G. Lactobacillus casei and bifidobacterium lactis supplementation reduces tissue damage of intestinal mucosa and liver after 2,4,6-trinitrobenzenesulfonic acid treatment in mice. *J Biol Regul Homeost Agents* 2014; 28 (2): 251-61.
9. Ocón B, Anzola A, Ortega-González M, Zarzuelo A, Suárez MD, Sánchez de Medina F, Martínez-Augustin O. Active hexose-correlated compound and Bifidobacterium longum BB536 exert symbiotic effects in experimental colitis. *Eur J Nutr* 2013; 52 (2): 457-66.
10. Martínez-Augustin O, López-Posadas R, González R, Suárez MD, Zarzuelo A, Sánchez de Medina F. Genomic analysis of sulfasalazine effect in experimental colitis is consistent primarily with the modulation of NF-kappaB but not PPAR-gamma signaling. *Pharmacogenet Genomics* 2009; 19 (5): 363-72.
11. Bellavia M, Altomare R, Cacciabauda F, Santoro A, Allegra A, Concetta Gioviale M, Lo Monte AI. Towards an ideal source of mesenchymal stem cell isolation for possible therapeutic application in regenerative medicine. *Biomed Pap Med Fac Univ Palacky Olomouc Czech Repub* 2013 Jul 29. doi: 10.5507/bp.2013.051. [Epub ahead of print]
12. Allegra A, Altomare R, Curcio P, Santoro A, Lo Monte AI, Mazzola S, Marino A. Gene expression of stem cells at different stages of ontological human development. *Eur J Obstet Gynecol Reprod Biol* 2013; 170 (2): 381-6.
13. Gioviale MC, Bellavia M, Damiano G, Lo Monte AI. Beyond islet transplantation in diabetes cell therapy: from embryonic cells to transdifferentiation of adult cells. *Transplant Proc* 2013; 45 (5): 2019-24.

Received: 18 July 2014

Accepted: 15 September 2014

Correspondance:

Prof. Giovanni Tomasello

“DICHIRONS”, Dep. of Surgical, Oncological and Stomatological Disciplines

University of Palermo, Italy

E-mail: giovanni.tomasello@unipa.it