

Leg ulcer and osteomyelitis due to methicillin-susceptible *Staphylococcus aureus* infection after fracture repair treatment: a case highlighting the potential role of prostaglandin E₁ vasodilator

Ruolo della prostaglandina E₁ nel trattamento di una lesione ulcerosa con osteomielite causata da infezione da *Staphylococcus aureus* meticillino-sensibile dopo intervento chirurgico per frattura tibiale

Erminia Bentivegna¹, Emanuele Citarrella², Roberto Vivaldi², Dario De Luca³,
Giovanna Grazia Maira⁴, Alessandra Casuccio⁵, Paola Di Carlo⁵

¹Vascular Surgical Unit, Orestano Clinic, Palermo, Italy;

²Orthopedic - Trauma Unit, Orestano Clinic, Palermo, Italy;

³Department of Rehabilitation Medicine, Hospital District Palermo 3, Palermo, Italy;

⁴Chief of regional medical Leadership of National Workers Compensation Authority (INAIL), Italy;

⁵Department of Sciences for Health Promotion and Mother-Child Care "G. D'Alessandro",
University of Palermo, Italy

■ INTRODUCTION

In order for antimicrobial therapy to be effective, it is usually necessary to remove implanted devices. The formation of adherent, multilayered bacterial biofilms is the most important factor for the pathogenesis of medical device-related staphylococcal infections. Therefore, it is imperative that we develop a better understanding of the functional factors involved in biofilm formation, the mechanisms that regulate their expression, and the interaction between those potential virulence factors and the host in device-related infection [1, 2]. Important developments in the last few years may ultimately lead to judicious new approaches to prevention, diagnosis and treatment. The only sign of bone infection in non-diabetic and immune-competent patients may be a local symptom

such as skin ulceration from a bony fistula. Some recent studies have shown that treatment with a combination of vasodilator prostaglandins, such as prostaglandin E₁ (PGE₁) and prostaglandin E₂ (PGE₂), and antibiotics can lead to a rapid recovery from osteomyelitis, without the need for orthopedic surgery [3, 4]. The prostaglandins appear to reduce biofilm formation and chronicization of the infection, and stimulate a rapid and effective clearance of the infecting microorganism [5]. Here we report a case of recovery from *Staphylococcus aureus* osteomyelitis after management with antibiotics, anti-thrombotics and PGE₁ vasodilator in a patient with previous tibial plateau fracture repaired with internal fixation devices.

■ CASE REPORT

In December 2013, a 47-year-old patient with osteomyelitis and chronic ulcer on the proximal third of his left leg was examined at the Ortho-

Corresponding author

Alessandra Casuccio

E-mail: alessandra.casuccio@unipa.it

pedic Unit of “Orestano Clinic” in Palermo, Italy. No comorbidities or risk factors were reported in his past medical history. Two years before, the patient had had open reduction internal fixation (ORIF) surgery in a different hospital to repair both complex tibial plateau fractures (Schatzker type V; complex Schatzker type V injury with shaft dissociation and lateral articular surface impaction) in his left leg. No acute vascular lesions or severely compromised soft tissues were reported. One year later, the patient underwent another operation to remove the fixators as he was experiencing tibial pain and pain over the locking bolt sites, which was compromising work-related and leisure activities. Laboratory and microbiological examinations of intraoperative samples carried out at that time had excluded any bacterial colonization/infection. The patient reported an improvement in pain, although mild functional limitations persisted, mainly regarding weight-bearing ability while walking. Five months before we examined him, he had noticed the onset of local phlogosis with serous and subsequently purulent discharge at the site where the fixators had been removed and which was not healing correctly. Skin biopsy specimens of the leg ulcer were positive for methicillin-susceptible *Staphylococcus aureus* (MSSA). Identification (ID) and antimicrobial susceptibility testing (AST) were routinely performed using a microdilution method (BD Phoenix™ Automated Microbiology System, Sparks, MD, US). The minimum inhibitory concentration of the MSSA strain isolated was as follows: oxacillin <0.5 mg/L; rifampin <0.5 mg/L; clindamycin <0.5 mg/L; levofloxacin <1 mg/L; vancomycin <1 mg/L; teicoplanin <0.5 mg/L; trimethoprim/ sulfamethoxazole <0.5/9.5 mg/L; gentamicin <0.5 mg/L; imipenem/meropenem <1 mg/L; erythromycin >1 mg/L; tetracycline >1 mg/L. The strain showed resistance to tetracycline and macrolides. Results were interpreted using the European Committee on Antimicrobial Susceptibility Testing (EUCAST) clinical breakpoints [6]. A whole-body bone scintigraphy with ^{99m}Tc radioleukocytes (^{99m}Tc-WBC) and planar focal bone scan of the knees was performed at the Arnas-Civico Hospital, Palermo Italy. Two tracer accumulations were observed, one in the region of the tibial plateau and the other situated more centrally (Figure 1). Following the patient’s wishes, antibiotics were administered orally, as follows:

rifampicin 600 mg q 24 h plus trimethoprim-sulfamethoxazole (160 mg-800 mg twice a day). Three weeks later, the patient was admitted to the Vascular Surgical Unit of “Orestano Clinic”, as there had been no improvement in his clinical condition.

When he presented to us, he had been experiencing severe walking difficulties and had extensive ulceration on his left leg (Figure 2). Vital signs on admission were as follows: temperature 38.5°C, blood pressure 120/75 mmHg, pulse 95 beats/min, respiratory rate 22 breaths/min, and oxygen saturation 99% on room air. Relevant laboratory values on admission were as follows: leukocytosis with 13,700 leukocytes with prevalence of segmented elements (83%) and C-reactive protein (CRP) 21 mg/L (normal range <0.8 mg/dl).

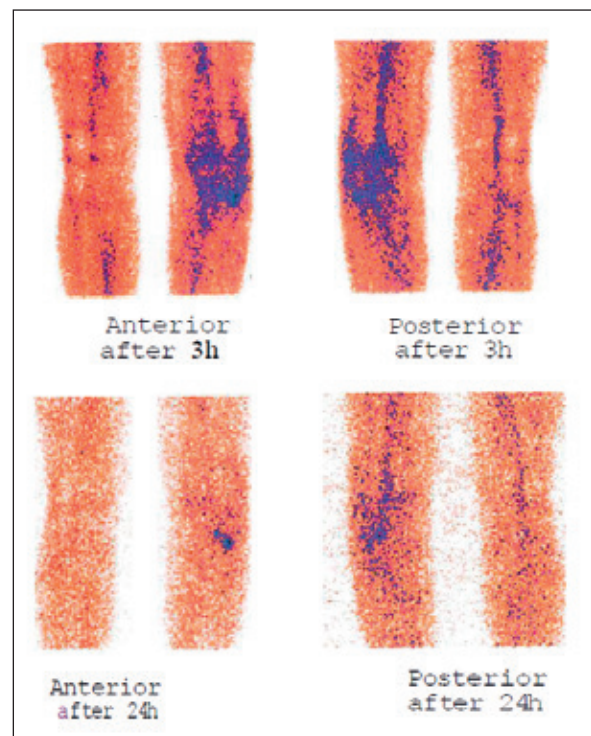


Figure 1 - “Whole body” biodistribution scintigraphy with intravenously administered radiolabeled autologous leukocytes and planar focal comparative and serial imaging of the knees at 3 and 24 hours showed two roundish, well-defined tracer accumulations of leukocytic phlogosis, one in the region of the lateral tibial plateau and the other more centrally located. They tend to increase in intensity over time (at 24 hours) and localize in a more evident manner.

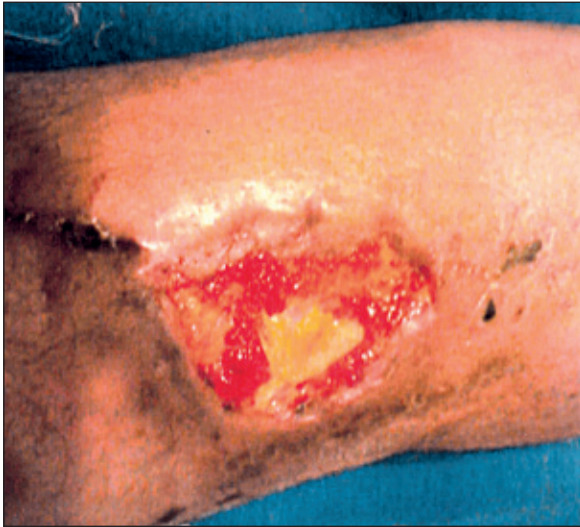

Figure 2 - Patient's ulcerative lesion on admission.

CT scan of the leg showed a high intensity area around the left proximal tibia. Blood culture identified MSSA with the same susceptibility profile as MSSA isolated from the skin biopsy. Consequently, the patient attended the "Orestano Clinic" Day Hospital facility to undergo the following 4-day therapeutic cycle: PGE₁ (alprostadiol 60 mg/

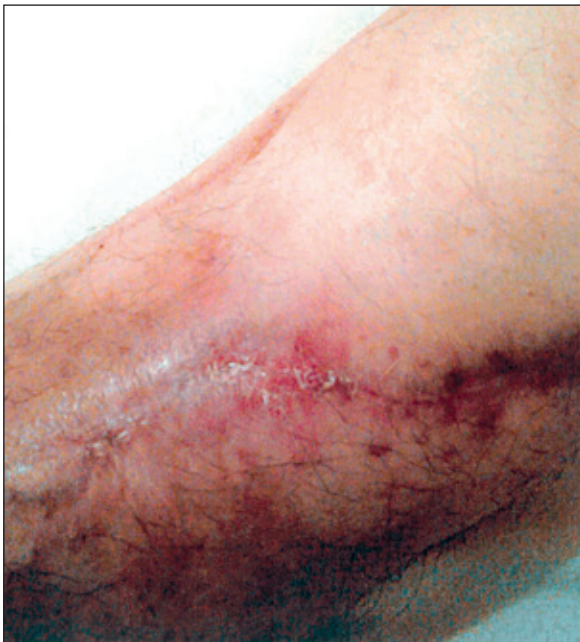

Figure 3 - Patient's ulcerative lesion after treatment.

day IV diluted with 250 cc of physiological solution in 3 hours, once a day) combined with nadroparin calcium (3800UI/0,4 ml, SC once a day) and gentamicin (6 mg/kg IV every 24 hours). This was subsequently followed by orally administered outpatient treatment with aminaftone (2-hydroxy-3-methyl- 1,4 naphthohydroquinone-2-p-aminobenzoate) 75mg/day plus propionyl L carnitine 1 g/day plus sulodexide 50 mg/day plus levofloxacin 750 mg one daily. The patient received this combination therapy for one month. During the treatment, outpatient vascular surgery evaluations showed an improvement in local symptoms and rapid re-epithelialization of the ulcer. We therefore recommended a second 4-day cycle of the intravenous treatment administered at the Day Hospital facility. At the time of discharge, the patient's painful symptoms had completely resolved and the ulcer had cicatrized (Figure 3); recovery from osteomyelitis was confirmed with a repeat scintigraphy.

■ DISCUSSION

Despite the development of various new methods of fracture reduction, implants for fracture fixation and better soft tissue handling techniques, decisions regarding the optimal treatment of Schatzker type V and VI tibial plateau fractures are controversial and challenging. Most patients have significant residual dysfunction after the completion of treatment [1]. Postoperative skin infections and osteomyelitis are prominently described in even the most recent, sophisticated protocols of international Orthopedic Trauma Societies [7]. For this reason, the authors do not attempt to discuss here the best surgical options, as this requires a specialized and multidisciplinary approach. Today, more than ever before, this type of orthopedic surgery takes a personalized approach, taking into account the characteristics of the initial trauma, the patient's risk factors and follow-up rehabilitation. Instead, we propose a new protocol for the management of infectious complications. After close examination of the literature, we maintain that this is the first clinical case of rapid recovery from osteomyelitis with ulceration due to bone fistulization in an immune-competent patient with no risk factors (*e.g.*, diabetes), following a treatment protocol for potential post-fracture in-

fection complications that included PGE₁. Recent studies have shown that prostaglandin-E and -I derivatives are potent stimulators of adenylate cyclase enzymes, producing cyclic adenosine monophosphate (cAMP) and inhibiting thrombocyte functions. These molecules induce vasorelaxation via direct effects on vascular smooth muscle, and by reducing oxygen consumption and superoxide anion production in injured organs [3-5].

Our case appears to corroborate the recent observations published by Lovati et al. [3, 4] which suggest that a combination of antibiotics and vasodilators may prevent bone infections in animal models. PGE₁ administration was found to significantly decrease the incidence of SSI in patients with spinal metastasis who underwent preoperative irradiation [8]. In our case, treatment was adapted to the wishes of the patient who refused intravenous antibiotics, therefore we prescribed combination treatment with rifampicin which appears to have a better outcome in oral therapy.

Nevertheless, it was only when we combined antibiotic therapy - and it should be noted that this involved a single antibiotic - with vascular-active substances that we saw a rapid improvement in the lesion and in clinical symptoms. Recently, evidence of their role in no-reflow phenomenon to hepatic injury after ischemia-reperfusion in transplanted patients has been reported [9].

It is possible that similar changes can occur after PGE₁ administration in the bone vessels, where alprostadil associated with nadroparin calcium may contribute to intraosseous hyperperfusion and block toxic osteonecrosis associated with

osteomyelitis. Moreover, sulodexide (SDX), a sulfated polysaccharide complex extracted from porcine intestinal mucosa, which is a blend of two glycosaminoglycan (GAG) entities, namely a fast-moving heparin (HP) fraction and a dermatan sulfate (DS; 20%) component, has been recommended for the treatment of vascular disease [10]. Findings on animal models suggest that a combination of antibiotics and vasodilators can prevent bone infections. On the basis of this case report and other research on organ transplants and animals, the authors suggest that PGE₁ has a favorable role in the evolution of bone infections. In conclusion, the case reported herein suggests that in the event of an accident at work, the protocol we used to treat osteomyelitis with cutaneous fistulization could reduce the healing time between the primary lesion and osteomyelitis complication. Whether these positive results will be confirmed later by other clinical trials could be a benefit for patients, with a significant improvement in quality of life and functional status and reduction in direct and indirect costs, in terms of a quicker recovery and return to work, fewer permanent after-effects and a lighter temporal and economic burden on the National Health Service.

Competing interest

The author(s) declare that they have no competing interests. No funding for Authors and for the manuscript preparation.

Keywords: Orthopaedic Implant-Related Infection, MSSA, osteomyelitis, prostaglandin E1 vasodilator.

SUMMARY

Prostaglandins appear to reduce biofilm formation and chronicization of infections, and stimulate a rapid and effective clearance of infecting micro-organisms. We report a case of recovery from methicillin-susceptible *Staphylococcus aureus* (MSSA) osteomyelitis after multidisciplinary management with antibiotics, anti-thrombotics and prostaglandin E1 (PGE₁) vasodilator, in a patient with tibial plateau fracture repaired with internal fixation devices. A 47-year-old HIV-negative male with chronic ulcer on the proximal third of the left leg was admitted to the Orthopaedic Unit of the Orestano Clinic in Palermo, Italy, for suspected osteomyelitis. A biopsy of the skin ulcer and blood cultures were performed and resulted positive for MSSA. Labelled leukocyte scintig-

raphy confirmed osteomyelitis. No clinical improvement was observed after combined antibiotic treatment with rifampicin plus trimethoprim-sulfamethoxazole. The patient underwent a 4-day therapeutic cycle: PGE₁ (alprostadil 60 mg/day IV) combined with nadroparin calcium plus gentamicin, followed by treatment with aminafone plus sulodexide plus levofloxacin. At discharge, the patient's painful symptoms had completely resolved and the ulcer had cicatrized; recovery from osteomyelitis was confirmed by scintigraphy. This treatment protocol including PGE₁ may result in a significant improvement in quality of life and functional status of patients with a reduction in direct and indirect costs and economic benefit for the National Health Service.

RIASSUNTO

Le prostaglandine sembrano ridurre la formazione di biofilm e la cronicizzazione delle infezioni, e stimolare una rapida ed efficace guarigione delle infezioni da parte di microrganismi patogeni. Al fine di riportare l'attenzione sulla rilevanza clinica di un trattamento multidisciplinare, descriviamo un caso di trattamento di osteomielite da *Staphylococcus aureus* meticillinosensibile (MSSA), trattata con antibiotici, antitrombotici e un farmaco vasodilatatore, la prostaglandina E1 (PGE₁), verificatosi in un paziente sottoposto a intervento chirurgico per frattura del piatto tibiale.

Nel dicembre 2013 un paziente di 47 anni con osteomielite cronica e ulcera sul terzo prossimale della gamba sinistra, è stato ricoverato presso l'Unità di Ortopedia della "Clinica Orestano" di Palermo, Italia. Sono stati eseguiti una biopsia dell'ulcera ed esame colturale che risultò positivo, al pari delle emocolture, per MSSA. La

scintigrafia ha confermato la diagnosi di osteomielite. Nessun miglioramento clinico è stato osservato dopo il trattamento antibiotico combinato con rifampicina più trimetoprim-sulfametossazolo.

Il paziente è stato sottoposto a 4 giorni di ciclo terapeutico con PGE₁ (alprostadi 60 mg/die IV) in combinazione con nadroparina calcio più gentamicina, seguita da trattamento con aminaftone più sulodexide più levofloxacina. Alla dimissione, la sintomatologia dolorosa era del tutto risolta e l'ulcera cicatrizzata; la guarigione dell'osteomielite è stata confermata mediante scintigrafia.

Il protocollo di trattamento che includeva PGE₁, può indurre un significativo miglioramento della qualità della vita e dello stato funzionale dei pazienti con riduzione dei costi diretti e indiretti e conseguenti benefici economici per il Servizio Sanitario Nazionale.

REFERENCES

- [1] Zimmerli W., Trampuz A., Ochsner P.E. Prosthetic joint infections. *N. Engl. J. Med.* 351, 1645-54, 2004.
- [2] Trampuz A., Widmer A.F. Infections associated with orthopedic implants. *Curr. Opin. Infect. Dis.* 19, 349-356, 2006.
- [3] Lovati A.B., Romanò C.L., Monti L., Vassena C., Previdi S., Drago L. Does PGE₁ vasodilator prevent orthopaedic implant-related infection in diabetes? Preliminary results in a mouse model. *PLoS One.* 9(4), e94758, 2014.
- [4] Lovati A.B., Drago L., Monti L., et al. Diabetic mouse model of orthopaedic implant-related *Staphylococcus aureus* infection. *PLoS One.* 8(6), e67628, 2013.
- [5] Gow A.J., Thom S.R., Ischiropoulos H. Nitric oxide and peroxynitrite-mediated pulmonary cell death. *Am. J. Physiol.* 274, 112e118, 1998.
- [6] European Committee on Antimicrobial Susceptibility Testing (EUCAST) clinical breakpoints Available online at: http://www.eucast.org/fileadmin/src/media/PDFs/EUCAST_files/Breakpoint_tables/. Last accessed October 20, 2014.
- [7] Hall J.A., Beuerlein M.J., McKee M.D., Canadian Orthopaedic Trauma Society. Open reduction and internal fixation compared with circular fixator application for bicondylar tibial plateau fractures. Surgical technique. *J. Bone Joint Surg. Am.* 91 (Suppl 2), Pt 1, 74-88, 2009.
- [8] Demura S., Kawahara N., Murakami H., et al. Surgical site infection in spinal metastasis: risk factors and countermeasures. *Spine (Phila Pa 1976)*, 34, 635-639, 2009.
- [9] Aliosmanoglu I., Sevmis S., Karakayali H., et al. Effect of Prostaglandin E-1 on Wisconsin University and Histidine-Tryptophan-Ketoglutarate Preservation Solutions on Preservation Injury of the Perfused Liver. *Transplantation Proceedings.* 45, 2446-2450, 2013.
- [10] Coccheri S., Mannello F. Development and use of sulodexide in vascular diseases: implications for treatment. *Drug Des. Devel. Ther.* 8, 49-65, 2013.