



Incarcerated hernia in a trocar site following laparoscopic gastric bypass



Ann. Ital. Chir.

Published online (EP) 18 November 2013

pii: S2239253X13021956

www.annitalchir.com

Giuseppina Ferro, Calogero Cipolla, Angela La Porta, Laura Montana, Clizia Airò Farulla, Giuseppina Guercio, Gianni Pantuso

A.O.U. Policlinico "Paolo Giaccone", Division of General and Oncological Surgery, University of Palermo, Palermo, Italy

Incarcerated hernia in a trocar site following laparoscopic gastric bypass

This paper reports a case of small bowel occlusion due to the herniation of an ileal ansa at the site of the insertion of a 12-mm trocar. A 28-year-old obese female patient underwent laparoscopic surgery for gastric bypass, the skin incisions of the trocar insertion sites were closed with absorbable sutures. Small bowel occlusion occurred on post-operative day 6 and the patient again underwent laparoscopic surgery. Laparoscopic exploration confirmed the suspected presence of the incarcerated hernia of an ileal ansa at the site of the trocar insertion which was freed without any need for bowel resection. The fascial defect was successfully closed under direct vision with the use of a special system of fascial sutures.

KEY WORDS: Incarcerated hernia, Laparoscopic surgery, Trocar site.

Introduction

Gastric bypass is one of the most frequently performed bariatric surgical procedures throughout the world. The annual number of cases has increased considerably in the last few years, ranging from 14,000 per year in 1998 to almost 100,000 at the present time¹. The weight reduction associated with the metabolic effects of gastric bypass, together with the now almost routine use of laparoscopy make it the procedure of choice for several types of patients, especially obese subjects with concomitant diseases such as diabetes, high blood pressure and dyslipidemia^{2,3}. The most frequent complications are fistulas, incision infection, bowel occlusion and anas-

tomotic stenosis. Furthermore, a fairly rare complication following laparoscopy is the herniation of bowel ansae at the trocar access sites.

This case report concerns bowel occlusion caused by the herniation of an ileal ansa at the site of a trocar insertion occurring at the immediate post-operative phase in a patient who had undergone videolaparoscopic gastric bypass.

Case report

In September 2010, we examined a 28-year-old obese woman with a BMI of 52 kg/m² and no concomitant disease. After the multidisciplinary preoperative work-up, consisting of surgical, medical and psychiatric examinations, the patient's extremely high BMI and the fact that she could be classified as a "sweet eater", led us to opt for a gastric bypass.

Surgery was performed under videolaparoscopy by means of the insertion of 5 10-12 mm trocars. After splitting the omentum, a gastric pocket of 24 cc was created and the jejunum was cut at 80 cm from Treitz's angle; gastro-jejunal anastomosis was performed with the use of

Pervenuto in Redazione Giugno 2013. Accettato per la pubblicazione Settembre 2013

Correspondence to: Calogero Cipolla, MD, Division of General and Oncological Surgery A.O.U. Policlinico "Paolo Giaccone", Via del Vespro 129, 90127 Palermo, Italy (e-mail: calogeroqipolla@virgilio.it)

Gagner's technique, using the small head of a CEEA 25 mm circular stitcher inserted along the oro-gastric pathway. Jejun-jejunal anastomosis with the proximal (biliary) ansa was performed at a meter from that of the gastro-jejunal anastomosis. The laparoscopic openings were closed in the normal way with fascial stitches of the skin incisions.

On post-operative day 2, the patient was canalized for gas. On day 4 an x-ray of the alimentary canal with the use of a water-soluble iodate contrast medium (Gastrografin Bayer ®) proved to be perfectly normal and the patient was therefore put on a water and semi-liquid diet.

On day 6, the patient vomited biliary material several times and the alvus became closed to feces and gas, although no abdominal pain was reported and the blood chemistry results, particularly the white blood cells and the electrolytes, proved to be quite normal.

Since the vomiting and absence of fecal canalization continued, on day 8 a further x-ray of the alimentary canal was performed with the use of a water-soluble iodate contrast medium (Gastrofin Bayer ®) together with a direct x-ray of the abdomen, which showed an interruption of the contrast means at the distal jejunum, with the dilatation of the upper bowel ansae and the presence of hydro-aerial levels (Fig. 1a).

The patient therefore underwent further laparoscopic surgery, which revealed an incarcerated bowel ansa below the jejun-jejunal anastomosis at the trocar site on the left hemiclavear line, at the point where the CEEA 25mm circular stitcher had been inserted for the gastro-jejunal anastomosis. The muscular fascia proved to be permeable at this point, probably because the fascial stitches applied from outside through the skin opening had not involved the peritoneal wall. This had most likely brought about the herniation of the bowel during elimination of the pneumoperitoneal CO₂ at the end of the operation (Fig. 1b).

After checking that the gastro-jejunal and jejun-jejunal anastomosis performed during the first operation were still integral, the herniated ansa was freed with extreme caution. As soon as its vitality and the normal functioning of peristaltic activity had been verified, all the laparoscopic openings were closed by means of a special direct vision closure system (Carter-ThomasonClose Sure System® - CooperSurgical Inc., Trumbull CT USA), made up of a blunt pilot inserted under direct vision into the laparoscopic openings, permitting the guided passage of the suture thread through the fascial layers with the use of a Reverdin needle along the preformed pathways (Fig. 2). In this way it was possible to make sure that all the openings were properly closed up.

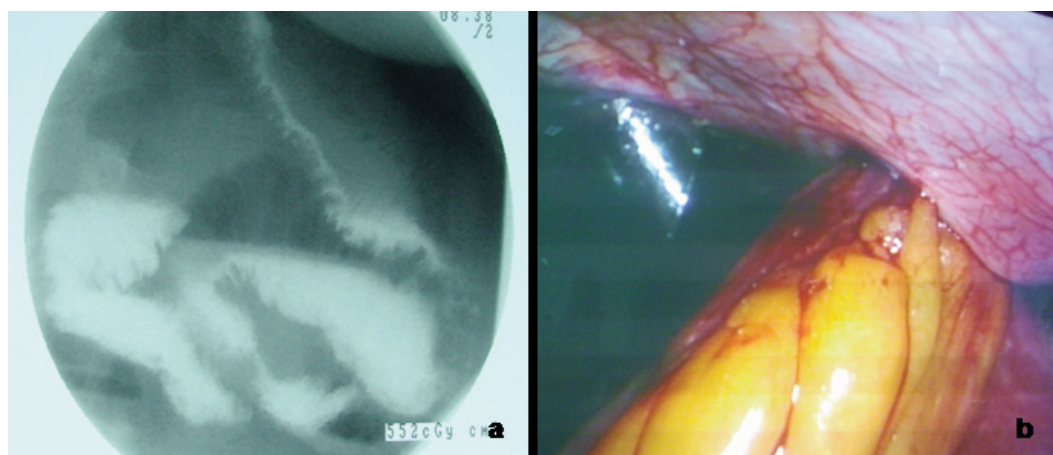


Fig. 1: A) Gastrografin® control performed on day 8 (dilatation of the bowel ansae); B) bowel incarcerated in a laparoscopic access point of the left hemiabdomen.

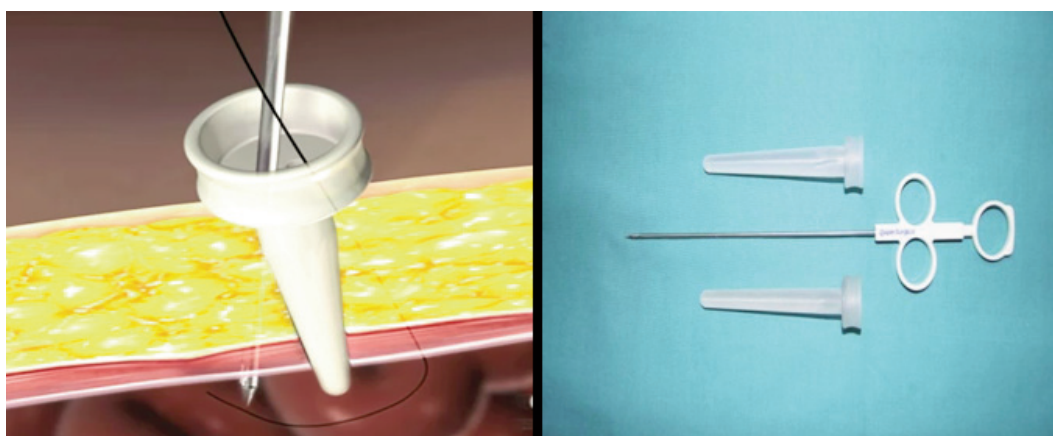


Fig. 2: Fascial suturing with Carter-ThomasonClose Sure System® - Cooper Surgical Inc., Trumbull CT USA.

On post-operative day 1, the patient was already canalized for feces and gas; x-ray control of the alimentary canal was performed with a water-soluble iodate contrast means (Gastrografin Bayer ®) on day 2 she was put on a semiliquid diet and on day 3 was sent home.

Discussion

Crist and Gadacz⁴ have defined herniation at the trocar site as developing through the insertion site of the cannula. Tounochi⁵ has reported the incidence of hernias at the port site as ranging from 0.65% to 2.8%; the percentage in cases of bariatric surgery is reported as 1%⁶.

Hernias occurring at the trocar site have been classified into three types: one with early onset, immediately following surgery; one with a much later onset several months after the operation; one, the so-called "special" hernia, which involves dehiscence of the whole abdominal wall⁵.

The pathogenesis of the occurrence of a hernia at a trocar site would appear to be linked to several predisposing factors, for example, the dimensions of the trocar⁷, infections of the surgical incision⁸ and malnutrition⁹. Obesity is also thought to be a predisposing factor, both because of the high intraabdominal pressure and of the larger preperitoneal space present in obese subjects¹⁰. Numerous Authors have shown that most trocar site hernias occur along the linea mediana, particularly in the umbilical and paraumbilical zone¹¹. Duron et al.¹² have reported a lower incidence of such hernias along the lateral abdominal wall due to the particular conformation of the fascial and muscular layers in that area.

From the clinical point of view, herniation at the trocar site may cause abdominal pain, nausea, vomiting, closure of the alvus to feces and gas or present without any symptoms at all, even for as long as several months¹³. Confirmation of the diagnosis requires direct abdominal x-ray or a CT scan of the abdomen¹⁴.

The aim of this case report is to emphasize the fact that phenomena of bowel occlusion may occur, even at a very early stage and without any clinical symptoms or laboratory data indicating acute abdomen¹⁵. In our own case, except for the rare episodes of vomiting and the lack of fecal and gas canalization, palpation of the patient's abdomen did not cause any pain and enterocolic tympanism was normal, as were the results of blood chemistry tests. The absence of hyperperistaltism, which is a typical sign of mechanical occlusion, might have been due to the lack of an antireflux mechanism, brought about physiologically by the pylorus, since the latter is excluded from the alimentary canal after gastric bypass.

We agree with most of the Authors concerned that a meticulous closure of the wall defects caused by the insertion of the trocars is of fundamental importance.

The fascial stitching of the small skin openings using normal sutures with a curved needle proves to be difficult, especially in obese subjects, and therefore not very efficient. Following this experience, in our routine surgical procedure we have begun to use the Carter-ThomasonClose Sure System® (CooperSurgical Inc. Trumbull CT USA) direct vision fascial suture system, consisting of a blunt pilot inserted under direct vision into the trocar holes which permits the guided passage of the suture thread with a Reverdin needle through all the fascial layers along the preformed canals. With the use of this method we have had no further similar complications.

In conclusion, this system of closure of the trocar access holes should be used in all obese patients because of the large amount of subcutaneous tissue present in such subjects. Closure without any laparoscopic vision might in fact prove to be difficult and insufficient, since the resulting sutures might not include all the layers of the abdominal wall.

Riassunto

Viene riportato un caso clinico di occlusione intestinale causata dall'erniazione di un'ansa ileale nel sito di introduzione di un trocar. La paziente, affetta da grave obesità, era stata sottoposta ad intervento chirurgico di bypass gastrico videolaparoscopico. La fascia muscolare nelle sedi di introduzione dei trocars era stata suturata dall'esterno con fili di sutura riassorbibili. In sesta giornata postoperatoria si registravano i sintomi di una occlusione intestinale, confermata anche da un controllo radioscopico del transito intestinale con mezzo di contrasto idrosolubile.

In videolaparoscopia è stata evidenziata un'ansa ileale erniata ed incarcerata all'interno del sito di introduzione di uno dei trocars da 12 mm. Delicata riduzione dell'ansa, ben vascolarizzata, in cavità peritoneale e sutura del difetto di parete sotto visione diretta con un sistema di chiusura sotto visione diretta (Carter-ThomasonClose Sure System®) per via laparoscopica.

Decorso postoperatorio regolare, canalizzazione ai gas già in prima giornata postoperatoria; dimissione della paziente in terza giornata post-operatoria dal secondo intervento.

Il sistema di chiusura sotto visione diretta della fascia muscolare nelle sedi di introduzione dei trocars dovrebbe sempre essere preso in considerazione nella chirurgia videolaparoscopica bariatrica considerato che l'abbondante pannicolo adiposo sottocutaneo può rendere difficoltosa se non addirittura inefficace la chiusura della fascia dall'esterno.

References

1. Mokdad AH, Bowman BA, Ford ES, Vinicor F, Marks JS, Koplan JP: *The continuing epidemics of obesity and diabetes in the United States*. JAMA, 2001; 286:1195-200.

2. Calle EE, Thun MJ, Petrelli JM, Rodriguez C, Heath CW Jr.: *Body mass index and mortality in a prospective cohort of US adults*. N Engl J Med, 1999; 341:1097-105.
3. Schauer PR, Ikramuddin S: *Laparoscopic surgery for morbid obesity*. Surg Clin North Am, 2001; 81:1145-179.
4. Crist DW, Gadacz TR: *Complications of laparoscopic surgery*. Surg Clin North Am, 1993; 73:265-89.
5. Tounouchi H, Ohmori Y, Kobayashi M, Kusunoki M: *Trocar site hernia*. Arch Surg, 2004; 139:1248-256.
6. Schauer PR, Ikramuddin S, Gourash W, Ramanathan R, Luketich J: *Outcomes after laparoscopic Roux-en-Y gastric bypass for morbid obesity*. Ann Surg, 2000; 232:515-29.
7. Azurin DJ, Go LS, Arroyo LR, Kirkland ML: *Trocar site herniation following laparoscopic cholecystectomy and the significance of an incidental preexisting umbilical hernia*. Am Surg, 1995; 61:718-20.
8. Wallace DH, O'Dwyer PJ: *Clinical experience with open laparoscopy*. J Laparoendosc Adv Surg Tech A, 1997; 7:285-88.
9. Coda A, Bossotti M, Ferri F, et al.: *Incisional hernia and fascial defect following laparoscopic surgery*. Surg Laparosc Endosc Percutan Tech, 2000; 10:34-38.
10. Cottam DR, Gorecki PJ, Curvelo M, Weltman D, Angus LD, Shaftan G: *Preperitoneal herniation into a laparoscopic port site without a fascial defect*. Obes Surg, 2002; 12:121-23.
11. Azurin DJ, Go LS, Arroyo LR, Kirkland ML: *Trocar site herniation following laparoscopic cholecystectomy and the significance of an incidental preexisting umbilical hernia*. Am Surg, 1995; 61:718-20.
12. Duron JJ, Hay JM, Msika S, Domergue J, Gainant A, Fingerhut A: *Prevalence and mechanisms of small intestinal obstruction following laparoscopic abdominal surgery: A retrospective multicenter study*. Arch Surg, 2000; 135:208-12.
13. Sanz-Lopez R, Martinez-Ramos C, Nunez-Pena JR, Ruiz de Gopegui M, Pastor-Sirera L, Tamames-Escobar S: *Incisional hernias after laparoscopic vs open cholecystectomy*. Surg Endosc, 1999; 13:922-24.
14. Maio A, Ruchman RB: *CT diagnosis of post laparoscopic hernia*. J Comput Assist Tomogr, 1991; 15:1054-55.
15. Velasco JM, Vallina VL, Bonomo SR, Hieken TJ: *Post laparoscopic small bowel obstruction: Rethinking its management*. Surg Endosc, 1998; 12:1043-45.