

## Original Article

**Euromediterranean Biomedical Journal**  
*for young doctors*  
(formerly: Capsula Eburnea)

### THE ROLE OF THE VASTUS LATERALIS FLAP IN HEAD AND NECK RECONSTRUCTION

Francesca Toia, Sebastiano Oieni, Salvatore D'Arpa, Luigi Montesano,  
Matteo Rossi, Adriana Cordova

#### SUMMARY

The Vastus lateralis flap is a very versatile flap, easy to harvest and with a long pedicle. It can be harvested as a muscle, musculo-cutaneous or chimeric flap. It is particularly suitable for head and neck reconstruction, as it allows for a two-team approach and can be tailored to the complex three-dimensional structure of this district.

In this paper, we discuss our experience and a review of the literature on the use of the free Vastus lateralis flap in the head and neck region, analyzing its indications, advantages and limitations. We also provide technical tips to minimize donor site morbidity.

#### Introduction

The Vastus lateralis (VL) flap is a very versatile flap: it is easy to harvest, has a long pedicle, and can be tailored to several reconstructive needs.

It was first described as a free flap in 1992 (1); however, despite its positive features, it has only seen a limited take up over time. Reviewing the literature we found that only 15 papers with a total of 1999 patients detail the use of this flap in the head and neck.

Over the last few years, the VL flap has become one of our preferred techniques for the repair of wide head and neck defects of various types and in various locations. This flap, which can be harvested as a muscle, musculo-cutaneous or chimeric flap, is particularly suitable for head and neck reconstruction, as it allows for a two-team approach, and can be tailored to the complex three-dimensional structure of this district.

In this paper, we describe our experience and a review of the literature on the use of the free VL flap in the head and neck region, analyzing its indications, advantages and limitations. We also provide technical tips to minimize donor site morbidity.

#### Literature review

A literature review of the studies on the use of VL flaps in the head and neck was performed on the PubMed electronic database using the keywords "vastus lateralis" and "head and neck". The references of selected articles were evaluated to identify any further relevant articles. Thirteen papers were eventually included in this review.

Data on the number of treated patients, defect location, type of flap, recipient vessels and complications were extrapolated from each study (see table 1).

#### Address of the authors

*Plastic and Reconstructive Surgery. Department of Surgical, Oncological and Oral Sciences. University of Palermo, Palermo, Italy.*

**Send correspondence to:** Francesca Toia, [francescatoia@gmail.com](mailto:francescatoia@gmail.com)

**Received:** November 12th, 2014 — **Revised:** December 16th, 2014 — **Accepted:** December 27th 2014

REFERENCE	PATIENTS (n)	TYPE OF FLAP	SITE	RECIPIENT VESSEL	COMPLICATIONS	
					Flaps Complications	Donor Site Complications
Ren et al, 2014	1212	Musculo-cutaneous Osteo- musculo - cutaneous Chimeric flaps	Floor of Mouth Tongue Cheek Oropharynx		Necrosis	Poor Wound Healing Skin Graft Necrosis Muscles Necrosis Haematoma Local Discomfort Mildly Impaired Muscle Function Delayed wound healing Severe Scarring
Yanko-Arzi et al, 2014	1	Musculo-cutaneous	Posterior neck	Superficial thyroid artery/external jugular vein	None	None
Cordova et al, 2014	21	Muscle Chimeric ALT-VL	Tongue Floor of mouth Cheek Retromolar trigone Auriculo-parotid region Mastoid region	Facial vessels Superior thyroid vessels Superficial temporal vessels	Partial Necrosis Infection	
Acarturk et al, 2012	1	Muscle	Anterior palate (recurrent oronasal fistula after cleft repair)	Facial vessels	None	None
Lo et al, 2011	1	Musculo-cutaneous	Anterior skull base	Superficial temporal vessels	None	None
Christiano et al, 2012	1	Muscle	Palate (recurrent oronasal fistula after cleft repair)	Facial vessels	None	None
Nelson et al, 2010	5	Muscle	Orbit Maxillary sinus Skull base Parotid space Retropharyngeal space and infratemporal fossa	Facial artery	None	Small area of numbness
Spyriounis et al, 2008	12	Muscle	Maxilla Mandible Buccal mucosa Forehead Scalp Parotid region		None	None
Sardesai M.G. et al, 2008	9	Muscle	Head/Neck		Partial flap loss	
Tsai et al, 2006	1	Muscle	Maxilla	Facial vessels	None	None
Posch et al, 2005	10	Musculo-cutaneous	Frontoparietal/orbita Mid-face Tongue		Haematoma Arterial occlusion Venous insufficiency (all resolved)	None
Schipper et al, 2005	6	Musculo-cutaneous	Floor of mouth Tongue Parotid region	Facial vessels Superior thyroid vessels	Partial Necrosis	None
Chana et al, 2003	6	Muscle Musculo-cutaneous	Skull base	Superficial temporal vessels	None	None
Demirkan et al, 2000	59	Muscle Musculo-cutaneous	Mandible Cheek Mouth Face	Superior thyroid vessels	Total necrosis Partial necrosis	Wound dehiscence Infection Haematoma
Wolff et al, 1998	60	Muscle Musculo-cutaneous	Forehead Scalp Facial Skin Tongue Floor of mouth Pharynx Tonsillar fossa Perforating defects	Facial vessels	Total Necrosis	None

**Table 1:** Literature review on the use of the free Vastus lateralis flap in the head and neck area.

### *Clinical series*

From 2009 to 2013, we used the VL flap in 36 patients for reconstruction of different head and neck defects located in the scalp (6 patients), in the intraoral cavity (21 patients), in the face (6 patients) and in the mastoid region (3 patients).

Data on the number of patients treated, type of flap, diagnosis, recipient vessels and complications were recorded and grouped for each defect location.

Twenty-four patients were male and 12 were female; mean age was 69 (range: 43-88).

All patients received only a single dose of preoperative prophylactic antibiotic (2). For intraoral reconstruction, the parotid and the submandibular glands were infiltrated preoperatively with botulin toxin, to reduce saliva and prevent complications (3).

### **Results**

#### *Literature review*

A total of 15 studies on the use of the VL flap in the head and neck district were identified (4-18) (table 1). In most cases, the flap was used to reconstruct the tongue and the intraoral cavity, but it was also used for facial and scalp resurfacing, and for reconstruction of deep or perforating defects. The flap was mostly harvested as a musculo-cutaneous flap.

The superficial temporal vessels were frequently used, but the long pedicle of this flap often reaches the facial and superior thyroid vessels, which are safer in selected cases.

Complication rate of the flap was low and comparable to other flaps. Complication rate of the donor site was also low, as was long-term donor site morbidity.

#### *Clinical series*

In 10 cases, the VL flap was used as a muscular flap, in 25 cases as a chimeric flap (VL muscle and ALT cutaneous pad), and in 1 case as a musculocutaneous flap (table 2).

A muscular flap was preferred for scalp reconstruction (100% of cases), while it was used in only 16% of cases for reconstruction of other head and neck defects, mainly facial defects (Figure 1). A chimeric flap was preferred for complex three-dimensional oral cavity or face reconstructions associated with a radical neck dissection with sternocleidomastoid (SCM) resec-

tion. In these cases, the cutaneous ALT pad was used to repair the defect resulting from tumor removal, while the VL was used to reconstruct the SCM muscle and protect the carotid artery from exposure and to prevent blow out syndrome (6). Also, a chimeric flap was preferred following bisphosphonates-related osteonecrosis of the jaw (BRONJ) resection. The ALT pad was used to reconstruct the soft tissue and the VL to fill the bone defect in the jaw. A musculocutaneous flap was used in 1 reconstruction of a wide defect of the auriculo-mastoid region.

The recipient vessel was the facial artery in 15 cases, the superior thyroid artery in 18 cases, the superficial temporal artery in 2 cases and the occipital artery in 1 case. When the flap was used for scalp reconstruction, the temporal vessels were used for anastomosis in 2 cases; the facial artery and the occipital artery were used in 2 cases, while in a further 2 cases a temporary vascular loop between the superior thyroid artery or the facial artery and the thyrolingual trunk was achieved with the great saphenous vein connecting the flap to the neck vessels.

Overall complication rate was 19%. Only 3 patients (8%) required revision surgery. In all but one case, the VL flap was effective in reconstructing the defect. There was 1 total flap necrosis managed with a secondary reconstruction with another VL flap. There was also 1 partial necrosis (skin pad) due to compression of the ALT perforator, which required a secondary reconstruction with a radial forearm flap.

Other complications were: 1 intraoperative thrombosis of the flap pedicle, resolved with thrombolysis (19), 1 infection (treated conservatively), and 3 oro-cutaneous fistulas, 1 of which required surgical correction.

### **Discussion**

The VL flap is very useful in head and neck reconstruction. The possibility of including a skin pad (as a musculocutaneous or a chimeric flap), and eventually a bone fragment from the iliac crest (20), makes this flap particularly appealing for complex head and neck reconstructions. It is indicated for defects of various types and in various locations, and can be tailored to both thin defects (scalp) and deep defects (jaw resection). Complication rate is very

SITE	TYPE OF FLAP			DIAGNOSIS			RECIPIENT VESSEL				VESSEL LOOP	COMPLICATIONS
	Muscle	Chimeric	Musculo-cutaneous	SCC	BRONJ	Other	Facial artery	Superior thyroid artery	Superficial temporal artery	Occipital artery		
Scalp	6	0	0	4	0	2	2	1	2	1	2	1 total flap necrosis
Oral cavity	1	20	0	14	7	0	9	12	0	0	0	1 partial necrosis (skin) 1 intraoperative thrombosis (resolved with thrombolysis) 3 orocutaneous fistulas (1 secondary surgery)
Orbitary region	1	0	0	1	0	0	1	0	0	0	0	0
Cheek	1	4	0	5	0	0	2	3	0	0	0	1 infection (conservative treatment)
Mastoid region	1	1	1	3	0	0	1	2	0	0	0	0
Total	10	25	1	27	7	2	15	18	2	1	2	0

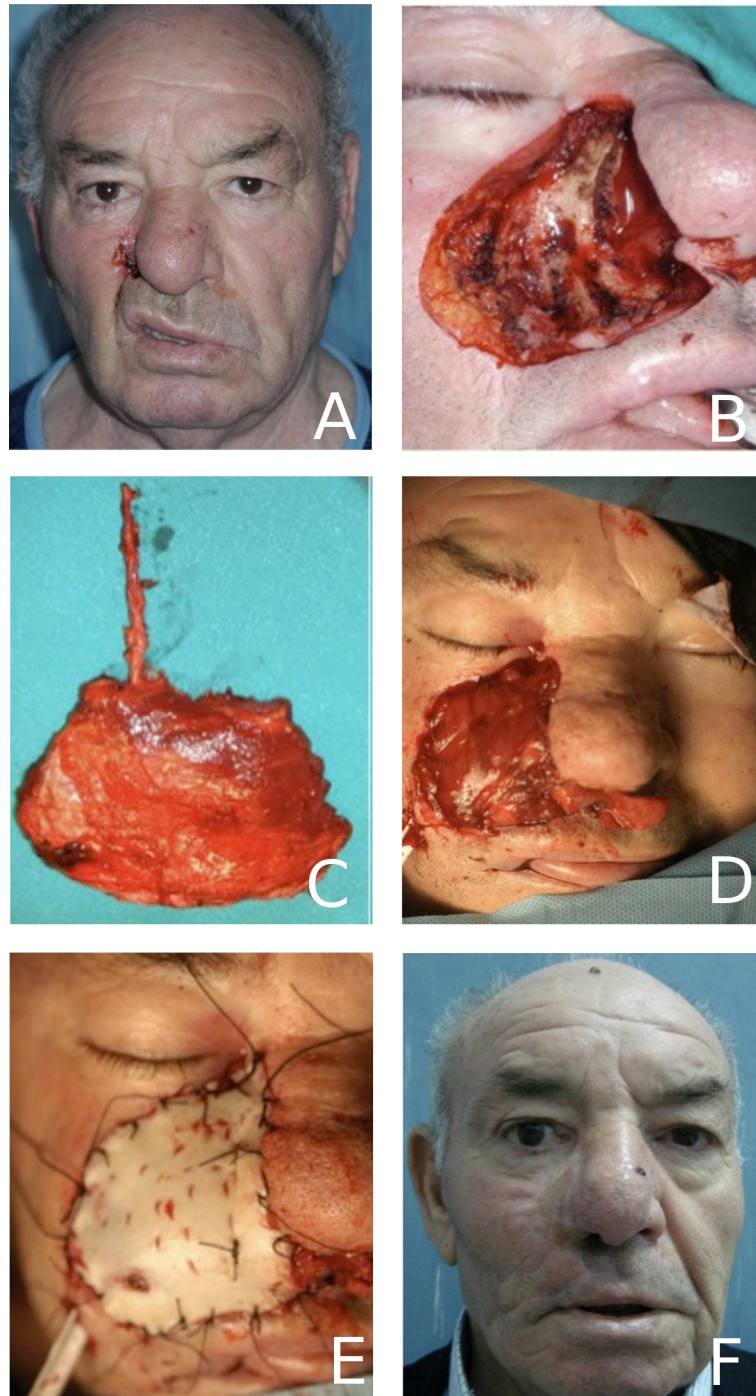
**Table 2:** Data on the type of defect and on the flap used for reconstruction in the different head and neck areas.

low, both at the donor and the recipient site (table 1).

The use of the VL flap has been described with different indications in all parts of the body, both as pedicled or free flap: reconstruction of thorax (21), abdomen (22), pelvis and genitoperineal region (23, 24), reconstruction of lower (25-27) and upper

limbs (28). Its use has also been recommended for controlling infection after resection arthroplasty of the hip (29) or osteomyelitis of the femur (30).

Over the last few years, several authors have pointed out the versatility of the VL flap in head and neck reconstruction (1, 4, 10, 14, 16, 18). However, a review of the



**Figure 1:** Squamous cell carcinoma of the right cheek. Preoperative view (A). The tumor was resected (B). A free Vastus lateralis flap was harvested for reconstruction (C). The flap was inset (D) and skin grafted (E). One-year post-operative view (F).

literature has shown that this flap is still underutilized, which inspired us to discuss the advantages, actual indications, and potential of the VL flap in microsurgical head and neck reconstruction.

*Advantages of the VL flap in head and neck reconstruction*

- It can be easily and rapidly harvested (1, 7, 11, 12, 26, 31);
- It has a consistent anatomy and a very long pedicle, thus there is no requirement for the use of vascular grafts in most cases (1, 10, 11, 16);
- Its source vessel has a large diameter, which simplifies its anastomosis to recipient vessels (11);
- It allows for a two-team approach, which is particularly useful in head and neck surgery (1, 10, 12, 16, 31).
- It can be harvested both as a pure muscular, as a musculocutaneous or chimeric ALT-VL flap. Also, it can include a vascularized bone graft from the iliac crest (4, 13, 20), vascularized fascia lata (16) and a nerve graft if required, while the freedom of the skin paddle makes it a good option for both internal or external lining (16).

Thus, the VL flap can be tailored to different reconstructive defects, ranging from small simple and thin defects, to composite, three dimensionally complex, deep defects (4, 15).

*Actual indications of the VL flap in head and neck reconstruction*

Specific head and neck regions are preferentially reconstructed with a muscular VL flap – such as resurfacing of face or scalp defects – or with a composite ALT-VL flap – as is often the case in intraoral reconstruction. However, in most cases, the choice of a VL or of a composite or chimeric ALT-VL flap depends on the extension and the three-dimensional pattern of the defect. In complex defects, a skin paddle is often used for resurfacing, while the muscle is used for filling dead spaces (4, 26).

The VL has proved its efficacy in a wide range of head and neck reconstructing procedures:

- scalp, face (32) (fig. 1), and posterior neck reconstruction (5)
- intraoral reconstruction (palate (7, 9), tongue (18));
- coverage of exposed bone, (artificial) dura or osteosynthesis material (14, 31);
- dead space obliteration (e.g.: maxillary sinus) (13, 14);

- reconstruction and separation of oral and nasal cavities (13, 14);

- skull base reconstruction and separation of the intracranial cavity from the oronasal space (8, 14, 16).

- reconstruction of the sternocleidomastoid muscle in high-risk head and neck cancers. It can provide adequate and long-lasting soft tissue coverage for the carotid artery after radical neck dissection, thus preventing the carotid blow-out syndrome (6).

Wolff et al (18, 32) particularly recommend use of this flap for extensive or perforating defects and in intraoral reconstruction (especially tongue reconstruction). Our experience is concordant with the literature. Our main indications for reconstruction with a free VL flap are scalp and face resurfacing, as grafted muscle flaps give a better aesthetic outcome in this region (33) (Fig. 1), while our main indication for chimeric ALT-VL flaps is reconstruction of complex or deep defects. Instead, the VL is not the best choice for reconstruction of small and three-dimensional complex structures such as the nose, where other local or free flaps are preferred (34-40). The VL flap is also particularly useful in intraoral reconstruction, especially when a large volume is needed to reconstruct the tongue or fill a deep defect. However, other techniques are indicated when thin resurfacing is needed for the cheek or the oral pelvis (41-43).

*Potential and future perspective of the VL flap in head and neck reconstruction*

- One reason for the limited popularity of the free VL flap is probably the fear of related donor site morbidity. However, even though no study has yet objectively and extensively evaluated donor site loss of strength, many authors suggest that this is not clinically relevant (6, 11, 14, 16, 23, 26, 31, 32). Donor site morbidity can also be minimized by a muscle-sparing harvesting approach (7, 25, 31). We recently described a muscle-sparing harvesting technique based on the segmental anatomy of the muscle, which allows for the raising of very large flaps, but leaves the majority of the VL in place, anatomically and functionally intact.

- The free VL flap can also be transferred as an innervated flap. Although the use of a free innervated VL flap has not been reported yet, it is technically feasible, and a muscle-sparing VL flap can even be har-

vested as an innervated flap (31). Its contraction strength is high, but its fibers' length excursion is limited, which makes this flap less suitable than the Gracilis or the Latissimus dorsi for functional muscle reconstruction. However, its use as an innervated flap may be indicated to maintain a stable flap volume over time.

### Conclusion

The free VL flap is an excellent and versatile option in head and neck reconstruction. It allows reconstruction of large and complex defects, and is particularly suitable for oral and maxillofacial reconstruction.

### References

1. Wolff KD, Grundmann A: The free vastus lateralis flap: an anatomic study with case reports. *Plast Reconstr Surg*. 1992;89(3):469-75; discussion 476-7.
2. Toia F, D'Arpa S, Massenti MF, Amodio E, Pirrello R, Moschella F: Perioperative antibiotic prophylaxis in plastic surgery: a prospective study of 1,100 adult patients. *J Plast Reconstr Aesthet Surg* 2012; 65(5):601-9.
3. Corradino B, Di Lorenzo S, Moschella F: Botulinum toxin A for oral cavity cancer patients: in microsurgical patients BTX injections in major salivary glands temporarily reduce salivary production and the risk of local complications related to saliva stagnation. *Toxins (Basel)* 2012; 4(11):956-61.
4. Ren ZH, Wu HJ, Wang K, Zhang S, Tan HY, Gong ZJ: Anterolateral thigh myocutaneous flaps as the preferred flaps for reconstruction of oral and maxillofacial defects. *J Craniomaxillofac Surg* 2014; May 9. pii: S1010-5182(14)00135-8
5. Yanko-Arzi R, Gur E, Margulis A, Bickels J, Dadia S, Gortzak Y, Zaretski A: The role of free tissue transfer in posterior neck reconstruction. *J Reconstr Microsurg* 2014; 30(5):305-12.
6. Cordova A, D'Arpa S, Di Lorenzo S, Toia F, Campisi G, Moschella F: Prophylactic chimera anterolateral thigh/vastus lateralis flap: preventing complications in high-risk head and neck reconstruction. *J Oral Maxillofac Surg* 2014; 72(5):1013-22.
7. Acartürk TO: Free segmental vastus lateralis muscle flap for reconstruction of recalcitrant defects of the cleft hard palate. *J Reconstr Microsurg* 2012; 28(8):509-14.
8. Lo KC, Jeng CH, Lin HC, Hsieh CH, Chen CL: A free composite de-epithelialized anterolateral thigh and the vastus lateralis muscle flap for the reconstruction of a large defect of the anterior skull base: a case report. *Microsurgery* 2011; 31(7):568-71.
9. Christiano JG, Dorafshar AH, Rodriguez ED, Redett RJ: Repair of recurrent cleft palate with free vastus lateralis muscle flap. *Cleft Palate Craniofac J* 2012; 49(2):245-8.
10. Nelson JA, Serletti JM, Wu LC: The vastus lateralis muscle flap in head and neck reconstruction: an alternative flap for soft tissue defects. *Ann Plast Surg* 2010; 64(1):28-30.
11. Spyriounis PK, Lutz BS: Versatility of the free vastus lateralis muscle flap. *B J Trauma*. 2008 Apr;64(4):1100-5.
12. Sardesai MG, Yoo JH, Franklin JH, Fung K: Vastus lateralis muscle-only free flap: defining its role in head and neck reconstruction. *J Otolaryngol Head Neck Surg* 2008; 37(2):230-4.
13. Tsai CY, Wei FC, Chang YL, Chen YY, Chen CT: Vastus lateralis muscle flap used for reconstruction of the maxilla after radical resection of recurrent ameloblastoma. *Chang Gung Med J*. 2006;29(3):331-5.
14. Posch NA, Mureau MA, Flood SJ, Hofer SO: The combined free partial vastus lateralis with anterolateral thigh perforator flap reconstruction of extensive composite defects. *Br J Plast Surg*. 2005;58(8):1095-103.
15. Schipper J, Boedeker CC, Horch RE, Ridder GJ, Maier W: The free vastus lateralis flap for reconstruction in ablative oncologic head and neck surgery. *Eur J Surg Oncol* 2006; 32(1):103-7.
16. Chana JS, Chen HC, Sharma R, Hao SP, Tsai FC: Use of the free vastus lateralis flap in skull base reconstruction. *Plast Reconstr Surg* 2003; 111(2):568-7.
17. Demirkan F, Chen HC, Wei FC, Chen HH, Jung SG, Hau SP, Liao CT: The versatile anterolateral thigh flap: a musculocutaneous flap in disguise in head and neck reconstruction. *Br J Plast Surg*. 2000;53(1):30-6.
18. Wolff KD: Indications for the vastus lateralis flap in oral and maxillofacial surgery. *Br J Oral Maxillofac Surg* 1998; 36(5):358-64.

19. D'Arpa S, Cordova A, Moschella F: Pharmacological thrombolysis: one more weapon for free-flap salvage. *Microsurgery* 2005; 25(6):477-80.
20. Dorafshar AH, Seitz IA, DeWolfe M, Agarwal JP, Gottlieb LJ: Split lateral iliac crest chimeric flap: utility of the ascending branch of the lateral femoral circumflex vessels. *Plast Reconstr Surg* 2010; 125(2):574-81.
21. Chen HC, Santamaria E, Chen HH, Cheng MH, Chang CJ, Tang YB: Microvascular vastus lateralis muscle flap for chronic empyema associated with a large cavity. *Ann Thorac Surg*. 1999 Mar;67(3):866-9.
22. Iida T, Mihara M, Narushima M, Tokoro T, Hara H, Yoshimatu H, Koshima I, Kadono T: Dynamic reconstruction of full-thickness abdominal wall defects using free innervated vastus lateralis muscle flap combined with free anterolateral thigh flap. *Ann Plast Surg*. 2013;70(3):331-4.
23. Di Summa PG, Tremp M, Meyer Zu Schwabedissen M, Schaefer DJ, Kalbermaten DF, Raffoul W: The Combined Pedicled Anterolateral Thigh and Vastus Lateralis Flap as Filler for Complex Perineal Defects. *Ann Plast Surg*. 2014 May 14. [Epub ahead of print]
24. Wong S, Garvey P, Skibber J, Yu P: Reconstruction of pelvic exenteration defects with anterolateral thigh-vastus lateralis muscle flaps. *Plast Reconstr Surg*. 2009;124(4):1177-85.
25. Cavadas PC, Sanz-Jiménez-Rico JR: Use of the extended-pedicle vastus lateralis free flap for lower extremity reconstruction. *Plast Reconstr Surg*. 2005;115(4):1070-6.
26. Lee JT, Cheng LF, Lin CM, Wang CH, Huang CC, Chien SH: A new technique of transferring island pedicled anterolateral thigh and vastus lateralis myocutaneous flaps for reconstruction of recurrent ischial pressure sores. *J Plast Reconstr Aesthet Surg*. 2007;60(9):1060-6.
27. Auregan JC, Bégué T, Tomeno B, Masquelet AC. Distally-based vastus lateralis muscle flap: a salvage alternative to address complex soft tissue defects around the knee. *Orthop Traumatol Surg Res*. 2010;96(2):180-4.
28. Hashimoto I, Sedo H, Inatsugi K, Nakaniishi H, Arase S: Severe radiation-induced injury after cardiac catheter ablation: a case requiring free anterolateral thigh flap and vastus lateralis muscle flap reconstruction on the upper arm. *J Plast Reconstr Aesthet Surg*. 2008;61(6):704-8.
29. Suda AJ, Heppert V: Vastus lateralis muscle flap for infected hips after resection arthroplasty. *J Bone Joint Surg Br*. 2010;92(12):1654-8.
30. Necmioglu S, Askar I, Lök V, Subasi M: Use of the vastus lateralis muscle flap with a grooving procedure in the surgical treatment of chronic osteomyelitis of the femur. *Ann Plast Surg*. 2004 Dec;53(6):570-6
31. Toia F, D'Arpa S, Brenner E, Melloni C, Moschella F, Cordova A: Segmental anatomy of vastus lateralis: guidelines for muscle-sparing flap harvest. *Plast Reconstr Surg* 2015; 135(1): 185e-198e
32. Wolff KD, Howaldt HP: Three years of experience with the free vastus lateralis flap: an analysis of 30 consecutive reconstructions in maxillofacial surgery. *Ann Plast Surg*. 1995;34(1):35-42.
33. Lutz BS: Beauty of skin-grafted free muscle flaps in head and neck reconstruction. *Microsurgery*. 2006;26(3):177-81.
34. Cordova A, D'Arpa S, Tripoli M, Toia F, Moschella F: A propeller flap for single-stage nose reconstruction in selected patients: supratrochlear artery axial propeller flap. *Facial Plast Surg* 2014;30:332-341.
35. D'Arpa S, Pirrello R, Toia F, Moschella F, Cordova A: Reconstruction of nasal alar defects with freestyle facial artery perforator flaps. *Facial Plast Surg* 2014; 30(3):277-86.
36. D'Arpa S, Toia F, Pirrello R, Moschella F, Cordova A: Propeller flaps: a review of indications, technique, and results. *Biomed Res Int* 2014; 2014:986829. doi: 10.1155/2014/986829. Epub 2014 May 26.
37. Pabla R, Gilhooly M, Visavadia B: Total nasal reconstruction using composite radial forearm free flap and forehead flap as a one-stage procedure with minor revision. *Br J Oral Maxillofac Surg*. 2013;51(7):662-4.
38. Valentini V, Terenzi V, Bartoli D, Battisti A, Aboh IV, Egidi S, Cassoni A: Single-step nasal reconstruction with osteocutaneous forearm flap after total rhinectomy. *J Craniofac Surg*. 2012;23(5):e474-6.
39. Seth R, Revenaugh PC, Scharpf J, Shipchandler TZ, Fritz MA: Free anterolateral thigh fascia lata flap for complex nasal lining defects. *JAMA Facial Plast Surg*. 2013;15(1):21-8.



40. Bank J, Beederman M, Naclerio RM, Gottlieb LJ: Prelaminated fascia lata free flap for large nasal septal defect reconstruction. *J Plast Reconstr Aesthet Surg*. 2014;67(10):1440-3.

41. Cordova A, Toia F, D'Arpa S, Giunta G, Moschella F: A new mucosal propeller flap (DLAAP): the renaissance of lingual flaps. *Plast Reconstr Surg* 2015; March, in press.

42. Shibahara T, Mohammed AF, Katakura A, Nomura T: Long-term results of free radial forearm flap used for oral reconstruction: functional and histological evaluation. *J Oral Maxillofac Surg*. 2006;64(8):1255-60.

43. Sun G, Lu M, Hu Q, Tang E, Yang X, Wang Z: Clinical application of thin anterolateral thigh flap in the reconstruction of intraoral defects. *B Oral Surg Oral Med Oral Pathol Oral Radiol*. 2013;115(2):185-91.