

Surg Radiol Anat (2013) 35:737–740
DOI 10.1007/s00276-013-1091-7

ANATOMIC BASES OF MEDICAL, RADIOLOGICAL AND SURGICAL TECHNIQUES

The little finger ulnar palmar digital artery perforator flap: anatomical basis

Francesca Toia · Marcella Marchese ·
Barbara Boniforti · Pierluigi Tos ·
Luca Delcroix

Received: 15 November 2012 / Accepted: 12 February 2013 / Published online: 27 February 2013
© Springer-Verlag France 2013

Abstract

Purpose The aim of this study was to explore the cutaneous vascularization of the hypothenar region and investigate the anatomical basis for perforator propeller flaps for coverage of the flexor aspect of the little finger.

Methods The area between the pisiform and the base of the little finger was studied in 14 hands of fresh cadavers injected with red latex. An oval flap 1.5 cm large was raised along the axis between these two points. Perforators going into the flap were dissected up to their origin from the ulnar palmar digital artery of the little finger, and their distance from the proximal edge of the A1 pulley was recorded.

Results The mean number of perforator arteries entering the flap was 5.8 (range 4–8). A constant sizeable perforator was identified within 0.7 cm from the proximal margin of the A1 pulley in all 14 specimens. In the majority of cases

(64 %), the most distal perforator was located at this level. Dissection of the flap was carried out suprafascially on the most distal perforator and 180° rotation allowed the flap to reach the flexor surface of the fifth finger. The donor site was closed primarily.

Conclusion Distal perforators of the ulnar palmar digital artery of the little finger are constantly found. Our anatomical findings support the possibility of raising a propeller perforator flap from the hypothenar region for coverage of the flexor aspect of the little finger. Its clinical application could provide a quick and straightforward single-stage option with a negligible donor-site morbidity for reconstruction of such defects.

Keywords Hypothenar flap · Ulnar palmar digital artery · Perforator flap · Little finger

F. Toia (✉)

Chirurgia Plastica e Ricostruttiva, Dipartimento di Discipline Chirurgiche ed Oncologiche, Università degli Studi di Palermo, Via del Vespro, 129, 90127 Palermo, Italy
e-mail: francescatoia@gmail.com

M. Marchese

Presidio Ospedaliero di Tione di Trento Reparto di Ortopedia e Traumatologia Via Ospedale, 11 - 38079 Tione di Trento (TN), Italy

B. Boniforti

Ortopedia e Traumatologia, Ospedale S. Andrea, Vercelli, Italy

P. Tos

UOD Reconstructive Microsurgery, Department of Orthopaedics and Traumatology, CTO-M. Adelaide Hospital, Turin, TO, Italy

L. Delcroix

Reconstructive Microsurgery Unit, Department of Oncology, Azienda Ospedaliera Careggi, CTO, Florence, Italy

Introduction

Soft tissue defects of the palmar aspect of the little finger are relatively frequently encountered in clinical practice as a result of trauma, Dupuytren or scar contracture release. Their coverage is a challenging problem, and local reconstructive options are limited. The cross-finger flap has the disadvantage of being a two-stage procedure, and to carry a significant donor-site morbidity. Reverse flaps from the hypothenar region have been described [7, 10, 11] but require sacrifice of the ulnar palmar digital artery of the little finger. A retrograde neurocutaneous flap of the dorsal branch of the ulnar nerve, as described by Casoli et al. [1], only reach the proximal phalanx of the little finger.

Local perforator flaps have recently gained popularity due to flexibility in their design and low donor-site morbidity.

The rich vascular network of the hand suggests that constant perforator vessels are likely to exist in the hypothenar region, which could supply perforator flaps.

The aim of this study was to explore the cutaneous vascularization of the hypothenar region and investigate the anatomical basis for perforator propeller flaps for coverage of the flexor aspect of the little finger.

Materials and methods

Fourteen amputated hands of fresh adult cadavers (8 males and 6 females) were used. Red latex was injected into the axillary artery. The area between the pisiform and the base of the little finger was studied. An oval flap 1.5 cm large was designed along the axis between these two points. An exploratory incision was made on the medial border of the flap, and the flap was raised ulnarward in the suprafascial plane between the loose areolar tissue of the hypothenar eminence and the fascia overlying the abductor and flexor digiti minimi, superficially to the palmaris brevis muscle. Perforators going into the flap were carefully dissected under loupe magnification and their diameter measured with a mechanical caliber. Perforators larger than 1 mm were dissected up to their source vessels; the distance from their origin to the proximal edge of the A1 pulley was recorded. Smaller perforators were divided. The lateral border of the flap was then incised and dissection of the flap completed, basing it on the most distal perforator, and 180° rotation of the flap was performed to reach the palmar aspect of the little finger.

Results

The mean number of perforator arteries larger than 1 mm (range 1–1.2 mm) entering the flap was 5.8 (range 4–8). Three to six most distal perforators originated from the ulnar palmar digital artery of the little finger, while one to two proximal perforators had an intramuscular or septo-cutaneous course and originated from the ulnar artery or its deep branch (Fig. 1). The distance from their origin to the proximal margin of A1 pulley ranged between 0 and 5 cm. In 9 out of 14 hands (64 %), the most distal perforator arose from the ulnar palmar digital artery of the little finger at the proximal margin of the A1 pulley, while in the remaining 5 specimens (36 %), the most distal perforator was located within 0.7 cm from this point. At least one perforator larger than 1 mm was then present in every specimen within 0.7 cm from the proximal margin of the A1 pulley (Fig. 2), and the mean number of perforator arteries within 1 cm from this point was 1.6 (range 1–2) (Fig. 3). Rotating the flap 180° with the pivot point at the

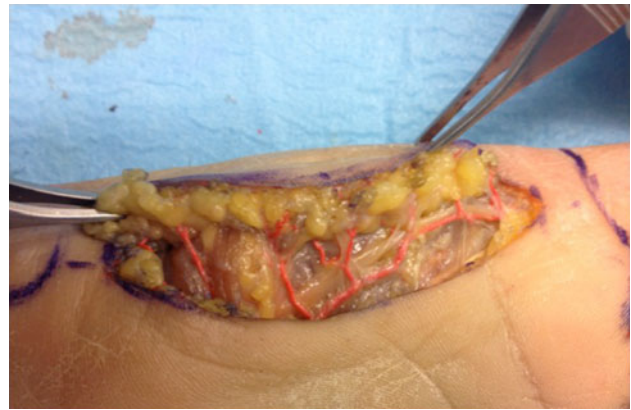


Fig. 1 Dissection view of the flap

origin of the most distal perforator allowed in every case to reach the distal interphalangeal joint, and when the most distal perforator was identified at the proximal margin of the A1 pulley, the flap reached the distal phalanx. The donor site was always closed primarily.

Discussion

The rich vascular network of the hypothenar region has raised the interest of several authors, who explored its potential as donor site for local or free flap for hand defect coverage. An hypothenar fat pad flap for recalcitrant carpal tunnel was described by Plancher et al. [14]. Kinoshita et al. [6] and Kojima et al. [7], respectively, provided anatomical studies and clinical series for a subcutaneous pedicle flap and a reverse vascular pedicle hypothenar island flap. Omokawa et al. [11, 12] identified the constant vascular supply of the distal half of the ulnar aspect of the hypothenar eminence from the ulnar palmar digital artery

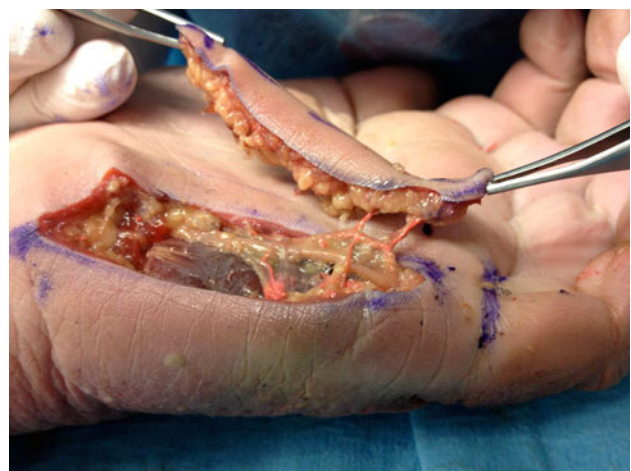

Fig. 2 Distal perforator of the ulnar palmar digital arteries

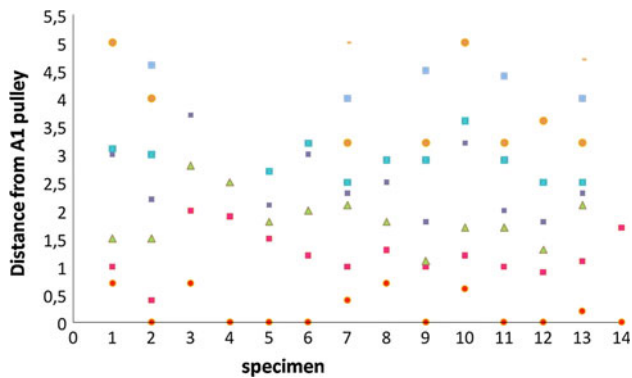


Fig. 3 Distance of perforator arteries from the proximal margin of the A1 pulley (specimen 1–14)

of the little finger, and reported favourable results on 11 patients with soft tissue defect of the palmar aspect of the little finger by a reverse ulnar hypothenar flap. The anatomical basis and clinical applicability of the reverse flap described by Kojima et al. and Omokawa et al. were confirmed in a study by Novelino et al. [10]. Reverse flaps, however, require sacrifice of the ulnar palmar digital artery of the little finger.

In recent years, local perforator flaps have become popular, allowing a greater freedom in flap design while minimizing donor-site morbidity. The possibility of raising perforator flaps from the hypothenar eminence has been addressed by several authors in anatomical studies and small clinical series [5–7, 10–12, 14–16].

Hwuang et al. [5] investigated the anatomical basis for a perforator flap from the proximal part of the hypothenar eminence, and described a constant cutaneous perforator of the ulnar artery, situated 2 ± 0.7 cm from the pisiform.

Uchida et al. [16] introduced the distal base ulnar palmar digital artery perforator flap. In their anatomical study on 10 hands, they investigated the perforators at the level of the distal palmar crease. They noted that perforators were often seen near the metacarpophalangeal joint (MCP) of the fifth finger, which was chosen as landmark, and at least one perforator was found within 9 mm from the MCP joint.

In our study, the proximal edge of the A1 flexor pulley was chosen as anatomical landmark, to allow for a more precise measurement and a better anatomical description. Inclusion of the distal palmar crease in the raised flap hindered use of this skin landmark; furthermore, surface landmarks studied on cadavers require clinical proof of efficiency [4]. The proximal margin of the A1 pulley was considered an accurate landmark, whose relationship with skin surface has been extensively investigated. Wilhelm et al. [17] and Fiorini et al. [4] demonstrated that the distance between the digital palmar and proximal interphalangeal crease corresponds to the distance of the proximal edge of the A1 flexor pulley from the palmar digital crease

in the fingers. Of note, the proximal margin of the A1 pulley has been reported to be a few millimeters distal to the distal palmar crease [9].

Uchida et al. [16] also report a single case of Dupuytren contracture of the fifth finger, in which a distally based flap from the ulnar aspect of the distal palm was transposed to the palm after contracture release. The flap was based on perforators, but raised on a subcutaneous pedicle.

Panseet and Sahasrabudhe [14] recently published a preliminary report on the “ulnar digital artery perforator flap” on four cadaver limbs and three patients. A flap based on a single distal perforator of the ulnar palmar digital artery of the little finger was raised and rotated 180° to cover defects of the flexor surface of the little finger. Three to four perforators supplying the flap were identified from the underlying digital artery; in their small clinical series, they found a perforator 3–5 mm distal to the distal palmar crease. Perforators near the MCP joint, distal to the distal palmar crease, had a larger caliber on visual inspection, although diameter has not been recorded.

Our study provides further insight into the anatomical basis of such perforator flaps, and confirms the constant and reliable vascular supply from the ulnar palmar digital artery of the little finger. However, we moved the flap radially on the hypothenar region, without impairing the vascular supply, to avoid scars on the ulnar border of the hand, which represents a contact area.

A constant sizeable perforator was identified within 0.7 cm from the proximal margin of the A1 pulley in all 14 specimens. Of note, in the majority of cases (64 %) the most distal perforator was located at this level (Fig. 3).

Perforators from the ulnar palmar digital artery of the little finger have been reported to supply the distal half of the hypothenar eminence [12], and concerns on pedicle reliability could be raised due to the eccentric position of the perforator supplying the flap.

Traditional width-to-length ratio for fasciocutaneous flaps are not directly applicable to perforator flaps, which are not random flaps and show a completely different setting [3].

Perforators larger than 0.5 mm are generally believed to adequately supply a perforator flap. In an anatomical study by Morris et al. [8], the authors dissected perforators supplying the skin and defined 61 vascular territories based on perforators greater than 0.5 mm in diameter. In the extensive experience of Ono et al. [13] in perforator surgery, a diameter greater than 1 mm can supply flaps extending beyond the borderline of the original territory off of which the perforator branches. Due to the eccentric position of the perforator in the flap described, only perforators larger than 1 mm were analyzed, which are likely to guarantee a reliable vascular inflow to the flap. In our opinion, the constancy of perforators of such a large caliber is of great

clinical importance; this anatomical findings support the possibility to base the flap on a perforator rather than a subcutaneous pedicle, and safely extend freedom of movement and indications of the flap described by Uchida et al., who do not report on the caliber of the perforators, to reach more distal defects of the palmar surface of the little finger.

Furthermore, very large free perforator flaps as DIEP and ALT flaps can be harvested on a single perforator and are routinely used in clinical practice, and the same principle can be applied to much smaller pedicled perforator flap. According to D'Arpa et al. [2], the possibility of achieving donor-site closure should be the main concern about pedicled perforator flaps dimension, rather than concerns about flap perfusion.

Our anatomical findings support the possibility of raising a propeller perforator flap from the hypothenar region based on distal perforators of the ulnar palmar digital artery of the little finger. Its clinical application could allow coverage of the flexor aspect of the little finger with a thin and pliable coverage and a good colour and texture matching, at the expense of a negligible donor-site morbidity. Future clinical application is desirable and could provide a quick and straightforward single-stage option for reconstruction of such defects.

Unfortunately, this cadaveric study did not evaluate the venous supply to the flap. It is advisable that future clinical studies will investigate the constancy and caliber of venous perforators, to verify the reliability of venous drainage, allow skeletization of the pedicle and improve freedom and safety of the flap. Based on available anatomical data, we advice to verify the numbers and caliber of venous perforators through the exploratory incision, and leave a cuff of adipose tissue around the pedicle in case they are not judged adequate, to ensure venous outflow.

Conflict of interest The authors declare that they have no conflict of interest.

Ethical standard The experiments comply with the current laws of the country in which they were performed.

References

1. Casoli V, Vérolino P, Pélissier P, Kostopoulos E, Caix P, Delmas V, Martin D, Baudet J (2004) The retrograde neurocutaneous

- island flap of the dorsal branch of the ulnar nerve: anatomical basis and clinical application. *Surg Radiol Anat* 26(1):8–13
2. D'Arpa S, Cordova A, Pignatti M, Moschella F (2011) Freestyle pedicled perforator flaps: safety, prevention of complications, and management based on 85 consecutive cases. *Plast Reconstr Surg* 128(4):892–906. doi:10.1097/PRS.0b013e3182268c83
3. D'Arpa S, Pignatti M, Cordova A, Moschella F (2012) Reply: how large can a pedicled perforator flap be? *Plast Reconstr Surg* 130(1):196e–198e. doi:10.1097/PRS.0b013e318254fc0e
4. Fiorini HJ, Santos JB, Hirakawa CK, Sato ES, Faloppa F, Albertoni WM (2011) Anatomical study of the A1 pulley: length and location by means of cutaneous landmarks on the palmar surface. *J Hand Surg Am* 36(3):464–468. doi:10.1016/j.jhsa.2010.11.045
5. Hwang K, Han JY, Chung IH (2005) Hypothenar flap based on a cutaneous perforator branch of the ulnar artery: an anatomic study. *J Reconstr Microsurg* 21(5):297–301
6. Kinoshita Y, Kojima T, Hirase Y, Kim H, Endo T (1991) Subcutaneous pedicle hypothenar island flap. *Ann Plast Surg* 27(6):519–526
7. Kojima T, Endo T, Fukumoto K (1990) Reverse vascular pedicle hypothenar island flap. *Handchir Mikrochir Plast Chir* 22(3):137–144
8. Morris SF, Miller BJ, Taylor GI (2006) Vascular anatomy of the integument. In: Blondeel PN, Morris SF, Hallock GG, Neligan PC (eds) *Perforators flaps anatomy, technique and clinical applications*, vol I. Quality Medical Publishing Inc., St. Louis, pp 11–36
9. Nagoshi M, Hashizume H, Nishida K, Takagoshi H, Pu J, Inoue H (1997) Percutaneous release for trigger finger in idiopathic and hemodialysis patients. *Acta Med Okayama* 51:155–158
10. Novelino F, Goncalves J, de l'Aulnoit SH, Schoofs M (2002) The fasciocutaneous hypothenar flap: preliminary anatomical and clinical study. *Ann Chir Plast Esthet* 47(1):9–11
11. Omokawa S, Yajima H, Inada Y, Fukui A, Tamai S (2010) A reverse ulnar hypothenar flap for finger reconstruction. *Plast Reconstr Surg* 106(4):828–833
12. Omokawa S, Ryu J, Tang JB, Han JS (1996) Anatomical basis for a fasciocutaneous flap from the hypothenar eminence of the hand. *Br J Plast Surg* 49(8):559–563
13. Ono S, Ogawa R, Hayashi H, Takami Y, Hyakusoku H (2012) How large can a pedicled perforator flap be? *Plast Reconstr Surg* 130(1):195e–196e. doi:10.1097/PRS.0b013e318254fc0e
14. Panse N, Sahasrabudhe P (2010) The ulnar digital artery perforator flap: a new flap for little finger reconstruction—a preliminary report. *Indian J Plast Surg* 43(2):190–194. doi:10.4103/0970-0358.73445
15. Plancher KD, Idler RS, Lourie GM, Strickland JW (1996) Recalcitrant carpal tunnel. The hypothenar fat pad flap. *Hand Clin* 12(2):337–349
16. Uchida R, Matsumura H, Imai R, Tanaka K, Watanabe K (2009) Anatomical study of the perforators from the ulnar palmar digital artery of the little finger and clinical uses of digital artery perforator flaps. *Scand J Plast Reconstr Surg Hand Surg* 43(2):90–93. doi:10.1080/02844310802556976
17. Wilhelmi BJ, Snyder N, Verbese JE, Ganchi PA, Lee WPA (2001) Trigger finger release with hand surface landmark ratios: an anatomic and clinical study. *Plast Reconstr Surg* 108:908–915