

Bisphosphonates and osteonecrosis of the jaw: pathogenetic hypothesis and new preventive measures.

1. Abstract

BRONJ is a serious oral complication of BP treatment involving the exposure of necrotic maxillary or mandibular bone. We investigated the pathogenetic hypothesis and new preventive measures for BRONJ in patients with bone metastases who received BP zoledronic acid (ZOL) and chemotherapy combined with the antiangiogenic agent bevacizumab (BEV).

The pathogenesis of BRONJ is uncertain: the type of BP, duration of the drug use and the occurrence of tooth extractions or other invasive dental procedures during treatment seem to play a major role. A theory that BRONJ is a form of avascular necrosis similar to osteoradio-necrosis also has been proposed. It maybe hypothesized that the combination of the antiangiogenic agent BEV with ZOL can lead to the enhancement of bone tissue avascularization (reduction of vascularization), which can account for a potentially higher incidence of ONJ in patients with bone metastases [to the bone] who receive this type of treatment. In order to better understand the problem we followed up a total of 121 patients for a period of 3 years.

Methods: Patients were divided into 2 groups: group PA (preventive approach, 78 patients) and group OB (observation, 63 patients). Group PA patients had never been previously treated with BP, and group OB patients had already undergone therapy with BP. All patients received a complete oral and dental examination and a panoramic radiograph. If necessary, oral hygiene, restorative and rehabilitation therapy were offered to patients. All patients participated in regular checkups every 3 months. Group PA patients underwent oral surgical procedures, as needed. Group OB patients underwent less invasive procedures (restorative treatment) or root canal and surgical procedures, as needed.

Results: In group OB is interesting to note that the 16 patients with root canal treatment have not developed BRONJ, suggesting that a mini invasive procedure is highly recommended for patients who have already started ZOL + BEV, while 14% of patients, who underwent oral surgical procedures, presented with BRONJ during the 18 month follow up period. No patients in group PA had ONJ.

Conclusion: Current evidence suggests that root canal therapy in cancer patients is a safe procedure and may reduce the incidence of ONJ.

2. Introduction

Bisphosphonates (also called diphosphonates) are a class of drugs that prevent the loss of bone mass. They are called bisphosphonates because they have two phosphonate (PO_3) groups and are similar in structure to pyrophosphate. Bisphosphonates are the main drugs used for skeletal health preservation and treatment of osteoporosis, osteitis deformans ("Paget's disease of bone"), bone metastasis (with or without hypercalcaemia), multiple myeloma, primary hyperparathyroidism, osteogenesis imperfecta, and other conditions that feature bone fragility(1).

This class of drug has been classified into 2 groups, non-nitrogen-containing bisphosphonates (etidronate and clodronate) and nitrogen-containing bisphosphonates (pamidronate, risedronate, alendronate, and zoledronate)(2). In oncology, nitrogen-containing bisphosphonates have been used widely to manage hypercalcemia related to malignancy and bone metastases (3,4,5).

Bisphosphonates were originally synthesized in 1865 their Germany (6), and due to their ability to inhibit calcium carbonate precipitation, first use was in the textile, fertilizer and oil industries as preventers of scaling (7).

Etidronate, the first bisphosphonate used to treat a human disease (8), was synthesized 100 yr ago. Their ability to inhibit calcium carbonate precipitation, similar to polyphosphates, was used in the prevention of scaling . Only in the past three decades bisphosphonates have been developed as drugs for use in various diseases of bone, tooth, and calcium metabolism.

Mechanisms of Action of BF

Many studies using a variety of experimental systems showed that bisphosphonates inhibit osteoclast-mediated bone resorption, not only in "in vitro" bone-cells cultures, but also in "in vivo" animals, both in normal ones and in those with experimentally increased bone resorption (9).

cellular effects

Bisphosphonates are recognized as inhibiting osteoclastic activity by four main processes:

- 1) Induction of osteoclastic apoptosis,
- 2) inhibition of osteoclastic resorption of bone,
- 3) inhibition of osteoclastic maturation,
- 4) inhibition of osteoclastic recruitment.

Apart from these effects on osteoclasts, bisphosphonates have also been shown to have effects on angiogenesis epithelial cells growth .

Angiogenesis plays a fundamental role in normal physiologic processes, such as organogenesis during embryonic development, tissue remodeling/maintenance healing throughout life, and reproductive functions(10,11). Compensatory angiogenesis is also required in the formation of collateral blood vessels in the setting of hypoxia and nutrient deprivation (11,12). Angiogenesis is essential in neoplasia and the vascular endothelial growth factor (VEGF) is produced and secreted by a number of neoplastic cells. In effect, the initiating event in the angiogenetic process is the release of proangiogenic growth factors, such as VEGF, fibroblast growth factor (FGF) or platelet-derived growth factor (PDGF) from diseased or injured cells (14,15) There are a variety of stimuli mediating the release of these growth factors – hypoxia, hypoglycemia, mechanical stress, secreted proteins in the microenvironment, inflammatory factors and genetic alterations.

Endothelial cell proliferation, adhesion and migration are inhibited by zoledronic acid *in vitro* (16). Both nitrogen and non-nitrogen containing bisphosphonates have been demonstrated to inhibit revascularization of tissue *in vivo* and angiogenesis (17,18)

Pamidronate has even been demonstrated to have a direct apoptotic effect on certain myeloma cell lines (19).

Clinical applications of BF

Bisphosphonate medications are currently prescribed for the treatment of osteoporosis, Paget's disease, bone metastases .Bisphosphonates are also effective in reducing the risk of skeletal-related events in persons with metastatic breast, lung, and prostate cancer as well as multiple myeloma – affecting a range of complications that include malignant severe hypercalcaemic episodes, new bone metastases, diffuse bone pain and pathologic fracture (20). They have also found off-label use in a number of bone-affecting diseases such as osteogenesis imperfecta (21,22).

The Epidemiology of BRONJ

The precise epidemiological features of BRONJ have not been determined.

In the general population amongst patients not receiving bisphosphonates as a treatment for cancer, Felsenberg reported an incidence of 0.00038% (23).

The American Society for Bone and Mineral Research taskforce in 2007 estimated the incidence, based on publications and pharmaceutical company reports, to be between 1 and 10% of patients taking intravenous bisphosphonates for the treatment of cancer and less than 1% in patients with osteoporosis or Paget's disease (24).

Current incidence data for BRONJ are limited to retrospective studies with limited sample sizes. The current difficulty in establishing exact incidence data stems from several factors, including a nonstandardized definition and inconsistencies in case recognition and reporting. With that understanding, the estimate of cumulative incidence of BRONJ in patients receiving intravenous bisphosphonates for malignant disease ranges from 0.8% to 12% (25) For those patients exposed to oral bisphosphonates, the incidence appears to be significantly less (25).

Risk factors

Several retrospective clinical studies have identified potential risk factors associated with the development of BRONJ. (26,27) These include a history of dentoalveolar trauma, duration of bisphosphonate exposure, and the type of bisphosphonate. In the majority of BRONJ cases reported to date, recent dentoalveolar trauma was the most prevalent and consistent risk factor. (26,28,29) Patients with a history of inflammatory dental disease (e.g., periodontal and dental abscesses) are at a sevenfold increased risk for developing BRONJ. (30) In a case series, the use of chronic steroids in conjunction with bisphosphonates has also been identified as a potential risk factor. (25)

Patients receiving oral bisphosphonate therapy for osteoporosis that develop BRONJ have typically been exposed to these agents for a longer period of time (greater than 3 years) or were also exposed to steroid therapy. (25,31)

Aetio-pathogenesis of BRONJ

The precise aetiological mechanism behind the development of bisphosphonate-related osteonecrosis has not been determined. Epidemiological correlations have been observed, however, and a number of theories have been proposed.

- Bisphosphonate Potency

To date, the most important predisposing factors identified for the development of bisphosphonate-associated osteonecrosis of the jaws are the type and total dose of bisphosphonate and the history of trauma, dental surgery or dental infection (27). BRONJ has been associated most often with the nitrogen containing bisphosphonates, specifically pamidronate and zoledronate (5,32,33). It is not currently understood by what specific mechanism nitrogen containing bisphosphonates induce a higher risk of BRONJ development than their non-nitrogen containing counterparts. The increased potency of nitrogen containing bisphosphonates over non-nitrogen containing bisphosphonates is, however, well recognized (34). Patients receiving bisphosphonates intravenously have been demonstrated to be more susceptible to BRONJ than those receiving the drug orally (35).

- Bisphosphonate Inhibition of Bone Remodeling

The prevailing hypothesis focuses on a drug-induced defect in jawbone physiologic remodeling or wound healing. The profound inhibition of osteoclast function inhibits normal bone turnover to an extent that local micro damage from normal mechanical loading or injury (tooth extraction) cannot be repaired. (36) This can ultimately result in bone necrosis. The recent reports of jaw necrosis in patients receiving Denosumab, a monoclonal antibody that targets osteoclasts by a completely different mechanism than bisphosphonates, supports the hypothesis osteoclast inhibition might be the primary event in the pathogenesis of this complication. (37,38)

- Direct Tissue Toxicity

Other studies have focused on the soft tissue response and demonstrated that bisphosphonates can be directly toxic to the oral mucosa, which may result in mucosal fenestration and bone exposure (39). It is possible bisphosphonates are accumulated in bone in concentrations sufficient to be directly toxic to the oral epithelium, resulting in the failure of healing of soft tissue lesions (40). Bisphosphonates at a high enough concentration have a demonstrable toxic effect, both in animal models (41) and in *in vivo* studies (42).

Because only a minority of bisphosphonate users develop bone necrosis, it is also possible that individual genetic variations in drug metabolism or skeletal homeostasis may confer susceptibility or resistance to developing BRONJ (43). These theories and suppositions need to be validated by evidence-based clinical and basic science research.

- Influence of Medical Co-Morbidities

The impact of local factors such as smoking, and of underlying medical conditions such as peripheral vascular diseases remains to be determined. There is some evidence and a theoretical justification for a correlation between diabetes mellitus and BRONJ (44), however more research is required in this area.

- Influence of Anatomy

The apparent selective involvement of the maxilla and mandible may be a reflection of the unique environment of the oral cavity. Typically, healing of an open bone wound (e.g., extraction socket) in the presence of normal oral microflora occurs quickly and without complication. However, when the healing potential of the mandible or maxilla is compromised either by tumoricidal radiation doses or some other agent(s) or pathologic process, then minor injury or disease in these sites increases the risk for osteonecrosis and possible secondary osteomyelitis. Also, bisphosphonates are preferentially deposited in bones with high turnover rates; given that the maxilla and mandible are sites of significant bone remodeling, it is possible that the levels of bisphosphonate within the jaw are selectively elevated. It is interesting to note that to date this complication of bisphosphonate-related bone necrosis has not been reported within bones outside the craniofacial skeleton.(31)

- Genetic Predisposition to BRONJ

A genetic predisposition to developing BRONJ has been suggested. The rs1934951 polymorphism mapped within cytochrome P450-2C polypeptide 8 gene may be associated with increased risk for the development of BRONJ in myeloma patients who receive intravenous bisphosphonates (43).

Staging of BRONJ

Staging of a disease allows for grouping of similar patients to compare outcomes and results of treatments, and the same holds true for BRONJ where several different staging systems have been proposed, but the simple clinically-based staging system proposed by Ruggiero et al has been the most widely accepted and used in most publications and guidelines on BRONJ(45) This was revised in the AAOMS position paper in 2009 (Table 2)(25).

Table 2 Staging of Bisphosphonate Related Osteonecrosis of the Jaws. Based on recommendations of the American Association of Oral & Maxillofacial Surgeons

Stage	Clinical features
Stage 0	No apparent exposed/necrotic bone (but who present with signs and/or symptoms suggestive of future disease)
Stage 1	Exposed/Necrotic bone in asymptomatic patient with no evidence on infection
Stage 2	Exposed/Necrotic bone associated with localised infection
Stage 3	Exposed/Necrotic bone associated with pathological fracture, extra-oral fistula or extension in to surrounding basal bone

Management of BRONJ

The aims of treating patients with BRONJ are to eliminate clinical symptoms such as pain, treat any infection of the soft tissues or bone, and minimise the progression of bone necrosis.(88) Clinical markers of success include an intact mucosa with no signs of infection or sinus formation and radiographic markers include the arrest of progression of the bony abnormality or remodelling of the affected area.(46)

Surgical management

The goal of surgical treatment is to remove necrotic bone and create soft tissue coverage of remaining healthy bone. The difficulty with this approach is knowing how much bone removal is sufficient because as BP are administered systemically and affect the whole bony skeleton, there is effectively no unaffected bone.(47,48,49)

The most commonly recommended approach is to remove symptomatic bony sequestra with minimal soft tissue disturbance and avoiding further bone exposure, although some authors advocate more extensive soft and hard tissue debridement and primary closure of the wound.(47,50)

More radical surgical management is advocated where there are large segments of necrotic bone or where there is pathological fracture of the bone (AAOMS stage 3).(47,25)

En bloc resection of alveolar and basal bone of the maxilla and mandible can then be reconstructed with a combination of local or regional flaps or vascularised or non-vascularised free flaps. In the maxilla an oral-nasal or oral-antral communication may be managed with an obturator.(25,51,52)

Non-surgical management

The use of antiseptic mouthwashes (chlorhexidine gluconate or hydrogen peroxide) and/or analgesia is proposed for patients with clinical evidence of BRONJ (such as exposed bone) but in the absence of any evidence of infection (AAOMS Stage 1).(47,25) It is essentially a strategy to reduce the likelihood of further progression of BONJ and avoid infection of exposed bone.(28)

Where there is evidence of local inflammation or infection, antibiotics are advised.(47,53) Broad spectrum antimicrobial therapy (phenoxymethylpenicillin, amoxicillin or coamoxiclav or clindamycin _ metronidazole) is recommended although the correct duration of treatment is not clear.(47,53,54) This approach is indicated for patients generally categorised as stage 2 BRONJ, but it may also be the preferred approach in patients with BRONJ and cancer with very poor prognosis in whom more extensive treatment is not indicated.(47,25,54)

Adjunctive therapies

They include hyperbaric oxygen (HBO), parathyroid hormone, platelet rich plasma, lasers and local application of O₃. With the exception of HBO, the literature consists primarily of small case series and further studies need to be undertaken before any are considered for routine use.(25)

HBO had very limited effects (32,28). Later studies did seem to indicate a beneficial effect of HBO as supportive therapy (55,56).

New and original therapeutic approach for the clinical management of small necrotic maxillary lesions in ONJ was based on a non-surgical intervention for the application of O₃. This approach consisted of in situ positioned O₃ oil suspension to increase the therapeutic effect of O₃ and to reduce the risk of infection or inspiration in the oral cavity. Consequently, this approach showed a good safety profile. Antimicrobial treatment before starting the O₃ oil applications plays a critical role in reducing the severity of inflammation and infection The results demonstrate that medical O₃ delivered in an oil suspension should be considered a promising, effective, safe and simple therapeutic option for the treatment of small ONJ lesions(57)

CLINICAL STUDY

3. Aims

The aim of the present study was to evaluate the effectiveness of preventive strategies in 121 patients who underwent therapy with BPs at the department of dentistry in Siena Hospital

The results were hoped to aid in gauging the scope of the impact that bisphosphonates may potentially have on the delivery of dental care to the general community

4. Materials and Methods

Patients were referred from the Department of Oncology to the Department of Dentistry, from January 2008 to July 2010, to undergo dental evaluation and receive necessary treatment before initiating therapy with zoledronate.

Eligibility criteria

The study involved patients with measurable or evaluable histologically confirmed solid tumors that received BP and bevacizumab combined with chemotherapy, not previously included in a preventive dental program (basal dental examination, OPT and preventive dental care), age 18-75 years, ECOG P.S. of 0-2, bidimensionally measurable disease, a life expectancy of at least 3 months, an absolute neutrophil count of $\geq 1.5 \times 10^9 \text{ l}^{-1}$ and platelet count of $\geq 100 \times 10^9 \text{ l}^{-1}$ and creatinine and total bilirubin levels ≤ 1.25 times the upper normal limit. All patients should have received iv BP and bevacizumab for at least 3 months. The main baseline characteristics of all participants who received zoledronic acid every three months for almost one year or more are listed in Table 1. The exclusion criteria were operable metastatic disease, severe cardiac dysfunction, chronic diarrhoea or uncontrolled infection. The study was approved by our local ethic and scientific committee.

Table 1

Characteristics	Patients (N°)	Patients who received zoledronic acid every 28 days for almost one year (N°)	Patients who received zoledronic acid every 28 days for more than one time per year (N°)
Total	121	55	66
Median Age (years-range)	60 (45-72)		
N° of Bone Lesions			
>3	74	36	38
< 3	47	19	28
Sex			
Male	64	35	29
Female	57	27	30
Primary Cancer			
Breast	41		
Non small cell lung	60		
Prostate	20		
Received BEV more than six months	92	43	49

Patients evaluation

All patients in the study provided written informed consent before the interview and visit. Information about their demographic characteristics, smoking habits, lifetime alcohol consumption and health history was collected.

The evaluation, performed before study entry, included a detailed history and physical examination, a complete blood cell count with differential and platelet counts, whole-blood chemistry, and computed tomography (CT) scans and/or magnetic resonance imaging (MRI) of the chest and abdomen. During treatment, a complete blood cell count with differential and platelet counts was performed every 2 weeks. In addition, the patients were clinically assessed every 2 weeks, and routine biochemical tests were performed. Imaging studies were performed prior to starting study and every

6 months after the initiation of treatment or earlier when there was clinical deterioration, and response was evaluated according to RECIST criteria (version 2.0) (58).

We evaluated a total of 121 patients that started BP and bevacizumab, and were examined by our Dental Care Unit at the first clinical visit at Oncology Department. For each patient, a dental examination and a Panoramic Radiographs were obtained at the first clinical visit and a dental examination was performed every month until patients, died or lost to follow-up. The criteria we used to diagnose BRONJ included an exposed necrotic bone in the mandible or maxilla (associated or not associated with pain, soft-tissue swelling or purulent discharge)

Patients were divided into 2 groups according to their BP history: group PA (preventive approach) or group OB (observation). Patients in group PA had never been previously treated with BP, whereas patients in group OB had already undergone therapy with BP. Patients in group PA received a clinical oral examination with visual inspection and palpation of the neck node regions, inspection of the oral and pharyngeal mucosa, periodontal examination and caries assessment. Finally, a panoramic radiograph was done to identify any radiographic anomalies.

On the same day, patients were informed about the possible risk of BRONJ. Dental risks factors (59) were identified: presence of dental plaque and calculus; caries; dental infection, including periapical lesions and periodontal disease; periodontally compromised teeth (pocket depth \geq 5 mm, clinical attachment level $>$ 50%, mobility II and III, furcation); or poorly fitting dentures.(25) In the following days, all patients were treated to remove dental risk factors. Professional oral hygiene was done on the second visit; restorative and surgical procedures were done in the following visits. Oral surgery was aimed to prevent or treat bone infections; patients were advised about the risks of the surgical treatment. Finally, patients' teeth were rehabilitated and oral hygiene instructions were given.

Patients in group OB visited the dental clinic and had a panoramic radiograph. Dental risk factors were identified and patients were informed of the possible risk of BRONJ. If necessary, dental hygiene with antibiotic therapy, rehabilitation therapy, restorative and root canal treatment or dental extraction were offered to patients.

Patients in both groups participated in regular checkups every 3 months, during which oral hygiene instructions were given again and patients were motivated to maintain good oral hygiene.

Patients were instructed to report any swelling, pain or exposed bone. Overall, patients were followed for more than 18 months.

5. Results

A total of 121 patients with bone metastases from different solid tumours were examined. The median age was 60 (range 45-72) years, 55 received zoledronic acid every 28 days for almost one year and 66 received zoledronic acid every 28 days for more than one time per year, the primitive tumor was a breast cancer for 51 patients and 70 for NSCLC. 92 patients received BEV for more of six months (43 of those received zoledronic acid every 28 days for almost one year and 49 zoledronic acid every 28 days for more than one time per year); 47 patients presented less of three bone lesions (19 received zoledronic acid every 28 days for almost one year and 28 received zoledronic acid every 28 days for more than one time per year). The median time the patients received zoledronic acid therapy was 16.7 months (range 4.1-24.3 months); 77 patients had received zoledronic acid for more than one year. The median time participants received BEV was 13.4 months (range 3.8-26.6 months).

Table 2. depicts dental risk factors for ONJ and associated comorbidities in our study population: 88 patients presented diabetes mellitus, 6 patients presented rheumatoid arthritis, 51 patients presented osteoarthritis and 20 patients presented osteoporosis.

Table 2. Putative dental risk factors for ONJ and associated comorbidities in the population study

Risk factor	All patients (No)
Total	121
Dental caries	30
Periodontal disease	21
Gingivitis	60
Chronic periodontitis	27
Poorly fitting dentures	16
Oral hygiene	
Excellent	0
Good	22
Fair	30

Poor	69
Comorbidities	
Diabetes mellitus	88
Rheumatoid arthritis	6
Osteoarthritis	51
Osteoporosis	20

A total of 121 patients (57 women, 64 men) were included in this analysis (PA: n = 78; OB: n = 63).

108 underwent maneuvers of oral health (included Dental hygiene) , 13 patients carried total (upper and lower) mobile denture, 64 partial denture. Most subjects had poor oral health, with widespread periodontal disease, gingival inflammation, bacterial plaque and in some cases, decayed teeth and halitosis with deep pain radiated to the surroundings to the lesion. For this, it was necessary to performe invasive procedures: dental hygiene, scaling and root-planning, tooth extraction and root canal treatment after antibiotic therapy .

None of the patients in group PA developed BRONJ in the following 18 months. Dental extractions were done for 26 of these patients, 72 dental hygiene, 23 scaling and root planing and 8 root canal treatment.

In group OB 36 patients had dental cure: via random selection 16 patients underwent tooth extraction and 16 underwent to root canal treatment, with rubber dam and fang; in elements with chronic periodontal disease, after root canal treatment, was made de-crowning of the specific element with less discomfort to the patient.

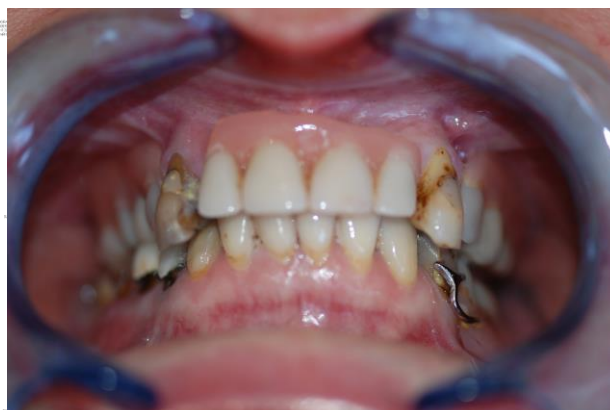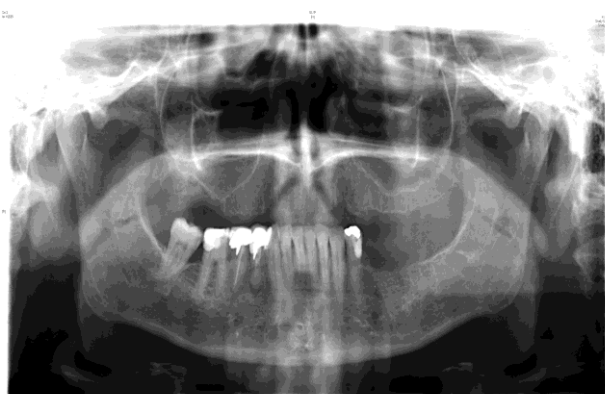
Before we performed tooth extraction these 16 patients stopped chemotherapy and BP for 15 days and they started a antibiotic therapy for 2 weeks. In these patients we observed BRONJ in 9 cases, 56.2% (9/16).

We describe one case of BRONJ reported OB (**Case 1**) and one case without BRONJ safe by root canal treatment(**Case 2**).

Case 1: female patient, aged 51, stage IV breast cancer treated with chemotherapy and bisphosphonate since June 2009, came to our observation with a partial edentulism in the lower jaw, widespread periodontitis and apical lesion at the element 44 and distal caries at the element 45 without pain; severe periodontitis with probing 7 at the elements 13 and 23, only elements of support for removable partial denture (Picture 1.0). The latter caused pain to the patient and therefore we opted for extraction therapy after antibiotic prophylaxis and discontinuation of bisphosphonates in the two weeks prior to the intervention and then to be rehabilitated with complete dentures. We have performed the extraction of the elements 13 and 23 after incision with full thickness periodontal epithelium with detachment for total coverage of dental alveolus (healing by first intention) for greater comfort for the patient postoperatively. She has performed with mouthwash rinse with chlorhexidine 0.2% and antibiotic therapy for 4 days after surgery. At a control after a week, the healing process was under way. The patient was referred to a control at a month, where it was detected a delay in healing was therefore programmed to a further control two months from baseline visit. In this occasion, we found mucositis and gingivitis in the post-extraction, jaw pain, exposed bone and halitosis. Radiography showed irregular and sclerotic bone in the area. Biopsy was performed and histological examination deposed for ONJ. Currently the patient after surgical treatment of sequestrectomy partial maxilla in the area affected by ONJ, it is completely healed (Picture 1.1).

Picture 1.1

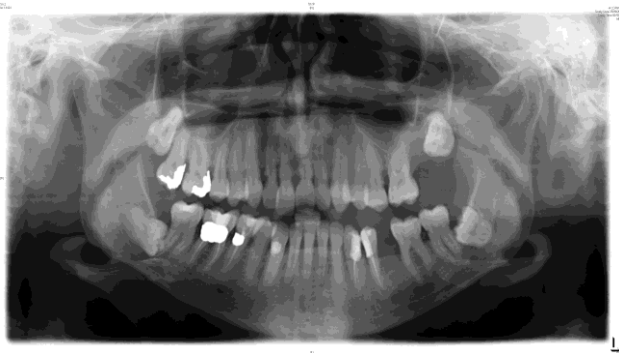
Picture1.0



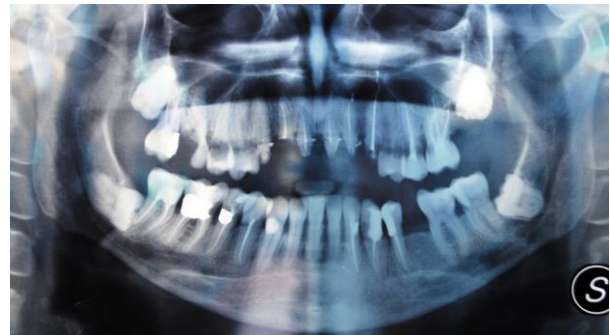Case 2: female patient, aged 57, stage IV breast cancer treated with chemotherapy from 2006, with the addition of bisphosphonates in 2007; at baseline examination widespread gingivitis and periodontal disease in all teeth with deep caries, some which also subgingival (Picture 2.0).

The patient complained of pain in the upper and lower jaw, so we opted for endodontic therapy after antibiotic prophylaxis. It was made the root canal of the elements following the insertion of a rubber dam and fang, taking particular care to not damage the pericoronal tissues, in several sessions at a distance of 15 days to be easy on the patient. Devitalized elements were clogged with gutta-percha hot condensation technique. For the post-endodontic controls at a week, radiography showed that the gradual healing process was under way, at the control at one month, radiology has been confirmed and at two months healing was almost complete. Even at the current controls was not detected any sign of ONJ (Picture 2.1).

Picture 2.0



Picture 2.1



6. Discussion

Any discussion of BRONJ is hampered somewhat by how little we know of the disease. As noted in the literature review, whilst it is accepted that the intravenously administered, higher potency nitrogen containing bisphosphonates, usually given for malignant disease are associated with a higher incidence of BRONJ (25), the precise aetiological mechanism by which the disease develops has yet to be determined.

The profound inhibition of osteoclastic activity would appear to be the most visible and possibly therefore, the most likely cause. However, we would then expect other medications with similar physiological activity to also predispose patients to developing osteonecrosis. There have been few cases reported of disease processes similar to BRONJ, without the actual influence of bisphosphonates, however isolated incidents have occurred. Recently, osteonecrosis of the jaw associated with the use of Bevacizumab were reported. Bevacizumab is a recombinant, humanized monoclonal antibody that binds to VEGF, inhibiting angiogenesis, a process that the authors speculate may have predisposed the cited patients to osteonecrosis in a similar fashion to which the anti-angiogenic effects of bisphosphonates may predispose to BRONJ (60,61). It can also be noted that monoclonal antibodies targeting osteoclastic function, such as Denosumab are also undergoing clinical trials (62). There is only a currently study reported cases in the literature of Denosumab related osteonecrosis (63). It will be interesting to see more studies about Bevacizumab-related osteonecrosis develop, or if Denosumab patients subsequently develop osteonecrosis, and what influence this may have on our understanding of BRONJ.

In this study, all patients received BP because they had oncological diseases. Although the mechanism of BRONJ is still not clear, many reports ascribe a causative role to therapy with BP (64). An hypothesis is that BP-associated BRONJ is probably due to a complex interplay of suppressed bone remodeling and hypovascularity compounded by local trauma, to an alteration in the normal bone homeostasis process that repairs the physiologic microdamage and to an antiangiogenic effects of BP, causing ischemic changes together with microtraumas, inflammations and chronic infections (35,17).

The cumulative incidence of BRONJ in patients receiving BPs for malignant disease ranges from 0.8% to 12.0%.(25) In the current study, 9 (14,2%) of 63 patients in group OB developed BRONJ patients with bone metastases from different

solid tumors not previously exposed to a preventive dental examination, who received zoledronic acid and chemotherapy combined with the antiangiogenic agent Bevacizumab.

None of the patients in group PA developed BRONJ, in contrast to the findings of previous studies.(65,26).

A point to consider is that all these 9 patients required a dental extraction during antitumoral therapy while no ONJ was observed in the other patients who received other dental procedures. In these 9 patients the length of i.v. bisphosphonate therapy was not longer compared to the other analysed patients (9,13 and 14 months) (66).

Length of exposure seems to be an important risk factor for this complication. Similarly, in a study from Germany,(65)the median time of exposure for patients with ONJ was higher than that for patients without ONJ (32 months versus 27 months).

The incidence of ONJ increased with time to exposure from 1.5% among patients treated for 4 to 12 months to 7.7% for treatment of 37 to 48 months

Moreover, studies suggest that the incidence of ONJ is related to the type of BP used (24). In the current study, all patients with BRONJ received zoledronate therapy. As suggested by the American Society of Clinical Oncology, zoledronate is one of the most powerful inhibitors of bone resorption within the drug class of BPs and its potency is the basis for the high incidence of BRONJ.(67)

Therefore, with the limits of a retrospective analysis and a small sample size, this study suggests that dental extraction during treatment is a particularly precipitating factor in the development in BRONJ in patients receiving chemotherapy combined with bevacizumab and BP. (27) Marx *et al.* first reported of an association between root canal therapy and BRONJ in 2005 (68). They observed that 11% of their patients with BRONJ had a history of endodontic treatment, but the authors noted BRONJ on teeth with radiographic evidence of failed root canal therapy or an inadequate obturation. Hence, there is a caveat to the association with BRONJ, namely the quality of endodontic care. Indeed, the authors of the follow-up study suggested that root canal therapy may be a preventive modality for BRONJ development (28).

Other authors identified dental extractions and treatment with zoledronic acid as significant factors associated with development of BRONJ. Precipitating factors there are dental extractions (55%), dental implants (2.9%), periodontal disease (41%), trauma related to intubation or poorly fitting dentures (17%), and bone exostosis at the site of osteonecrosis (34%). Marx *et al.* (61) also reported that 37.8% of their patients with BRONJ were associated with dental extractions, 29% due to periodontal disease and 11% to periodontal surgery; in another study (111) seventeen patients (16%) with Multiple Myeloma treated with BP developed BRONJ after a median number of 43 BP infusions. In 11 of 17 patients, BRONJ arose after a tooth extraction. There is a risk of spontaneous ONJ occurring in any patient on bisphosphonates. Based on Australian data, (65) a dental extraction can increase this risk of BRONJ by a factor of up to seven. For the patients who have received bisphosphonates for the treatment of malignancy the risk of post-extraction BRONJ is high while for the majority of patients who have received bisphosphonates for the management of osteoporosis, the risk of post-extraction BRONJ is lower. Indeed in the cancer patients there is an increasing recognition of the influence of other risk factors in relation to post-extraction BRONJ, the concurrent prescribing of chemotherapeutic agents with corticosteroids and bisphosphonates place the patient at a higher risk of spontaneous and post-extraction BRONJ (71).

Our data confirm the importance of dental extraction as a risk factor of BRONJ and report that 56,2% (9/16) (72) of our patients with BRONJ are associated with dental extractions under antibiotic therapy, in addition this patients received antiangiogenic therapy with Bevacizumab, another important risk factor for the development of BRONJ.

The study of Hoff *et al* (73) confirmed and highlighted observations made by others regarding the relationship between preexisting dental health and development of BRONJ. These findings further reinforce the recommendation for pre-BP dental evaluation as a strategy for prevention of BRONJ. In addition, caution should be exercised in performing dental extraction in patients receiving intravenous BP treatment as part of a cancer therapy regimen (73). In this setting, an our previous study suggested that a dental examination and preventive dental measures can minimize the risk of developing ONJ, but not that is safe to provide dental care when patients are receiving zoledronic and bevacizumab therapy. In this previous study all dental extractions, if needed, were performed before starting antitumoral treatment while in the current study all patients had already started when BP and bevacizumab and a preventive dental examination had not been performed. It is interesting that the 16 patients with root canal treatment have not developed ONJ, suggesting that a mini invasive procedure may be safely recommended for patients who have already started zoledronic acid + bevacizumab, while tooth extraction remains as one of the most important risk factors for the development of BRONJ in this type of patients. It is increasingly recognised that the healing ability of the oral soft tissues in these cases appears also to be compromised, the exact nature of which has not yet been established. When extractions are performed, the ensuing breach in the protective soft tissue envelope leads to long-term jaw exposure and secondary infective complications. The insidious, progressive osteomyelitis that often follows can be very destructive (71). Extraction avoidance strategies and adjunctive therapy may reduce or delay this disease process. A wide spectrum of jaw disease and risk of BRONJ therefore exists, but unfortunately reliable tests or markers for assessing the healing ability of the oral soft tissues and the underlying bone are not yet available.

The preventive strategies adopted for this study may have been effective and reduced the risk of

osteonecrosis. Indeed, data from another our study (61) indicate that preventive dental treatment decreased the risk of BRONJ among patients with malignancy treated with BP.

7. Conclusion

The stated aim of this project was to review the pathogenetic hypothesis and new preventive measures on the use of bisphosphonates, in a general population attending a public dental care facility.

The BRONJ lesions were treated with antibiotic therapy in all patients and two patients also received hyperbaric oxygen therapy.

Some patients were pre-treated with antibiotic therapy (Azithromycin 500 mg/day) for 10 days prior to the initiation of the medical O₃ (ozone therapy) oil treatment (57). In addition to antibiotic treatment, the exposed bone and osteomucosal edge were cleaned with a tartar supersonic scaler in order to reduce the infective component at gum level and favour the penetration of O₃ oil through the mucosa around the ONJ lesion. We applied the O₃ oil suspension in situ, directly on the ONJ lesion area using a patient customised silicone device.

Propellant clinical response was achieved in all patients treated.

Our main theory that BRONJ is a form of avascular necrosis similar to osteoradio-necrosis also has been proposed. It maybe hypothesized that the combination of the antiangiogenic agent bevacizumab (BEV) with ZOL can lead to the enhancement of bone tissue avascularization, which can account for a potentially higher incidence of BRONJ in patients with metastases to the bone who receive this type of treatment.

About new preventive measures we support the safety of root canal therapy in patients receiving bisphosphonates, it may be employed as a risk reduction strategy, as it may be used to delay or avoid dental extractions (1,69); in conclusion our study suggests that the incidence of ONJ in patients receiving BP and bevacizumab who requires dental extraction during treatment may be much higher compared to that usually reported, although further research is needed to elucidate the complex interactions of BP with chemotherapy and with antiangiogenic therapies; current evidence suggests that root canal therapy in these patients is a safe procedure and may well reduce the prevalence of BRONJ (74)

Although the incidence of BRONJ is fairly low, it remains a painful and difficult complication to treat. An interdisciplinary approach involving dentists, medical oncologists, oral and maxillofacial surgeons, and others is a good strategy to prevent and manage this condition. Also, a preventive regimen involving the maintenance of good oral hygiene should be emphasized.

8. Bibliography

1. Kyrgidis A, Triaridis S, Vahsevanos K, Antoniadis K.
Osteonecrosis of the jaw and bisphosphonate use in breast cancer patients. *Expert Rev Anticancer Ther.* 2009 Aug;9(8):1125-34.
2. Curi MM, Cossolin GS, Koga DH, Araújo SR, Feher O, dos Santos MO, Zardetto C.
Treatment of avascular osteonecrosis of the mandible in cancer patients with a history of bisphosphonate therapy by combining bone resection and autologous platelet-rich plasma: Report of 3 cases. *J Oral Maxillofac Surg.* 2007 Feb;65(2):349-55.
3. Robinson NA, Yeo JF:
Bisphosphonates—A word of caution. *Ann Acad Med Singapore* 33:48, 2004 (Suppl 4)
4. Wang J, Goodger NM, Pogrel MA:
Osteonecrosis of the jaws associated with cancer chemotherapy. *J Oral Maxillofac Surg* 61:1104, 2003
5. Marx RE:
Pamidronate (Aredia) and zoledronate (Zometa) induced avascular necrosis of the jaws: A growing epidemic. *J Oral Maxillofac Surg* 61:1115, 2003
6. Menschutkin, M (1865). "Ueber die Einwirkung des Chloracetyles auf phosphorige Saure." *Ann Chem Oharm* 133: 317-320
7. Fleisch H.
Bisphosphonates: mechanisms of action. *Endocr Rev.* 1998 Feb;19(1):80-100
- 8 Bassett CAL, Donath A, Macagno F, Preisig R, Fleisch H, Francis MD 1969
Diphosphonates in the treatment of myositis ossificans. *Lancet* 2:845
9. Fleisch H.
Development of bisphosphonates. *Breast Cancer Res.* 2002;4(1):30-4. Epub 2001 Nov 30.
10. Risau W, Lemmon V,
Changes in the vascular extracellular matrix during embryonic vasculogenesis and angiogenesis. *Dev Biol* 125(2): 441-450 (1988);
11. Ferrara N,
Role of vascular endothelial growth factor in regulation of physiological angiogenesis. *Am J Physiol Cell Physiol* 280 (6) C1358-C1366 (2001)
12. Shweiki D, Itin A, Soffer D, Keshet E,
Vascular endothelial growth factor induced by hypoxia may mediate hypoxia-induced angiogenesis. *Nature* 359, 843-845 (1992);
13. Banai s, Shweiki D, Pinson A, Chandra M, Lazarovigi G, Keshet E,
Upregulation of vascular endothelial growth factor expression induced by myocardial ischaemia: implication for coronary angiogenesis. *Cardiovasc Res* 28, 1176-1779 (1994)).
14. Ferrara N, Davis-Smyth T,
The biology of vascular endothelial growth factor. *Endocr Rev* 18, 4-25 (1997);
15. Klagsburn M, D'Amore PA.
Regulators of angiogenesis, *Ann Rev Physiol* 53, 217-239 (1991)).
16. Wood J, Bonjean K, Ruetz S, Bellahcène A, Devy L, Foidart JM, Castronovo V, Green JR.
Novel antiangiogenic effects of the bisphosphonate compound zoledronic acid. *J Pharmacol Exp Ther.* 2002 Sep;302(3):1055-61.
17. Fournier P, Boissier S, Filleur S, Guglielmi J, Cabon F, Colombel M, Clézardin P.

Bisphosphonates inhibit angiogenesis in vitro and testosterone-stimulated vascular regrowth in the ventral prostate in castrated rats. *Cancer Res.* 2002 Nov 15;62(22):6538-44.

18. Yamagishi S, Abe R, Inagaki Y, Nakamura K, Sugawara H, Inokuma D, Nakamura H, Shimizu T, Takeuchi M, Yoshimura A, Bucala R, Shimizu H, Imaizumi T.

Minodronate, a newly developed nitrogen-containing bisphosphonate, suppresses melanoma growth and improves survival in nude mice by blocking vascular endothelial growth factor signaling. *Am J Pathol.* 2004 Dec;165(6):1865-74.

19. Shipman CM, Rogers MJ, Apperley JF, Russell RG, Croucher PI.

Bisphosphonates induce apoptosis in human myeloma cell lines: a novel anti-tumour activity. *Br J Haematol.* 1997 Sep;98(3):665-72.

20. Kimmel DB.

Mechanism of action, pharmacokinetic and pharmacodynamic profile, and clinical applications of nitrogen-containing bisphosphonates. *J Dent Res.* 2007 Nov;86(11):1022-33. Review.

21. Glorieux FH, Bishop NJ, Plotkin H, Chabot G, Lanoue G, Travers R.

Cyclic administration of pamidronate in children with severe osteogenesis imperfecta. *N Engl J Med* 1998;33:947-52.

22. Rauch F, Glorieux FH.

Osteogenesis imperfecta, current and future medical treatment. *Am J Med Genet C Semin Med Genet* 2005;139(1):31-7.

23. Felsenberg D.

Osteonecrosis of the jaw--a potential adverse effect of bisphosphonate treatment. *Nat Clin Pract Endocrinol Metab.* 2006 Dec;2(12):662-3.

24. Khosla S, Burr D, Cauley J, Dempster DW, Ebeling PR, Felsenberg D, et al.

Bisphosphonate-associated osteonecrosis of the jaw: report of a task force of the American Society for Bone and Mineral Research. *J Bone Miner Res.* 2007;22(10):1479-91

25. Ruggiero SL, Dodson TB, Assael LA, Landesberg, Marx RE, Mehrotra B.

American Association of Oral and Maxillofacial Surgeons position paper on bisphosphonate-related osteonecrosis of the jaws e 2009 update. *J Oral Maxillofac Surg* 2009;67:2e12.

26. Badros, A., D.Weikel & A. Salama. 2006.

Ostonecrosis of the jaw in multiple myeloma patients: clinical features and risk factors. *J. Clin. Oncol.* 24: 945-952.

27. Woo, S., J. Hellstein & J. Kalmar. 2006.

Narrative review: bisphosphonates and osteonecrosis of the jaws. *Ann. Intern.Med.* 144: 753-776.

28. Marx RE, Sawatari Y, Fortin M, Broumand V.

Bisphosphonate-induced exposed bone (osteonecrosis/osteopetrosis) of the jaws: risk factors, recognition, prevention, and treatment. *J Oral Maxillofac Surg* 2005;63:1567e75.

29. Durie, B., M. Katz & J. Crowley. 2005.

Osteonecrosis of the jaw and bisphosphonates. (Letter). *N. Engl. J. Med.* 353:99

30. Hoff, A., B. Toth & K. Altundag. 2006.

Osteonecrosis of the jaw in patients receiving intravenous bisphosphonate therapy. *J. Clin. Oncol.* 24: 8528.

31. Ruggiero SL.

Bisphosphonate-related osteonecrosis of the jaw: an overview. *Ann N Y Acad Sci.* 2011 Feb;1218:38-46. doi: 10.1111/j.1749-6632.2010.05768.x. Epub 2010 Sep 28.

32. Ruggiero, S., B.Mehrotra&T.Rosenberg. 2004.

Osteonecrosis of the jaws associated with the use of bisphosphonates: review of 63 cases. *J. Oral Maxillofac. Surg.* 62: 527-534.

33. Leite AF, Figueiredo PT, Melo NS, Acevedo AC, Cavalcanti MG, Paula LM, Paula AP, Guerra EN.

Bisphosphonate-associated osteonecrosis of the jaws. Report of a case and literature review. *Oral Surg Oral Med Oral Pathol Oral Radiol Endod.* 2006 Jul;102(1):14-21. Epub 2006 Mar 20. Review.

34. Reinholz GG, Getz B, Pederson L, Sanders ES, Subramaniam M, Ingle JN, Spelsberg TC. Bisphosphonates directly regulate cell proliferation, differentiation, and gene expression in human osteoblasts. *Cancer Res.* 2000 Nov 1;60(21):6001-7.
35. Migliorati CA, Casiglia J, Epstein J, et al. Managing the care of patients with bisphosphonate-associated osteonecrosis. *J Am Dent Assoc* 2005; 136:1658-68
36. Allen, M. & D. Burr. 2008. Mandible matrix necrosis in beagle dogs following 3 years of daily oral bisphosphonate treatment. *J. Oral. Maxillofac. Surg.* 66: 987–994.
37. Stopeck, A., J. Body & Y. Fujiwara. 2009. Denosumab versus zoledronic acid for the treatment of breast cancer patients with bone metastases: results of a randomized phase 3 study. *Eur. J. Cancer Suppl.* 7: 2.
38. Aghaloo, T., A. Felsenfeld & S. Tetradis. 2010. Osteonecrosis of the jaw in a patient on Denosumab. *J. Oral Maxillofac. Surg.* 68: 959–963.
39. Landesberg, R. *et al.* 2008. Inhibition of oral mucosal cell wound healing by bisphosphonates. *J. OralMaxillofac. Surg.* 66: 839–847.
40. Reid IR, Bolland MJ, Grey AB. Is bisphosphonate-associated osteonecrosis of the jaw caused by soft tissue toxicity? *Bone.* 2007 Sep;41(3):318-20. Epub 2007 May 10. Review.
41. Moreira MS, Katayama E, Bombana AC, Marques MM. Cytotoxicity analysis of alendronate on cultured endothelial cells and subcutaneous tissue. a pilot study. *Dent Traumatol.* 2005 Dec;21(6):329-35.
42. Rubegni P, Fimiani M. Images in clinical medicine. Bisphosphonate-associated contact stomatitis. *N Engl J Med.* 2006 Nov 30;355(22):e25..
43. Sarasquete, M. 2008. BRONJ is associated with polymorphisms of the cytochrome P450 CYP2C8 in multiple myeloma: a genome-wide single nucleotide analysis. *Blood* 111: 2709.
44. Khamaisi M, Regev E, Yarom N, Avni B, Leitersdorf E, Raz I, Elad S. Possible association between diabetes and bisphosphonate-related jaw osteonecrosis. *J Clin Endocrinol Metab.* 2007 Mar;92(3):1172-5. Epub 2006 Dec 19.
45. Ruggiero SL, Fantasia J, Carlson E. Bisphosphonate-related osteonecrosis of the jaw: background and guidelines for diagnosis, staging and management. *Oral Surg Oral Med Oral Path Oral Radiol Endod* 2006;102(4):433e41
46. Williamson RA. Surgical management of bisphosphonate induced osteonecrosis of the jaws. *Int J Oral Maxillofac Surg*2010;39:251e5.
47. Br J Mcleod NMH, Patel V, Kusanale A, Rogers SN, Brennan PA. Bisphosphonate osteonecrosis of the jaw e a literature review of UK policies versus international policies on the management of bisphosphonate osteonecrosis of the jaw. *Oral Maxillofac Surg* doi:10.1016/j.bjoms.2010.08.005.
48. Patel V, McLeod NMH, Roger SN, Brennan PA. Bisphosphonate osteonecrosis of the jaw e a literature review of UK policies versus international policies on bisphosphonates, risk factors and prevention. *Br J Oral Maxillofac Surg* doi:10.1016/j.bjoms. 2010.05.
49. Tubiana-Hulin M, Spielmann M, Roux C, Campone M, Zelek L, Gligorov J, et al. Physiopathology and management of osteonecrosis of the jaws related to bisphosphonate therapy for malignant bone lesions. A French expert panel analysis. *Crit Rev Oncol Hematol* 2009;71(1):12e21.

50. Markose G, Mackenzie FR, Currie WJR, Hislop WS.
Bisphosphonate osteonecrosis: a protocol for surgical management. *Br J Oral Maxillofac Surg* 2009;47:294e7.
51. Marx RE.
Reconstruction of defects caused by bisphosphonate-induced osteonecrosis of the jaws. *J Oral Maxillofac Surg* 2009;67(Suppl. 1):107e19.
- 52 Engroff SL, Coletti D.
Bisphosphonate related osteonecrosis of the palate: report of a case managed with free tissue transfer. *Oral Surg Oral Med Oral Pathol Oral Radiol Endod* 2008;105:580e2.
53. Bocanegra Pe´rez S, Vincente Barrero M, Sosa Herna´ndez M, Knezevic M, Castellano Navarro JM, Rodrı´guez Millares J.
Bisphosphonate-associated osteonecrosis of the jaw. A proposal for conservative treatment. *Med Oral Patol Oral Cir Bucal* 2008;13(12):E770e3
54. Baga´n J, Blade J, Cozar JM, Constela M, Garcı´a Sanz R, Go´mez Veiga G, et al. Recommendations for the prevention, diagnosis, and treatment of osteonecrosis of the jaw (ONJ) in cancer patients treated with bisphosphonates. *Med Oral Patol Oral Cir Bucal* 2007;12:E336e40.
55. Freiburger, J, Padilla-Burgos, R, Chhoeu, A, Kraft, K, Boneta, O, Moon, R and Piantadosi, C (2007). "Hyperbaric oxygen treatment and bisphosphonate-induced osteonecrosis of the jaw - A case series." *Journal of Oral Maxillofacial Surgery* 65: 1321-1327.
56. Magopoulos, C, Karakinaris, G, Telioudis, Z, Vahtsevanos, K, Dimitrakopoulos, I, Antoniadis, K and Delaroudis, S "Osteonecrosis of the jaws due to bisphosphonate use. A review of 60 cases and treatment proposals." *American Journal of Otolaryngology* (2007). 28(3): 158-163.
57. Ripamonti CI, Cislighi E, Mariani L, Maniezzo M.
Efficacy and safety of medical ozone (O₃) delivered in oil suspension applications for the treatment of osteonecrosis of the jaw in patients with bone metastases treated with bisphosphonates: Preliminary results of a phase I-II study. *Oral Oncol.* 2011 Mar;47(3):185-90.
58. Therasse P, Eisenhauer EA, Verweij J.
RECIST revisited: a review of validation studies on tumour assessment. *Eur J Cancer* 2006;42:1031–1039
59. Maerevoet M, Martin C, Duck L.
Osteonecrosis of the jaw and bisphosphonates. *N Engl J Med.* 2005;353(1):99-102
60. Estilo, C, Fornier, M, Farooki, A, Carlson, D, Bohle, G and Huryn, J (2008). "Osteonecrosis of the jaw related to bevacizumab." *Journal of Clinical Oncology* 26(24): 4037-4043
61. Francini F, Pascucci A, Francini E, Miano ST, Bargagli G, Ruggiero G, Petrioli R. Osteonecrosis of the jaw in patients with cancer who received zoledronic acid and bevacizumab. *J Am Dent Assoc.* 2011 May;142(5):506-13
62. Cummings, S, San Martin, J, McClung, M, Siris, E, Eastell, R, Reid, I, Delmas, P, Zoog, H, Wang, A, Kutilek, S, Adami, S, Zanchetta, J, Libanati, C, Siddhanti, S and Christiansen, C (2009). "Denosumab for prevention of fractures in postmenopausal women with osteoporosis." *New England Journal of Medicine* 361(8): 756-765.
63. Akhtar NH, Afzal MZ, Ahmed AA. Osteonecrosis of jaw with the use of denosumab. *J Cancer Res Ther.* 2011 Oct;7(4):499-500. No abstract available. PMID: 22269422 [PubMed - in process]
64. Filleul O, Crompton E, Saussez S.
Bisphosphonate-induced osteonecrosis of the jaw: a review of 2,400 patient cases. *J Cancer Res Clin Oncol.* 2010;136(8):1117-24. Epub 2010 May 28.
65. Boonyapakorn T, Schirmer I, Reichart PA, Sturm I, Massenkeil G.

Bisphosphonate-induced osteonecrosis of the jaws: prospective study of 80 patients with multiple myeloma and other malignancies. *Oral Oncol.* 2008;44(9):857-69. Epub 2008 Feb 20.

66. Cherry L, Estilo, Catherine H, Van Poznak, Tijaana Williams, George C. Bohle, Phyu T. Lwin, Qin Zhou, Elyn R. Riedel, Diane L. Carlson, Heiko Schoder, Azeez Farooki, Monica Fornier, Jerry L. Halpern, Steven J. Tunick, Joseph M. Huryna. Osteonecrosis of the Maxilla and Mandible in Patients with Advanced Cancer Treated with Bisphosphonate Therapy. *The Oncologist*, Vol. 13, No. 8, 911-920, August 2008

67. Hillner BE, Ingle JN, Chlebowski RT, Gralow J, Yee GC, Janjan NA, et al. American Society of Clinical Oncology 2003 update on the role of bisphosphonates and bone health issues in women with breast cancer. *J Clin Oncol.* 2003;21(21):4042-57. Epub 2003 Sep 8.

68. Carter GD, Goss AN. Bisphosphonates and avascular necrosis of the jaws. *Aust Dent J.* 2003;48:268..

69. Cafro AM, Barbarano L, Nosari AM, D'Avanzo G, Nichelatti M, Bibas M, Gaglioti D, Taroni A, Riva F, Morra E, Andriani A Osteonecrosis of the jaw in patients with multiple myeloma treated with bisphosphonates: definition and management of the risk related to zoledronic acid. *Clin Lymphoma Myeloma.* 2008 Apr;8(2):111-6.

70. Mavrokokki, T. et al. 2007. The nature and incidence of bisphosphonate associated osteonecrosis of the jaws in Australia. *J. Oral Maxillofac. Surg.* 3: 415-423.

71. Malden N, Beltes C, Lopes V Dental extractions and bisphosphonates: the assessment, consent and management, a proposed algorithm. *Br Dent J.* 2009 Jan 24;206(2):93-8.

72. Saad F, Brown JE, Van Poznak C, Ibrahim T, Stemmer SM, Stopeck AT, Diel IJ, Takahashi S, Shore N, Henry DH, Barrios CH, Facon T, Senecal F, Fizazi K, Zhou L, Daniels A, Carrière P, Dansey R. Incidence, risk factors, and outcomes of osteonecrosis of the jaw: integrated analysis from three blinded active-controlled phase III trials in cancer patients with bone metastases. *Ann Oncol.* 2011 Oct 10. [Epub ahead of print]

73. Ana O Hoff, Béla B Toth, Kadri Altundag, Marcella M Johnson, Carla L Warneke, Mimi Hu, Ajay Nooka, Gilbert Sayegh, Valentina Guarneri, Kimberly Desrouleaux, Jeffrey Cui, Andrea Adamus, Robert F Gagel, and Gabriel N Hortobagyi. Frequency and Risk Factors Associated With Osteonecrosis of the Jaw in Cancer Patients Treated With Intravenous Bisphosphonates. *J Bone Miner Res.* 2008 June; 23(6): 826-836

74. Athanassios Kyrgidis, MD, DDS, MSC1; Amit Arora, DDS2; Kleoniki Lyroudia, DDS, PhD3; and Konstantinos Antoniadis, MD, DDS, PhD1. Root canal therapy for the prevention of osteonecrosis of the jaws: An evidence-based clinical update. *aej_280 130.133 Aust Endod J* 2010; 36: 130-133

9. CURRICULUM VITAE

Name: Filippo Francini
Date of Birth: 13 July 1983
Place of Birth: Siena, Italy
Nationality: Italian
E-mail: francini19@unisi.it

Fellowships and Awards

2004-2007 Università degli Studi di Siena, Faculty of Dentistry
B.A. in Dentistry. Final Grade 110/110. Thesis: "Accuratezza dimensionale di materiali da impronta utilizzati in protesi implantare"
2008-2011 Dottorato in Oncologia Clinica e Sperimentale Applicata in Università degli Studi di Palermo

Scientific Activities

2009 Osteonecrosi dei mascellari (ONJ) prevenzione diagnosi e trattamento - Alessandria
2009 Collegio dei Docenti di Odontoiatria - Roma
2010 Collegio dei Docenti di Odontoiatria – Chieti
2011 XXVI Congresso Società Italiana di Dermatologia Chirurgica ed Oncologica (S.I.D.C.O.) – Pisa

Oral Presentations

2009 23 June: Osteonecrosi dei mascellari (ONJ) prevenzione diagnosi e trattamento - Alessandria
2011 28/29/30 April XXVI Congresso Società Italiana di Dermatologia Chirurgica ed Oncologica (S.I.D.C.O.) – Pisa

Professional Career

2009-2011 Lecture at Dental Hygiene School in Università degli Studi di Siena
2011 May to August . Period of visit study at Clinica Rotger, Palma De Mallorca, Spain.
I have haunted Oncology Unit of Prof. Christian Rolfo. During this period I completed a training in oncology patients with metastatic breast cancer who have received bone level and Bisphosphonate therapeutics new target as part of my thesis work.
The training period included :
-External outpatient oncology patients
-Patients admitted to hospital for oncological pathology
-Visit external Maxillofacial Surgery unit by Mar Pellicer MD, PhD.
-Visit of two weeks in University Hospital Son Espases (Palma de Mallorca) in Maxillofacial Surgery Unit
-Training in diagnostic imaging (PET/CT, bone scan) in patients with metastatic breast cancer who have received bone level and Bisphosphonate in Department of Nuclear Medicine with Dr Marta Valero Camps the head of this department.

Professional Societies Membership

2007-2011 Ordinary Member Albo dei Medici Chirurghi ed Odontoiatri of Siena
2012 Ordinary Member Società Italiana di Parodontologia (S.I.d.P.)

10. PAPERS PUBLISHED DURING THE PHD COURSE

Osteonecrosis of the jaw in patients with cancer who received zoledronic acid and bevacizumab.

Francini F, Pascucci A, Francini E, Miano ST, Bargagli G, Ruggiero G, Petrioli R.

J Am Dent Assoc. 2011 May;142(5):506-13.

Effects of intravenous zoledronic acid and oral ibandronate on early changes in markers of bone turnover in patients with bone metastases from non-small cell lung cancer.

Francini F, Pascucci A, Bargagli G, Francini E,

Conca R, Miano ST, Martellucci I, Migali C, Gotti G, Fiaschi AI, Cozzolino A, Petrioli R.

Int J Clin Oncol. 2011 Jun;16(3):264-9. Epub 2011 Jan 18.

Bevacizumab and weekly docetaxel in patients with metastatic castrate-resistant prostate cancer previously exposed to docetaxel.

Francini F, Pascucci A, Francini E, Bargagli G,

Conca R, Licchetta A, Roviello G, Martellucci I, Chiriaco G, Miano ST, Marzocca G, Manganelli A, Ponchietti R,

Savelli V, Petrioli R. Prostate Cancer. 2011;2011:258689. Epub 2011 Aug 21.

11. APPENDIX

Bevacizumab and Weekly Docetaxel in Patients with Metastatic Castrate-Resistant Prostate Cancer Previously Exposed to Docetaxel

Filippo Francini,¹ Alessandra Pascucci,² Edoardo Francini,² Gianluca Bargagli,² Raffaele Conca,² Antonella Licchetta,² Giandomenico Roviello,² Ignazio Martellucci,² Giorgio Chiriaco,² Salvatora Tindara Miano,² Giuseppe Marzocca,³ Antonio Manganelli,⁴ Roberto Ponchietti,⁵ Vinno Savelli,⁶ and Roberto Petrioli^{2*}

¹Department of Odontostomatology and Maxillo-Facial Surgery, University of Siena, Policlinico Le Scotte, Viale Bracci 11, 53100 Siena, Italy

²Medical Oncology, University of Siena, Policlinico Le Scotte, Viale Bracci 11, 53100 Siena, Italy

³General Surgery, University of Siena, Policlinico Le Scotte, Viale Bracci 11, 53100 Siena, Italy

⁴Urologic Surgery, University of Siena, Policlinico Le Scotte, Viale Bracci 11, 53100 Siena, Italy

⁵Genitourinary Unit, University of Siena, Policlinico Le Scotte, Viale Bracci 11, 53100 Siena, Italy

⁶Department of Surgery, University of Siena, Policlinico Le Scotte, Viale Bracci 11, 53100 Siena, Italy

*Roberto Petrioli: Email: r.petrioli@ao-siena.toscana.it

Academic Editor: Ravi A. Madan

Received March 22, 2011; Accepted June 21, 2011.

This is an open access article distributed under the Creative Commons Attribution License, which permits unrestricted use, distribution, and reproduction in any medium, provided the original work is properly cited.

Other Sections ▼

Abstract

Background. The aim of this paper was to evaluate the activity and tolerability of docetaxel (D) and bevacizumab (Bev) in patients with metastatic castrate-resistant prostate cancer (CRPC) previously exposed to D. **Methods.** Treatment consisted of D 30 mg/m² i.v. for four consecutive weekly administrations followed by a 2-week rest interval, in addition to Bev 5 mg/kg i.v. every 2 weeks. **Results.** Forty-three patients were enrolled: a PSA response was observed in 27 patients (62.7%, 95% CI: 0.41 to 0.91), and a palliative response was achieved in 31 patients (72.1%, 95%CI: 0.48 to 1.02). After a median followup of 11.3 months, only five patients had died. The regimen was generally well tolerated. **Conclusion.** Weekly D + biweekly Bev seems to be an effective and well-tolerated treatment option for patients with metastatic CRPC previously exposed to D-based chemotherapy.

Other Sections ▼

1. Introduction

The results of two large randomised trials have provided substantial support in favor of the role of chemotherapy in the treatment of castrate-resistant prostate cancer (CRPC) by demonstrating that docetaxel (D) and prednisone (P) improve survival in comparison with older regimens and significantly improve the quality of life [1, 2]. Therefore, D has become the first-line standard of care for metastatic CRPC, with PSA responses of about 50% and median survivals of usually less than 20 months.

Patients with CRPC who progress after D treatment may be considered for a second-line chemotherapy, especially if they have a reasonable performance status, have symptoms, and/or are likely to soon develop symptoms for their disease. In this setting, a recent randomized phase III trial demonstrated that cabazitaxel, a tubuline-binding taxane drug, improved survival in metastatic CRPC patients with progressive disease after D-treatment, with a 30% reduction in the risk of death compared with mitoxantrone taken as control group [3].

D resistance is a common problem in the treatment of many tumors including CRPC, and the development of new drugs that may overcome such resistance is important to extend D activity [4].

Angiogenesis is an important process for growth, progression, and metastasis of solid tumors, and the inhibitor of the vascular endothelial growth factor (VEGF) bevacizumab (Bev) is currently approved for the treatment of colon, lung, breast, and clear cell renal carcinoma in the metastatic setting [5].

In addition, preclinical data demonstrated that VEGF inhibition may also prevent further tumor growth of the prostate cancer cell line DU 145 implanted in nude mice, and preliminary clinical studies suggested that Bev combined with chemotherapy is tolerable and has promising activity in CRPC patients [6, 7].

Although Bev achieved no PSA response when it was used in monotherapy, interesting results were reported by the combination of Bev with D and estramustine as first-line treatment in a previous study of the Cancer and Leukemia Group B [8]. Moreover, a recent study described promising data in terms of PSA response and objective response in pretreated patients with CRPC receiving D and Bev [9]. On these previous experiences, and in the hypothesis that Bev may overcome the resistance to D, we tested the activity and tolerability of Bev combined with D in CRPC patients with disease progression during or after D-based first-line chemotherapy.

Other Sections ▼

2. Patients and Methods

2.1. Eligibility Criteria

This phase II study involved patients with histologically confirmed, measurable, or evaluable advanced prostatic adenocarcinoma who had progressed while on D or within 60 days after the last D dose. This last eligibility criterion, together with a minimum of 3 months of D-based chemotherapy as first-line treatment, was required in order to better elucidate the benefit of the addition of Bev. Patients were admitted to the chemotherapy protocol provided that they met at least one of the following criteria: a positive bone scan a $\geq 25\%$ increase in PSA (PSA higher than 2 ng/mL) in comparison with baseline on two successive occasions separated by at least two weeks for patients without measurable disease; new metastatic lesions revealed by a bone scan; and a $\geq 25\%$ increase in a bidimensionally measurable tumor mass. All of the patients had to have an Eastern Cooperative Oncology Group (ECOG) performance status (PS) of ≤ 2 , adequate hematological (leukocytes $\geq 3000/\text{mm}^3$; hemoglobin ≥ 10 g/dL, platelets $\geq 100,000/\text{mm}^3$), renal (serum creatinine ≤ 2.0 mg/dL), and hepatic function (serum bilirubin ≤ 2.0 mg/dL; [Table 1](#)).

Table 1
Main eligibility criteria.
Histologically confirmed advanced prostatic carcinoma
Progression while on D or within 60 days after the last D dose
A positive bone scan and a $\geq 25\%$ increase in PSA in comparison with baseline
New metastatic lesions revealed by a bone scan
A $\geq 25\%$ increase in bidimensionally measurable tumor mass
ECOG PS of ≤ 2
Leukocytes $\geq 3000/\text{mm}^3$, haemoglobin ≥ 10 g/dL, platelets $\geq 100,000/\text{mm}^3$
Serum creatinine ≤ 2.0 mg/dL, serum bilirubin ≤ 2.0 mg/dL.

Table 1
Main eligibility criteria.

Patients were excluded if they had not received prior D-based chemotherapy or if they had congestive heart failure, a recent myocardial infarction, or any other previous malignant diseases except basal cell carcinoma of the skin. Bisphosphonates were admitted in all of patients who presented with bone metastases.

The study was approved by the ethical committee of Siena University, and all patients provided their written informed consent.

2.2. Treatment Plan

Treatment consisted of D 30 mg/m² as a 30-minute intravenous infusion, using a schedule of four consecutive weekly administrations followed by a 2-week rest interval, in addition to Bev 5 mg/kg intravenously every 2 weeks. Premedication consisted of P 10 mg p.o. (12 h before, at the time of, and 12 h after D administration). Cycles were administered if serum leukocytes were $\geq 3000/\text{mm}^3$, granulocytes $> 1500/\text{mm}^3$, and platelets $> 100,000/\text{mm}^3$. Ondansetron 8 mg was administered at the beginning of each treatment cycle as antiemetic medication. The patients continued to take analgesic medication at doses adjusted to provide optimal pain control. The chemotherapy was administered until disease progression or

unacceptable toxicity, and for a maximum of 30 weekly D cycles. In responding patients, Bev could be continued at the investigator's discretion, or until disease progression or unacceptable toxicity.

2.3. Response Assessments

Tumor response in patients with measurable lesions was evaluated using the RECIST criteria [10]. Serum PSA was measured every three weeks: a PSA response was defined as a reduction from baseline of at least 50% for at least three weeks whereas PSA progression was defined as an increase from nadir of at least 25% and ≥ 2 ng/mL [11]. Pain symptomatology was measured at baseline and then every 6 weeks by the McGill Melzack Pain Questionnaire, and pain response was defined as a 2-point reduction in the 6-point present pain intensity scale (or the complete disappearance of pain if the initial score was 1+) [12]. These results had to be maintained at two consecutive evaluations made at least 3 weeks apart and without any increase in analgesic consumption. The patients were asked to classify the average pain level during the previous 24 h. We used a translated form of the McGill Melzack Questionnaire to which the “reconstruction-based methodology” has been applied [13]. Analgesic consumption was based on the average daily quantities taken by the patient during the previous week, and assigned oral morphine equivalents before analysis [14].

The laboratory studies (blood and platelet counts, and a comprehensive screening profile) were performed at baseline and every three weeks, and the patients underwent a weekly complete blood cell count and electrolytes profile before chemotherapy.

The imaging studies included abdominal and pelvic CT or magnetic resonance imaging, a bone scan, and chest radiography. All measurable diseases were reevaluated at 8-week intervals. Radionuclide bone scans were repeated after 3 months. In all subjects, fasting venous blood samples were drawn between 8.00 and 9.00 a.m. after a 12-h fasting period at baseline and after 3 months in order to assess the bone resorption marker crosslinked C-terminal telopeptide (CTX) and the bone formation marker bone alkaline phosphatase (B-ALP).

In all cases, a baseline ECG was obtained, and a further cardiac work-up was performed if indicated. Bone disease progression was defined as the appearance of any new bone lesion or the progression of existing bone metastases. A dental examination, including orthopantomography (OPT), was performed in all patients at baseline, and active dental surveillance every three months.

2.4. Treatment-Related Adverse Events

Toxicity was defined using the National Cancer Institute (NCI) Common Toxicity Criteria, version 3.0. The treatment was delayed at the first occurrence of grade II hematological toxicity, and administered at the same dose after it returned to grade I or better. In the case of grade III or IV toxicity, the treatment was interrupted and a maximum of three weeks was allowed for recovery, after which the patients were withdrawn from the study. In the case of a second episode of grade III or IV toxicity in the same patient, treatment was resumed after recovery and the subsequent administration of D was reduced to 20 mg/m². Chemotherapy protocol was discontinued if the ejection fraction decreased below the institutional lower limit of normal and declined by $\geq 15\%$.

2.5. Statistical Considerations

The primary endpoint was PSA response. In accordance with Simon's “optimal design”, a sample size of 36 patients was planned, assuming a response rate of approximately 10% for other second-line chemotherapies, and a target level of interest of 30%, with an α of 0.05 and a β of 0.90. In the hypothesis of 10%–20% inevaluable patients, about 40 patients were planned to be enrolled to better estimate the response. Secondary endpoints were pain response, progression-free survival (PFS), and overall survival. PFS was defined as the time from starting chemotherapy to the first occurrence of objective or PSA progression, or death due to any cause.

3. Results

From September 2008 to April 2010, 43 patients were enrolled. Their median age was 74 years (range 58–82 years) Thirty-seven patients had bone metastases. and seventeen patients had measurable disease (Table 1). Most of enrolled patients have participated in a randomized phase II study which compared the combination of weekly D and weekly Epirubicin (EPI) with the conventional 3-weekly D [15]. All patients who had achieved a response or a stable disease during first-line chemotherapy had been retreated with D-based chemotherapy. The median dose of D received before the enrollment in the current study was 940.8 mg/m² (range 30–1122,3).

All enrolled patients were treated with the new treatment regimen within 60 days from the end of last D dose (range 12 to 52 days). Two patients received only one weekly chemotherapy cycle for treatment-unrelated reasons. Two patients were lost to followup after four and six months from the start of treatment. All patients were included in the overall analysis (intent-to-treat). A total of 968 weekly D cycles (median 21, range 11–30) and a total of 1172 biweekly cycles of Bev (median 26, range 6–41) were administered.

3.1. Biochemical Response

A decrease in PSA levels >50% was observed in 27 patients (62.7%, 95% CI: 0.41 to 0.91), and nine patients (20.9%) had stable PSA for at least twelve weeks (Table 3). After the first 3 weekly cycles a PSA surge was observed in 18 out of 27 responding patients: in all these patients PSA then progressively decreased and at the third month was less than 50% with respect to the baseline values (Figure 1).

Enrolled patients	43
Biochemical response	
PSA decline ≥50%	27 (62.8%)
Stable disease	9 (20.9%)
Progressive disease	7 (16.3%)
Objective response	
Partial remission	8/17 (47.1%)
Stable disease	7/17 (41.1%)
Progressive disease	2/17 (11.8%)
Palliative response	31 (72.1%)

Table 3
Response to treatment.




Figure 1
Median PSA (with minimum and maximum values) in 18 out of 27 responding patients who showed a PSA surge within the first 3 months of treatment with weekly D + biweekly Bev.

During the prior first-line chemotherapy, 15 out of the 27 responding patients had achieved PSA response while 8 had achieved stable disease and 4 patients had progressed.

3.2. Objective Response

Of seventeen patients with measurable disease, eight achieved PR and seven had stable disease: objective responses were observed on prostate cancer (3 cases), prostate cancer and pelvic lymph nodes (3 cases), and prostate cancer and lung metastases (2 cases).

The bone scan, which could be repeated after 3 months of treatment in 35 out of 37 patients with bone metastases, showed stable disease in 29 patients, and partial remission in 5 patients; two or more new lesions compared with the prior scan for trial entry were described in one patient. This same patient had PSA progression after 3 months and chemotherapy was stopped. The bone markers CTX and B-ALP were reduced >50% with respect to baseline values in 33 and 28 patients, respectively, after 12 weeks from the

start of treatment (65% median reduction for CTX and 58% median reduction for B-ALP). A palliative response was observed in 31 patients after 12 weeks (72.1%, 95% CI: to 0.48 to 1.02).

After 12 weeks from the start of the new treatment protocol, seven patients (including two subjects who received only one treatment cycle) had PSA progression, but three of them had a reduction in bone pain with decrease in analgesics use, improvement in performance status, and reduction in serum levels of the bone markers CTX and BALP. Despite the initial end-point of the study, because of the achieved clinical benefit, our oncology group and the scientific ethical committee decided to continue D + Bev in these three patients until worsening of pain and/or performance status.

After a median followup of 11.3 months, 18 patients showed PSA progression and only five patients had died.

The regimen was generally well tolerated, and no unexpected toxic effects were observed ([Table 4](#)). No grade 4 toxicity or congestive heart failure was observed, and all cycles were administered on an outpatient basis. The most frequent side effects were neutropenia, anemia, thrombocytopenia, epistaxis, and fatigue, which were grade I or II in most cases. Grade III fatigue was observed in two patients after nine and sixteen cycles, respectively: despite the reduction of D dose and the discontinuation of Bev, treatment was then interrupted in these cases because of the persistence of this side effect. Grade 1 epistaxis was observed in 23 patients (53.4%) during treatment, but reached grade 2 in only 7 cases and grade 3 in one patient. No patient developed osteonecrosis of the jaw (ONJ). Dose reduction of D was required in a total of twelve patients: 37 (3.8%) weekly D cycles were administered with a 33% reduction, down to 20 mg weekly. A total of 57 (5.8%) weekly D cycles were delayed: the reason for the delays were hematological in 41 (71.9%) and nonhematological in 16 (28.1%) cycles. A total of 46 (39.2%) biweekly Bev cycles were delayed: the reasons for the delays were haematological in 39 (84.8%) and non-hematological in 7 (15.2%) cycles.

	Grade 1	Grade 2	Grade 3
Hematological			
Neutropenia	19 (44.1%)	14 (32.5%)	8 (18.6%)
Anemia	20 (46.5%)	15 (34.8%)	6 (13.9%)
Thrombocytopenia	18 (41.8%)	12 (27.9%)	4 (9.3%)
Nonhematological			
Nausea/vomiting	12 (27.9%)	8 (18.6%)	0
Diarrhea	9 (20.9%)	6 (13.9%)	0
Constipation	13 (30.2%)	11(25.5%)	0
Nail changes	22 (51.1%)	17 (39.5%)	2 (4.6%)
Dry eye/tearing	26 (60.4%)	15 (34.8%)	0
Mucositis/cheilitis	19 (43.6%)	12 (27.9%)	0

Table 4
Number of patients experiencing the most frequent treatment-related adverse events.

Other Sections ▼

4. Discussion

The current phase II study is the first extended report which suggests that the combination of weekly D with the biweekly administration of the antiangiogenic agent Bev is effective and tolerable in the treatment of patients with metastatic CRPC who have progressed after D-based chemotherapy: the 62.7% PSA and 72.1% palliative response compare favorably with the results observed in phase II studies of second-line chemotherapy [16, 17]. Other chemotherapeutic agents might be used after initial treatment with D, including old drugs such as vinorelbine, oral cyclophosphamide, etoposide, mitoxantrone, vinblastine, and doxorubicin, but most studies reported no objective response and less than 15% laboratory response [18]. Other studies described modest activity with satraplatin, a third-generation platinum analog, or ixabepilone, an epothilone, with mitoxantrone, or also with the combination of D and high-dose calcitriol [19–21].

It must be remembered that in most clinical trials a few patients stop the first-line treatment with D while still responding to the drug. In this group of patients a repeated treatment with D might be appropriated if progression occurs after a reasonably long time interval [22]. In our study, the strict eligibility requirement of progression while on D or within 60 days of the last D dose means that these patients might have not responded to rechallenge with D. Notably, responses were seen also in patients who had not shown an initial

response to prior D as first-line treatment. Therefore, this finding and the characteristics of enrolled patients support an effective role of Bev in restoring the sensitivity to D and also in reversing resistance in patients who were previously nonresponders to the drug ([Table 1](#)). Bev is able to alter tumor vasculature, for example, decreasing tumor vessel permeability and increasing intratumoral perfusion, which might turn into an improved tumor delivery of a cytotoxic agent, thus enhancing its antitumor activity [23]. Since the limited tissue penetration is an important mechanism of tumor resistance to taxanes, the effects of the antiangiogenic agent Bev may be a possible explanation of the observed reversal of D resistance in our population study [24].

Another point to consider is the observed PSA surges during treatment protocol in 18 out of 27 responding patients, which may suggest massive cancer cell death and PSA release, thus indicating efficacy, as also reported in other previous trials during chemotherapy for CRPC [25, 26]. Nevertheless, despite the unknown biological relevance of this transient initial PSA increase, most of our patients achieved an improvement in bone symptomatology and in performance status, and PSA decreased > 50% at 3 months ([Figure 1](#)). Furthermore, PSA results correlated with changes in bone markers, since CTX and B-ALP were reduced with respect to baseline values in all these patients, and this was probably related to the real antitumor activity of the D + Bev combination.

Notably, despite PSA progression after 3 months of treatment, three patients continued to have an improvement in performance status and reduction in bone symptomatology and bone markers, and because of this achieved clinical benefit they continued to receive D + Bev. This finding may confirm that the progression criteria that are usually suitable for assessment of efficacy of cytotoxic agents in CRPC may not be suitable for discriminating treatment effects of targeted agents such as Bev [27, 28]. It may be that significant treatment benefits with targeted therapies need long time scales to emerge, possibly due to its noncytotoxic-targeted mechanism of action.

As Bev-based salvage treatment, a 55% PSA response and 37.5% objective response was found in 20 pretreated patients with CRPC receiving D 60 mg/m² and Bev 10 mg/kg every 3 weeks [9]. Another recent experience suggested a benefit in progression-free and in overall survival by the use of weekly D 25 mg/m² combined with Bev 10 mg/kg every two weeks in CRPC patients [29]. The toxicity profile of our treatment protocol was comparable to that observed in these BEV-based salvage treatments, with a major incidence of grade IV neutropenia and thrombocytopenia reported by the use of 3-weekly D schedule. Considering the strict eligibility criteria of our study and the fact that all our patients had previously received at least two chemotherapy lines, the current results appear even more encouraging than that found in the aforementioned reports. Nevertheless, it must be considered that most of metastatic CRPC patients who relapse after the first line D and D rechallenge do not survive more than 6 months. It is notable that in the current study, after a median follow-up time of 11.3 months, only five patients had died and most patients who started the new treatment protocol more than 12 months ago are still alive and have a good quality of life.

Therefore, although three-weekly D and P remains the conventional treatment protocol in first-line setting, it may be hypothesized that weekly D combined with biweekly Bev, as applied by us, is an appropriate schedule in terms of activity and toxicity for heavily pretreated patients. The combination of weekly scheduling of D with Bev has shown interesting activity without significant toxicity also in breast, ovarian and mesenchymal tumors [30–32].

The efficacy and safety results of the current study compare favorably also with those reported with the drug cabazitaxel, that was recently approved by US Food and Drug administration for second-line treatment of metastatic CRPC patients [3]. Severe neutropenia was common in cabazitaxel trial (89%), and 18% of patients discontinued the study treatment because of adverse events while grade III neutropenia was observed in only 18.6% of cases in our population study. Nevertheless toxicity was mild in our patients: adverse events likely related to Bev (hypertension, epistaxis, and albuminuria) never reached grade 3 and

were easily manageable, as usually reported in other tumors with the biweekly schedule of 5 mg/kg of Bev. The low toxicity of D was mainly due to the weekly schedule. The efficacy of weekly D seems to be similar to that of the usual 3-weekly schedule, but their comparative toxicities differ markedly, with moderate to severe myelosuppression being common when the drug is administered once every 3 weeks [33]. As well as is concerned other adverse events, Although the new and potent antiangiogenic therapies might theoretically enhance the antiangiogenic effects of zoledronic acid on bone tissue, our findings do not suggest a trend for a possible higher incidence of bisphosphonate-induced ONJ for patients receiving zoledronic acid and Bev [34].

Another point to consider is that the percentage of enrolled patients ≥ 75 years was about 50% in the current study, compared with only 18% in cabazitaxel trial. On these findings, it seems that weekly D and biweekly Bev can be safely administered also to elderly patients, who represent the most part of CRPC population. Therefore, although cabazitaxel will be the only established second-line treatment of CRPC patients in the next future, weekly D and Bev may be a valid option for patients with a decreased hematological reserve and/or for elderly subjects. Moreover, in the absence of a randomized comparison between cabazitaxel and our proposed treatment protocol, weekly D and Bev might be used after cabazitaxel failure.

In conclusion the results of this study suggest that weekly D and biweekly Bev is an effective and well-tolerated treatment option for patients with metastatic CRPC previously exposed to D. Bev seems to overcome the resistance to the drug in patients who had progressed during or after D-based chemotherapy.

5. Conclusion

Weekly D + biweekly Bev seems to be an effective and well-tolerated treatment option for patients with metastatic CRPC previously exposed to D-based chemotherapy.

Enrolled patients	43
Median age (range) years	74 (58–82)
≥ 75 years	21 (48.8%)
ECOG performance status	
0	9
1–2	34
Sites of metastases	
Bone	26
Bone + prostate cancer	4
Bone + prostate cancer + lymph nodes	4
Bone + lung	3
–	–

Table 2
Main patient characteristics.

Acknowledgments

The authors wish to thank the following members of the Oncology Group on Genitourinary Tumors who substantially contributed to recruit eligible patients and made this study possible: Prof. F. Roviello, Prof. D. Marrelli, Oncologic Surgery, University of Siena; Dr. Massoni, Urology, Siena; Dr. G. Giusti, USL 10, Pisa, Italy; Dr. G. Vegni, Volterra Hospital; Dr. R. Terreni, Castelfiorentino, AUSL 11 Empoli, Dr. ssa T. Cerri Vestri, USL Arezzo.

Other Sections ▼

References

1. Tannock IF, de Wit R, Berry WR, et al. Docetaxel plus prednisone or mitoxantrone plus prednisone for advanced prostate cancer. *The New England Journal of Medicine*. 2004;351(15):1502–1512. [PubMed]
2. Petrylak DP, Tangen CM, Hussain MH, et al. Docetaxel and estramustine compared with mitoxantrone and prednisone for advanced refractory prostate cancer. *The New England Journal of Medicine*. 2004;351(15):1513–1520. [PubMed]
3. de Bono JS, Oudard S, Ozguroglu M, et al. Prednisone plus cabazitaxel or mitoxantrone for metastatic castration-resistant prostate cancer progressing after docetaxel treatment: a randomised open-label trial. *The Lancet*. 2010;376(9747):1147–1154.

4. Mathew P, DiPaola R. Taxane refractory prostate cancer. *Journal of Urology*. 2007;178(3, part 2):S36–S41. [[PubMed](#)]
5. Pañares RL, Garcia AA. Bevacizumab in the management of solid tumors. *Expert Review of Anticancer Therapy*. 2007;7(4):433–445. [[PubMed](#)]
6. Borgström P, Bourdon MA, Hillan KJ, Sriramarao P, Ferrara N. Neutralizing anti-vascular endothelial growth factor antibody completely inhibits angiogenesis and growth of human prostate carcinoma micro tumors in vivo. *Prostate*. 1998;35(1):1–10. [[PubMed](#)]
7. Ryan CJ, Lin AM, Small EJ. Angiogenesis inhibition plus chemotherapy for metastatic hormone refractory prostate cancer: history and rationale. *Urologic Oncology*. 2006;24(3):250–253. [[PubMed](#)]
8. Picus J, Halabi S, Rini B, et al. The use of bevacizumab (B) with docetaxel (D) and estramustine (E) in hormone refractory prostate cancer (HRPC): initial results of CALGB 90006. *Proceeding of the American Society of Clinical Oncology*. 2003;22, abstract 1578
9. Di Lorenzo G, Figg WD, Fossa SD, et al. Combination of bevacizumab and docetaxel in docetaxel-pretreated hormone-refractory prostate cancer: a phase 2 study. *The European Urology*. 2008;54(5):1089–1096.
10. Therasse P, Arbuck SG, Eisenhauer EA, et al. New guidelines to evaluate the response to treatment in solid tumors. *Journal of the National Cancer Institute*. 2000;92(3):205–216. [[PubMed](#)]
11. Scher HI, Halabi S, Tannock IF, et al. Design and end points of clinical trials for patients with progressive prostate cancer and castrate levels of testosterone: recommendations of the Prostate Cancer Clinical Trials Working Group. *Journal of Clinical Oncology*. 2008;26(7):1148–1159. [[PubMed](#)]
12. Melzack R. The McGill pain questionnaire: major properties and scoring methods. *Pain*. 1975;1(3):277–299. [[PubMed](#)]
13. De Benedittis G, Massei R, Nobili R, Pieri A. The Italian pain questionnaire. *Pain*. 1988;33(1):53–62. [[PubMed](#)]
14. McCormack A, Hunter-Smith D, Piotrowski ZH, Grant M, Kubik S, Kessel K. Analgesic use in home hospice cancer patients. *Journal of Family Practice*. 1992;34(2):160–164. [[PubMed](#)]
15. Petrioli R, Pascucci A, Conca R, et al. Docetaxel and epirubicin compared with docetaxel and prednisone in advanced castrate-resistant prostate cancer: a randomised phase II study. *The British Journal of Cancer*. 2011;104(4):613–619.
16. Berthold DR, Sternberg CN, Tannock IF. Management of advanced prostate cancer after first-line chemotherapy. *Journal of Clinical Oncology*. 2005;23(32):8247–8252. [[PubMed](#)]
17. Oh WK, Manola J, Babcic V, Harnam N, Kantoff PW. Response to second-line chemotherapy in patients with hormone refractory prostate cancer receiving two sequences of mitoxantrone and taxanes. *Urology*. 2006;67(6):1235–1240. [[PubMed](#)]
18. Garney EG, Sartor O, Halabi S, Vogelzang NJ. Second-line chemotherapy for advanced hormone-refractory prostate cancer. *Clinical Advances in Hematology and Oncology*. 2008;6(2):118–122, 127–132. [[PubMed](#)]
19. Sternberg CN. Satraplatin in the treatment of hormone-refractory prostate cancer. *The British Journal of Urology International*. 2005;96(7):990–994.
20. Galsky MD, Small EJ, Oh WK, et al. Multi-institutional randomized phase II trial of the epothilone B analog ixabepilone (BMS-247550) with or without estramustine phosphate in patients with progressive castrate metastatic prostate cancer. *Journal of Clinical Oncology*. 2005;23(7):1439–1446. [[PubMed](#)]
21. Petrioli R, Pascucci A, Francini E, et al. Weekly high-dose calcitriol and docetaxel in patients with metastatic hormone-refractory prostate cancer previously exposed to docetaxel. *The British Journal of Urology International*. 2007;100(4):775–779.
22. Loriot Y, Massard C, Gross-Goupil M, et al. The interval from the last cycle of docetaxel-based chemotherapy to progression is associated with the efficacy of subsequent docetaxel in patients with prostate cancer. *The European Journal of Cancer*. 2010;46(10):1770–1772.
23. Dickson PV, Hamner JB, Sims TL, et al. Bevacizumab-induced transient remodeling of the vasculature in neuroblastoma xenografts results in improved delivery and efficacy of systemically administered chemotherapy. *Clinical Cancer Research*. 2007;13(13):3942–3950. [[PubMed](#)]

24. Kyle AH, Huxham LA, Yeoman DM, Minchinton AI. Limited tissue penetration of taxanes: a mechanism for resistance in solid tumors. *Clinical Cancer Research*. 2007;13(9):2804–2810. [\[PubMed\]](#)
25. Thuret R, Massard C, Gross-Goupil M, et al. The postchemotherapy PSA surge syndrome. *Annals of Oncology*. 2008;19(7):1308–1311. [\[PubMed\]](#)
26. Nelius T, Filleur S. PSA surge/flare-up in patients with castration-refractory prostate cancer during the initial phase of chemotherapy. *Prostate*. 2009;69(16):1802–1807. [\[PubMed\]](#)
27. Collette L, Burzykowski T, Carroll KJ, Newling D, Morris T, Schröder FH. Is prostate-specific antigen a valid surrogate end point for survival in hormonally treated patients with metastatic prostate cancer? Joint research of the European Organisation for Research and treatment of cancer, the Limburgs Universitair Centrum, and AstraZeneca Pharmaceuticals. *Journal of Clinical Oncology*. 2005;23(25):6139–6148. [\[PubMed\]](#)
28. Scher HI, Warren M, Heller G. The association between measures of progression and survival in castrate-metastatic prostate cancer. *Clinical Cancer Research*. 2007;13(5):1488–1492. [\[PubMed\]](#)
29. Heidenreich A, Pfister DA, Thüer R, Brehmer B. Docetaxel rechallenge versus docetaxel/bevacizumab in castration-resistant prostate cancer following first-line docetaxel. *Journal of Clinical Oncology*. 2010;28(15_supplement, abstract e15006)
30. Ramaswamy B, Elias AD, Kelbick NT, et al. Phase II trial of bevacizumab in combination with weekly docetaxel in metastatic breast cancer patients. *Clinical Cancer Research*. 2006;12(10):3124–3129. [\[PubMed\]](#)
31. Cohn DE, Valmadre S, Resnick KE, Eaton LA, Copeland LJ, Fowler JM. Bevacizumab and weekly taxane chemotherapy demonstrates activity in refractory ovarian cancer. *Gynecologic Oncology*. 2006;102(2):134–139. [\[PubMed\]](#)
32. Gorelik B, Ziv I, Shohat R, et al. Efficacy of weekly docetaxel and bevacizumab in mesenchymal chondrosarcoma: a new theranostic method combining xenografted biopsies with a mathematical model. *Cancer Research*. 2008;68(21):9033–9040. [\[PMC free article\]](#) [\[PubMed\]](#)
33. Engels FK, Verweij J. Docetaxel administration schedule: from fever to tears? A review of randomised studies. *The European Journal of Cancer*. 2005;41(8):1117–1126.
34. Ferretti G, Fabi A, Carlini P, et al. Zoledronic acid and angiogenesis. *Clinical Cancer Research*. 2007;13(22, part 1):p. 6850.

Articles from *Prostate Cancer* are provided here courtesy of
Hindawi Publishing Corporation

Original Article

Effects of intravenous zoledronic acid and oral ibandronate on early changes in markers of bone turnover in patients with bone metastases from non-small cell lung cancer

Filippo Francini¹, Alessandra Pascucci², Gianluca Bargagli², Edoardo Francini², Raffaele Conca², Salvatora Tindara Miano², Ignazio Martellucci², Cristina Migali², Giuseppe Gotti³, Anna Ida Fiaschi⁴, Annunziata Cozzolino¹ and Roberto Petrioli²✉

(1) Department of Odontostomatology and Maxillo-Facial Surgery, University of Siena, Siena, Italy

(2) Department of Medical Oncology, University of Siena, Viale Bracci, 53100 Siena, Italy

(3) Department of Thoracic Surgery, University of Siena, Siena, Italy

(4) Pharmacology Unit, University of Siena, Siena, Italy

✉ Roberto Petrioli

Email: r.petrioli@ao-siena.toscana.it

Received: 14 September 2010 **Accepted:** 17 December 2010 **Published online:** 18 January 2011

Abstract

Background

The aim of this study was to assess the early effects of zoledronic acid (ZOL) and oral ibandronate (IBA) on the bone resorption marker s-CTX (serum C-telopeptide of collagen type I) and the bone formation marker B-ALP (bone-alkaline phosphatase) in patients with bone metastases from non-small cell lung cancer (NSCLC).

Methods

Fifty-five patients with at least one site of bone metastasis secondary to NSCLC were randomly assigned to receive intravenous ZOL 4 mg every 4 weeks, or oral IBA 50 mg/day.

Results

At 1 month of treatment, s-CTX was reduced by 54.8% (95% CI 40.4–59.8%) in the ZOL group (26 evaluable patients) compared with 38.2% (95% CI 29.8–48.7%) in the oral IBA group (27 evaluable patients) ($p = 0.03$). At 3 months, s-CTX was reduced by 72.6% (95% CI 58.6–71.3%) in the ZOL group, compared with 66.4% (95% CI 54.3–79.5%) in the oral IBA group ($p = 0.22$). Both bisphosphonates similarly decreased the bone marker B-ALP at 1 month (ZOL 24.7%, 95% CI 3.6–39.5%, and IBA 24.2%, 95% CI 2.8–43.4%) and 3 months (ZOL 28.6%, 95% CI +2.8–43.3%, and IBA 24.2%, 95% CI 3.2–47.4%). Both bisphosphonates were well tolerated.

Conclusion

Considering the changes in bone markers, ZOL and oral IBA show comparable efficacy in patients with NSCLC and bone metastases.

Keywords Bone markers – Bone metastases – Breast cancer – Ibandronate – NSCLC – Prostate cancer – Zoledronate

Introduction

Bone is a frequent site of metastasis in patients with many solid tumors, including non-small cell lung cancer (NSCLC) [1]. Metastatic bone disease is associated with the potential occurrence of skeletal-related events (SREs), including pathologic fractures, spinal cord compression, need for radiation and/or surgery to bone, and hypercalcemia, which can cause severe morbidity and reduction in quality of life [2]. Bisphosphonates are drugs that effectively inhibit bone resorption and are now recommended as an important component of care to prevent skeletal complications in patients with bone metastases.

Zoledronic acid (ZOL) and ibandronate (IBA) are the two newer aminobisphosphonates with substantial activity and tolerability for the treatment of metastatic bone disease [3, 4]. ZOL demonstrated high efficacy in the treatment of hypercalcemia of malignancy (HCM) and bone metastases from different solid tumors [5, 6]. IBA reduced the risk of new SREs by approximately 40% in patients with breast cancer and bone metastases in placebo-controlled phase III trials, and also exhibited efficacy in patients with bone metastases from a variety of other primary malignancies [7, 8]. IBA is available also as an oral formulation, which seems to have an equal efficacy to i.v. administration, is well tolerated, exhibits long-term safety, and offers convenient home administration [9]. IBA is approved only for the treatment of bone metastases from breast cancer, and few data are reported on the use of this bisphosphonate in NSCLC patients with bone lesions. Moreover, at the start of the investigation described in this work, there were no data that directly compared the activity of ZOL and oral IBA in patients with bone metastases from different solid tumors, including NSCLC.

Although the reduction of SREs is the primary endpoint in patients with bone metastases, the measurement of biochemical markers of bone metabolism, which reflect both bone resorption and formation, can provide useful information about the effects of bisphosphonates and underlying anticancer therapy [10, 11]. A marked reduction in the levels of bone resorption markers during treatment with bisphosphonates in cancer patients with bone metastases has been reported, resulting in fewer skeletal complications and a more favorable prognosis. The bone resorption markers type I collagen telopeptide NTX (serum and urinary concentration) and serum level of crosslinked C-terminal telopeptide (s-CTX) exhibited similar efficacies for the prediction of SREs in metastatic bone disease [12, 13]. One of the most well-investigated bone formation markers, bone alkaline phosphatase (B-ALP), was useful for monitoring treatment with bisphosphonates in patients with prostate cancer, lung cancer, and other solid tumors [14, 15].

The aim of this study was to assess the early effects of ZOL and oral IBA on the bone turnover markers s-CTX and B-ALP in patients with bone metastases from NSCLC.

Patients and methods

Patients ≥ 18 years of age with an Eastern Cooperative Oncology Group (ECOG) performance status of ≤ 2 and at least one site of bone metastasis secondary to NSCLC were eligible. Patients were excluded if they had liver metastases with a total bilirubin level of >2.5 mg/dL, a serum creatinine level of >3.0 mg/dL, or symptomatic brain metastases. Patients were also excluded if they had been

previously exposed to bisphosphonates, had severe cardiovascular disease, hypertension refractory to treatment, or symptomatic coronary artery disease. The study was approved by the local institutional ethical committee, and all patients provided written informed consent.

In all subjects, fasting venous blood samples were drawn between 8.00 and 9.00 a.m. after a 12-h fasting period at baseline and at one and three months in order to assess s-CTX and B-ALP. A complete blood chemistry, including serum electrolytes, calcium and magnesium, was performed at baseline and then every 3 weeks. Decreased renal function was defined as a change from the baseline serum creatinine of ≥ 0.5 mg/dL for patients with normal baseline serum creatinine and ≥ 1.0 mg/dL for patients with abnormal baseline serum creatinine, or at least double the baseline values.

S-CTX was evaluated by an enzyme-linked immunosorbant assay (ELISA) method (Serum Cross Laps ELISA, Nordic Bioscience Diagnostics, Herlev, Denmark). The intra- and interassay coefficients of variation for s-CTX at our institution were 5.4 and 7.9%, respectively. B-ALP was measured by a radioimmunometric method (BALP-Tandem-R Ostase, Hybritech, San Diego, CA, USA). The intra- and interassay coefficients of variation for B-ALP in our institution were 6.7 and 8.1%, respectively.

The normal ranges of s-CTX and B-ALP were obtained in age-matched groups of 100 healthy males and 100 healthy pre- and postmenopausal women.

All patients had stage IV disease. A radionuclide bone scan and other radiologic techniques (X-ray: Rx; computed tomography: CT, and/or magnetic resonance imaging: MRI) were performed at baseline and repeated every 6 months. Bone metastasis response was evaluated by the bone-specific response criteria of the MD Anderson Cancer Center (MDA), which updated previous bone response criteria by expanding radiographic assessment and incorporating both CT and MRI [16]. Bone marker data should be available for all patients at baseline and at 1 and 3 months.

Pain measurement was performed according to the 6-point pain intensity scale of the McGill–Melzack pain questionnaire at baseline and then after 1 and 3 months [17]. The pain scale has verbal descriptors (0, no pain; 1, mild pain; 2, discomforting pain; 3, distressing pain; 4, horrible pain; 5, excruciating pain), and the patients were asked to classify the average pain level during the previous 24 h. We used a translated form of the McGill–Melzack questionnaire to which the “reconstruction-based methodology” was applied [18]. Analgesic consumption was based on the average daily quantities taken by the patient during the previous week, and assigned oral morphine equivalents before analysis [19].

Treatment

Patients were randomly assigned to receive intravenous ZOL 4 mg via 15-min infusion in 100 mL every 4 weeks, or oral IBA 50 mg/day. IBA tablets were taken after an overnight fast (at least 6 h) and at least 30 min before the first food or drink of the day. Conventional chemotherapy for patients with advanced NSCLC was started at the same time as bisphosphonates. Bisphosphonates were administered until the occurrence of severe adverse events, and for a maximum of 2 years.

Before the first study treatment, the medical history was reviewed and a complete physical examination, tumor assessment, bone scan, and bone survey were performed. Pain and analgesic scores were assessed at baseline and then at 1 and 3 months. A dental assay, performed in order to reduce the risk of development of osteonecrosis of the jaw (ONJ), was performed at baseline and then every 3 months.

Tumors were evaluated every 3 months according to the Response Evaluation Criteria in Solid Tumors (RECIST) [20]. Skeletal-related events (SRE), including pathologic fracture, spinal cord compression, radiation therapy to bone, or surgery to bone, were recorded at each visit every 4 weeks.

Statistical analysis

Assuming about a 70% decrease in s-CTX at 3 months of treatment with ZOL in patients with bone metastases, the study required the enrollment of at least 26 patients per treatment group with 90% power to detect a 15% difference in the median percentage change in s-CTX between ZOL and oral IBA at 3 months of treatment [21]. Secondary end-points were bone pain and the proportion of patients with at least a SRE; time to first SRE, time to progression of bone metastases, and overall survival were determined using the Kaplan–Meier method, and treatment groups were compared using the log-rank test.

The comparison of the median percentage change from baseline of bone markers during the observation period between the two groups was achieved using the Mann–Whitney test. All tests were two-sided with a significance level of 0.05.

Results

From April 2005 to May 2010, 55 patients with NSCLC and bone metastases were enrolled in the study and randomly assigned to receive ZOL or oral IBA; 53 received at least 3 months of treatment and were considered evaluable (2 patients in the ZOL group received less than 2 months of treatment because of reasons unrelated to treatment). The two treatment groups were well balanced for age, performance status, pain score, number and type of bone metastases, anticancer therapies, and baseline median values of the bone markers s-CTX and B-ALP (Table 1).

Table 1 Baseline characteristics

	ZOL	IBA
Enrolled patients	28	27
Evaluable patients	26	27
Median age, years (range)	69 (55–79)	71 (62–78)
Male	22	19
Female	6	8
No of bone lesions		
>3	15	16
≤3	13	11
≥2 Metastatic sites	23	25
Predominant lytic	26	25
Predominant blastic	2	2
SRE before treatment	1	1
s-CTX (ng/ml) (range)	0.94 (0.18–2.95)	0.91 (0.22–3.16)
B-ALP (IU/L) (range)	24.8 (8.66–72.12)	32.1 (12.3–89.5)
Pain score	1.98 ± 1.12	1.88 ± 0.89
Chemotherapy		

	ZOL	IBA
CDDP/GEM	14	16
CDDP/VBN	4	3
CDDP/GEM + BEV	10	8

S-CTX and B-ALP are expressed as median values, and pain score as mean \pm standard deviation (SD)
CDDP/GEM cisplatin and gemcitabine, *CDDP/VBN* cisplatin and vinorelbine, *BEV* bevacizumab

Of 26 assessable patients in the ZOL group, 18 (69.2%) and 15 (57.6%) had baseline s-CTX and B-ALP above the normal range, respectively. Of 27 assessable patients in the IBA group, 20 (74.0%) and 17 (62.9%) had baseline s-CTX and B-ALP above the normal range, respectively.

At 1 month of treatment, S-CTX was reduced by 54.8% (95% CI 40.4–59.8%) below the baseline in the ZOL group, compared with 38.2% (95% CI 29.8–48.7%) in the oral IBA group ($p = 0.03$). At 3 months, CTX was reduced by 72.6% (95% CI 58.6–71.3%) in the ZOL group, compared with 66.4% (95% CI 54.3–79.5%) in the oral IBA group ($p = 0.22$) (Fig. 1).

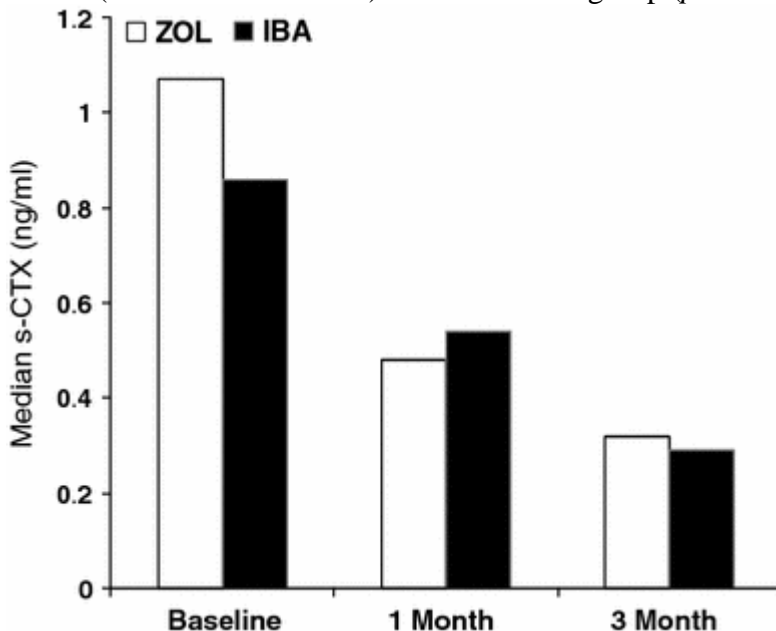


Fig. 1 Median percentage decreases in s-CTX levels with zoledronic acid (ZOL) and oral ibandronate (IBA) at 1 and 3 months of treatment

At 3 months, in patients who had elevated baseline s-CTX levels, ZOL and oral IBA normalized the bone resorption marker in 84.6 and 77.7% of patients, respectively.

Both bisphosphonates similarly decreased the bone marker B-ALP at 1 month (ZOL 24.7%, 95% CI 3.6–39.5%, and IBA 26.1%, 95% CI 2.8–43.4%) and 3 months (ZOL 28.6%, 95% CI +2.8–43.3%, and IBA 24.2%, 95% CI 3.2–47.4%) (Fig. 2).

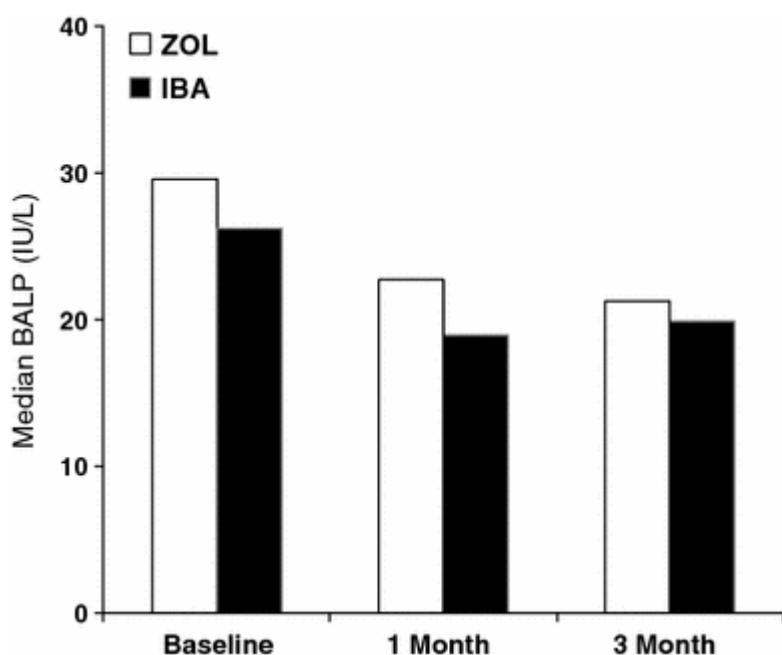


Fig. 2 Median percentage decreases in B-ALP levels with zoledronic acid (ZOL) and oral ibandronate (IBA) at 1 and 3 months of treatment

At 3 months, 12 patients (52.1%) in the ZOL group and 14 patients (56.0%) in the IBA group showed responses of metastases in parenchymatous organs as evaluated by RECIST criteria. At 6 months, bone scan and other imaging techniques could be performed in 49 patients, and these suggested a partial response of bone lesions in 8 patients (34.7%) in the ZOL group and 10 patients (38.4%) in the IBA group.

All 53 evaluable patients were assessable for pain and analgesic use at 1 and 3 months. At 1 month there was a trend for a more rapid decrease in bone pain score in favor of the ZOL group (41.6 vs. 29.3%; $p = 0.05$), while the maximum pain relief was achieved at 3 months and was similar in the ZOL and IBA groups (66.2 vs. 61.8%; $p = 0.31$). At 3 months, a decrease in pain score of ≥ 2 points without any increase in analgesic consumption in patients with a baseline pain score ≥ 2 was observed in 11/18 (61.1%) patients in the ZOL group and 9/16 (56.2%) patients in the IBA group.

There was no significant difference between the two treatment groups in the proportion of patients with a new SRE: after a median observation time of 14.5 months, 5 (19.2%) patients in the ZOL group and 7 (25.9%) in the IBA group had skeletal complications. The most common SREs were a need for radiation to the bone for pain relief and pathologic fracture: the median time to first SRE was 10.2 months (range 4.6–14.3) in the ZOL group and 9.4 months (range 5.7–16.1) in the IBA group ($p = 0.034$) (log-rank test).

Both bisphosphonates were well tolerated. The most common adverse events, considered treatment-related by the investigators, were bone pain, nausea, constipation, dyspnea, fatigue, and gastrointestinal disorders. The incidence of adverse events such as pyrexia and influenza-like symptoms in the first 3 days of treatment was higher in the ZOL group than the IBA group (23.0 vs. 7.4%). One patient in the ZOL group developed ONJ after 15 months of treatment, and one patient in the IBA group had to stop taking the drug orally because of gastrointestinal disorders after 6 months of treatment. The proportion of patients with decreased renal function was slightly higher in the ZOL than the IBA group, but the difference was not statistically significant (15.3 vs. 3.7%, $p = 0.13$).

Discussion

This is the first clinical study that compares the early effects of the bisphosphonates ZOL and oral IBA on bone resorption in NSCLC patients with bone metastases. A higher initial potency of ZOL was suggested by a trend for a more rapid reduction in s-CTX levels and bone pain at 1 month compared to oral IBA ($p = 0.03$; $p = 0.05$), while at 3 months the effects of the two bisphosphonates were comparable (Fig. 1). In addition, a similar high percentage of s-CTX normalization was observed with ZOL (84.6%) and oral IBA (77.7%). The early normalization of bone resorption markers during treatment is considered an important endpoint, since it has been reported to be associated with a reduced risk of first SRE and a significant improvement in survival [22, 23]. With the limitation of the small sample size and the short follow-up, ZOL and oral IBA also appeared to be comparable in terms of SRE efficacy (19.2 vs. 25.9%). These findings suggest that it may be appropriate to start with an intravenous formulation of a potent bisphosphonate (such as ZOL or IBA) in patients with widespread and painful bone metastases from NSCLC, while oral IBA seems to achieve the same efficacy after 3 months, and thus may also be considered.

All of the analyzed patients were receiving concomitant chemotherapy, which would be expected to influence the s-CTX decrease and changes in bone pain [23, 24]. Nevertheless, the use of a concomitant effective first-line chemotherapy achieved overall response rates of 34.7 and 38.4% on bone lesions in the ZOL and IBA groups, respectively, which probably contributed to the similar clinical activities of the two bisphosphonates observed during treatment. In line with our study, recent reports suggested the role of early changes in bone resorption markers for monitoring NSCLC patients with bone metastases receiving bisphosphonates combined with chemotherapy [25, 26].

Another point to consider is that 10 patients in ZOL group and 8 patients in the IBA group received the antiangiogenic bevacizumab (Bev), which is currently approved (in combination with chemotherapy) for the first-line treatment of many solid tumors, including NSCLC [27]. Although it may be hypothesized that Bev might potentially increase the antiresorptive effects of bisphosphonates, the bone resorption marker s-CTX similarly decreased in Bev-treated patients compared to patients who were not receiving Bev. However, further studies are needed to clarify the impact on bone metabolism of the new antiangiogenic drugs when combined with chemotherapy and bisphosphonates.

The early changes in B-ALP during treatment were similar in the two treatment groups, and a substantial proportion of the patients showed a B-ALP increase at 3 months, which was associated with a response to treatment in most patients (Fig. 2). In this setting, it must be underlined that while a s-CTX increase generally reflects a progression in bone metastases, B-ALP may also increase to balance an increase in the osteolytic component, or increase as an indication of bone formation to repair bone lesions that respond to treatment [13, 24, 28, 29]. Therefore, the association of B-ALP with a response to therapy is usually less consistent than bone resorption markers, since an increase in B-ALP may have negative but also positive prognostic implications.

Our results are similar to those reported in a recent comparative study performed in patients with bone metastases from breast cancer, which demonstrated that oral IBA was statistically noninferior to ZOL in terms of percentage change in s-CTX at week 12 (76 vs. 73%). The aforementioned study suggested that oral IBA also similarly reduced bone pain and bone formation markers at week 12, while, unlike in our study, early changes in these parameters (i.e., at 1 month) were not investigated [30]. Another study reported mean reductions of >40% in the bone markers u-NTX and s-CTX in patients with metastatic bone disease treated with daily oral clodronate after 6 weeks of

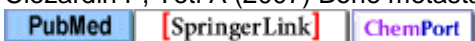
treatment [31]. However, a dose–response relationship of oral clodronate was suggested, and the commonly used 1,600 mg dose was appropriate for breast cancer patients but suboptimal for other cancers. Therefore, in the absence of randomized phase III trials, and considering changes in bone marker levels as a surrogate end-point, our results suggest that ZOL and oral IBA administered with concomitant chemotherapy have comparable efficacies in NSCLC patients and bone metastases. In patients with severe bone pain (who are able to move), widespread bone involvement and high baseline levels of bone resorption markers, the current best approach seems to be the administration of an effective anticancer treatment combined with i.v. bisphosphonates such as ZOL (or i.v. IBA), which achieves a more rapid and potent inhibition of bone resorption. Thereafter, a switch to oral IBA, which can be safely used as maintenance therapy for long periods, may be considered. In this setting, it is known that patient compliance may be a problem associated with daily oral bisphosphonates. Previous randomized trials on osteoporosis reported similar results with oral IBA to those seen in our study in terms of reduction in bone turnover markers. However, adherence to and persistence with therapy were poor, particularly with daily dosing [32, 33]. It was observed that more than half of the patients receiving daily oral bisphosphonates were not compliant and thus were at increased risk of fracture compared with compliant patients [32, 34]. However, more advanced and convenient oral bisphosphonates schedules are currently available, such as weekly and monthly administration [35]. In the current study, all patients were informed about the importance of adhering to the treatment, and compliance with oral IBA was good, with 98% of patients receiving >90% of the study drug. Both ZOL and oral IBA were well tolerated, and, as observed in other studies, the overall incidence of adverse events was lower for patients receiving IBA, particularly as for pyrexia and flu-like symptoms on days 1–3 (3.0 vs. 26.8%), while a trend for an increase in serum creatinine level was found in the ZOL group [36]. The lack of renal toxicity for oral IBA may be an advantage for patients receiving concomitant potentially nephrotoxic treatments, and/or for old patients with chronic renal failure in particular, for whom a switch to or the initial use of this drug should be considered. Other adverse events were rare, with the exception of a case of ONJ which occurred in the ZOL group and required the discontinuation of bisphosphonate treatment. In this setting, it should be underlined that all patients receiving ZOL should have an oral examination at least every 3 months, while this diagnostic procedure may be sufficient at each 6-monthly visit along with oral IBA. Although gastrointestinal toxicity may occur with oral IBA, only one subject withdrew from the treatment after 6 months due to severe gastrointestinal disorders attributed to this drug by investigators, probably due to the fact that all of the patients were well informed and followed the precautionary measures.

















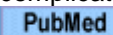

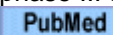












In conclusion, this study may add useful information about the effects of ZOL and oral IBA on NSCLC patients with bone metastases, and might help physicians to prescribe the most appropriate bisphosphonate based on factors such as safety and convenience. However, the sample size in this study was very small, and the observation period for the primary end-point was only 3 months, so it is difficult to draw definite conclusions about the most efficacious administration route for bisphosphonates (oral or intravenous) in the treatment of bone metastases. A longer observation period and an increased number of participants are needed to conclusively demonstrate the effects of the treatment on quality of life, continuity of reduction in bone markers, and overall survival.

Conflict of interest No author has any conflict of interest.

References

1. Clezardin P, Teti A (2007) Bone metastasis. *Clin Exp Metastasis* 24:599–608



2. Coleman RE, Purohit OP, Vinholes JJ et al (1997) High dose pamidronate: clinical and biochemical effects in metastatic bone disease. *Cancer* 80(Suppl 8):1686–1690
  
3. Lipton A (2003) Bisphosphonate therapy in the oncology setting. *Expert Opin Emerg Drugs* 8:469–488
  
4. Cameron D, Fallon M, Diel I (2006) Ibandronate: its role in metastatic breast cancer. *Oncologist* 11(Suppl 1):27–33
  
5. Major P, Lortholary A, Hon J et al (2001) Zoledronic acid is superior to pamidronate in the treatment of hypercalcemia of malignancy: a pooled analysis of two randomized, controlled clinical trials. *J Clin Oncol* 19:558–567
 
6. Berenson JR, Rosen LS, Howell A et al (2001) Zoledronic acid reduces skeletal-related events in patients with osteolytic metastases. *Cancer* 91:1191–1200
  
7. Heidenreich A, Elert A, Hofmann R (2002) Ibandronate in the treatment of prostate cancer associated painful osseous metastases. *Prostate Cancer Prostate Dis* 5:231–235
 
8. Body JJ, Diel IJ, Lichinitser MR et al (2003) Intravenous ibandronate reduces the incidence of skeletal complications in patients with breast cancer and bone metastases. *Ann Oncol* 14:1399–1405
 
9. Body JJ, Diel IJ, Lichinitzer M et al (2004) Oral ibandronate reduces the risk of skeletal complications in breast cancer patients with metastatic bone disease: results from two randomised, placebo-controlled phase III studies. *Br J Cancer* 90:1133–1137
  
10. Francini G, Gonnelli S, Petrioli R et al (1992) Treatment of bone metastases with dichloromethylene bisphosphonate. *J Clin Oncol* 10:591–598
 
11. Coleman RE (2002) The clinical use of bone resorption markers in patients with malignant bone disease. *Cancer* 94:2521–2533
 
12. Brown JE, Thomson CS, Ellis SP et al (2003) Bone resorption predicts for skeletal complications in metastatic bone disease. *Br J Cancer* 89:2031–2037
  
13. Coleman RE, Major P, Lipton A et al (2005) Predictive value of bone resorption and formation markers in cancer patients with bone metastases receiving the bisphosphonate zoledronic acid. *J Clin Oncol* 23:4925–4935
  
14. Brown JE, Cook RJ, Major P et al (2005) Bone turnover markers as predictors of skeletal complications

in prostate cancer, lung cancer, and other solid tumors. *J Natl Cancer Inst* 97:59–69



15. Hannon RA, Eastell R (2006) Bone markers and current laboratory assays. *Cancer Treat Rev* 32(Suppl 1):7–14




16. Hamaoka T, Madewell JE, Podoloff DA et al (2004) Bone imaging in metastatic breast cancer. *J Clin Oncol* 22:2942–2953



17. Melzack R (1975) The McGill Pain Questionnaire: major properties and scoring methods. *Pain* 1:277–299



18. De Benedittis G, Massei R, Nobili R et al (1988) The Italian Pain Questionnaire. *Pain* 33:53–62




19. McCormack A, Hunter-Smith D, Piotrowski ZH et al (1992) Analgesic use in home hospice cancer patients. *J Fam Pract* 34:160–164



20. Therasse P, Arbuck SG, Eisenhauer EA et al (2000) New guidelines to evaluate the response to treatment in solid tumors. *J Natl Cancer Inst* 92:216



21. Simon R, Wittes RE, Ellenberg SS (1985) Randomized phase II clinical trials. *Cancer Treat Rep* 69:1375–1381



22. Lipton A (2008) Emerging role of bisphosphonates in the clinic-antitumor activity and prevention of metastasis to bone. *Cancer Treat Rev* 34(Suppl 1):S25–S30



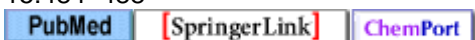
23. Aapro M, Abrahamsson PA, Body JJ et al (2008) Guidance on the use of bisphosphonates in solid tumors: recommendations of an international expert panel. *Ann Oncol* 19:420–432




24. Francini G, Petrioli R, Gonnelli S et al (2001) Urinary calcium excretion in the monitoring of bone metastases. *Cancer* 92:1468–1474



25. Kaira R, Murakami H, Kaira K et al (2010) N-telopeptide of type I collagen is useful for monitoring therapeutic response in non-small cell lung cancer patients with bone metastases. *Int J Clin Oncol* 15:484–488



26. Hirsh V, Major PP, Lipton A et al (2008) Zoledronic acid and survival in patients with metastatic bone disease from lung cancer and elevated markers of osteoclast activity. *J Thorac Oncol* 3:228–236



27. Panãres RL, Garcia AA (2007) Bevacizumab in the management of solid tumors. *Expert Rev Anticancer Ther* 7:433–445
[PubMed](#) [crossref](#)
28. Smith MR (2006) Markers of bone metabolism in prostate cancer. *Cancer Treat Rev* 32(Suppl 1):23–26
[PubMed](#) [crossref](#) [ChemPort](#)
29. Lein M, Miller K, Wirth M et al (2009) Bone turnover markers as predictive tools for skeletal complications in men with metastatic prostate cancer treated with zoledronic acid. *Prostate* 69:624–632
[PubMed](#) [crossref](#) [ChemPort](#)
30. Body JJ, Lichinitser M, Tjulandin S et al (2007) Oral ibandronate is as active as intravenous zoledronic acid for reducing bone turnover markers in women with breast cancer and bone metastases. *Ann Oncol* 18:1165–1171
[PubMed](#) [crossref](#)
31. Brown JE, McCloskey EV, Dewar JA et al (2007) The use of bone markers in a 6-week study to assess the efficacy of oral clodronate in patients with metastatic bone disease. *Calcif Tissue Int* 81:341–351
[PubMed](#) [SpringerLink](#) [ChemPort](#)
32. Briesacher BA, Andrade SE, Yood RA et al (2007) Consequences of poor compliance with bisphosphonates. *Bone* 41:882–887
[PubMed](#) [crossref](#) [ChemPort](#)
33. Cramer JA, Gold DT, Silverman SL et al (2007) A systemic review of persistence and compliance with bisphosphonates for osteoporosis. *Osteoporos Int* 18:1023–1031
34. Rabenda V, Mertens R, Fabri V et al (2008) Adherence to bisphosphonates therapy and hip fracture risk in osteoporotic women. *Osteoporos Int* 19:811–818
[PubMed](#) [SpringerLink](#) [ChemPort](#)
35. Hochberg MC, Silverman SL, Barr CE et al (2010) The utility of changes in serum levels of C-terminal telopeptide of type I collagen in predicting patient response to oral monthly ibandronate therapy. *J Clin Densitom* 13:181–189
[PubMed](#) [crossref](#)
36. Tripathy D, Body JJ, Bergström B (2004) Review of ibandronate in the treatment of metastatic bone disease: experience from phase III trials. *Clin Ther* 26:1947–1959
[PubMed](#) [crossref](#) [ChemPort](#)

