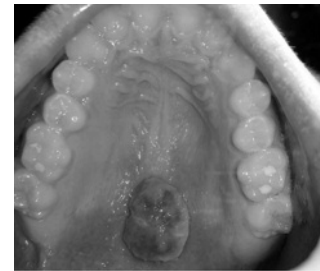


Case Report

Minimally invasive approach to eliminate pyogenic granuloma using Er, Cr: YSGG laser



M.E. Licata¹, A. Albanese¹, G. Giannatempo², M. Dioguardi², G. Campisi¹

¹Department of Surgical, Oncological and Oral Sciences, Sector of Oral Medicine "V. Margiotta", University of Palermo, Italy; ²Department of Surgical Sciences, University of Foggia, Italy

Background. PG or granuloma pyogenicum is a common tumor like growth of the oral cavity that is considered to be of non-neoplastic nature, arising commonly as a result of constant low grade trauma and poor oral hygiene and in few instances because of hormonal disturbances. Since it is a benign lesion, choice of treatment is surgical excision with removal of underlying cause if any. A newer treatment modality using laser has been reported^{1, 2}

Case report. A 16-year-old male patient reported to our sector of oral medicine with the chief complaint of intra-oral painless growth since four months. Past history and medical history did not reveal any relevant information. He was taking no medication and had no history of known drug allergy. On intra-oral examination smooth surfaced and lobulated growth of approximately 1.5 × 1 × 0.5 cm in size was present in the palate. The lesion was pedunculated and was freely movable over peduncle. The surface of the lesion showed non-homogenous red color whereas in certain area was covered by yellowish plaque like material. On palpation, growth was non-tender, nonfluctuant, hard and fibrous in consistency. Treatment plan comprising of excisional biopsy of the lesion using an Er, Cr: YSGG laser. An elliptical incision was made around the peduncle, the lesion was lifted along with the underlying periosteum from the bone surface and removed. Hemostasis was achieved with the same laser and healing was obtained for second intention. Excised specimen was preserved and sent for histopathological examination. At 7 days recall, the gingival tissues were healthy with successful healing.

Conclusion. Excisional surgery is the treatment of choice for PG. The use of laser may be a valid approach for the excision of this lesion, as it is minimally invasive and offers many clinical advantages (minimal intra-operative bleeding, hemostasis, reduced times of healing).

References

1. Rai S, Kaur M, Bhatnagar P. Laser: a powerful tool for treatment of pyogenic granuloma. *J Cutan Aesthet Surg* 2011 May; 4(2):144-7.
2. Lindenmüller IH, Noll P, Mameghani T, Walter C. Co₂ Laser-assisted treatment of a giant pyogenic granuloma of the gingiva. *Int J Dent Hyg* 2010 Aug; 8(3):249-52.