

CASE REPORT

Parasitic myomas after laparoscopic surgery: an emerging complication in the use of morcellator?

Description of four cases

Gaspare Cucinella, M.D., Ph.D.,^a Roberta Granese, M.D., Ph.D.,^b Gloria Calagna, M.D.,^a
Edgardo Somigliana, M.D., Ph.D.,^c and Antonio Perino, M.D., Ph.D.^a

^a Department of Obstetrics and Gynaecology, University Hospital "Paolo Giaccone," Palermo; ^b Department of Obstetrics and Gynaecology, University Hospital "Gaetano Martino," Messina; and ^c Department of Obstetrics and Gynaecology, Fondazione Cà Granda, Ospedale Maggiore Policlinico, Milan, Italy

Objective: To report the development of parasitic myomas after the use of a morcellator.

Design: Retrospective study.

Setting: Tertiary care referral center for the treatment of benign gynecologic pathologies.

Patient(s): Women undergoing surgery for uterine fibroids.

Intervention(s): Chart review.

Main Outcome Measure(s): Presence of parasitic leiomyomas.

Result(s): We identified four cases of parasitic myomas over the 3-year study period. Two out of the four were symptomatic. The prevalence of this complication, considering all women with whom the electric morcellator was used ($n = 423$) was 0.9% (95% CI, 0.3–2.2%). Considering exclusively the women who underwent myomectomy ($n = 321$), it was 1.2% (95% CI, 0.4–2.9%).

Conclusion(s): Laparoscopic myomectomy with the use of a morcellator is associated with an increased risk of developing of parasitic myomas. A thorough inspection and washing of the abdominopelvic cavity at the end of the surgery should be performed to prevent this rare complication. (Fertil Steril® 2011;96:e90–6. ©2011 by American Society for Reproductive Medicine.)

Key Words: Fibroid, laparoscopy, leiomyoma, morcellator, parasitic myoma

Parasitic myomas are rare pathologic phenomena, and although they have been known for some time (1), their etiopathogenesis is still uncertain. The classic view is that these lesions arise from pedunculated subserosal myomas that have for some reason, such as a torsion around its peduncle (2), become partially or completely separated from the uterus and started to receive an alternative blood supply from another source, such as omental or mesenteric vessels (2–7). An alternative pathogenetic mechanism is that these lesions may develop from metaplasia of the peritoneum. This appears particularly likely for leiomyomatosis peritonealis disseminata (8, 9).

In very recent years, a third intriguing pathogenetic mechanism with an iatrogenic origin has emerged. There have been some reports of parasitic leiomyomas in the peritoneum after laparoscopic myomectomies or hysterectomies with the use of electric tissue morcellator (10–17). In an attempt to shed light on this singular pathologic

condition, we present four cases of iatrogenic parasitic myomas that occurred after laparoscopic procedures and a review of the literature on the topic.

MATERIALS AND METHODS

All patients undergoing surgery in the Gynaecological and Obstetrics Department of the Policlinico Hospital of Palermo between April 2007 and March 2010 were reviewed to identify those in whom parasitic leiomyomas had been detected. Our unit is a tertiary care referral center for Western Sicily for the treatment of benign gynecologic pathologies. During the study period, 256 laparoscopic hysterectomies and 345 laparoscopic myomectomies were performed. The morcellator was used in 102 (40%) and 321 (93%) cases, respectively. The indications for surgery were the presence of pelvic pain or abnormal uterine bleeding caused by different sizes or numbers of myomas or for a fibromatous uterus, refractory to medical treatment. An electric Steiner Morcellator (Karl Storz) with 15-mm bladders was used when the size of the myoma exceeded 3 cm or after a subtotal hysterectomy.

All patients in our unit routinely give informed consent for the use of their data for research purposes. The study was approved by the local institutional review board.

Received February 12, 2011; revised May 15, 2011; accepted May 31, 2011; published online June 29, 2011.

G.C. has nothing to disclose. R.G. has nothing to disclose. G.C. has nothing to disclose. E.S. has nothing to disclose. A.P. has nothing to disclose.

G.C. and R.G. contributed equally to this article.

Reprint requests: Roberta Granese, M.D., Ph.D., Via Ducezio 15, Residence 74, 98124, Messina, Italy (E-mail: robertagr74@gmail.com).

We also carried out a review on parasitic leiomyomas after laparoscopic myomectomy or hysterectomy. To this end, we identified all English language medical papers published in the period 1990 to 2010 that are available on the PubMed electronic database.

RESULTS

We identified four cases of parasitic myomas that were diagnosed and treated in our department over the 3-year study period. The main characteristics of these cases are reported in Table 1. These patients had previously undergone laparoscopic myomectomy with an electric tissue morcellator used to extract the lesions. None of them had received gonadotropin releasing-hormone (GnRH) agonists preoperatively before laparoscopic myomectomy. When we considered all women who had undergone surgery with the use of an electric morcellator ($n = 423$), the prevalence of this complication was 0.9% (95% CI, 0.3–2.2%). Considering exclusively those who had undergone laparoscopic myomectomy with the use of a morcellator ($n = 321$), it was 1.2% (95% CI, 0.4–2.9%).

Two women (patients 1 and 3) underwent a laparotomic total hysterectomy after the initial laparoscopic myomectomy and before the subsequent diagnosis of the parasitic myomas (see Table 1). The average time between the initial laparoscopic myomectomy and the identification of the parasitic myomas was 69 months (range: 24 to 108 months). In patient 2, a pregnancy occurred during the latent period. Two out of four patients were symptomatic (see Table 1). In one case, the lesion was identified during the caesarean section; in the remaining three cases, the masses were diagnosed through ultrasound. In patient 1, magnetic resonance imaging was deemed necessary to confirm the diagnosis (Fig. 1). This first case also was investigated with laparoscopy as it was our first experience with the condition. In patient 4, the parasitic masses were found in conjunction with a symptomatic uterine fibroid. The number of lesions varied from one to five. The most frequent localizations were the pelvic parietal peritoneum, the anterior parietal peritoneum at the level of the abdomen recto muscles, and along the gastrointestinal tract. Others localizations included the left paracolic fossa and the peritoneum at the level of the promontory of sacrum. In three cases, removal was successfully achieved through laparoscopic surgery, and the morcellation was performed inside an endoscopic bag; in the case detected during the caesarean section, removal was through the laparotomic incision. No intrasurgical or postsurgical complications were observed. Histologic analyses on all samples confirmed the diagnosis of benign leiomyomas. Representative cases are illustrated in Figures 2 through 5.

Our review of the literature identified 13 published studies (10–16, 18–22). Nine were single case reports, two referred to two cases each, one referred to four cases, and only one reported on a case series of 10 women. Nine of the 13 studies were published within the last 5 years (since 2005). The main results of these studies are shown in Table 2.

Based on all the cases (including those from our report), we found the most common symptoms were abdominal and pelvic pain, a sense of a mass in the abdomen, and deep dyspareunia. In 29 (93%) of 31 women, the lesions were identified after a laparoscopic approach (95% CI, 81–99%); in 21 (68%) patients after a myomectomy (95% CI, 51–82%), and in 8 (26%) patients after a hysterectomy (95% CI, 13–42%). A morcellator was used in 27 (87%) of 31 women (95% CI, 73–96%). Lesions were commonly multiple and located either in the pelvis (70%) or abdomen (28%) and vagina

TABLE 1

Main characteristics of the patients with parasitic myomas.

Patient	First surgery			Surgery for parasitic myoma					
	Parity	Age (y)	Intervention	Use of morcellator	Age (y)	No. pregnancies since first surgery	Months since first surgery	Symptoms	Number (diameters)
Case 1	4	34	LPS myomectomy, then LPT hysterectomy ^a	Yes	41	0	72	Abdominal mass, abdominal/pelvic pain	3 (60, 45, and 15 mm)
Case 2	0	33	LPS myomectomy	Yes	35	1	24	No symptoms	1 (18 mm)
Case 3	0	27	LPS myomectomy, then LPT hysterectomy ^a	Yes	36	0	108	Dyspareunia, left-side tenderness	5 (35, 25, 7, 5, and 4 mm)
Case 4	1	42	LPS myomectomy	Yes	48	0	72	No symptoms	2 (60 and 43 mm)

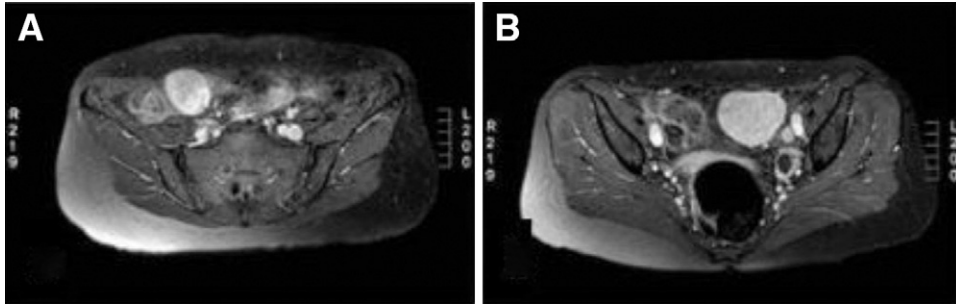
Note: LPS = laparoscopic; LPT = laparotomic.

^a In both cases, hysterectomy was performed 24 months after myomectomy.

Cucinella. Parasitic myomas. Fertil Steril 2011.

FIGURE 1

(A, B) Magnetic resonance images of three parasitic peritoneal leiomyomas, which had a clear reaction to the contrast agents (case 1).



Cucinella. Parasitic myomas. Fertil Steril 2011.

(2%). An interval since surgery of more than 2 years was found in 73%. Multiple lesions were referred in 13 (45%) of 29 patients (95% CI, 28–62%). The histology was invariably benign (100%).

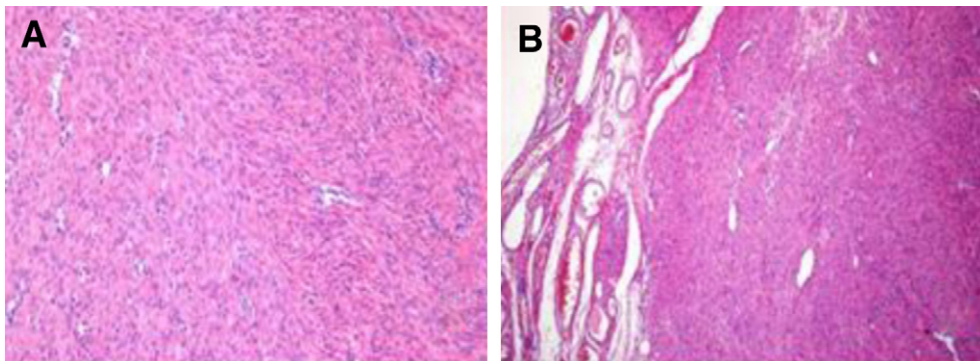
DISCUSSION

The progressive diffusion of laparoscopic surgery in gynecology and the consequent improvement of laparoscopic armamentarium could explain the recent rise in reported cases of parasitic myomas (10–16, 20–22, 24). The development of electric tissue morcellators in particular was crucial as it permits shrinking the lesions into small fragments and removing them through a tiny incision made in the abdominal wall. In this way, there is the possibility that these fragments may implant themselves in the abdominopelvic cavity and subsequently develop into a large fibroid (10–14, 19). The observation that lesions are located mostly in the pelvis supports this interpretation, as the fragments are expected to move to the lower part of the abdomen because of gravity. It is intriguing that leiomyoma cells seem to show the same behavior as endometriotic cells implanted after retrograde menstruation (23).

Indirectly, the fact that most publications on this topic are very recent further supports the iatrogenic theory (6, 11–14, 16–18, 20). In fact, these publications reflect the recent diffusion of laparoscopic myomectomy throughout the world. It is likely that the more this technique is used, the higher the frequency of parasitic fibroids will become. In our study, using all the women treated with a morcellator as a denominator, the prevalence was 0.9% (95% CI, 0.3–2.2%). It raised to 1.2% (95% CI, 0.4–2.9%) when we exclusively focused on women who had undergone laparoscopic myomectomy with a morcellator; in our experience, all parasitic fibroids developed after this procedure. The frequency of this event should, however, be interpreted with caution because the number of observed cases cannot be related to the number of interventions performed with the use of a morcellator during the study period because this complication may arise several years after surgery; moreover, some asymptomatic cases may be missed. A reliable estimate would require prospective studies with long-term follow-up observation.

FIGURE 2

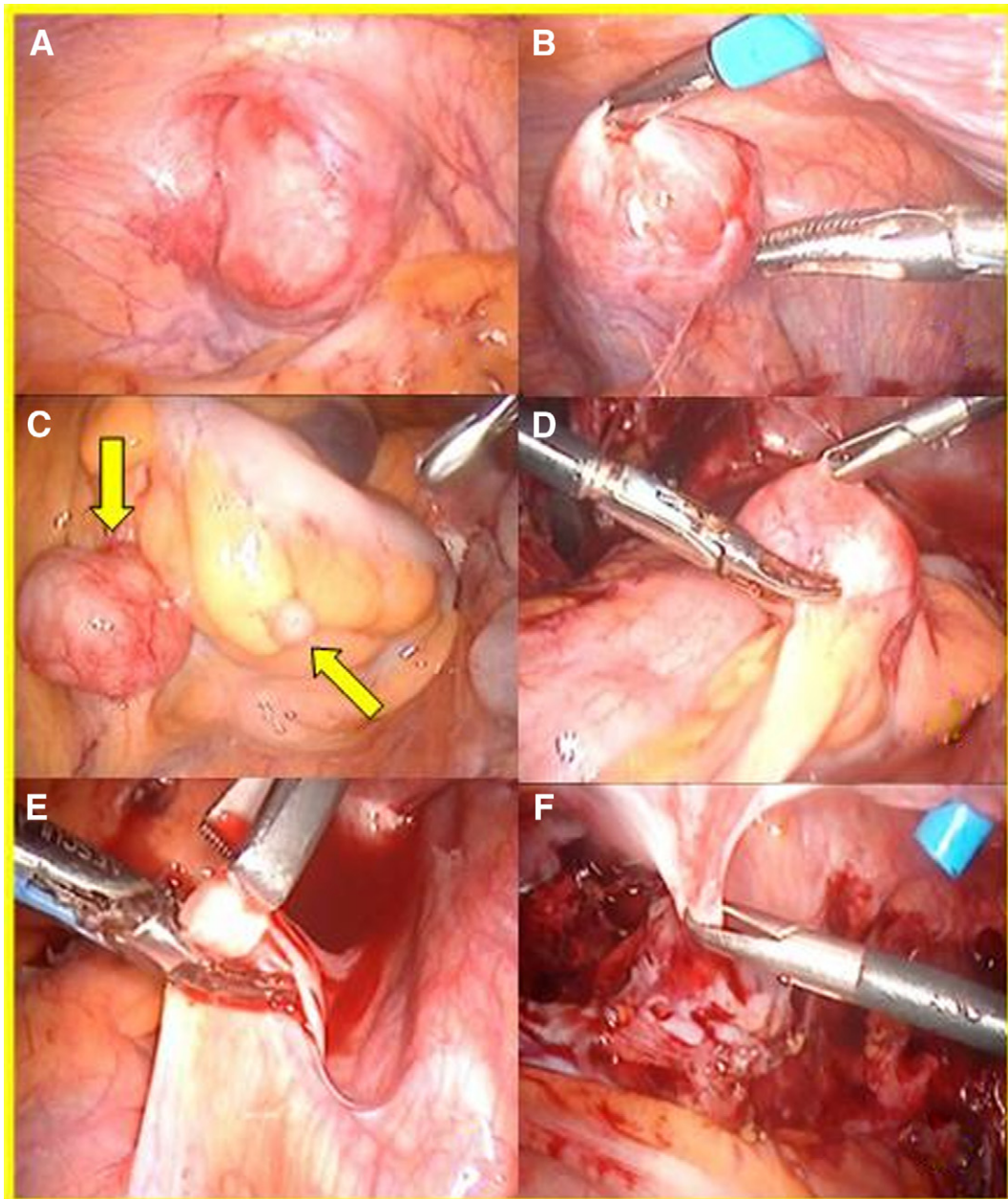
(A, B) Histologic tissue image (hematoxylin and eosin staining) of a small myoma found in the anterior parietal peritoneum at the right rectal muscle (case 2).



Cucinella. Parasitic myomas. Fertil Steril 2011.

FIGURE 3

(A–F) Laparoscopic images of the leiomyomas. The largest mass was located on the left paracolic fossa. The second seems to have originated in the mesosigmoid. The third attached to the omental appendage of the rectosigma. An additional two smaller formations were found at the peritoneal level of the sacral promontory, adhering to the anterior parietal peritoneum of the right rectal muscle (case 3).



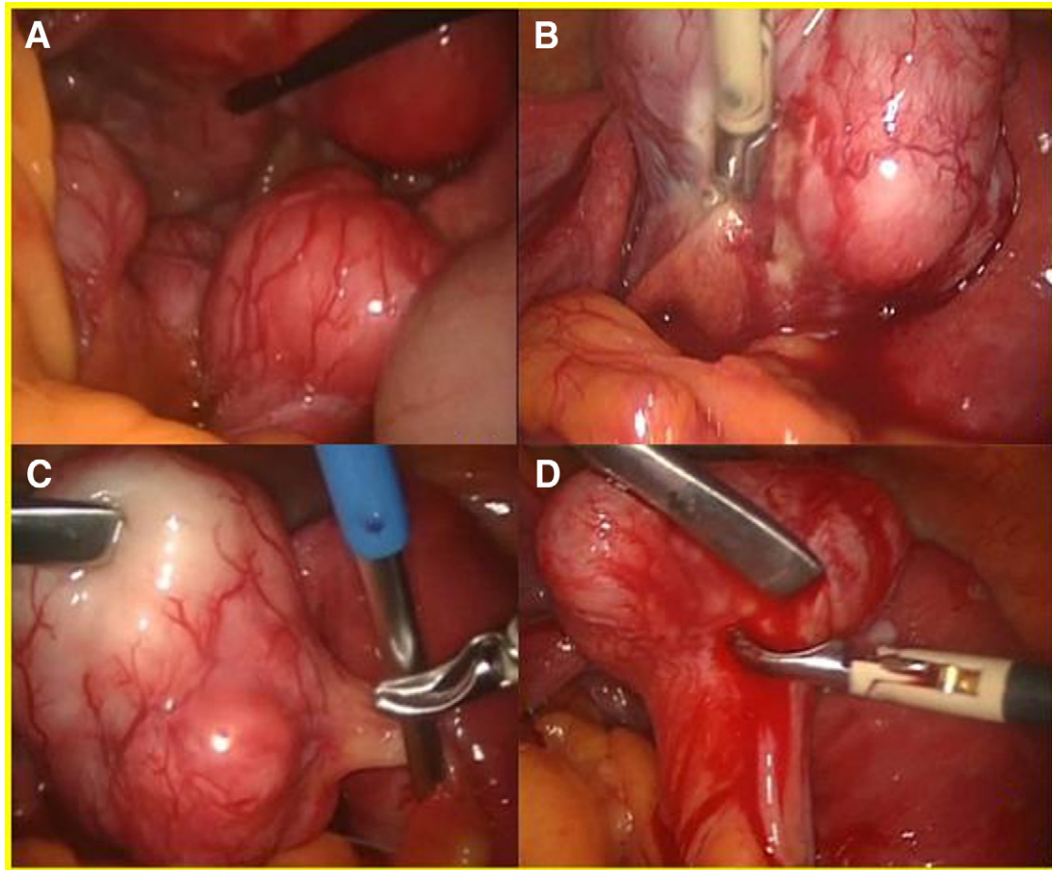
Cucinella. Parasitic myomas. Fertil Steril 2011.

Overall, our study corroborates the theory of the iatrogenic origin of at least some parasitic fibroids (24). Of relevance here is the fact that this complication is not frequent, whereas the loss of tissue fragments within the abdominal cavity during morcellation is presumably extremely common, if not systematic. For this reason, it seems reasonable to hypothesize that

other factors may contribute to the occurrence of this complication (15, 22). Exposure of fragments to steroid hormones and growth factors may play a role (22). It is interesting that in our series the time between the previous laparoscopic surgery and the diagnosis of parasitic myomatosis was shorter in the case of the patient who became pregnant soon after surgery.

FIGURE 4

(A–D) Laparoscopic images of leiomyomas. Two highly vascularized formations were located in the pouch of Douglas, without uterine connection. The first mass had been drawing both from the vascular peduncle in the original site and from a branch of the omental flap adhering to the fibroma itself. The second formation originated from the serosal surface of the sigmoid colon (case 4).



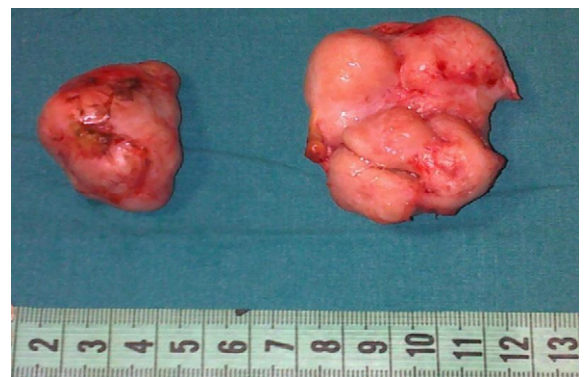Cucinella. Parasitic myomas. *Fertil Steril* 2011.

This could be related to typical immunologic and hormonal changes in pregnancy (25).

Even though our findings are speculative, we believe that they have some clinical implications. They emphasize the importance of an accurate use of the electric morcellator. A thorough inspection along with abundant and repeated washing and aspiration in the abdominopelvic cavity at the end of surgery is important to remove all fragments. Patients must be informed about this risk, and physicians should be aware of it. It is interesting that we found no serious clinical complications associated with the presence of parasitic myomas, and their histology was invariably benign; in our opinion, surgery must be considered mandatory in symptomatic cases, when there is progressive growth of the lesions, or when parasitic myomas are identified during other surgical procedures. Moreover, if surgery is decided on, a conservative intervention should be adopted. In these cases, we suggest a laparoscopic approach with the use of an endoscopic bag if the morcellation of the fibroids is considered.

FIGURE 5

The two leiomyomas removed (case 4).



Cucinella. Parasitic myomas. *Fertil Steril* 2011.

TABLE 2**Review of the literature on parasitic myomas after laparoscopic surgery.**

Study	No. of cases	Previous surgery	Use of morcellator	Months since first surgery	Symptoms	No. of myomas (diameter)	Location	Histology
Ostrzenski et al., 1997 (10)	1	LPS myomectomy	No	2	Incisional pain and mass	1 (8 mm)	Abdominal (1)	Leiomyoma
Donnez and Nisolle, 2001 (18)	2	LPS subtotal hysterectomy	Yes	NR	Deep dyspareunia	NR	Pelvic (small piece of morcellated uterus)	Leiomyoma
La Coursiere et al., 2005 (19)	1	LPS hysterectomy	Yes	10	Dyspareunia, dysuria, pelvic pain	4 (37, 37, 37, and 27 mm)	Pelvic (3) and abdominal (1)	Leiomyoma-cervical tissue
Paul and Koshy, 2006 (11)	1	LPS myomectomy	Yes	30	None	3 (NR)	Pelvic (1) and abdominal (2)	Leiomyoma
Takeda et al., 2007 (13)	1	LPS myomectomy	Yes	72	None	5 (60, 40, 45, 35, and 10 mm)	Pelvic (4) and abdominal (1)	Leiomyoma
Sinha et al., 2007 (7)	2	LPS myomectomy then hysterectomy/LPS hysterectomy	Yes	36 and 8	Abdominal mass (both), pain in 1 case	3 (150, 70, and 80 mm) and 1 (100 mm)	Pelvic (4)	Leiomyoma
Moon et al., 2008 (20)	1	LPS myomectomy	Yes	36	Abdominal mass	1 (25 mm)	Abdominal (1)	Leiomyoma
Kumar et al., 2008 (14)	1	LPS myomectomy	Yes	9	Abdominal distension, breathlessness	7 (250 mm, others 20–30 mm)	Pelvic (6) and abdominal (1)	Leiomyoma
Kho and Nezhat, 2009 (15)	10	LPS myomectomy (6), LPT myomectomy (2), LPS hysterectomy (2)	8 cases	75 (range: 2–204)	Pain, menorrhagia, dyspareunia, pelvic pressure	15 (diameters carrying between 30 and 120 mm)	Pelvic (14) and abdominal (1)	Leiomyoma
Epstein et al., 2009 (21)	1	LPS myomectomy	Yes	27	Pelvic pain, pelvic pressure	2 (30, 80 mm)	Abdominal (2)	Leiomyoma
Wada-Hiraike et al., 2009 (24)	1	LPS assisted myomectomy	No	48	Abdominal mass	1 (105 × 95 × 60 mm)	Abdominal (1)	Leiomyoma
Pezzuto et al., 2010 (22)	1	LPS myomectomy	Yes	132	None	2 (50 and 30 mm)	Pelvic (2)	Leiomyoma
Larrain et al., 2010 (16)	4	LPS myomectomy (2), LPS hysterectomy (2)	Yes	99 (range: 36–192)	Pelvic pain (2 cases), mass in vagina (1 case)	4 (diameters carving between 40 and 70 mm)	Pelvic (3), vaginal (1)	Leiomyoma (in 1 case infiltrated by endometrial glands)

Note: The indication for hysterectomy was fibroids and metrorrhagia in all cases. Locations were divided in two groups: [1] pelvic locations that included the pouch of Douglas, pelvic wall, vesicouterine pouch, rectum, and sigmoid mesentery, and [2] abdominal location that included myomas of the intestine above the sigma, omentum, abdominal wall, and upper abdomen. LPS = laparoscopic; LPT = laparotomic; NR = not reported.

Cucinella. Parasitic myomas. Fertil Steril 2011.

1. Kelly HA, Cullen TS. Myomata of the uterus. Philadelphia: WB Saunders; 1909:13.
2. Yeh HC, Kaplan M, Deligdisch L. Parasitic and pedunculated leiomyomas: ultrasonographic features. *J Ultrasound Med* 1999;18:789–94.
3. Brody S. Parasitic fibroid. *Am J Obstet Gynecol* 1953;65:1354–6.
4. Gowri V, Sudheendra R, Oumachigui A, Sankaran V. Giant broad ligament leiomyoma. *Int J Gynaecol Obstet* 1992;37:207–10.
5. Brieger GM, MacGibbon AL, Peat BP. Torsion of a parasitic fibroid. *Aust NZ J Obstet Gynaecol* 1995;35:224–5.
6. Hutchins FL, Reinhoehl EM. Retained myoma after laparoscopic supracervical hysterectomy with morcellation. *J Am Assoc Gynecol Laparosc* 1998;5:293–5.
7. Sinha R, Hegde A, Mahajan C. Parasitic myoma under the diaphragm. *J Minim Invasive Gynecol* 2007;14:1.
8. Bekkers RL, Willemsen WN, Schijf CP, Massuger LF, Bulten J, Merkus JM. Leiomyomatosis peritonealis disseminata: does malignant transformation occur? A literature review. *Gynecol Oncol* 1999;75:158–63.
9. Vaquero ME, Magrina JF, Leslie KO. Uterine smooth-muscle tumors with unusual growth patterns. *J Minim Invasive Gynecol* 2009;16:263–8.
10. Ostrzensky A. Uterine leiomyomata particle growing in an abdominal-wall incision after laparoscopic retrieval. *Obstet Gynecol* 1997;89:853–4.
11. Paul PG, Koshy AK. Multiple peritoneal parasitic myomas after laparoscopic myomectomy and morcellation. *Fertil Steril* 2006;85:492–3.
12. Sinha R, Sundaram M, Mahajan C, Sambhus A. Multiple leiomyomas after laparoscopic hysterectomy: report of two cases. *J Minim Invasive Gynecol* 2007;14:123–7.
13. Takeda A, Mori M, Sakai K, Mitsui T, Nakamura H. Parasitic peritoneal leiomyomatosis diagnosed 6 years after laparoscopic myomectomy with electric tissue morcellation: report of a case and review of the literature. *J Minim Invasive Gynecol* 2007;14:770–5.
14. Kumar S, Sharma JB, Verma D, Gupta P, Roy KK, Malhotra N. Disseminated peritoneal leiomyomatosis: an unusual complication of laparoscopic myomectomy. *Arch Gynecol Obstet* 2008;278:93–5.
15. Kho KA, Nezhad C. Parasitic myomas. *Obstet Gynecol* 2009;114:611–5.
16. Larrain D, Rabischong B, Khoo CK, Botchorishvili R, Canis M, Mage G. “Iatrogenic” parasitic myomas: unusual late complication of laparoscopic morcellation procedures. *J Minim Invasive Gynecol* 2010;17:719–24.
17. Nezhad C, Kho K. Iatrogenic myomas: new class of myomas? *J Minim Invasive Gynecol* 2010;17:544–50.
18. Donnez J, Nisolle M. LASH: laparoscopic subtotal hysterectomy. In: Donnez J, editor. *An atlas of operative laparoscopy and hysteroscopy*. 2nd ed. Pearl River, NY: Parthenon; 2001:238.
19. La Coursiere DY, Kennedy J, Hoffmann CP. Retained fragments after total laparoscopic hysterectomy. *J Minim Invasive Gynecol* 2005;12:67–9.
20. Moon HS, Koo JS, Park SH, Park GS, Choi JG, Kim SG. Parasitic leiomyoma in the abdominal wall after laparoscopic myomectomy. *Fertil Steril* 2008;90:1201.e1–2.
21. Epstein JH, Nejat EJ, Tsai T. Parasitic myomas after laparoscopic myomectomy: case report. *Fertil Steril* 2009;91:932.e13–4.
22. Pezzuto A, Pontrelli G, Ceccaroni M, Ferrari B, Nardelli GB, Minelli L. Case report of asymptomatic peritoneal leiomyomas. *Eur J Obstet Gynecol Reprod Biol* 2010;148:205–6.
23. Vercellini P, Abbiati A, Vignani P, Somigliana ED, Daguati R, Meroni F, Crosignani PG. Asymmetry in distribution of diaphragmatic endometriotic lesions: evidence in favour of the menstrual reflux theory. *Hum Reprod* 2007;22:2359–67.
24. Wada-Hiraike O, Yamamoto N, Osuga Y, Yano T, Kozuma S, Taketani Y. Aberrant implantation and growth of uterine leiomyoma in the abdominal wall after laparoscopically assisted myomectomy. *Fertil Steril* 2009;92:1747.e13–5.
25. Das C, Kumar VS, Gupta S, Kumar S. Network of cytokines, integrins and hormones in human trophoblast cells. *J Reprod Immunol* 2002;53:257–68.