

Systematic review: macrophage activation syndrome in inflammatory bowel disease

W. Fries*, M. Cottone[†] & A. Cascio[‡]

*Clinical Unit for Chronic Bowel Disorders, Department of Internal Medicine, IBD-unit Messina, University of Messina, Messina, Italy.

[†]Clinical Unit of Internal Medicine 2, United Hospitals Villa Sofia-Cervello, University of Palermo, Palermo, Italy.

[‡]Tropical and Parasitological Diseases Unit, Department of Human Pathology, IBD-unit Messina, AILMI (Italian Association for the Control of Infectious Diseases), University of Messina, Messina, Italy.

Correspondence to:

Dr W. Fries, Clinical Unit for Chronic Bowel Disorders, Department of Internal Medicine, Policlinico "G. Martino", Via Consolare Valeria, 1 98125 Messina, Italy.
E-mail: fwalter@unime.it

Publication data

Submitted 30 September 2012
First decision 19 October 2012
Resubmitted 12 March 2013
Accepted 13 March 2013

This uncommissioned systematic review was subject to full peer-review.

SUMMARY

Background

Recently, there have been increasingly frequent reports on the occurrence of macrophage activation syndrome (MAS) in patients with inflammatory bowel disease (IBD). Clinically, MAS is characterized mainly by fever, hepatosplenomegaly, cytopenia, and elevated circulating ferritin and CD25. Mortality, even if diagnosed rapidly, is high.

Aim

To identify all reports on MAS in IBD and to establish data on triggering agents, immunosuppression leading to MAS, and mortality.

Methods

A language unrestricted search on Pubmed and Scopus relating to the past 30 years was carried out by matching the following search-terms: h(a)emophagocytic lymphohistiocytosis OR h(a)emophagocytic lymphohistiocytic syndrome OR macrophage activation syndrome OR opportunistic infections OR cytomegalovirus OR Epstein-Barr virus AND Crohn's disease OR ulcerative colitis OR inflammatory bowel disease(s).

Results

Fifty cases were identified with an overall mortality of 30%. Virus-related MAS associated with cytomegalovirus or Epstein-Barr virus infections represents the main type of MAS, but in isolated cases bacterial infections precipitated the syndrome. In four cases (8%), a lymphoma was present at the time of MAS diagnosis or developed shortly thereafter. Thiopurine monotherapy was given before MAS onset in 56% of the patients, whereas multiple immunosuppression, including biologics, was administered to 24%.

Conclusions

In IBD patients, the syndrome appears to be triggered by infections, but genetic susceptibility may contribute to its development. Since immunosuppressive therapy represents the backbone of therapeutic interventions in IBD, with the risk of new, or the reactivation of latent infections, even more frequent cases of macrophage activation syndrome may be expected.

Aliment Pharmacol Ther

INTRODUCTION

Macrophage activation syndrome (MAS) or Hemophagocytic lymphohistiocytosis (HLH) is a life-threatening clinical syndrome characterised by high grade non-remitting fever, cytopenias affecting at least two of three lineages in peripheral blood, and hepatosplenomegaly associated with biochemical abnormalities, such as high circulating levels of serum ferritin, soluble interleukin-2 receptor (sCD25), and triglycerides, together with a decrease of circulating NK activity. Liver involvement is more frequent in pediatric cases but may be present in adults with variable levels of transaminases up to signs of acute liver failure and coagulopathy. Respiratory distress is frequently present and respiratory insufficiency represents a negative prognostic sign and may need assisted ventilation. The key feature of MAS is the presence of hemophagocytic CD163 + ve macrophages (HPC) in bone marrow (Figure 1) or lymph-node aspirates.

Diagnosis is based on the fulfillment of a series of criteria established in 2004¹ (Table 1) for HLH associated with autosomal recessive disorders (familial HLH, fHLH) that lead to defects involving perforin,² a molecule implicated in apoptosis induction of virus-infected cells or tumor cells by cytolytic immune cells such as natural killer (NK) cells or cytotoxic T lymphocytes (CTL). Other mutations have been identified on the UNC13D gene, that encodes for Munc13-4, a protein involved in perforin delivery to target cells,³ and the genes of syntaxin 11 or Munc18-2, both proteins which regulate and control membrane fusion.⁴ Other genetically determined

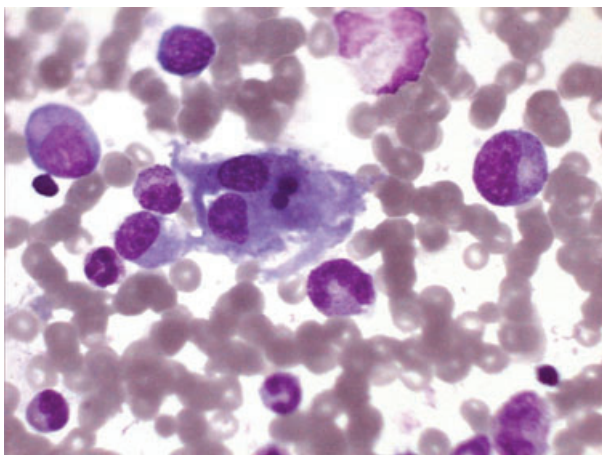


Figure 1 | Haemophagocytosis in bone marrow macrophages (from case report Palermo) (Giemsa stain; original magnification 1000×).

disorders associated with defects of cytotoxic activities of NK or CTL cells (Griscelli syndrome,⁵ Chediak-Higashi syndrome,⁶ Hermansky-Pudlak syndrome type II,⁷ and X-linked lymphoproliferative syndrome type 1⁸ and type 2⁹) are due to mutations of proteins involved in intracellular trafficking of granules, sorting, transporting, docking, membrane fusion etc. (for review see ref 4). The secondary form of HLH, also called MAS (synonyms: reactive MAS, secondary HLH), is an acquired form of HLH associated with chronic inflammatory diseases, especially rheumatic disorders, and is triggered by a variety of infectious agents ranging from viruses, bacteria, and fungi to protozoa. Moreover, MAS has been observed in immunocompromised patients, regardless of the cause of immunosuppression: pharmacologic, infectious, or neoplastic (neoplasia/lymphoma-related HLH). An apparent hybrid situation is present in systemic juvenile idiopathic arthritis (sJIA)¹⁰ where MAS belongs to the clinical picture of disease being present in a subclinical form in 30–40% of patients, whereas the overt form occurs in 10–20%. In sJIA, several mutations have been reported very recently, not only in the perforin gene,¹¹ different from those involved in primary HLH, but also in the IRF5 gene,¹² a factor involved in transcription of toll-like receptor activation, especially in the virus-mediated signalling pathways.¹³ In at least 50% of sJIA patients with MAS, the search for Cytomegalovirus (CMV)- or Epstein-Barr virus (EBV)-DNA yielded positive results,^{14, 15} thus emphasizing the role of additional infectious or other co-factors precipitating MAS.

Macrophage activation syndrome (MAS) complicating inflammatory bowel diseases (IBD) has received little attention in literature, but the increasing frequency of reported cases led us to systematically review this issue in order to identify precipitating factors such as immunosuppressive therapy, infectious agents, and outcome. We use the term MAS in order to keep it distinct from familial HLH.

METHODS

A computerized search without language restriction was conducted on literature of the past 30 years (PubMed, Scopus, and within reviews). Due to the variety of names used for the syndrome, a combination of terms was used: h(a)emophagocytic lymphohistiocytosis OR h(a)emophagocytic lymphohistiocytic syndrome OR macrophage activation syndrome OR opportunistic infections OR cytomegalovirus OR Epstein-Barr virus AND Crohn's disease OR ulcerative colitis OR inflammatory bowel disease(s).

Table 1 | Hemophagocytic lymphohistiocytosis (HLH) 2004, Diagnostic criteria for familial haematophagocytosis (from ref.¹)

The diagnosis of HLH can be established if either 1 or 2 below is fulfilled:

1	A molecular diagnosis consistent with HLH
2	Diagnostic criteria for HLH are fulfilled (five out of the eight criteria below):
	Fever
	Splenomegaly
	Cytopenias (affecting ≥ 2 lineages in the peripheral blood):
	Hemoglobin <90 g/L (in infants <4 weeks: hemoglobin <100 g/L)
	Platelets $<100.000/\mu\text{L}$
	Neutrophils $<1000/\mu\text{L}$
	Hypertriglyceridemia and/or hypofibrinogenemia: Fasting triglycerides ≥ 265 mg/dL Fibrinogen ≤ 1.5 g/L
	Hemophagocytosis in bone marrow or spleen or lymph nodes
	Low or absent NK-cell activity
	Ferritin ≥ 500 $\mu\text{g/L}$
	Soluble CD25 ≥ 2400 U/L
	Supportive clinical criteria include neurologic symptoms and cerebrospinal fluid pleocytosis, conjugated hyperbilirubinemia, and transaminitis, hypoalbuminemia and hyponatremia

A report was considered eligible for inclusion when data on gender, age, IBD-type, treatment before MAS onset, triggering agent, and outcome were stated. Reports were excluded when more than two of the requested items were not reported. Furthermore, additional data on the methodology employed to identify the triggering agents and therapy of MAS were collected. Case finding strategy is represented in Figure 2.

RESULTS

We identified 50 cases of MAS associated with IBD including two unpublished cases from our clinic and one case from the IBD-centre of Palermo (Table 2),^{16–51}. The first report was published in 1988 followed by six isolated reports over the following 16 years, up to 2004. Thereafter, we observed a sharp increase in published cases with an additional 41 cases between 2005 and October 2012, 22 of them in the previous 24 months.

We excluded three cases from analysis: one case from a series with different background pathologies because of insufficient clinical data,⁵² and two cases of EBV infection (one of them fatal) and clinical features which resembled MAS, but diagnosis of MAS was not made by the authors.^{53, 54}

Case description of yet unpublished cases

Clinic of Messina: Case 1: a 38 year-old woman was admitted to our hospital because of high grade fever unresponsive to antibiotics, lasting 5 days. She had been diagnosed with ulcerative colitis 8 years before and was in stable remission while on azathioprine at a dose of 2 mg/kg/day over the past 8 years. On admission, pancytopenia (leucocytes $1800/\mu\text{L}$, hemoglobin 92 g/L, platelets $85\ 000/\mu\text{L}$) and mild transaminitis were present. An ultrasound evaluation of the abdomen revealed an enlarged spleen and a moderate hepatomegaly; no lymph nodes were identified. A chest film was negative. Azathioprine was stopped and repeated blood cultures and search for EBV, CMV, human Herpes Virus-6 (HHV-6), and serology for leishmania yielded negative results. She was treated empirically with broad-spectrum antibiotics, methylprednisolone, and filgrastim. High serum ferritin and triglycerides, hyponatremia, and absent activity of NK cells were suggestive for MAS, but a bone marrow aspirate was negative for hemophagocytosis. Her clinical picture evolved rapidly, and death due to multiorgan failure occurred 10 days after admission. Clinical diagnosis, based on clinical and blood parameters was consistent with MAS. Authorization for a post-mortem investigation was denied.

Case 2: a 72-year-old woman was diagnosed with Crohn's ileitis which responded well to oral mesalazine and systemic steroids. She developed steroid-dependency in a few months and azathioprine was added 1 year after diagnosis at 2.2 mg/kg/day in order to control symptoms. Six months later she was admitted to our hospital because of high grade fever, unresponsive to antibiotic therapy and azathioprine withdrawal. On admission, she presented acutely ill, dyspneic (oxygen saturation at room air 85%), malnourished (albumin, 22 g/L), with leucopenia (2200/mL) and anemia (hemoglobin 88 g/L). On physical examination, herpetic lesions were noted at her lips and i.v. treatment with acyclovir together with methylprednisolone and parenteral nutrition was started. An ultrasound examination of the abdomen revealed a slightly enlarged spleen and a homogeneous, hypoechoic wall thickening (12 mm) of the ileum proximally to the known Crohn's localization, raising the suspect of a small bowel lymphoma. A chest film was positive for significant pleural effusion, which was repeatedly drained in order to improve ventilation. The search for serum CMV-DNA yielded positive results and i.v. ganciclovir was commenced. High serum ferritin, together with hypertriglyceridemia and absent NK activity led to the diagnosis of CMV-related MAS. After improvement

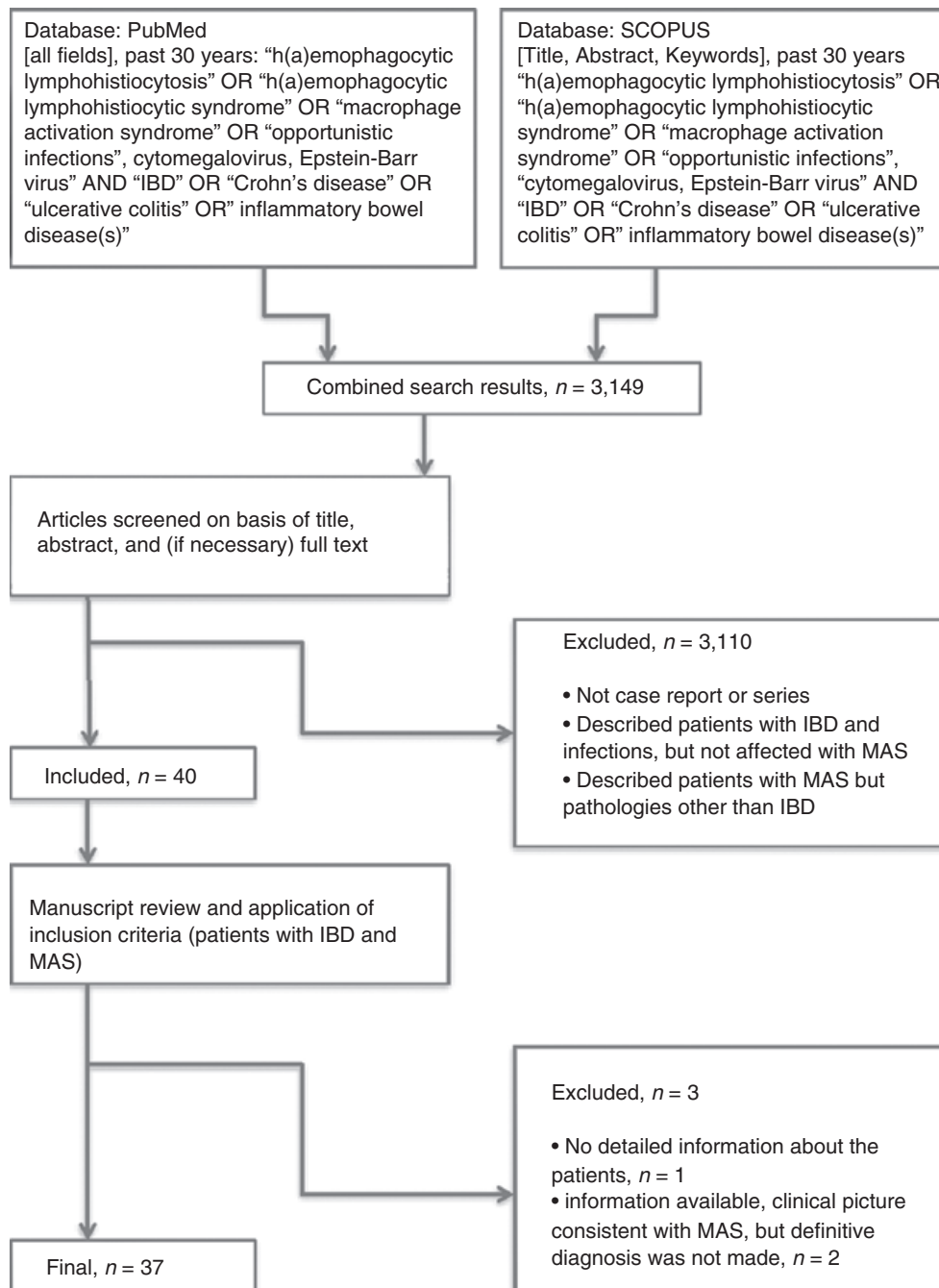


Figure 2 | Search strategy and flow of information relative to the systematic review.

of the clinical picture and blood parameters, she was transferred to our Surgery Unit and underwent resection of the distal 50 cm of the ileum. Histopathological evaluation of the resected bowel was consistent with intestinal B-cell lymphoma and Crohn's disease. After discharge, the patient was followed by hematologists, but died 3 months later, after a second chemotherapy cycle.

Clinic of Palermo: a 54-year-old man, diagnosed with Crohn's disease of the ileum in 2007 by means of colonoscopy, histology, and magnetic resonance imaging, was initially treated with steroids due to fever and mild diarrhea. The patient initially responded with clinical remission, but relapsed early with high-grade fever. A complete screening for infection was negative, so steroids were re-started with an initial response, followed again

Table 2 | Year of publication, patient's characteristics, disease type, IBD treatment and duration before macrophage activation syndrome (MAS) onset, infectious trigger, modality of diagnosis of infectious agent, treatment of MAS, and outcome of the retrieved cases

Author, year	IBD	Gender	Age; years	IBD-Therapy	Duration in months	Pathogen	Detection	MAS treatment	Fatal
Reiner, 1988 ¹⁶	CD	F	44	S 36	36	Histoplasma	Culture	n.a.	N
Posthuma, 1995 ¹⁷	CD	M	19	AZA 20	20	EBV	IgM-VCA	Acyclovir, IV-Ig α -interferon Plasmapheresis	Y
Sjipkens, 1996 ¹⁸	CD	F	20	S-AZA	n.a.–18	CMV	IgM anti-CMV IgG anti-CMV pp65 antigenemia	Ganciclovir Prednisone Transfusions	N
Kanaji, 1998 ¹⁹	UC	M	25	S	n.a.	?	?	Prednisolone IV-Ig	N
Babu, 2004 ²⁰	CD	M	12	AZA	24	CMV	IgM anti-CMV IgG anti-CMV CMV-mRNA for pp67	AZA withdrawal	N
Koketsu, 2004 ²¹	UC	M	35	S-colectomy	n.a.	CMV	Ab anti-CMV pp65 antigenemia	Ganciclovir IV-Ig, G-CSF	N
Chauveau, 2005 ²²	CD	M	37	AZA-IFX	n.a.–n.a.	CMV	n.a.	n.a.	N
Hindupur, 2005 ²³	CD	M	26	IFX 0.5	0.5	MTB	Culture post-mortem	Dexamethasone Cyclosporin A	Y
Kohara, 2006 ²⁴	CD	M	22	MP-IFX	n.a.–4	CMV	IgM anti-CMV IgG anti-CMV CMV-PCR Histology	Ganciclovir Splenectomy Transfusions	N
James, 2006 ²⁵	CD	M	26	S-IMM-IFX	n.a.–n.a.–n.a.	MTB	n.a.	n.a.	Y
Siegel, 2007 ²⁶	UC	M	29	MP	n.a.	CMV	Post-mortem	IV-Ig, etoposide Dexamethasone, G-CSF, acyclovir	Y
Francolla, 2008 ²⁷	CD	F	15	AZA-IFX	30–24	EBV	IgM-VCA	Acyclovir Dexamethasone	N
Serrate, 2009 ²⁸	CD	F	53	AZA	20	EBV	IgG-VCA EBV-DNA	Methylprednisolone Rituximab Etoposide, IV-Ig	N
Miquel, 2009 ²⁹	CD	F	63	AZA	48	CMV	pp65 antigenemia	Ganciclovir, IV-Ig	N
	CD	M	23	S-AZA-IFX	12–12–12	CMV	IgM anti CMV pp65 antigenemia CMV-DNA	Methylprednisolone Ganciclovir	N
Dapena Diaz, 2009 ³⁰	CD	F	Pediatric	n.a.	n.a.	n.a.	n.a.	HLH-04	Y
N'Guyen, 2009 ³¹	CD	M	35	AZA	36	EBV	IgM-VCA IgG-VCA EBV-DNA	IV-Ig, prednisone Cyclophosphamide Vincristine, acyclovir, rituximab	Y
Wolschke, 2010 ³²	CD	F	28	AZA	24	CMV	Serum CMV-DNA BAL CMV-DNA	Ganciclovir HLH-04	N
Numakura, 2010 ³³	CD	F	48	lfx	n.a.	MTB	PCR sputum	Anti-TBC IV-Ig Steroids	N
Fox, 2010 ³⁴	UC	M	50	5-ASA	n.a.	EBV	IgG-VCA EBV-DNA	HLH-04 IV-Ig	Y

Table 2 (Continued)									
Author, year	IBD	Gender	Age; years	IBD-Therapy	Duration in months	Pathogen	Detection	MAS treatment	Fatal
Uslu, 2010 ³⁵	CD	M	11	S-AZA	24–24	Acinetobacter	Blood culture	Methylprednisolone CSA, IV-Ig	Y
Deneau, 2010 ³⁶	IBDU	M	11	AZA-Ifx	n.a.–12	EBV/ lymphoma	Tissue Immunohistochemistry	Etoposide Dexamethasone	Y
Petrache, 2010 ³⁷	CD	F	31	S-AZA	n.a.–n.a.	CMV	CMV-DNA	Ganciclovir	N
	UC	M	27	AZA	36	CMV	CMV-DNA	n.a.	N
Kim, 2010 ³⁸	UC	M	32	SASP	24	n.a.	n.a.	Steroids	N
Ross, 2011 ³⁹	CD	M	10	AZA	12	EBV	IgM-VCA EBV-DNA	Cyclophosphamide Vincristine Prednisolone rituximab	Y
Gunson, 2011 ⁴⁰	CD	F	14	AZA	60	EBV	EBV-DNA IgG-EBNA	Methylprednisolone IV-Ig, acyclovir Rituximab	N
Coté-Daigneault, 2011 ⁴¹	CD	M	21	MP-IFX	48–48	Lymphoma	IgG-EBNA	G-CSF HLH-04	N
N'Guyen, 2011 ³¹	CD	F	28	AZA-IFX	60–24	CMV	IGM anti-CMV	Ganciclovir, steroids	N
	CD	F	33	AZA	60	CMV	CMV-DNA	Ganciclovir, steroids	N
	CD	F	30	AZA-IFX	48–1	CMV	IgM anti-CMV	Ganciclovir, steroids,	N
	CD	F	38	AZA	24	CMV	CMV-DNA IgM-anti-CMV blood CMV-DNA BAL CMV-DNA IgM anti-CMV CMV-DNA	foscarnet, IV-Ig Ganciclovir, IV-Ig Foscarnet, steroids	Y
Lo Presti, 2011 ⁴²	CD	F	30	AZA	8	CMV	CMV-DNA	Ganciclovir, steroids	N
Salado, 2011 ⁴³	CD	M	24	S-IFX	n.a.–4	EBV	EBV-DNA	HLH-04	N
Biank, 2011 ⁴⁴	CD	n.a.	Pediatric	MP	13	EBV	EBV-DNA	HLH-04	N
	CD	n.a.	Pediatric	AZA	4	EBV	EBV-DNA	HLH-04	N
	CD	n.a.	Pediatric	AZA	78	EBV	EBV-DNA	HLH-04	Y
	CD	n.a.	Pediatric	AZA	52	EBV	EBV-DNA	HLH-04	N
	CD	n.a.	Pediatric	MP	6	n.a.	n.a.	Infliximab	N
van Langenberg, 2011 ⁴⁵	UC	F	32	AZA	24	CMV	IgM anti-CMV	Ganciclovir	N
	CD	M	22	AZA	24	CMV	PCR blood/BAL IgM anti-CMV PCR blood/BAL	Ganciclovir	N
Duque, 2011 ⁴⁶	UC	M	19	AZA	36	EBV	IgM-VCA EBV on LN histology	Prednisolone, Transfusions IV-Ig, G-CSF	N
Ingvarsdn, 2012 ⁴⁷	UC	M	22	AZA	n.a.	EBV	n.a.	n.a.	Y
Munoz, 2012 ⁴⁸	CD	F	24	MP	24	CMV	IgM-anti-CMV CMV-DNA	HLH-04 IV-Ig, ganciclovir	N
Altaf, 2012 ⁴⁹	CD	F	15	MP	n.a.	EBV/ lymphoma	IgG-EBNA EBV-DNA	Rituximab, IV-Ig HLH-04	N
Fitzgerald, 2012 ⁵⁰	CD	F	14	AZA	48	EBV	EBV-DNA	Rituximab	N

Table 2 | (Continued)

Author, year	IBD	Gender	Age; years	IBD-Therapy	Duration in months	Pathogen	Detection	MAS treatment	Fatal
Weinkove, 2012 ⁵¹	CD	M	21	AZA	n.a.	CMV	IgM anti-CMV CMV-DNA	HLH-04 Foscarnet Valganciclovir	N
Clinic of Messina	UC	F	38	AZA	96	?	?	Methylprednisolone	Y
	CD	F	72	AZA	6	CMV/ lymphoma	PCR	G-CSF Methylprednisolone Ganciclovir	N
Clinic of Palermo	CD	M	54	IFX	15	?	?	HLH-04	Y

UC, ulcerative colitis; CD, Crohn's disease; F, female; M, male; 5-ASA, mesalazine; SASP, salazopyrin; AZA, azathioprine; MP, mercaptopurine; IMM, immunomodulator (exact molecule not stated); n.a., information not available; ?, no infectious agent identified; CMV, cytomegalovirus; EBV, Epstein-Barr virus; MTB, *Mycobacterium tuberculosis*; HSTL, hepatosplenic T-cell lymphoma; IV-Ig, intravenous immunoglobulin; G-CSF, granulocyte colony stimulating factor; HLH-04, treatment protocol recommended in HLH⁵², i.e. an association of steroids, etoposide and cyclosporine A; S, steroids; N, no; Y, yes.

by early relapse with fever and arthralgias. Azathioprine was added and the patient went into remission for 2 years, but in December 2009 he relapsed with high fever unresponsive to steroids. Infliximab was initiated followed by complete remission until October 2011 when he relapsed again with high fever and arthralgias. At admission, splenomegaly and an increase in size of abdominal lymph-nodes were observed; a complete screening of infectious diseases through blood and urine cultures for bacterial, viral and fungal infections was performed. HSV-1, with typical labial lesions, was present and i.v. acyclovir was started. Despite negative bacterial cultures, an empiric broad-spectrum antibiotic treatment was started. At this moment, red blood cell, platelet and leucocyte counts were normal and a bone marrow aspirate was negative. Subsequently, red blood cell, platelet and leucocyte counts decreased gradually and serum ferritin increased to more than 10000 g/dL while serum triglycerides rose to 800 mg/dL. Bone marrow aspirate was repeated and haemophagocytosis was identified (Figure 1). A treatment regimen according to the treatment protocol HLH-04 was established with dexamethasone, etoposide and cyclosporine A, but the patient's conditions deteriorated and he died 10 days later.

In the retrieved cases, gender distribution was equal (21 females, 24 males, five not reported) in the whole series and 36/50 (72%) were adults, aged from 19 to 72 years; the median age in adults was 28.5 years. The underlying bowel diseases in adults were Crohn's disease (CD) in 26/36 (72%), and ulcerative colitis (UC) in 10 patients (28%). In the 14 pediatric patients, 13 (92.8%)

were diagnosed with CD and one with inflammatory bowel disease unclassified (IBDU) (6%).

Overall mortality was 30%. In adults, death occurred in 10/36 (28%), whereas fatal outcome was observed in 5/14 pediatric patients (38%). Where indicated, the final cause of death was multiorgan failure in six patients; hepatic failure, respiratory failure, gastrointestinal bleeding, or intracerebral hemorrhage were reported in other patients. One patient died during emergency surgery due to a perforated gastric ulcer. Two adult patients with lymphoma died during the follow-up after MAS had been successfully treated (our clinic,⁴¹).

Treatment before MAS onset. Treatment with thiopurines was reported in 39/50 patients with a duration that ranged from 4 months to 8 years. Thiopurine monotherapy was administered in 28/37 patients, whereas in the remaining cases thiopurines were associated with steroids (three cases), with infliximab (seven patients) or both (one case). In two patients, an immunosuppressor without indication of the exact molecule was associated with infliximab and steroids²⁵ or was used as single therapeutic agent,³⁰ respectively. Infliximab was used as single therapy in three patients, associated with steroids in 1 patient. All other patients were treated with a combination with thiopurines. Duration of infliximab treatment, when reported, ranged from 0.5–60 months.

In pediatric patients, thiopurines were administered to 13/14 patients, as monotherapy in 10/13, or combined with steroids (one patient) or with infliximab (two patients). In one patient treatment was not indicated.³⁰

Table 3 | Cases where erythrocyte (RBC) concentrations of thiopurine metabolites were assessed shortly before macrophage activation syndrome onset showing non-toxic concentrations

Author, year	IBD	6-TGN pmol/ 8 × 10 ⁸ RBC	6-MMP pmol/ 8 × 10 ⁸ RBC
Francolla, 2008 ²⁷	CD	166	790
Biank, 2011 ⁴⁴	CD	72	875
	CD	210	4066
	CD	171	1952
Fitzgerald, 2012 ⁵⁰	CD	264	–
Weinkove, 2012 ⁵¹	CD	201	–

6-TGN, 6-thioguanine nucleotides; 6-MMP, 6-methylmercaptapurine; RBC red blood cells.

Weinkove's case, author's personal communication.

When indicated, thiopurine dosing ranged from 0.9 to 3.15 mg/kg/day for azathioprine and 1.4 to 1.76 mg/kg/day for mercaptopurine. In six patients (Table 3), determination of erythrocyte concentrations of 6-thioguanine nucleotides (6-TGN), and in four patients also those of 6-methylmercaptapurines (6-MMP), was available shortly before onset of MAS, showing the former levels to be within the therapeutic range and the latter below the toxic limit.^{27, 44, 50, 51}

Mesalazine or sulphasalazine alone were reported in one patient, steroids alone in two patients and steroids followed by colectomy in one patient with UC.

Triggers associated with MAS onset. Viral infections were causally associated in 39/50 patients (78%) with infections due to EBV equally frequent to those due to CMV (19 EBV, 20 CMV); one CMV/herpes simplex virus (HSV) co-infection was seen (own observation). Interestingly, in pediatric patients, EBV was identified in 11/14 (79%), CMV or *Acinetobacter* in one case each, and in one patient no infectious agent was indicated.

Primary EBV infections were reported in 12 patients, while the remaining were consistent with EBV reactivation. Primary CMV infections were diagnosed in 7 out of 20 patients.

In the whole series, bacterial or fungal infections were identified in five cases. Among these latter agents *Mycobacterium tuberculosis* was reported in three patients and all these patients received infliximab.

In seven cases, no infectious agent was identified. Three cases were associated with lymphomas; one hepatosplenic T-cell lymphoma (HSTCL) in a 21-year old male treated with infliximab + MP,⁴¹ one B-cell lymphoma in a 72-year old woman treated with AZA for CD (own observation), and one NK/T-cell lymphoma in an 11-year old boy treated with infliximab + AZA for IBDU³⁶; the two former patients died due to neoplastic disease, the latter patient died due to MAS.

Clinical presentation of MAS in IBD

With respect to the diagnostic criteria of HLH (Table 1), and given that not all reports indicate numeric data, clinical features included temperature ranging from 38.6 to 40°C in 92% of all cases. In four reports, no detailed data were available. Enlargement of liver and spleen was reported in almost half of patients. In all cases, leucopenia was reported with a median value of 1200/mL (range 300–3100/mL). In roughly 30% cases, leucocytes were above the limit set by Henter *et al.*¹ Median haemoglobin levels were 87 g/L (range 65–133 g/L), with only 8% above the upper limit. Median platelet counts were 80 000/mL (range 8000–187 000/mL) with 10% above the limit indicated by diagnostic criteria. Serum ferritin was the most frequently reported variable, with all of the reported values above the threshold of 500 µg/L (median value 5000 µg/L; range 583–52 397 µg/L), whereas triglycerides were normal in 16% with a median concentration of 339 mg/dL (range 162–1235 mg/dL). Only seven reports included serum fibrinogen with a range from 0.3 to 1.7 g/L (normal in 1/7) and another seven gave circulating levels of CD25 (range 5941–39 222 U/mL). NK activity was reported in only four reports with values compatible with HLH.

Treatment of established MAS. Besides withdrawal of immunosuppressive therapy, sufficient to resolve the clinical picture in one patient,²⁰ and specific treatment for recognized bacterial, fungal or viral infections, various approaches were described including administration of i.v. immunoglobulins, plasmapheresis, granulocyte-colony stimulating factor, and foscarnet in addition to ganciclovir. Vincristine and/or cyclophosphamide were used in EBV-related lymphoproliferative disorders. The full HLH-04 protocol, published in 2007,¹ an association of dexamethasone, etoposide, and cyclosporine A, was employed in 13 patients, starting from 2009 (eight patients with EBV, three with CMV, and two patients without identification of an infectious agent). Death occurred in four of them. Four patients with EBV-related

MAS were treated successfully with one or more administrations of rituximab, an anti-CD20 antibody, whereas one patient died despite this treatment. Interestingly, infliximab was administered successfully in a pediatric MAS virus-negative patient formerly treated with mercaptopurine.⁴⁴

Outcome after MAS. Follow-up ranging from 6 months to 3 years was reported in 20 of the surviving patients. Apparently, no patient resumed the same immunosuppressor given before MAS-onset. Four patients remained in remission on oral and topical mesalazine,^{20, 41, 45, 46} in two patients methotrexate was started successfully, one patient is on low-dose prednisolone (10 mg/day) and one is on low dose cyclosporine (target serum trough level 100 ng/mL, personal communication from ref 51) treatment. Finally, one patient is on an empirical anti-MAP (*Mycobacterium avium* spp. *paratuberculosis*) therapy⁴⁵ and one patient is on evaluation for stem cell transplantation.⁴⁸

DISCUSSION

In the retrieved records, most of the patients suffered from CD and all except five patients were under immunosuppressive therapy. The prevalence of CD may reflect the more frequent use of immunomodulators in this disease compared to UC rather than a disease-related susceptibility to MAS. Roughly one out of three patients died. Although we have no epidemiologic data on the incidence of MAS in IBD, it is plausible that the rising frequency is due to an improved awareness on the part of gastroenterologists rather than to a phenomenon that has increased over the past 5 years. Immunomodulators such as AZA or MP have been constantly used over the past 30 years throughout the world, and biologic therapies have now been in use for almost 10 years. The main therapeutic intervention prior to onset of MAS was with thiopurines, while the duration of thiopurine treatment seems not to have been significant (range 4–69 months). Other treatments for IBD include biologics, infliximab alone or in combination with steroids or thiopurines. Adalimumab has not yet been reported in IBD to be associated with MAS, but has been reported in one patient with rheumatoid arthritis.⁵⁵ Surprisingly, salazopyrin and mesalazine were reported in one patient each as the only therapy before MAS onset, pointing to genetic factors, thus making immunosuppression as the only causative factor unlikely.

It is possible that the occurrence of MAS in patients with IBD is the result of a fatal combination between persistence of, or a new infection with, a virus, the effect

of immunosuppressive therapy weakening immune surveillance, and the potential presence of a genetic susceptibility. Thiopurines inhibit the activity of CD4 T-lymphocytes by inducing apoptosis through inhibition of Rac1⁵⁶ thus weakening defence against viral infections. Biologics, on the other hand, seem to expose patients more to fungal or bacterial agents.⁵⁷ In systemic lupus erythematosus (SLE) patients, a killing defect of NK cells has been demonstrated which is ultimately accentuated by a reduction of NK cells induced by azathioprine.⁵⁸ Likewise in kidney transplant patients⁵⁹ there is a significant difference in NK cell activity depending on the immunosuppressive drug used to prevent graft rejection. Indeed, the combination of tacrolimus/mycophenolate mofetil did significantly better in terms of less NK cell reduction and less NK cytotoxicity reduction than the combination with cyclosporine/azathioprine. In an experimental murine model of MAS, repeated stimulation of the toll-like receptor 9 (TLR9) with CpG DNA precipitates the syndrome.⁶⁰ EBV is known to trigger TLR9, and high loads of EBV were found in macrophages of patients with MAS.³³ In the juvenile form of SLE, where MAS appears to have a high clinical impact,⁶¹ overstimulation of TLR9 is believed to be induced by autoantigens.⁶² In sJIA-related MAS, occult MAS appears to be present in up to 30%^{9, 63} and it has been hypothesized that an intrinsic hyperactivity of TLR/IL-1R signaling may trigger evolution to MAS⁶⁴. The common denominator is an inefficacious response to antigens that leads to an overwhelming Th1/Th1-related cytokine production and, finally, to macrophage activation in the bone marrow, liver, and spleen leading to its principal feature i.e. a two- to three-line cytopenia.

It is becoming apparent that compared to other immunomodulators or biologics, thiopurines carry a risk for reactivation of viral infections other than CMV, including activating warts (human papilloma virus, HPV) with possible cervical dysplasia/cancer,⁶⁵ and Epstein-Barr virus (EBV) with an increased risk of related lymphomas.⁶⁶ Herpes viruses, after the primary infection, enter in latency in the human organism but remain under the control of the immune system, namely NK cells and cytotoxic T cells. Latent varicella-zoster virus (VZV) and HSV are harbored in neural cells, whereas latent EBV and CMV reside in precursors of myeloid derived monocytes and dendritic cells.⁶⁷ The figures for seroprevalence in healthy adults for CMV, EBV, HSV, and VZV reach 100%, 96%, >90%, and >90%, respectively^{68–72}, which means that nearly every patient is at risk for reactivation. Interestingly, in the retrieved cases,

12 patients were reported to have a primary EBV infection and 7 patients were classified as primary CMV infection. Despite these findings, no recommendation concerning a search for antibodies against either EBV or CMV has been advised in the most recent ECCO guidelines on opportunistic infections.⁷³

Since TNF plays a role in the inhibition of viral replication,⁷⁴ much attention has been paid to potential viral infections in anti-TNF treated patients. In a large register from rheumatologic patients in Spain, VZV and HSV infections were the most frequent viral infections in patients treated with biologics, ranking however after bacterial or fungal complications.⁷⁵ Atypical varicella and VZV reactivation have been reported⁷⁶ and severe infections due to VZV are reported among the most frequent viral complications of anti-TNF therapy in the French RATIO registry, followed by HSV. However, the overall risk of reactivation of latent herpes viruses in patients on biologics appears to be low; at least after 3 months of therapy in IBD⁷⁷ and after 6 weeks in rheumatoid arthritis.⁷⁸ Concerning CMV, T-cell response to CMV was investigated in 25 patients on anti-TNF therapy, showing that the interferon- γ response of CD4 + ve cells and the proliferative response were maintained upon CMV antigen stimulation⁷⁹. Indeed, in most of the retrieved cases, and other reports on CMV infections⁸⁰, patients were on concomitant thiopurine treatment. EBV is a virus with the potential of inducing malignant lymphomas, and many studies deal with this topic.⁸¹ Investigating reactivation of EBV on anti-TNF therapy, however, yielded negative results in rheumatologic^{78, 82} as well as in IBD patients.⁷⁷

Despite these considerations, in the past few years a growing number of reports have been published on IBD patients with opportunistic infections complicated by a syndrome of macrophage and T-cell activation, accompanied by a potentially fatal cytokine storm and overwhelming inflammatory reaction, the MAS syndrome, which, in the present review, reaches a mortality rate of 30%. For comparison, over the past 5 years, one of the major concerns regarding therapeutic interventions in IBD has been represented by HSTCL, a highly lethal lymphoma affecting mostly young males treated with thiopurine monotherapy or with combined therapies (thiopurines plus biologics). Altogether, 38 cases of HSTCL are reported, 23 of them on thiopurine monotherapy⁸³ with a range of therapy duration between three and 17 years. In the present series of MAS, a 21-year old male patient was diagnosed with HSTCL after MAS onset and died somewhat later due to sepsis.⁴⁰

It appears that one of the major problems is to recognize the syndrome, which may present with a variety of symptoms, ranging from neurologic-predominant signs to acute liver failure. In fact, two of the retrieved reports were excluded as MAS was not diagnosed despite a compatible clinical picture.^{53, 54} Misinterpretation of clinical/biochemical signs leads to diagnostic delays, since fever and cytopenia may represent side effects of thiopurine therapy, whereas cytopenia may be present in patients on biologics. The presence of hemophagocytic CD163 + ve macrophages in bone marrow or lymph-node aspirates, may be missed, at least in initial stages, and negative histology should not rule out MAS,⁸⁴ whereas repeated aspirates retard diagnosis. The clinical picture, together with the infiltration of bone marrow or liver by activated macrophages, may lead to the correct diagnosis. Additional features such as the reduction/absence of peripheral CD8 + ve NK cells,⁸⁵ are present in early stages in nearly all patients.⁸⁶ Other biochemical signs, e.g. a highly elevated serum ferritin, most likely expression of the acute phase response, are almost always present and an early decrease after therapy start may be used as prognostic marker for a more favourable outcome in HLH.⁸⁷ Other immunologic markers are raised in MAS, such as sCD25 and the receptor for haemoglobin/haptoglobin complexes CD163. CD25 is believed to have an immunosuppressive action as it binds circulating IL-2, but may reflect in MAS only the complete dysregulation of the immune system.⁸⁸ A proinflammatory action of CD25, by enhancing the IL-17 immune response, has been shown recently in an animal model of autoimmune disease.⁸⁹ CD163 is involved in clearance and endocytosis of haemoglobin/haptoglobin complexes by macrophages and may protect tissues from free haemoglobin-mediated oxidative damage. In sJIA, high circulating levels of sCD25 and sCD163 are promising diagnostic markers for early diagnosis of MAS together with serum ferritin⁹⁰ and should be investigated in IBD patients with suspected MAS.

With regard to therapy, treatment of the underlying infection is mandatory and may require empirical treatment in the first 24–48 h. If MAS is suspected, a broad search for infectious agents with appropriate techniques is necessary, including determination of EBV-, CMV-, human herpes virus-6 (HHV-6)-DNA, search for *Mycobacterium tuberculosis*, histoplasmosis (urines), repeated blood and urinary cultures, etc. In hyperacute situations, additional immunosuppression with steroids, cyclosporine A, or etoposide may be required (see Henter, ref 1). Other treatment options, e.g. rituximab, immunoglobulins,

or intrathecal dexamethasone are extensively reviewed in Jordan et al⁹¹.

In conclusion, in IBD patients, thiopurine treatment in particular is associated with MAS, most likely by promoting viral reactivation through inhibition of NK and cytotoxic T cells. However, although less frequent, almost every treatment and a variety of infectious agents may lead to this syndrome. Overall, mortality is high, especially in pediatric patients. It is possible that genetic susceptibility, together with reactivated latent or primary viral infections, contributes to the occurrence of MAS. Genetic determinants should be investigated in IBD patients with MAS.

AUTHORSHIP

Guarantor of the article: Walter Fries.

Author contributions: WF and AC designed the research study, performed and analyzed the literature search, and drafted the paper. MC contributed the case from Palermo and critically reviewed the manuscript. All authors approved the final version of the manuscript.

ACKNOWLEDGEMENT

Declaration of personal interests: WF served as an advisory board member for MSD and Abbvie. The authors wish to thank Trays Ricciardi for language assistance.

Declaration of funding interests: None.

REFERENCES

- Henter JI, Horne A, Aricò M, et al. HLH-2004: diagnostic and therapeutic guidelines for hemophagocytic lymphohistiocytosis. *Pediatr Blood Cancer* 2007; **48**: 124–31.
- Stepp SE, Dufourcq-Lagelouse R, Le Deist F, et al. Perforin gene defects in familial hemophagocytic lymphohistiocytosis. *Science* 1999; **286**: 1957–9.
- Feldmann J, Callebaut I, Raposo G, et al. MUNC13-4 is essential for cytolytic granules fusion and is mutated in a form of familial hemophagocytic lymphohistiocytosis (FHL3). *Cell* 2003; **115**: 461–73.
- Tang YM, Xu XJ. Advances in hemophagocytic lymphohistiocytosis: pathogenesis, early diagnosis/differential diagnosis, and treatment. *Scientific WorldJournal* 2011; **11**: 697–708.
- Menasche G, Pastural E, Feldmann J, et al. Mutations in RAB27A cause Griscelli syndrome associated with haemophagocytic syndrome. *Nat Genet* 2000; **25**: 173–6.
- Kaplan J, De Domenico I, Ward DM. Chediak-Higashi syndrome. *Curr Opin Hematol* 2008; **15**: 22–9.
- Enders A, Zieger B, Schwarz K, et al. Lethal hemophagocytic lymphohistiocytosis in Hermansky-Pudlak syndrome type II. *Blood* 2006; **108**: 81–7.
- Engel P, Eck MJ, Terhorst C. The SAP and SLAM families in immune responses and X-linked lymphoproliferative disease. *Nat Rev Immunol* 2003; **3**: 813–21.
- Rigaud S, Fondaneche MC, Lambert N, et al. XIAP deficiency in humans causes an X-linked lymphoproliferative syndrome. *Nature* 2006; **444**: 110–4.
- Stephan JL, Kone-Paut I, Galanbrun C, Mouy R, Bader-Meunier B, Prieur AM. Reactive haemophagocytic syndrome in children with inflammatory disorders: a retrospective study of 24 patients. *Rheumatology (Oxford)* 2001; **40**: 1285–92.
- Vastert SJ, van Wijk R, D'Urbano LE, et al. Mutations in the perforin gene can be linked to macrophage activation syndrome in patients with systemic onset juvenile idiopathic arthritis. *Rheumatology (Oxford)* 2010; **49**: 441–9.
- Yanagimachi M, Goto H, Miyamae T, et al. Association of IRF5 polymorphisms with susceptibility to hemophagocytic lymphohistiocytosis in children. *J Clin Immunol* 2011; **31**: 946–51.
- Sherry B. Rotavirus and reovirus modulation of the interferon response. *J Interferon Cytokine Res* 2009; **29**: 559–67.
- Grom AA, Villanueva J, Lee S, Goldmuntz EA, Passo MH, Filipovich A. Natural killer cell dysfunction in patients with systemic-onset juvenile rheumatoid arthritis and macrophage activation syndrome. *J Pediatr* 2003; **142**: 292–6.
- Ravelli A, Grom AA, Behrens EM, Cron RQ. Macrophage activation syndrome as part of systemic juvenile idiopathic arthritis: diagnosis, genetics, pathophysiology and treatment. *Genes Immun* 2012; **13**: 289–98.
- Reiner AP, Spivak JL. Hematophagocytic histiocytosis. A report of 23 new patients and a review of the literature. *Medicine (Baltimore)* 1988; **67**: 369–88.
- Posthuma EF, Westendorp RG, van der Sluys Veer A, et al. Fatal infectious mononucleosis: a severe complication in the treatment of Crohn's disease with azathioprine. *Gut* 1995; **36**: 311–3.
- Sijpkens YW, Allaart CF, Thompson J, et al. Fever and progressive pancytopenia in a 20-year-old woman with Crohn's disease. *Ann Hematol* 1996; **72**: 286.
- Kanaji S, Okuma K, Tokumitsu Y, Yoshizawa S, Nakamura M, Niho Y. Hemophagocytic syndrome associated with fulminant ulcerative colitis and presumed acute pancreatitis. *Am J Gastroenterol* 1998; **93**: 1956–9.
- Babu TG, Boctor D, Davey A, Bond MC, Jacobson K. Cytomegalovirus-associated hemophagocytic syndrome in a child with Crohn disease receiving azathioprine. *J Pediatr Gastroenterol Nutr* 2004; **39**: 418–21.
- Koketsu S, Watanabe T, Hori N, Umetani N, Takazawa Y, Nagawa H. Hemophagocytic syndrome caused by fulminant ulcerative colitis and cytomegalovirus infection: report of a case. *Dis Colon Rectum* 2004; **47**: 1250–3.
- Chauveau E, Terrier F, Casassus-Buihle D, Moncoucy X, Oddes B. Macrophage activation syndrome after treatment with infliximab for fistulated Crohn's disease. *Presse Med* 2005; **34**: 583–4.
- Hindupur S. Hemophagocytosis in hemophagocytic lymphohistiocytosis. *Am J Hematol* 2005; **80**: 299–300.
- Kohara MM, Blum RN. Cytomegalovirus ileitis and hemophagocytic syndrome associated with use of anti-tumor necrosis factor- α antibody. *Clin Infect Dis* 2006; **42**: 733–4.
- James DG, Stone CD, Wang HL, Stenson WF. Reactive hemophagocytic syndrome complicating the treatment of inflammatory bowel disease. *Inflamm Bowel Dis* 2006; **12**: 573–80.

26. Siegel CA, Bensen SP, Ely P. Should rare complications of treatment influence decision-making in ulcerative colitis? *Inflamm Bowel Dis* 2007; **13**: 242.
27. Francolla KA, Altman A, Sylvester FA. Hemophagocytic syndrome in an adolescent with Crohn disease receiving azathioprine and infliximab. *J Pediatr Gastroenterol Nutr.* 2008; **47**: 193–5.
28. Serrate C, Silva-Moreno M, Dartigues P, *et al.* Epstein-barr virus-associated lymphoproliferation awareness in hemophagocytic syndrome complicating thiopurine treatment for Crohn's disease. *Inflamm Bowel Dis* 2009; **15**: 1449–51.
29. Miquel T, Bonnet DP, Leport J, Longuet P, Bletry O, Leport C. Hemophagocytic syndrome in the course of Crohn's disease: possible association with cytomegalovirus infection. *Am J Gastroenterol* 2009; **104**: 252.
30. Dapena Dóaz JL, Dóaz de Heredia Rubio C, Bastida Vila P, *et al.* Haemophagocytic syndrome: a common pathogenic mechanism of various aetiologies. *An Pediatr (Barc)* 2009; **71**: 110–6.
31. N'guyen Y, Andreoletti L, Patey M, *et al.* Fatal epstein-barr virus primo infection in a 25-year-old man treated with azathioprine for Crohn's disease. *J Clin Microbiol* 2009; **47**: 1252–4.
32. Wolschke Ch, Fiedler W, Habermann RC, *et al.* 28-year old female patient with respiratory insufficiency, elevated liver enzymes, pancytopenia and fever. *Internist (Berl)* 2010; **51**: 1434–8.
33. Numakura T, Matsuura Y, Takiguchi H, Hara Y, Ameku K, Takashi H. Tuberculosis associated with hemophagocytic syndrome complicated by treatment with infliximab. *Nihon Kokyuki Gakkai Zasshi* 2010; **48**: 449–53.
34. Fox CP, Shannon-Lowe C, Gothard P, *et al.* Epstein-barr virus-associated hemophagocytic lymphohistiocytosis in adults characterized by high viral genome load within circulating natural killer cells. *Clin Infect Dis* 2010; **51**: 66–9.
35. Uslu N, Demir H, Balta G, *et al.* Hemophagocytic syndrome in a child with severe Crohn's disease and familial Mediterranean fever. *J Crohns Colitis* 2010; **4**: 341–4.
36. Deneau M, Wallentine J, Guthery S, *et al.* Natural killer cell lymphoma in a pediatric patient with inflammatory bowel disease. *Pediatrics* 2010; **126**: e977–81.
37. Petrache A, Møller MB, Frederiksen H. Hemophagocytosis associated with cytomegalovirus infection and azathioprine treatment for inflammatory bowel disease. *Ugeskr Laeger* 2010; **172**: 52–3.
38. Kim YC, Kim GM, Lee HS, *et al.* A case of hemophagocytic syndrome in an ulcerative colitis patient. *Korean J Gastroenterol* 2010; **56**: 45–8.
39. Ross S, Rajwal SK, Sugarman I, *et al.* Epstein-barr virus-associated lymphoproliferative disorder in Crohn disease treated with azathioprine. *J Pediatr Gastroenterol Nutr* 2010; **51**: 229–31.
40. Gunson RN, Hague R, Gartner B, Aitken C. A case of a girl presenting with fever, cytopenia, liver dysfunction, hepatosplenomegaly, and hemophagocytosis in the bone marrow. *J Clin Virol* 2011; **51**: 1–3.
41. Côté-Daigneault J, Bernard EJ. Hepatosplenic lymphoma presenting initially as hemophagocytic syndrome in a 21-year-old man with Crohn's disease: a case report and literature review. *Can J Gastroenterol* 2011; **25**: 417–8.
42. Lo Presti MA, Costantino G, Della Torre A, Belvedere A, Cascio A, Fries W. Severe CMV-related pneumonia complicated by the hemophagocytic lymphohistiocytic (HLH) syndrome in quiescent Crohn's colitis: harmful cure? *Inflamm Bowel Dis* 2011; **17**: e145–6.
43. Salado CT, Gallego AG, Carnerero EL, *et al.* Hemophagocytic lymphohistiocytosis in Crohn's disease associated with primary infection by Epstein-Barr virus. *Inflamm Bowel Dis* 2011; **17**: e143–4.
44. Biank VF, Sheth MK, Talano J, *et al.* Association of Crohn's disease, thiopurines, and primary epstein-barr virus infection with hemophagocytic lymphohistiocytosis. *J Pediatr* 2011; **159**: 808–12.
45. van Langenberg DR, Morrison G, Foley A, Buttigieg RJ, Gibson PR. Cytomegalovirus disease, haemophagocytic syndrome, immunosuppression in patients with IBD: 'A cocktail best avoided, not stirred'. *J Crohns Colitis* 2011; **5**: e469–72.
46. Duque G, Ferreira R, Figueiredo P, *et al.* Rare cause of fever in a patient with ulcerative colitis. *Inflamm Bowel Dis* 2011; **17**: e64–5.
47. Ingvarsen JC, Ballegaard VC, Homøe P. Fatal haemophagocytic lymphohistiocytosis and mononucleosis in a patient with colitis ulcerosa. *Ugeskr Laeger* 2012; **174**: 1461–2.
48. Munoz J, Shareef N, Donthireddy V. Cytomegalovirus-induced haemophagocytic lymphohistiocytosis syndrome. *BMJ Case Rep* 2012; doi:10.1136/bcr.10.2011.4963 [Epub ahead of print].
49. Altaf S, Atreaga GM, Joshi AY, Rodriguez V. Diffuse large B-cell lymphoma in an adolescent female presenting with Epstein-Barr virus-driven hemophagocytic lymphohistiocytosis: a case report. *J Med Case Rep* 2012; **6**: 141.
50. Fitzgerald MP, Armstrong L, Hague R, Russell RK. A case of EBV driven haemophagocytic lymphohistiocytosis complicating a teenage Crohn's disease patient on azathioprine, successfully treated with rituximab. *J Crohns Colitis* 2013; **7**: 314–7.
51. Weinkove R, Dickson M, Eliadou E, Stace NH, Goossens L, Ferguson P. Fever and pancytopenia in a patient with Crohn's disease. *Gut* 2012; doi:10.1136/gutjnl-2012-303632 [Epub ahead of print].
52. Sun XH, Zheng WJ, Zhang W, Zhao Y. A clinical analysis of hemophagocytic syndrome in autoimmune diseases. *Zhonghua Nei Ke Za Zhi* 2010; **49**: 836–40.
53. Garrido-Serano A, Pérez Martón F, Guerrero Igea FJ, Galbarro Muñoz J, Palomo Gil S. Fatal infectious mononucleosis during azathioprine treatment in Crohn's disease. *Gastroenterol Hepatol* 2000; **23**: 7–8.
54. Weinberg I, Neuman T, Margalit M, Ayman F, Wolf DG, Ben-Yehuda A. Epstein-barr virus-related diarrhea or exacerbation of inflammatory bowel disease: diagnostic dilemma. *J Clin Microbiol* 2009; **47**: 1588–90.
55. Moltó A, Mateo L, Lloveras N, Olivé A, Mínguez S. Visceral leishmaniasis and macrophagic activation syndrome in a patient with rheumatoid arthritis under treatment with adalimumab. *Joint Bone Spine* 2010; **77**: 271–3.
56. Tiede I, Fritz G, Strand S, *et al.* CD28-dependent Rac1 activation is the molecular target of azathioprine in primary human CD4 + T lymphocytes. *J Clin Invest* 2003; **111**: 1133–45.
57. Toruner M, Loftus EV Jr, Harmsen WS, *et al.* Risk factors for opportunistic infections in patients with inflammatory bowel disease. *Gastroenterology* 2008; **134**: 929–36.
58. Green MR, Kennell AS, Larche MJ, Seifert MH, Isenberg DA, Salaman MR. Natural killer cell activity in families of patients with systemic lupus erythematosus: demonstration of a killing defect in patients. *Clin Exp Immunol* 2005; **141**: 165–73.
59. Vacher-Coponat H, Brunet C, Moal V, *et al.* Tacrolimus/mycophenolate mofetil improved natural killer lymphocyte reconstitution one year after kidney transplant by reference to cyclosporine/azathioprine. *Transplantation* 2006; **82**: 558–66.
60. Behrens EM, Canna SW, Slade K, *et al.* Repeated TLR9 stimulation results in macrophage activation syndrome-like disease in mice. *J Clin Invest* 2011; **121**: 2264–77.

61. Parodi A, Davò S, Pringe AB, *et al.* Lupus Working Group of the Paediatric Rheumatology European Society. Macrophage activation syndrome in juvenile systemic lupus erythematosus: a multinational multicenter study of thirty-eight patients. *Arthritis Rheum* 2009; **60**: 3388–99.
62. Avalos AM, Busconi L, Marshak-Rothstein A. Regulation of autoreactive B cell responses to endogenous TLR ligands. *Autoimmunity* 2009; **43**: 76–83.
63. Behrens EM, Beukelman T, Paessler M, Cron RQ. Occult macrophage activation syndrome in patients with systemic juvenile idiopathic arthritis. *J Rheumatol* 2007; **34**: 1133–8.
64. Fall N, Barnes M, Thornton S, *et al.* Gene expression profiling of peripheral blood from patients with untreated new-onset systemic juvenile idiopathic arthritis reveals molecular heterogeneity that may predict macrophage activation syndrome. *Arthritis Rheum* 2007; **56**: 3793–804.
65. Seksik P, Cosnes J, Sokol H, Nion-Larmurier I, Gendre JP, Beaugerie L. Incidence of benign upper respiratory tract infections, HSV and HPV cutaneous infections in inflammatory bowel disease patients treated with azathioprine. *Aliment Pharmacol Ther* 2009 May 15; **29**(10): 1106–13.
66. Beaugerie L, Brousse N, Bouvier AM, *et al.* CESAME Study Group. Lymphoproliferative disorders in patients receiving thiopurines for inflammatory bowel disease: a prospective observational cohort study. *Lancet* 2009; **374**: 1617–25.
67. Hahn G, Jores R, Mocarski ES. Cytomegalovirus remains latent in a common precursor of dendritic and myeloid cells. *Proc Natl Acad Sci USA* 1998; **95**: 3937–42.
68. de Jong MD, Boucher CA, Danner SA, *et al.* Summary of the international consensus symposium on management of HIV, CMV and hepatitis virus infections. *Antiviral Res* 1998; **37**: 1–16.
69. Staras SA, Flanders WD, Dollard SC, Pass RF, McGowan JE Jr, Cannon MJ. Cytomegalovirus seroprevalence and childhood sources of infection: a population-based study among pre-adolescents in the United States. *J Clin Virol* 2008; **43**: 266–71.
70. Cohen JL. Epstein-barr virus infection. *N Engl J Med* 2000; **343**: 481–92.
71. Fatahzadeh M, Schwartz RA. Human herpes simplex virus infections: epidemiology, pathogenesis, symptomatology, diagnosis, and management. *J Am Acad Dermatol* 2007; **57**: 737–63.
72. Arvin A, Gershon A, Seward J, Galil K, Wharton M. Epidemiology of varicella. In: Mandell GL, Bennett GE, Dolin R, eds. *Principles and Practice of Infectious diseases. Varicella-Zoster Virus*. Cambridge University Press, 2000; 187–205.
73. Rahier JF, Ben-Horin S, Chowers Y, *et al.* on behalf of the European Crohn's and Colitis Organisation (ECCO). European evidence-based Consensus on the prevention, diagnosis and management of opportunistic infections in inflammatory bowel disease. *J Crohns Colitis* 2009; **3**: 47–91.
74. Wong GH, Goeddel DV. Tumour necrosis factors alpha and beta inhibit virus replication and synergize with interferons. *Nature* 1986; **323**: 819–22.
75. Pérez-Sola MJ, Torre-Cisneros J, Pérez-Zafra B, Carmona L, Descalzo MAGómez-Reino JJ, BIOBADASER Study Group. Infections in patients treated with tumor necrosis factor antagonists: incidence, etiology and mortality in the BIOBADASER registry. *Med Clin (Barc)* 2011; **137**: 533–40.
76. Lawrance IC, Radford-Smith GL, Bampton PA, *et al.* Serious infections in patients with inflammatory bowel disease receiving anti-tumor-necrosis-factor-alpha therapy: an Australian and New Zealand experience. *J Gastroenterol Hepatol* 2010; **25**: 1732–8.
77. Lavagna A, Bergallo M, Daperno M, *et al.* Infliximab and the risk of latent viruses reactivation in active Crohn's disease. *Inflamm Bowel Dis* 2007; **13**: 896–902.
78. Torre-Cisneros J, Del Castillo M, Castón JJ, Castro MC, Pérez V, Collantes E. Infliximab does not activate replication of lymphotropic herpesviruses in patients with refractory rheumatoid arthritis. *Rheumatology (Oxford)* 2005; **44**: 1132–5.
79. Davignon JL, Boyer JF, Jarnard B, Nigon D, Constantin A, Cantagrel A. Maintenance of cytomegalovirus-specific CD4pos T-cell response in rheumatoid arthritis patients receiving anti-tumor necrosis factor treatments. *Arthritis Res Ther* 2010; **12**: R142.
80. Cascio A, Iaria C, Ruggeri P, Fries W. Cytomegalovirus pneumonia in patients with inflammatory bowel disease: a systematic review. *Int J Infect Dis* 2012; **16**: e474–9.
81. Shale MJ, Seow CH, Coffin CS, Kaplan GG, Panaccione R, Ghosh S. Review article: chronic viral infection in the anti-tumour necrosis factor therapy era in inflammatory bowel disease. *Aliment Pharmacol Ther* 2010; **31**: 20–34.
82. McKeown E, Pope JE, Leaf S. Epstein-barr virus (EBV) prevalence and the risk of reactivation in patients with inflammatory arthritis using anti-TNF agents and in those who are biologic naive. *Open Rheumatol J* 2009; **3**: 30–4.
83. Kotlyar DS, Osterman MT, Diamond RH, *et al.* A systematic review of factors that contribute to hepatosplenic T-cell lymphoma in patients with inflammatory bowel disease. *Clin Gastroenterol Hepatol* 2011; **9**: 36–41.
84. Gupta A, Tyrrell P, Valani R, Benseler S, Weitzman S, Abdelhaleem M. The role of the initial bone marrow aspirate in the diagnosis of hemophagocytic lymphohistiocytosis. *Pediatr Blood Cancer* 2008; **51**: 402–4.
85. Freeman HR, Ramanan AV. Review of haemophagocytic lymphohistiocytosis. *Arch Dis Child* 2011; **96**: 688–93.
86. Janka GE. Familial and acquired hemophagocytic lymphohistiocytosis. *Eur J Pediatr* 2007; **166**: 95–109.
87. Lin TF, Ferlic-Stark LL, Allen CE, Kozinetz CA, McClain KL. Rate of decline of ferritin in patients with hemophagocytic lymphohistiocytosis as a prognostic variable for mortality. *Pediatr Blood Cancer* 2011; **56**: 154–5.
88. Witkowska AM. On the role of sIL-2R measurements in rheumatoid arthritis and cancers. *Mediators Inflamm* 2005; **3**: 121–30.
89. Russell SE, Moore AC, Fallon PG, Walsh PT. Soluble IL-2R α (sCD25) exacerbates autoimmunity and enhances the development of Th17 responses in mice. *PLoS ONE* 2012; **7**: e47748.
90. Blessing J, Prada A, Siegel DM, *et al.* The diagnostic significance of soluble CD163 and soluble interleukin-2 receptor alpha-chain in macrophage activation syndrome and untreated new-onset systemic juvenile idiopathic arthritis. *Arthritis Rheum* 2007; **56**: 965–71.
91. Jordan MB, Allen CE, Weitzman S, Filipovich AH, McClain KL. How I treat hemophagocytic lymphohistiocytosis. *Blood* 2011; **118**: 4041–52.