


Contents lists available at [SciVerse ScienceDirect](http://SciVerse.Sciencedirect.com)

International Journal of Gerontology

journal homepage: www.ijge-online.com

Case Report

Multidisciplinary Approach for a Relapsing Goiter with Severe Tracheal Stenosis: A Case Report in an Elderly Patient[☆]

Damiano Giuseppe^{1,2}, Maione Carolina^{1,2}, Palumbo Vincenzo Davide^{1,2}, Calvagna Cristiano^{1,2}, Spinelli Gabriele^{1,2}, Lo Monte Attilio Ignazio^{1,2,3,4*}

¹ University of Palermo, ² School of Medicine, ³ School of Biotechnology, ⁴ Department of General Surgery and Organ Transplantation (GEN.UR.T.O.), Palermo, Italy

ARTICLE INFO

Article history:

Received 1 October 2010
Received in revised form
8 December 2010
Accepted 5 March 2011
Available online 30 March 2012

Keywords:

complication,
Dumon prosthesis,
Montgomery prosthesis,
thyroid,
thyroidectomy

SUMMARY

Total thyroidectomy is considered the gold standard for thyroid benign pathology treatment. Unfortunately, many partial interventions carried out in the past created many complications due to the tendency of the goiter to relapse and the formation of adhesions in the anterior region of the neck. A woman 72 years of age with a relapsing goiter and severe respiratory symptomatology underwent thyroidectomy. After thyroid removal, tracheal stenosis persisted, making the positioning of a T silicon prosthesis (Montgomery's T-tube) necessary. After 60 days, the prosthesis was replaced with a new made out of the same material but with a larger diameter and a softer consistency, which was removed after 4 months. The patient completely recovered her respiratory function and also maintained normal vocal cord activity without any kind of surgical sequelae. The full success was possible because of the involvement of different specialists.

Copyright © 2012, Taiwan Society of Geriatric Emergency & Critical Care Medicine. Published by Elsevier Taiwan LLC. All rights reserved.

1. Introduction

Surgical reintervention on thyroid gland for nonmalignant pathologies is a rare event, which is primarily related to previous cases that dealt with a partial intervention. According to the medical literature, this kind of therapeutic management is carried out in 10%–20% of patients^{1,2}, whereas thyroid pathology recurrence occurs in 12% of all surgical interventions³. Because of a higher risk of complications linked to the difficult surgical technique, in the last few years partial thyroidectomy has been abandoned on behalf of the more invasive, but also more effective, radical intervention¹.

Even today reinterventions on residual glands must be carried out and sometimes require the collaboration of surgical teams from different specialties in different temporal steps, especially when a great temporal gap among the time of partial intervention and the reintervention passes or due to the different individual tendency in adhesions formation or the type of underlying thyroid pathology (e.g., autoimmune thyroiditis).

2. Case report

A woman aged 72 years of age who underwent subtotal thyroidectomy 40 years before presented to our clinic with a huge subhyoid swelling that was created in only 2 months. Respiratory symptomatology was very important and it was characterized as rest dyspnea and frequent asphyctic fits on clinostatism. On physical examination, the thyroid had considerably increased in volume (maximum diameter of about 10 cm), especially in the right side of the neck; it was of hard consistency and firm in deep layers. Chest radiography showed a remarkable lateral deviation of the tracheal axis (Fig. 1). Taking into consideration the clinical and radiographic picture, there was indication for a surgical intervention, and a computed tomography (CT) scan⁴ was performed to explore the anterior mediastinum in more detail. The CT scan confirmed the tracheal deviation and also provided evidence of a tracheal stenotic segment with a diameter of 7 mm in the point of major compression and deviation of the esophagus (Fig. 2). Such conditions occur in 27% of patients suffering from nodular goiter with respiratory symptoms⁵. The goiter extended from hyoid bone to the aortic arc. Such retrosternal goiters represent a diagnostic dilemma, because their dimensions and the compressive symptoms can often mimic many malignant pathologies, therefore making therapeutic management difficult⁶. On the basis of the anatomical data alone, an anaplastic thyroid carcinoma was suspected. At this point, the patient underwent otorhinolaryngologic and

[☆] All contributing authors declare no conflicts of interest.

* Correspondence to: Dr Lo Monte Attilio Ignazio, Department of General Surgery and Organ Transplantation (GEN.UR.T.O.), University of Palermo School of Medicine, Via del Vespro, 129, 90127 Palermo, Italy.

E-mail address: ailomonte@unipa.it (L.M. Attilio Ignazio).

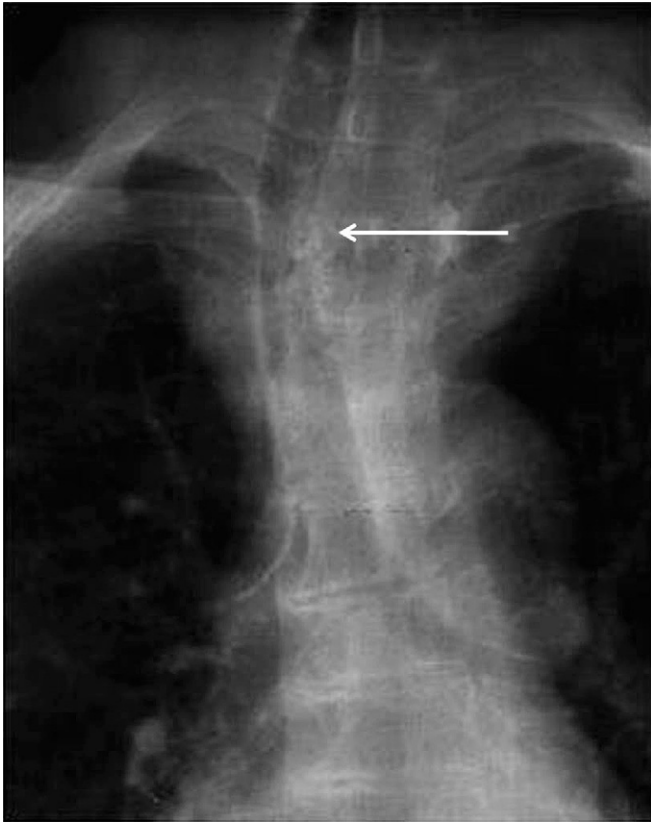


Fig. 1. Chest radiography. There is lateral deviation of the trachea (arrow).

anesthesiologic consultations. The former clarified that there was indication to tracheostomy, and the latter remarked the absolute necessity to perform that kind of surgical maneuver, considering the impossibility to allocate an endotracheal tube with the same dimensions of the stenosis.

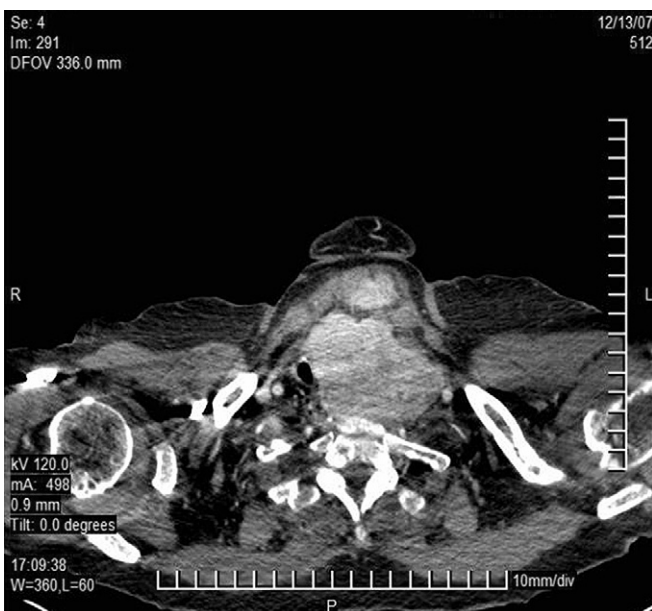

Fig. 2. Computed tomography scan. There is mediastinum involvement with tracheal stenosis and esophageal deviation due to the retrosternal goiter.

Because of the precipitation of the respiratory function, an urgent tracheostomy with local anaesthesia was performed by the otolaryngologist and, at the same time, a biopsy of the gland was performed. After the procedure, the patient incurred several episodes of asphyctic fits that required continuous medical assistance. After 1 week, histologic examination showed a multinodular macrofollicular goiter. Therefore, taking into consideration the relative benign aspect of the pathology, and in spite of the high risk of the procedure, the patient, fully knowing, decided to undergo thyroidectomy, which was performed by an endocrine surgeon in collaboration with the otorhinolaryngologist. The operation was very difficult because of the presence of the tracheal stent, which imposed an incision more cranial than the classical Kocher one; furthermore, the huge presence of adhesions made the detection of inferior laryngeal nerves and parathyroid glands impossible. After the removal of the thyroid, the stenosis persisted and maintenance of the tracheostomy was necessary. After consulting a thoracic surgeon, we agreed upon the positioning of a T silicon prosthesis (Montgomery's T-tube), which usually employed in permanent stenosis (Fig. 3)⁷. After about 5 days after this intervention, the patient recovered her physiologic respiratory and phonatory activity and avoided the auxilium of tracheostomy. After 60 days, a Montgomery prosthesis was replaced with a new one of the same material but with a larger diameter and softer consistency and a cylindric shape (Tracheobronxane™ Dumon® silicone stent-Novatech, La Ciotat Cedex, France); this new implant was removed after 4 months.

The patient completely recovered her respiratory function, as reported by functional examinations (spirometry, hemogas analysis), and maintained normal vocal cord activity without any kind of surgical sequelae.

3. Discussion

The complexity of the reported case was due to the long interval of time elapsed from the first operation and the final surgical resolution as well as because of the severe clinical symptomatology she experienced when she was first admitted to our clinic. The rapid worsening of the respiratory clinical picture associated with a sudden thyroid volume growth suggested the possibility of a highly malignant pathology, besides being supported by an imaging profile, which was only susceptible of a palliative treatment. A



Fig. 3. Positioning of Montgomery's T-tube.

rescue intervention was necessary to save this patient's life. The choice of a complex surgical team composed of an otorhinolaryngologist and an endocrine surgeon helped give the patient a chance at survival; this same team helped us reach the right diagnosis by means of surgical biopsy specimens. The resolved intervention, which was carried out in election and with the precious collaboration of the thoracic surgeon, who solved the tracheal stenotic complication, led to this good final result, with the patient experiencing recovered physiologic functions.

4. Conclusion

The above case report is an emblem of complexity in relapsing thyroid pathology, and a multidisciplinary approach was necessary to contain the complications linked to this reintervention maneuver. In fact, just the synergy of the different professional figures in different moments of the diagnostic and therapeutic iter led us not only to act with timeliness in a moment of urgency but also to reach the appropriate diagnosis and the resolution of the severe clinical picture. The right integration of different professional

figures was crucial to guaranteeing the solution of such a difficult and complex case, thus allowing the patient to maintain a quality of life adequate to perform all of the daily activities normal for a woman of her age.

References

1. Snook KL, Stalberg PL, Sidhu SB, et al. Recurrence after total thyroidectomy for benign multinodular goiter. *World J Surg.* 2007;31:593–600.
2. Moalem J, Suh I, Duh QY. Treatment and prevention of recurrence of multinodular goiter: an evidence-based review of the literature. *World J Surg.* 2008;32:1301–1312.
3. Shaha AR. Surgery for benign thyroid disease causing tracheoesophageal compression. *Otolaryngol Clin North Am.* 1990;23:391–401.
4. Toyota K, Uchida H, Ozasa H, et al. Preoperative airway evaluation using multi-slice three-dimensional computed tomography for a patient with severe tracheal stenosis. *Br J Anaesth.* 2004;93:865–867.
5. Miller MR, Pincock AC, Oates GD, et al. Upper airway obstruction due to goitre: detection, prevalence and results of surgical management. *Q J Med.* 1990;274:177–188.
6. Shah PJ, Bright T, Singh SS, et al. Large retrosternal goitre: a diagnostic and management dilemma. *Heart Lung Circ.* 2006;15:151–152.
7. Liu HC, Lee KS, Huang CJ, et al. Silicone T-tube for complex laryngotracheal problems. *Eur J Cardiothorac Surg.* 2002;21:326–330.