

Management of benign paroxysmal positional vertigo of lateral semicircular canal by Gufoni's manoeuvre

Riggio Francesco, MD, PhD^a, Dispenza Francesco, MD^{a,*},
Gallina Salvatore, MD, PhD^a, Kulamarva Gautham, MS, DNB, MRCS, DOHNS^b,
Gargano Rosalia, MD, PhD^a, Speciale Riccardo, MD^a

^aDipartimento Scienze Otorinolaringoiatriche, Università degli Studi di Palermo, Palermo, Italy

^bENT Clinic Nayak's Road, Kasaragod, India

Received 7 January 2008

Abstract

Benign paroxysmal positional vertigo (BPPV) of lateral semicircular canal (LSC) is one of the rarer forms of BPPV as compared to posterior semicircular canal BPPV. Various particle repositioning manoeuvres have been described in the literature as a mode of treating this condition.

Purpose: Evaluation and discussion of the procedure of the Gufoni's manoeuvre and its advantages in the treatment of BPPV of LSC.

Material and methods: Prospective study of 58 patients affected by LSC BPPV who were office-treated with Gufoni's manoeuvre.

Results: Seventy-nine percent of the patients so treated had complete resolution of symptoms, and 6.9% did not show any improvement in their symptoms. The remaining 13.8% had a conversion into posterior semicircular canal BPPV during treatment and were successfully treated with Epley's or Semont's manoeuvre.

Conclusions: Gufoni's manoeuvre is effective in treating patients suffering from BPPV of LSC; it is simple to perform; there are not many movements to execute, it needs low time of positioning, and positions are comfortable to the patient.

© 2009 Elsevier Inc. All rights reserved.

1. Introduction

Any patient presenting with history of vertigo is a challenge for the ear, nose, and throat (ENT) specialist. Vertigo affects the patients both physically and psychologically as it becomes impossible for the patient to go through daily routines of life without external help from others. Many of these patients are usually managed by primary care physicians medically for a long time before they are referred to an ENT surgeon. Because of this reason, they have to go through several unnecessary diagnostic procedures before arriving at a diagnosis or being referred further to a specialist

centre. Fortunately, in patients affected by vertigo crisis due to benign paroxysmal positional vertigo (BPPV), correct diagnostic evaluation and appropriate management allows, in the great number of cases, to solve the problem quickly, without the need for any medical treatment.

Benign paroxysmal positional vertigo is the most common cause of peripheral vertigo [1]. It accounts for approximately 24% of all cases of peripheral vestibular disorders [2]. This type of vertigo is generally seen in individuals aged 40 years and older with the highest age distribution between 50 and 70 years [3]. The exact etiology of BPPV is still under debate. More than 50% of all reported cases are idiopathic in nature [4]. Classic BPPV involves the posterior semicircular canal (PSC) and represents the most common type of BPPV [3,5–7]. Lateral semicircular canal (LSC) BPPV accounts approximately for only 10–20% of all the patients presenting with BPPV [8]. In addition, treatment

* Corresponding author. Dipartimento Scienze Otorinolaringoiatriche, Università degli Studi di Palermo, 90127 Palermo, Italy. Tel.: +393334565471.
E-mail address: francesco-dispenza@libero.it (D. Francesco).

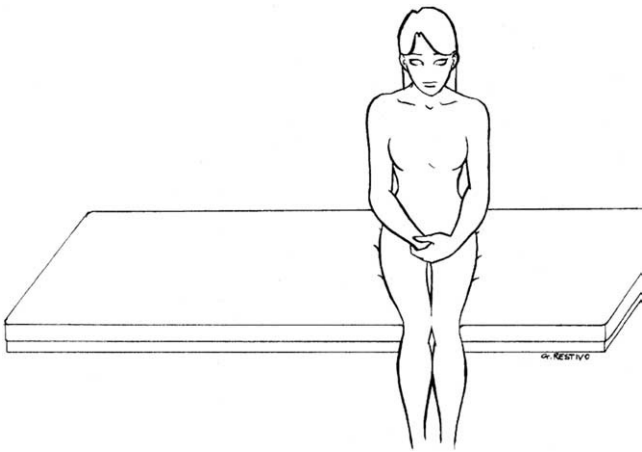


Fig. 1. Position 1, patient seated on the examination couch with both the legs hanging out from the same side, arms held close to the body and hands resting on the knees.

of LSC BPPV has got a lower success rate of between 60% and 90% as compared to PSC BPPV. Nuti et al [7] reported a success rate of 71% with barbecue rotation and 73% with forced prolonged position in patients with LSC-BPPV. Fife showed that 75% in 24 patients responded to the canalolith repositioning maneuver [8,9].

Diagnosis of BPPV is based mainly on a history of characteristic positional vertigo along with the classical clinical signs. Symptoms are similar for BPPV of LSC and PSC characterized by rotating vertigo with nausea and vomiting, elicited by movements of the head (when rising up or when lying down). The nystagmus typically has a latency (of few seconds) and is of limited duration, transient, fatigable, and reversible on return to upright position [5].

Patients of LSC BPPV have traditionally been treated with various particle repositioning manoeuvres. Therapeutic head-shaking, as suggested by Vannucchi et al [10], Lempert's so called "barbecue rotation" [11], Baloh's

modification of the same with 360° rotation [3], Vannucchi's forced prolonged position or FPP [12], Epley's 360° rotation suggested in 1995 [13] and modified Semont's manoeuvre are few of the various treatment modalities currently being followed in treating this condition [14]. Gufoni [15] proposed a repositioning manoeuvre based on the hypothesis of the presence of free-floating debris with a higher density than endolymphatic fluid in the anterior arm of the horizontal semicircular canal [16]. This manoeuvre has the advantage of simplicity while maintaining the efficacy in treating this condition. We studied 58 patients having horizontal semicircular canal BPPV who were treated with Gufoni's manoeuvre.

The aim of our study was to evaluate the efficacy of Gufoni's manoeuvre in office management of patients affected with BPPV of LSC.

2. Materials and methods

We prospectively studied 58 patients (23 men and 35 women), aged between 27 and 81 years, presenting with BPPV secondary to LSC in the period 2001–2004. The inclusion criteria were as follows: first-time diagnosis of BPPV of LSC, no previous medical treatment for vertigo, no history of chronic ear disease. We study only geotropic variant of LSC BPPV. All patients diagnosed and managed in the emergency department were excluded from the present study.

All the patients underwent ENT and head and neck examination, posture evaluation, pure tone audiometric test, impedance, and stapedial reflex study. Spontaneous nystagmus was assessed with Frenzel's glasses in the seated position, with head rotated to right and to left, in the supine position, and in the Rose' position (patient lay in supine position with the head falling down over the end of a table). Evoked nystagmus was evaluated by Dix-Hallpike's

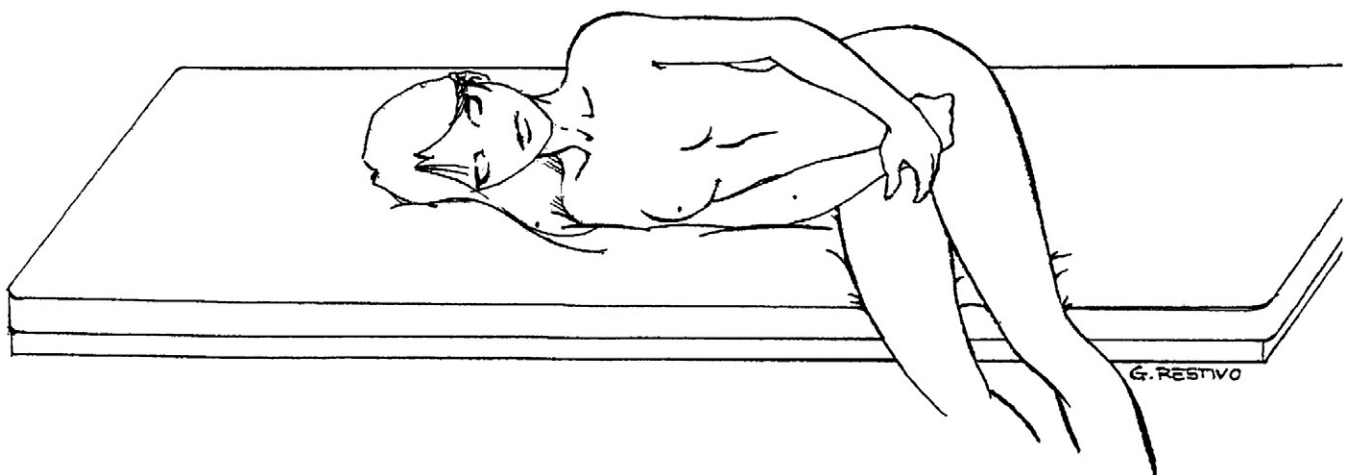


Fig. 2. Position 2, patient is then made to lie down on the uninvolved lateral side with a quick lateral movement and maintained in this position for 2 minutes until the end of evoked geotropic nystagmus.

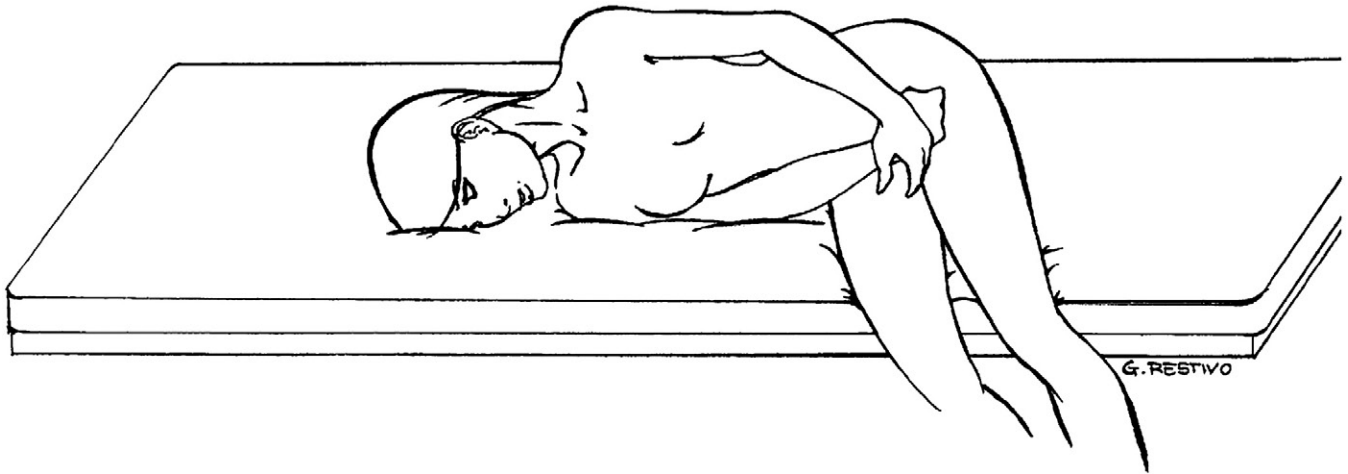


Fig. 3. Position 3, quick 45° rotation of the head towards the floor, position being maintained for 2 minutes.

manoeuvre [17] and by Pagnini's manoeuvre (patient in supine position and quick rotation of the head to right and to left) [10] in order to identify the involved semicircular canal. After ruling out other possible causes for the patients' symptoms, a diagnosis of LSC was arrived at.

Once the patients were diagnosed with BPPV of LSC, they were managed by Gufoni's manoeuvre.

Before performance of the treatment, an informed consent was obtained from each patient and the institutional ethical commission approved the procedure. This included putting

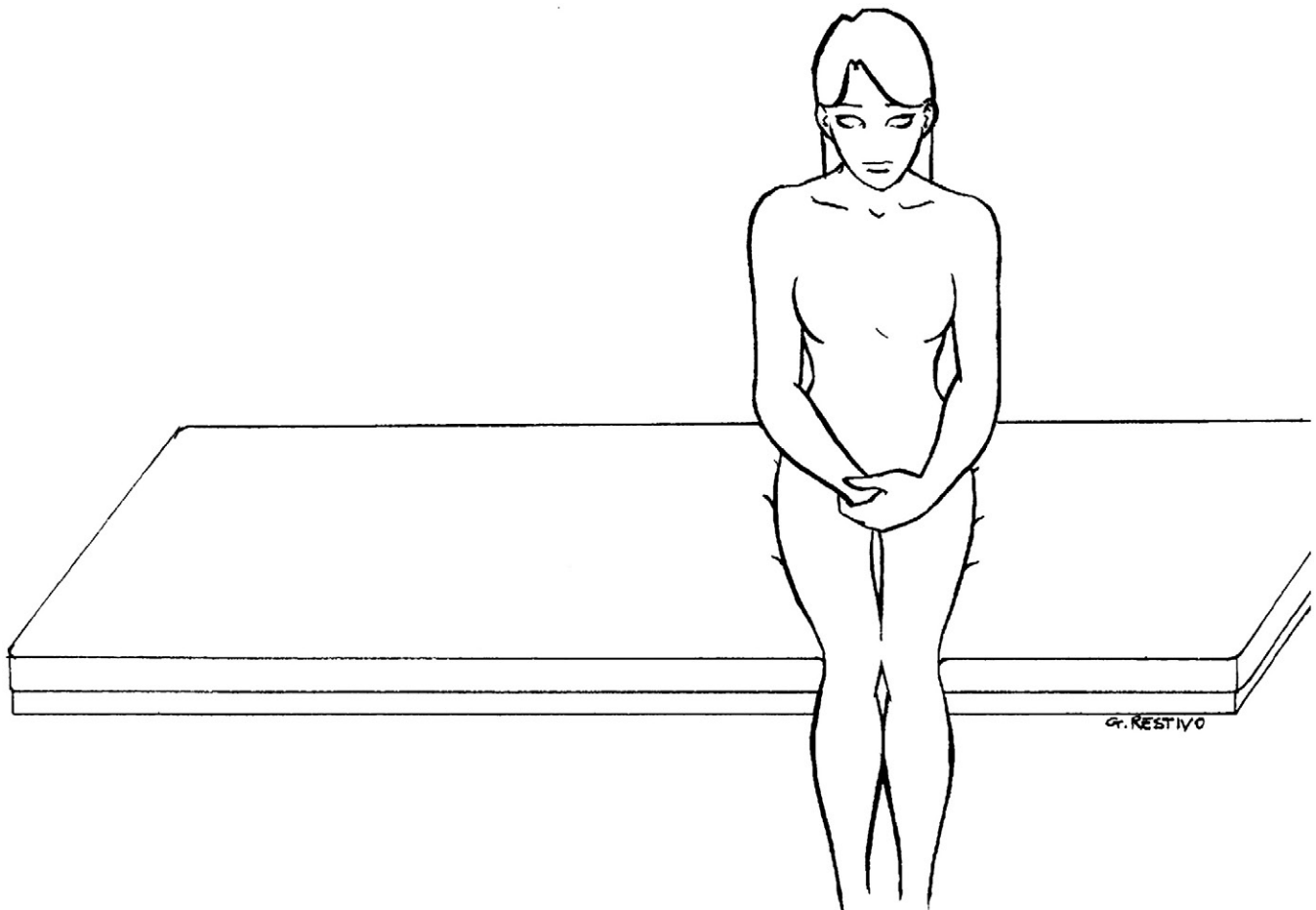


Fig. 4. Position 4, slow return back to the starting position.

Table 1
Outcome of treatment of BPPV of LSC by Gufoni's manoeuvre

| Patients | Outcome |
|------------|------------------------|
| 46 (79.3%) | Complete resolution |
| 8 (13.8%) | BPPV of PSC conversion |
| 4 (6.9%) | No benefits |
| 58 | |

BPPV: benign paroxysmal positional vertigo; LSC: lateral semicircular canal; PSC: posterior semicircular canal.

the patients through the following positions: (1) patient seated on the examination couch with both the legs hanging out from the same side, arms held close to the body, and hands resting on the knees (Fig. 1); (2) patient is then made to lie down on the uninvolved lateral side with a quick lateral movement and maintained in this position for 2 minutes until the end of evoked geotropic nystagmus (Fig. 2); (3) quick 45° rotation of the head towards the floor, position being maintained for 2 minutes (Fig. 3); (4) slow return back to the starting position (Fig. 4).

Gufoni's manoeuvre was executed twice, and after this, the patients were reevaluated. The presence of attenuated vertigo, or persistence of nystagmus, implies the need for a repetition of the manoeuvre. At the end of the treatment, patients were discharged home. Postural restriction, even during night, was not advised. First clinical follow-up was 3 days after the procedure. Patients were further followed up on 2 more occasions, at the end of the first week and again at 3 months after the initial procedure.

Our institutional review board reviewed and approved the present study, and an informed consent was obtained from all patients before treatment.

3. Results

In 46 patients (79.3%) we obtained a complete resolution of vertigo and nystagmus after the first session (Table 1). This improvement was maintained up to the last clinical review. In all these patients a slight sensation of unsteadiness was present for two weeks after the treatment, which however resolved completely, spontaneously. Eight patients (13.8%) had a conversion to PSC canalolithiasis during the treatment, and those patients were managed promptly with Epley's manoeuvre (6 cases) or Semont's manoeuvre (2 cases) with resolution of symptoms. Four patients (6.9%) did not have any benefit after the treatment. They were advised Vannucchi's positions with resolution of symptoms subsequently, after several weeks.

4. Discussion

Etiology of BPPV is not always related to a definite cause and may be a sequelae of several inner ear diseases such as posttraumatic, viral, and vascular causes, as is described in the literature [18]. However, 70% of cases are thought to be

idiopathic. Currently, the hypothesis that is widely accepted is that of displacement of otoliths from the utricular macula and consequent deposition of these fragments in the LSC or PSC. These otoliths provoke a piston-like mechanism of action on endolymph flowing from or toward the ampullae, causing activation or inhibition of the canals respectively [19]. Diagnosis of LSC BPPV is based on the history and features of the positioning nystagmus provoked by a quick turn of the head to either side with the patient lying supine. The characteristics of the positioning nystagmus leading to a diagnosis of LSC BPPV have been well summarized by Ciniglio Appiani et al [16] as having the following features typically: (1) very short latency (a few seconds), (2) paroxysmal character, (3) duration <1 minute, (4) purely horizontal (geotropic or apogeotropic direction changing) position and greater intensity on one side, and (5) not fatigable with repeated positioning.

Various manoeuvres have been proposed for the treatment of LSC BPPV. Most of these manoeuvres constitute quickly rolling the supine patient towards the unaffected side. This is thought to shift the otoconial debris out of the nonampullated end of the horizontal canal into the utricle [16]. Gufoni introduced a manoeuvre for treating LSC BPPV in 1998. The advantage of this manoeuvre was that, apart from showing very good results in geotropic LSC BPPV, it can be conducted even in patients with cervical spondylosis and obesity. This brisk deceleration manoeuvre was based on the rationale that the otoconial debris is moved from the lateral semicircular canal to the utricle, exploiting its inertia and correct disposition in the canal outlet, obtained by correct positioning of patient's head [12].

Based on this theory, the lateral decubitus position on the affected side should give rise to migration of otolithic debris to the posterior end of the lateral semicircular canal with a concomitant flow of endolymph toward the ampulla. This, in turn, causes activation of the hair cells with resultant vertigo and geotropic nystagmus. The rotation of the patient to the unaffected side should give rise to a reversal of flow with posterior migration of the otoliths and an inhibitory endolymphatic flow. In this case, the vertiginous symptoms are not as severe as in the precedent one, and also, the nystagmus is less intense. This pathophysiologic mechanism has 2 possible explanations: (1) Pagnini, in accordance with the Ewald's laws, suggested that after intense accelerations the excitatory stimulus is much more strong respect to inhibitory one [18]; (2) Baloh et al [4] hypothesized that otoliths present in the posterior arm of the LSC are placed in an asymmetric fashion and, consequently, the amplitude of its movement is different on assuming lateral decubitus posture on the affected and unaffected side, symptoms and nystagmus being much more intense on the affected side.

Gufoni's manoeuvre consists of the following steps (1) the patient sits on the edge of the bed; (2) the patient is made to lie down suddenly on one side: for geotropic LSC-BPPV, the patient lies on the healthy side, in the apogeotropic form on the affected side; (3) patient's head is rotated 45°

Table 2

Treatment and outcome of patients with benign paroxysmal positional vertigo of LSC with conversion to PSC after Gufoni's manoeuvre

| Patients with PSC conversion | Treatment | Outcome |
|------------------------------|--------------------|-----------------|
| 6 | Epley's manoeuvre | Resolution 100% |
| 2 | Semont's manoeuvre | Resolution 100% |

LSC: lateral semicircular canal; PSC: posterior semicircular canal.

downward and held for 2–3 minutes; (4) patient returns to sitting position; (5) outcome of the manoeuvre is checked. Vannucchi et al. [12] quoted a success rate of 96% for geotropic LSC BPPV and 77% for apogeotropic LSC BPPV. No side effects were observed in any of the 174 cases studied by them. Ciniglio Appiani et al [16], in their case review, quoted 100% success in 32 patients of geotropic LSC BPPV, treated with this manoeuvre, after 2 attempts. In comparison, we had an overall success of 93.1% in our patient population studied. In the first instance, 48 patients (79.3%) improved. The 8 patients (13.8%) whose vertigo was converted into a PSC BPPV had their vertigo corrected with Epley's manoeuvre or Semont's manoeuvre (Table 2). The remaining 4 patients (6.9%) who did not benefit from this manoeuvre were advised Vannucchi's forced prolonged position with which their symptoms resolved subsequently. All the patients complied well with our treatment, and there were no dropouts. In addition, we didn't observe any adverse effects of this manoeuvre on any of our patients.

Gufoni's manoeuvre is believed to clear the nonampullary arm of the LSC from otoliths using gravity and inertia of the particles. The quick variation from seated position to lateral decubitus on the unaffected side, putting the LSC on a vertical plane, causes movement of otolithic debris towards the nonampullary end of the canal. The subsequent 45° downward head rotation moves the otoliths, by inertia, into the utricle [15]. One of the main advantages of this manoeuvre is its acceptability to the patients. This is because the patients are made to roll on to the unaffected side, making it more readily acceptable. This also helps to keep the dropout rates very low [12]. It is possible to execute the Gufoni's manoeuvre under videonystagmographic control in order to evaluate step by step the nystagmus and verifying the efficacy of the several positions as suggested by Asprella et al [2]. In situations where the patient is having neck pain/stiffness and severe neurovegetative symptoms such as vomiting, causing them to refuse this treatment; in very elderly patients; and also in severe obesity, repositioning the manoeuvre may be difficult to perform. In these patients who are unable to tolerate the positional manoeuvres or in whom the treatment is unsuccessful, vestibular suppressant drugs and vestibular rehabilitation may be used [14].

5. Conclusion

Gufoni's manoeuvre is effective in treating patients suffering from BPPV of LSC and offers significant

advantages. It is simple to perform; there are not many movements to execute, it needs low time of positioning, and positions are comfortable to the patient. Because of these favorable features, there are not many contraindications for its reasonable application in any patient. In our experience, we obtained good results in 79% (overall 93.1% after including the PSC-PPV converted patients) of the patients studied, and only 6.9% of patients did not have any benefit with this treatment. The clinical evidence, from the application of Gufoni's manoeuvre, allows considering its use as the treatment of first choice in cases of BPPV of LSC.

Acknowledgments

The authors thank Dr Giampaolo Restivo for the draw of the positions illustration.

References:

- [1] Asprella Libonati G, Gufoni M. Vertigine parossistica da CSL: manovre di barbecue ed altre varianti XVI Giornate Italiane di Otoneurologia. Revisione critica di venti anni di vertigine parossistica posizionale benigna. Sorrento (NA): Formenti; 1999. p. 321-36.
- [2] Asprella Libonati G, Gagliardi G, Cifarelli D, et al. Step by step treatment of lateral semicircular canal canalolithiasis under videonystagmographic examination. *Acta Otorhinolaryngol Ital* 2003;23: 10-5.
- [3] Baloh RW, Jacobson K, Honrubia V. Horizontal semicircular canal variant of benign positional vertigo. *Neurology* 1993;43:2542-9.
- [4] Baloh RW, Yue Q, Jacobson K, et al. Persistent direction-changing positional nystagmus: another variant of benign positional nystagmus? *Neurology* 1995;45:1297-301.
- [5] Casani A, Fattori B, Misale M, et al. Terapia delle VPPB del canale semicircularare posteriore. Tecniche a confronto. VII Giornata di Vestibologia Pratica. Siena: Formenti; 1998. p. 35-54.
- [6] Mc Clure JA. Horizontal canal BPV. *Am J Otolaryngol* 1985:14.
- [7] Nuti D, Vannucchi P, Pagnini P. Benign paroxysmal vertigo of the horizontal canal: a form of canalolithiasis with variable clinical features. *J Vest Res* 1996;6:173-84.
- [8] Choung YH, Shin YR, Kahng H, et al. Bow and Lean test to determine the affected ear of horizontal canal benign paroxysmal positional vertigo. *Laryngoscope* 2006;116:1776-81.
- [9] Chiou WY, Lee HL, Tsai SC, et al. A single therapy for all subtypes of horizontal canal positional. *Laryngoscope* 2006;115:1432-5.
- [10] Vannucchi P, Giannoni B, Pagnini P. Treatment of horizontal semicircular canal benign paroxysmal positional vertigo. *J Vest Res* 1997;7:1-6.
- [11] Lempert T, Tiel-Wilck K. A positional manoeuvre for treatment of horizontal canal benign positional vertigo. *Laryngoscope* 1996;106: 476-8.
- [12] Vannucchi P, Asprella Libonati G, Gufoni M. The physical treatment of lateral semicircular canal canalolithiasis. *Audiological Med* 2005;3: 52-6.
- [13] Epley JM. Positional vertigo related to semicircular canalolithiasis. *Otolaryngol Head Neck Surg* 1995;112:154-61.
- [14] Casani A, Vannucci G, Fattori B, et al. The treatment of horizontal canal positional vertigo: our experience in 66 cases. *Laryngoscope* 2002;112:172-8.
- [15] Gufoni M, Mastro Simone L. Trattamento con manovra di riposizionamento per la canalolithiasi orizzontale. *Acta Otorhinolaryngol Ital* 1998; 18:363-7.

- [16] Ciniglio Appiani G, Catania G, Gagliardi M. A liberatory maneuver for the treatment of horizontal canal paroxysmal positional vertigo. *Otol Neurotol* 2001;22:66-9.
- [17] Dix MR, Hallpike CS. Pathology, symptomatology and diagnosis of certain common disorders of the vestibular system. *Ann Otol Rhinol Laryngol* 1952;61:987-1016.
- [18] Cipparone L, Corridi G, Pagnini P, Cupololitiasi V. *Giornata Italiana di Nistagmografia Clinica*. San Marino: Formenti; 1985. p. 36-53.
- [19] Parnes LS, Mc Clure JA. Free-floating endolymph particles: a new operative finding during posterior semicircular canal occlusion. *Laryngoscope* 1992;102:988-92.