

REFERENCES

1. Punjasawadwong Y, Boonjeungmonkol N, Phongchiewboon A. Bispectral index for improving anaesthetic delivery and postoperative recovery. *Cochrane Database Syst Rev*. 2007;4:CD003843
2. Dahaba AA. Different conditions that could result in the bispectral index indicating an incorrect hypnotic state. *Anesth Analg*. 2005;101:765–773.
3. Dunham CM, Katradis DA, Williams MD. The bispectral index, a useful adjunct for the timely diagnosis of brain death in the comatose trauma patient. *Am J Surg*. 2009;198:846–851.
4. Seder DB, Fraser GL, Robbins T, et al. The bispectral index and suppression ratio are very early predictors of neurological outcome during therapeutic hypothermia after cardiac arrest. *Intensive Care Med*. 2010;36:281–288
5. Myles PS, Daly D, Silvers A, et al. Prediction of neurological outcome using bispectral index monitoring in patients with severe ischemic-hypoxic brain injury undergoing emergency surgery. *Anesthesiology*. 2009;110:1106–1115.

Taravana: Documentation of Bubbles by Computerized Tomography

To JNA Readership:

“Taravana” is a syndrome reported by Cross in 1962,¹ in which an unusual condition of decompression illness caused by repetitive breath hold (BH) diving. Although computerized tomography (CT) imaging of affected patients is commonly performed, the mechanisms of brain damage caused by BH diving remain uncertain.^{2,3} It has been postulated that nitrogen (N₂) bubbles, passing through the lungs or heart, becoming arterialized, would be the most likely etiologic factor.⁴ Nevertheless, such bubbles have never been detected by radiologic imaging techniques.

Here we report a case of a 41-year-old expert diver who, after a series of BH dives (60 to 80 s/dive at 20 to 24 m of depth for 5 consecutive hours), experienced vertigo, ringing in the left ear, and confusion, followed by right arm paresthesia trailed by right hemiparesis after a few minutes. After < 60 minutes from the emergence of these symptoms, he was admitted to the emergency unit of our hospital with less severe clinical features, presenting only

confusion and paresthesia of the right hand.

We immediately performed a brain CT scan that showed 4 cerebral bubbles, 3 in the left hemisphere (Fig. 1A) and 1 in the right (not shown) at the level of the internal carotid and ophthalmic arteries. After rehydration, pharmacologic therapy with parnaparin, recompression, and hyperbaric oxygen therapy, the symptoms disappeared and a new CT examination confirmed the disappearance of the bubbles (Fig. 1B).

To the best of our knowledge, this should be the first report of the documented presence of bubbles in a patient with Taravana Syndrome. We were probably able to visualize these bubbles in CT images because of the short period of time that passed between the emergence of the symptoms and the medical examination. These images support the hypothesis that nitrogen bubbles are responsible for symptoms in Taravana patients. In summary, we consider these images to be of significant interest for all

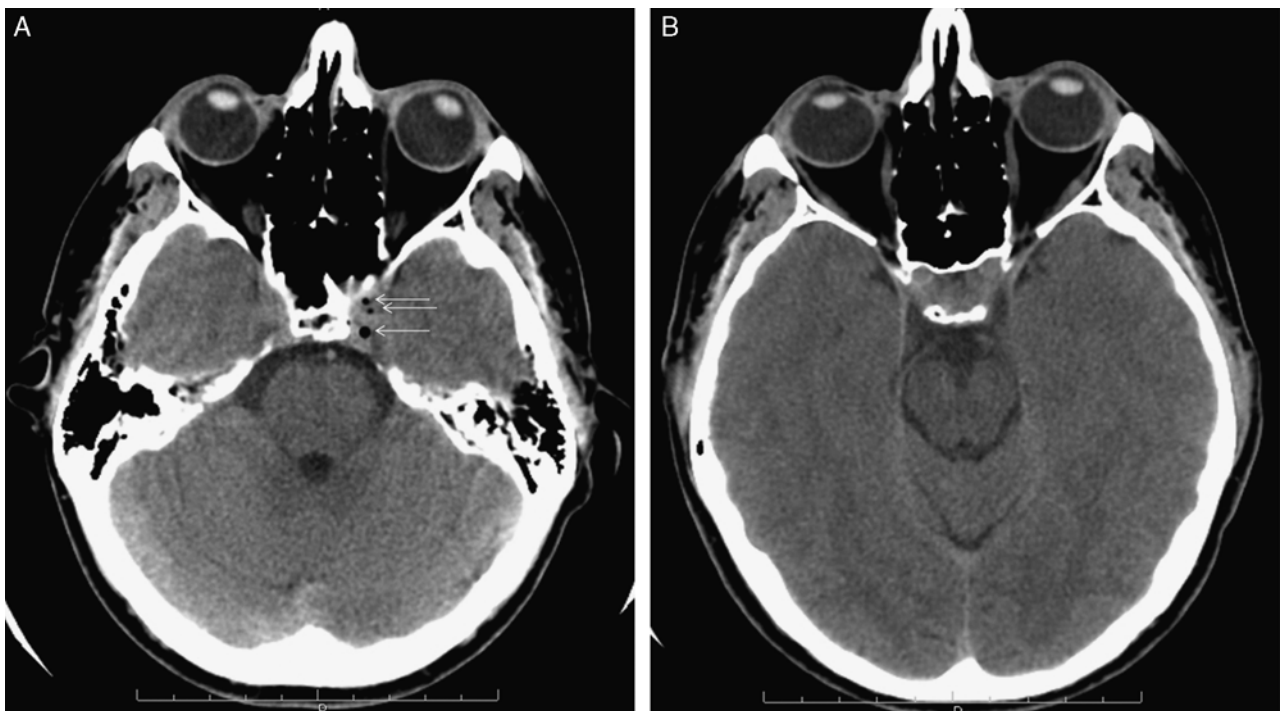


FIGURE 1. A, CT image showing 3 bubbles, 1 (posterior) into the left internal carotid artery and 2 (medial and anterior) into the left ophthalmic arteries. B, CT image of the same patient after treatment, showing disappearance of the bubbles. CT indicates computerized tomography.

physicians involved in the field of decompression illness.

Mario Alaimo, MD*
Giuseppe Aiello, MD*
Eduardo Marino, MD*
Leila Zummo, MD†

Francesco Cappello, MD†

*Servizio di Anestesia Rianimazione e
 Medicina Iperbarica

P.O. di Partinico, ASP Palermo

†Dipartimento di Biomedicina

Sperimentale e Neuroscienze Cliniche

Unniversità degli Studi di Palermo, Italy

REFERENCES

1. Cross ER. Taravana. *Skin Diver Magazine*. 1962;11:42–45.
2. Melamed Y, Shupak A, Bitterman H. Medical problems associated with underwater diving. *N Engl J Med*. 1992;326:30–35.
3. Kohshi K, Wong RM, Abe H, et al. Neurological manifestations in Japanese Ama divers. *Undersea Hyperb Med*. 2005;32:11–20.
4. Paulev P. Decompression sickness following repeated breath-hold dives. *J Appl Physiol*. 1965;20:1028–1031.

A Wake “Anesthesia” for Intraoperative Language Testing During Temporary Clip Application in a Patient With Giant Intracranial Aneurysm

To JNA Readers:

To the JNA readership, craniotomy with awake anesthesia is the preferable technique for neurosurgical procedures that require intraoperative localization of eloquent brain areas and for other functional neurosurgical procedures.^{1–5} We used this technique in a new setting to test motor and speech abilities during temporary arterial clipping in a patient undergoing surgical resection of a giant intracranial aneurysm.

A 46-year-old woman with a history of familiar arterial hypertension and a 4-month history of refractory

arterial hypertension and headache was referred to our hospital with an angiographically documented giant aneurysm involving a terminal branch of the left middle cerebral artery (maximum diameter 3.2 cm, Fig. 1). As a balloon occlusion test proved impossible during angiography, we decided to use awake “anesthesia” to test motor and speech abilities intraoperatively. For local anesthesia, 40 mL of 7.5% ropivacaine was injected through the left semilateral coronal line, into the surgical wound incision line, and the Mayfield head frame pin sites, and was also used for bilateral selective block of the supraor-

bital trigeminal nerve branches. Propofol was infused at the beginning and end of the surgical procedure at a dose of 0.1 to 0.5 mg/kg/h, and 2 additional boluses of 30 mg were given before bladder catheter placement and Mayfield head frame positioning. A 200 µg dose of fentanyl was infused: 100 µg before Mayfield head frame placement and 100 µg before skin incision. Mean arterial blood pressure was maintained within the range 75 and 95 mm Hg by infusing 2 mg of metoprolol and 30 mg of diltiazem throughout the procedure. Spontaneous ventilation with 50% O₂ effectively maintained normal blood

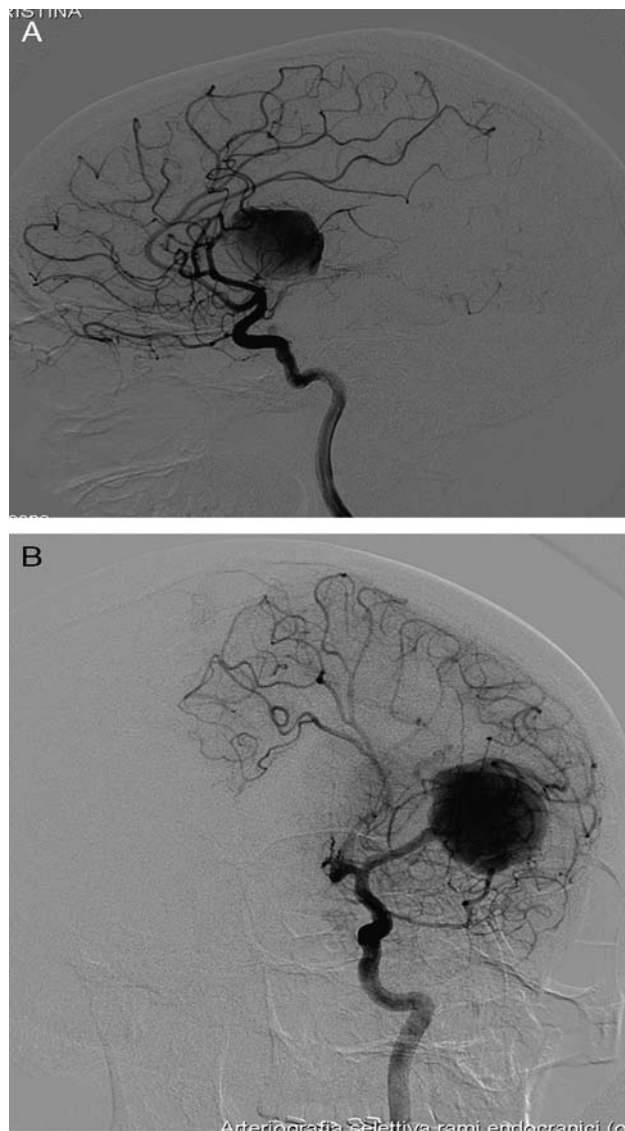


FIGURE 1. A, Preoperative angiogram, left lateral view; (B) Preoperative angiogram, a.p, AP view. These images show the giant aneurysm (max diameter 3.2 cm) and the inflow and outflow arteries [then why does the text say afferent?].