

## Original Study

# One-Trocar, Video-Assisted Stripping Technique for Use in the Treatment of Large Ovarian Cysts in Infants

Marcello Cimador, MD, Fabiola Sireci, MD, Maria Rita Di Pace, MD, and Enrico De Grazia, MD  
Pediatric Surgical Unit, Department of Mother and Child Care, Università di Palermo, Palermo, Italy

**Abstract.** *Background:* Management of ovarian cysts in infants is controversial; it can be conservative or surgical, and the management is determined by the cyst's size and sonographic features.

*Methods:* A surgical approach using a 10-mm umbilically placed operative laparoscope was taken in 3 female infants with antenatally diagnosed large, simple ovarian cysts. The contents of the cysts were partially aspirated and the cyst walls were stripped off the remaining ovarian parenchyma. No intraoperative or postoperative complications were recorded.

*Conclusions:* The one-trocar video-assisted stripping technique for large ovarian cysts in infants appears to be an ovarian-tissue-preserving procedure, and it sidesteps the disadvantages of large scars and formation of adhesions.

---

**Key Words.** Pediatric—Ovarian cyst—Laparoscopy—Stripping technique

---

### Introduction

Prenatal observation of ovarian cysts is occurring with increasing frequency during routine obstetric ultrasound scans.<sup>1</sup> The cause of fetal ovarian cysts is not entirely clear; ovarian hyperstimulation in full-term newborns is probably the result of placental insufficiency in addition to incomplete maturation of the gonadostat.<sup>2</sup>

The most common complication of ovarian cyst is torsion, which can occur during the fetal period in as much as 38% of cases<sup>1,3</sup> or during the neonatal period in 50% to 78% of cases.<sup>3</sup>

Preserving the ovary is the key goal in the management of these apparently benign lesions.

---

*Address correspondence to:* Marcello Cimador, MD, U.O. Chirurgia Pediatrica, Dipartimento Materno-Infantile, Università di Palermo, Via A.Giordano, 3,90100 Palermo, Italy; E-mail: [mcimador@unipa.it](mailto:mcimador@unipa.it)

Postpartum management remains somewhat controversial. It can be conservative in cases of simple, decreasing cysts, or it can be surgical in cases of complicated or symptomatic cysts and in simple cysts that increase in size or persist unchanged.

Stripping the cystic wall is the technique used by gynecologists for the treatment of large benign ovarian cysts.<sup>4</sup> The procedure can be performed by using an open<sup>5</sup> or a laparoscopic approach,<sup>4</sup> even if ovarian tissue is not macroscopically evident. This procedure helps to save the ovarian tissue.

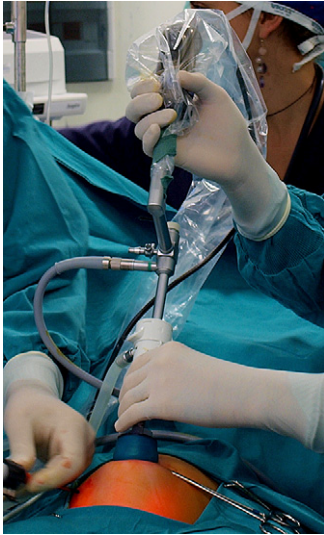We describe the technique of one-trocar, video-assisted stripping of three large ovarian cysts in infants.

### Materials and Methods

In our institution, three female infants (8 months, 4 months, and 2 months of age, respectively) underwent excision of large ovarian simple cysts. The children were born at full term. Antenatal ultrasound scans had shown a cyst in each ovary (two in the right ovary and one in the left), all of them entirely anechoic and characterized by thin walls. These findings were confirmed by postnatal ultrasound in all three of the babies.

The increase in size of the cysts was the indication for laparoscopy. The patients were treated under general anaesthesia, and the operations were performed using a 10-mm umbilically placed operative laparoscope (Fig. 1). A pneumoperitoneum was created at 8 mm Hg of pressure.

At first glance, the cysts were noted to originate in the ovary (Fig. 2A). The other adnexa were normal. The cysts were punctured transabdominally under direct vision, using a 16-gauge needle (Fig. 2B). The contents of the cysts (clean yellow fluid) were partially aspirated to allow delivery through the umbilical port. At surgery, the cyst walls were stripped off the remaining ovarian parenchyma by means of traction exerted in the opposite direction by the use of two atraumatic grasping forceps (Fig. 2C).



**Fig. 1.** View of operative laparoscope, 23 cm long.

When necessary, hemostasis was achieved by applying the bipolar forceps on the ovarian parenchyma after excision of the cystic wall. An uninterrupted suture was placed on the edge of the residual ovarian parenchyma. The cyst walls were sent for routine histologic examination.

Follow-up was performed by pelvic ultrasound at 3, 6, 12, and 18 months after surgery.

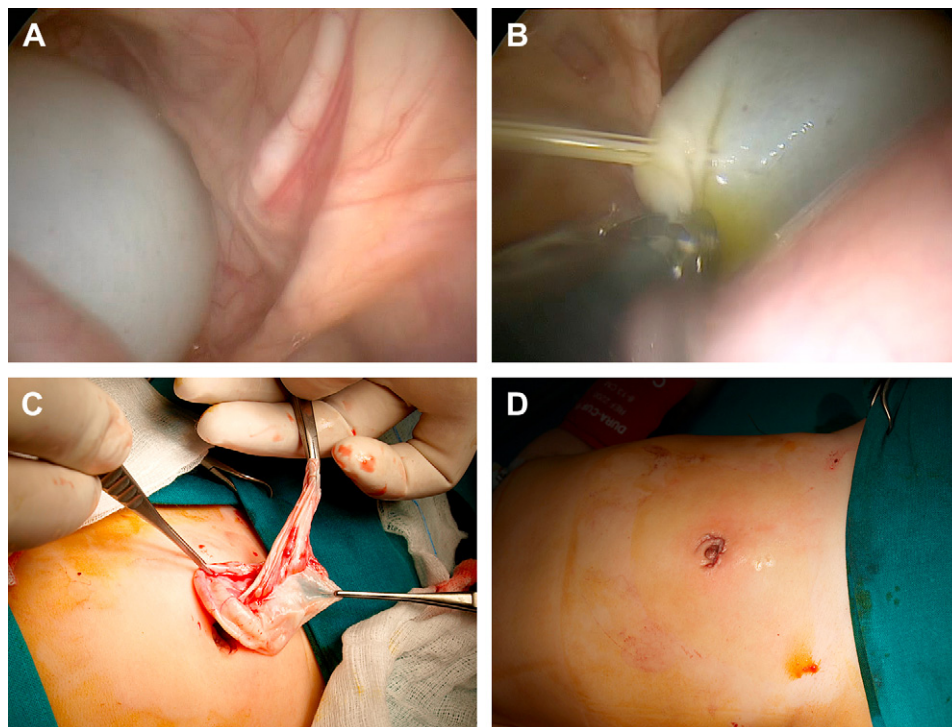
## Results

Each patient had a simple ovarian cyst that had been revealed prenatally by ultrasound scan. The operations were performed at 2 months (5.6 kg of weight); at 4 months (6.6 kg of weight); and at 8 months (8.3 kg of weight), respectively.

In the 2-month-old patient, the ovarian cyst had been diagnosed at 31.6 weeks of gestational age. The initial diameter was  $36 \times 40$  mm, but it increased progressively during pregnancy (it was 47 mm at 39 weeks of gestation). Follow-up ultrasound scans were done before surgery, and they showed that after birth the cyst measured  $34 \times 30$  mm, appearing as a simple cyst without calcifications; it measured  $60 \times 30$  mm at the time of surgery.

In the 4-month-old patient, the ovarian cyst was diagnosed at 34.3 weeks of gestational age and had a diameter of 19 mm, which increased progressively during pregnancy (it was  $44 \times 57$  mm at 37.5 weeks of gestation). During follow-up, at 1 month, the cyst measured 6.4 cm in diameter. The same measurements were seen at the time of surgery. It seemed to be a simple cyst, totally anechoic and with a thin wall.

In the 8-month-old patient, the ovarian cyst was diagnosed at 30 weeks of gestational age, when the diameter was  $45 \times 55$  mm. During follow-up ultrasound scans, the cyst measured  $50 \times 55$  mm after birth, and at time of surgery the cyst measured  $65 \times 50$  mm.



**Fig. 2.** Laparoscopic view of ovarian cyst. A, percutaneous puncture of the cyst under direct vision; B, stripping of the cystic wall; C, cosmetic appearance after surgery.

Also in this case, the cyst appeared to be a simple one, entirely anechoic and with a thin wall.

In all patients tumor markers (alpha-fetoprotein, beta-human chorionic gonadotropin) were within normal ranges. The mean operative time was 45 minutes. No complications resulted from the surgeries, and the patients were discharged 2 days after operation.

Histological evaluation demonstrated that cysts were simple and serous, with no malignancies. No ovarian tissue was found. Cosmetic results were excellent and follow-up results have been good; 6 months after surgery, ultrasound scans revealed the presence of ovarian tissue on the operated side.

## Discussion

The management of ovarian cysts in infants depends on cyst size and sonographic features. There is nearly general agreement about conservative management of simple cysts that are smaller than 4 cm. Most simple cysts resolve spontaneously in the first several months after birth. Esposito and colleagues suggested that prenatal aspiration of cysts larger than 4 cm should be considered so as to decrease the high incidence of ovarian loss<sup>6</sup>; this enforces the importance of antenatal diagnosis.

Nussbaum and colleagues have developed ultrasound diagnostic criteria that differentiate simple from complex ovarian cysts.<sup>3</sup> A simple cyst is anechoic and has an imperceptible wall, no solid components, and no fluid debris levels. A complicated cyst contains fluid debris levels, retracting clot, and septa or is completely filled with echoes that produce a solid mass-like appearance.<sup>3</sup> On the postnatal side, for cysts larger than 4 cm and for complicated cysts, treatment is recommended to avoid the risk for ovarian torsion and other complications, such as compression on the bowel, ureter, or inferior vena cava; rupture and peritonitis with hemoperitoneum; or incarceration in the canal of Nuck.<sup>7,8</sup>

The postnatal management options vary from repeated ultrasound-guided needle aspiration to laparotomy, laparoscopic oophorectomy, or ovarian cystectomy.<sup>6-9</sup>

Aspiration as opposed to surgery for an ovarian cyst is still controversial in the literature because there are some risks for complications resulting from needle puncture of the cyst. In the majority of cases the site produced by aspiration closes again and the cyst re-forms.<sup>10</sup> Percutaneous or laparoscopic needle aspiration have a recurrence rate ranging from 50%<sup>11</sup> to 84%.<sup>12</sup> Moreover, there is a direct correlation between cyst diameter and higher rate of recurrence.<sup>11</sup> On the other hand, laparoscopic excision of cysts shows

a very low rate of recurrence (4%; statistically significant  $P < .0001$ ).<sup>12</sup>

Furthermore, some authors<sup>5,13</sup> report that the stripping technique is a safe and effective ovarian-tissue-sparing procedure, even at the pediatric age.

The development of sophisticated microinstrumentation and the increasing experience of pediatric surgeons suggest that the laparoscopic approach is the most appropriate for the management of large ovarian cysts in infants.

Laparoscopy can be used to extend diagnostic capabilities (i.e., visualization and, if necessary, biopsy of the ovarian cyst) as well as to facilitate a smooth transition to therapeutic measures when necessary. It is well tolerated by neonates, even premature ones. Infants can well sustain pneumoperitoneum (maximum 8 mm Hg) with careful monitoring of carbon dioxide levels.

Decker and colleagues<sup>14</sup> have described a single case using a three-port technique. Van der Zee and colleagues<sup>15</sup> have described two cases in which they used a laparoscopic port and a small counterincision to remove an ovarian cyst. Esposito and colleagues<sup>6</sup> managed 22 benign cysts using a three-port technique, one of which underwent autoamputation.

We have utilized a one-trocar technique using a 10-mm operative laparoscope. The cysts were punctured transabdominally under direct vision, using a 16-gauge needle, and the contents of the cysts were accurately aspirated. Then the cysts were extracted through the umbilical access, and the cysts' walls were stripped off the remaining ovarian parenchyma.

Gynecologists have introduced the stripping technique for enucleation of benign large ovarian cysts. The primary goal of the stripping technique is to preserve ovarian tissue. This procedure can be performed through an open or a laparoscopic approach and even in the absence of macroscopic evidence of any ovarian tissue. Our experience shows this technique to be feasible in infants without intraoperative or postoperative complications.

In order to spare ovarian tissue, we suggest careful use of electro-surgical coagulation on the residual tissue after excision of the cyst; however, when appropriate techniques are used, small vessels may be identified and safely coagulated using bipolar forceps.

Dissection of the cyst is easier when it is intact, so we suggest not total but partial aspiration of the cyst so as to allow delivery via a minimally invasive approach.

## Summary

In conclusion, the one-trocar, video-assisted stripping technique of large ovarian cysts in infants appears to

be an ovarian-tissue-preserving procedure and it eliminates the disadvantages of large scars.

## References

1. Meizner I, Levy A, Katz M, et al: Fetal ovarian cysts: Prenatal ultrasonographic detection and postnatal evaluation and treatment. *Am J Obstet Gynecol* 1991; 164:874
2. Sedin G, Bergquist C, Lindegren PG: Ovarian hyperstimulation syndrome in preterm infants. *Pediatr Res* 1985; 19:548
3. Nussbaum AR, Sanders RC, Hartman DS, et al: Neonatal ovarian cysts: Sonographic-pathologic correlation. *Radiology* 1988; 168:817
4. Bristow RE, Nugent AC, Zahurak ML, et al: Impact of surgeon specialty on ovarian-conserving surgery in young females with an adnexal mass. *J Adolesc Health* 2006; 39:411
5. Muzii L, Bianchi A, Crocè, et al: Laparoscopic excision of ovarian cysts: Is the stripping technique a tissue-sparing procedure? *Fertil Steril* 2002; 77:609
6. Esposito C, Garipoli V, Di Matteo G, et al: Laparoscopic management of ovarian cysts in newborns. *Surg Endosc* 1998; 12:1152
7. Brandt ML, Helmrath MA: Ovarian cysts in infants and children. *Semin Pediatr Surg* 2005; 14:78
8. Dobremez E, Moro A, Bondonny JM, et al: Laparoscopic treatment of ovarian cyst in the newborn. *Surg Endosc* 2003; 17:328
9. Comparetto C, Giudici S, Coccia ME, et al: Fetal and neonatal ovarian cysts: What's their real meaning? *Clin Exp Obstet Gynecol* 2005; 32:123
10. Heling KS, Chaoui R, Kirchmair F, et al: Fetal ovarian cysts: Prenatal diagnosis, management and postnatal outcome. *Ultrasound Obstet Gynecol* 2002; 20:47
11. Zanetta G, Lissoni A, Torri V, et al: Role of puncture and aspiration in expectant management of simple ovarian cysts: A randomised study. *BMJ* 1996; 313:1110
12. Marana R, Caruana P, Muzii L, et al: Operative laparoscopy for ovarian cysts: Excision vs. aspiration. *J Reprod Med* 1996; 41:435
13. Arena F, Romeo C, Castagnetti M, et al: Is the stripping technique a tissue-sparing procedure in large simple ovarian cysts in children? *J Pediatr Surg* 2008; 43:1353
14. Decker P, Chammas J, Sato TT: Laparoscopic diagnosis and management of ovarian torsion in the newborn. *J Soc Laparoendoscop Surg* 1999; 3:141
15. Van der Zee DC, van Seumeren IG, Bax KM, et al: Laparoscopic approach to surgical management of ovarian cysts in the newborn. *J Pediatr Surg* 1995; 30:42