

## BREAST METASTASES FROM GASTRIC CARCINOMA - A CASE REPORT

DAMIR GUGIĆ<sup>1</sup>, JOSIPA FLAM, MIRELA ŠAMBIĆ PENC<sup>1</sup>,  
MILANKA MRČELA<sup>2</sup> and SLAVICA ROMIĆ<sup>3</sup>

<sup>1</sup>Radiotherapy and Oncology Department,

<sup>2</sup>Institute of Pathology and Forensics, Osijek Clinical Hospital, Croatia

<sup>3</sup>Pathology and Cytology Department, Vinkovci General Hospital, Croatia

---

### Summary

Gastric cancer is one of the most common causes of cancer death. In 2005, there were 1059 newly diagnosed cases of gastric cancer in Croatia.

Stomach cancer spreads very early and usually to regional lymph nodes and surrounding tissues such as the liver, lungs, or ovaries, and less often to the bones and central nervous system, whereas the breast is very rarely the site of its metastases.

Among the available data, we have found only 9 publications describing cases of gastric metastases developed in the breast, we decided to publish this case report presenting a patient who underwent total gastrectomy for gastric cancer in May 2000, and then surgery for metastases of gastric cancer to the breast in January 2005.

KEY WORDS: *gastric cancer, breast metastases*

### METASTAZE KARCINOMA ŽELUCA U DOJCI – PRIKAZ SLUČAJA

#### Sažetak

Karcinom želuca je jedan od vodećih uzroka smrti od karcinoma. U Hrvatskoj je u 2005 godini otkriveno 1059 novih slučajeva karcinoma želuca.

Karcinom želuca obično metastazira vrlo rano i to u okolne limfne čvorove, jetru, pluća, jajnike, te rjeđe u kosti i središnji živčani sustav, dok je dojka vrlo rijetko sijelo metastaza.

U dostupnoj literaturi pronašli smo samo 9 radova koji opisuju širenje karcinoma želuca u dojku, te smo odlučili prikazati slučaj naše pacijentice koja je u svibnju 2000. godine operirana radi karcinoma želuca, a u siječnju 2005. operirana radi metastaze u dojci.

KLJUČNE RIJEČI: *karcinom želuca, metastaze u dojci*

---

### INTRODUCTION

Gastric cancer is still one of the most common causes of cancer death worldwide. According to the Croatian National Cancer Registry, there were 1268 newly diagnosed cases of gastric cancer in Croatia in 2000. Out of that number, the number

of women diagnosed with gastric cancer was lower – 535 (42.2%) compared to the number of newly diagnosed men - 733 (57.8%) (1). In 2005, there were 1059 reported cases of gastric cancer - the number of women was again lower - 395 (37.3%) compared to the number of men diagnosed with the same disease - 664 (62.7 %) (1). Of all gastric

cancer cases diagnosed in 2005, the majority was reported among patients aged between 65 and 80 years, 573 (45.2%) cases in total (1).

Most gastric cancers (over 90%) are adenocarcinomas which may be further classified as intestinal and diffuse types. Diffuse adenocarcinomas have poorer survival (2). Stomach cancer spreads very early and usually to regional lymph nodes and surrounding tissues such as the liver, lungs, or ovaries, and less often to the bones and central nervous system, whereas the breast is very rarely the site of metastases (3).

### CASE REPORT

In this report, we present a rare case of signet-ring-cell gastric cancer with metastases to the breast.

A 43-year-old female patient was first admitted to the Radiotherapy and Oncology Department at Osijek Clinical Hospital in May 2000, after total gastrectomy with omentectomy and lymphadenectomy performed at the Surgery Clinic Abdominal Surgery Department a month earlier.

Her pathohistological diagnosis (PHD) was gastric adenocarcinoma. Several stomach tissue samples were taken from the suspected sites and the tumor tissue found in two sections was moderately differentiated, appearing as signet-ring cells, characteristic of this type of cancer (Figure 1). Fifteen lymph nodes – 9 of which containing malignant cells – metastases – were found in tissue surrounding the stomach (Figure 2). The histology report showed mixed-type gastric carcinoma, composed of both diffuse and intestinal fea-

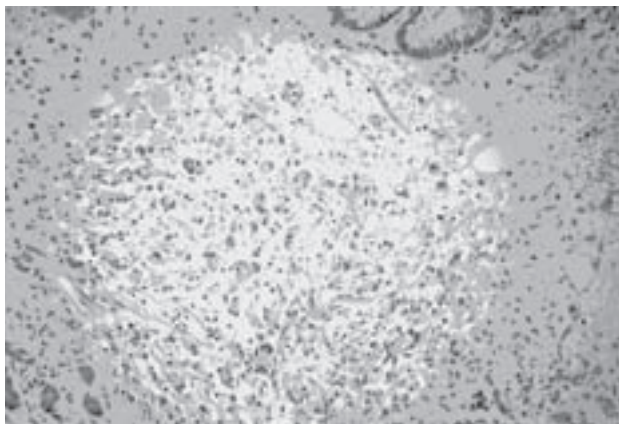


Figure 1. Gastric carcinoma, 200x, H&E stain

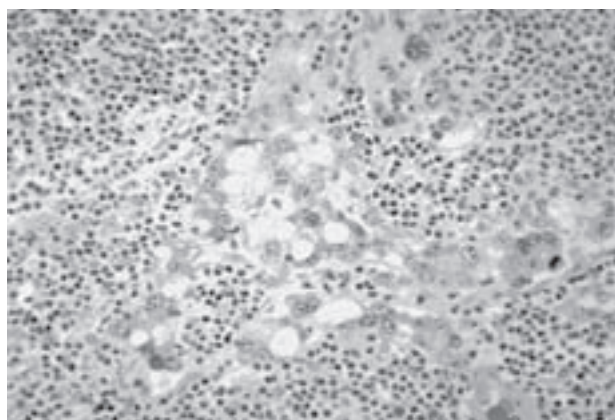


Figure 2. Regional lymph node metastase from gastric carcinoma, 400x, H&E stain

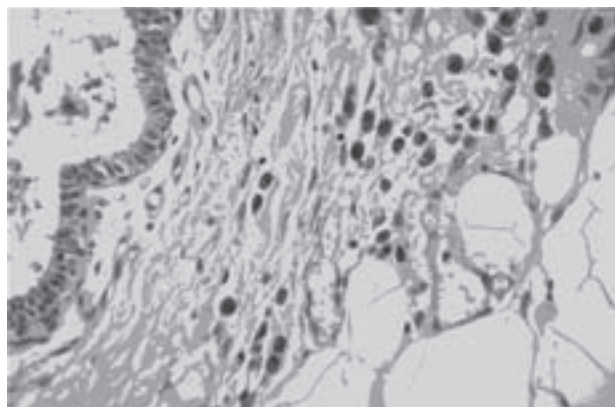


Figure 3. Breast metastase from gastric carcinoma, 400x, PAS stain

tures, with prevalence of the diffuse type with poorer survival (2).

On May 5, 2000, the patient started receiving cytostatic therapy under the FEM protocol (Fluorouracil, Epirubicin and Mitomycin) (4). The patient was given four courses of chemotherapy until November 30, 2000.

Regular examinations of the lungs and abdomen and tumor marker levels so far were normal. In July 2000, the patient underwent skeletal scintigraphy using radioactive isotopes. Carcinoembryonic antigen (CEA) and Ca 19.9 tumor marker levels were within the reference values as well as her endoscopic examinations and oesophagojejunal anastomosis. Until the beginning of 2005, the patient was undergoing regular examinations – first, at two-month intervals and afterwards, every six months. Regular abdominal ultrasound, endoscopic anastomosis examination, chest x-ray,

laboratory tests, as well as regular examinations by an abdominal surgeon, did not indicate the existence of any secondary metastases.

At the beginning of 2005, the patient noticed a change in her right breast during her breast self-exam. On January 18, 2005, the patient underwent surgery at the Vinkovci General Hospital with pathohistological diagnosis (PHD) indicating possible metastases of stomach cancer to the breast. The pathohistological finding at Vinkovci GH showed the resected tumor of 4x4x1.2 cm in size, and histologically normal breast tissue with normal vessel tissue, but infiltrated with atypical tumor cells appearing like a signet-ring cells (Figure 3). In order to confirm the spread of cancer from the stomach to the breast, and to exclude a new primary breast tumor, immunohistochemical staining was performed and pathohistological diagnoses (PHD) of the first gastric cancer surgery compared with the breast cancer surgery several years later. By comparing pathohistological findings of gastric cancer and the new pathohistological finding of breast cancer, an uncommon and rare case of primary stomach cancer with metastases to the breast was found.

The patient underwent another chemotherapy cycle under the ELF protocol (folinic acid, etoposide, fluorouracil) (5). Several months later, in 2005, the patient underwent another skeletal scintigraphy which showed minor changes in the bone structure indicative of diffuse bone metastases. Bisphosphonates-pamidronate were included into therapy (6).

Because of the patient's poor response to therapy, on April 27, 2005, the chemotherapy protocol was changed – combined chemotherapy with continuous infusion of FU à 1250 mg for three days and Cisplatin à 100 mg for one day were included into treatment. In July 2005, there was another increase in tumor marker levels and docetaxel and cisplatin were introduced.

By the end of 2005, tumor marker levels increased again: Ca 19-9 (245), therefore the patient started Capecitabin therapy à 500 mg 3+3 at the beginning of 2006. Tumor marker levels were still increasing (1144), therefore in June 2006, the patient was exposed to the ECF chemotherapy protocol (epirubicin, cisplatin and fluorouracil).

The patient's condition was worsening and in July 2006, CT scanning confirmed secondary

metastases in the ovaries. In September 2006, we exposed the patient to a new chemotherapy protocol - CMF (cyclophosphamide, methotrexate, fluorouracil) (7) and also palliative radiotherapy (RT) for painful bone metastases.

On October 12, 2006, the patient came for her last palliative chemotherapy. The patient died in November 2006.

## CONCLUSIONS

Breast metastases from gastric carcinoma are a relatively rare form of gastric carcinoma spread. To our knowledge, only nine papers describing this type of metastases of gastric carcinoma were published to date (8-16). All patients diagnosed with gastric carcinoma metastases to the breast had a relatively bad prognosis, as such was unfortunately the case of our patient, too.

## REFERENCES

1. The Croatian National Cancer Registry (The Croatian National Institute of Public Health)
2. American Joint Committee on Cancer. AJCC Cancer Staging Manual. Philadelphia: Lipincott-Raven, 1997
3. VT DeVita Jr et al. Cancer: Principle and Practice of Oncology, 1997; 1025-7.
4. Mršić-Krmpotić Z et al. Internistička onkologija. 2004; 272-3.
5. Hedrich K. Selected schedules of therapy for malignant tumors. 1999; 14.
6. Fleisch H. Bisphosphonates in bone disease. 2000; 90-1.
7. Kuhr T et al. Chemotherapy protocols. 2007; 74
8. Krichen Makni S, Abbes K, Khanfir A et al. Metastatic signet ring cell carcinoma to the breast from stomach: Elsevier Masson SAS, 2007
9. Hasegawa S, Yoshikava T et al. A case of breast metastasis of gastric cancer. Japanese Journal of Cancer and Chemotherapy 2007; 34(7): 1115-8.
10. Marcos Sanches F, Albo Castano MI et al. Breast metastasis of gastric carcinoma mimicking inflammatory carcinoma, Anales de medicina interna 2006; 23(4): 197.
11. Boutis AL et al. Gastric signet ring adenocarcinoma presenting with breast metastasis. World Journal of Gastroenterology 2006; 12(18): 2958-61.
12. Cetintas SK et al. Gastric metastasis of signet ring cell carcinoma of the breast. Saudi Medical Journal 2006; 27(2): 259-61.
13. Qureshi SS, Shrikhande SV et al. Breast metastases of gastric signet ring carcinoma: A differential diagnosis with primary breast signet ring cell carcinoma. Journal of Postgraduate Medicine 2005; 51(2): 125-7.

14. Kwak JY, Kim EK, Oh KK. Radiologic findings of metastatic signet ring cell carcinoma to the breast from stomach. *Yonsei Medical Journal* 2000; 41(5): 669-72.
15. Briest S, Horn LC et al. Metastasizing signet ring cell carcinoma of the stomach - mimicking bilateral inflammatory breast cancer. *Gynecologic Oncology* 1999; 74(3): 491-4.
16. Friedrich T et al. Atypical metastasis of stomach carcinoma. *Zentralblatt fur Chirurgie* 1997; 122(2): 117-21.

*Author's address: Damir Gugić, M.D., Ph.D., Radiotherapy and Oncology Department, Clinical Hospital Osijek, Huttlerova 4, 31 000 Osijek, Croatia*