



**UNIVERSITÀ
DEGLI STUDI
DI PADOVA**

Sede Amministrativa: Università degli Studi di Padova

Dipartimento di SALUTE DELLA DONNA E DEL BAMBINO

**DOTTORATO DI RICERCA IN
MEDICINA DELLO SVILUPPO E SCIENZE DELLA PROGRAMMAZIONE
CICLO XXVII**

TITOLO TESI

Atassie ereditarie degenerative ad esordio precoce: descrizione del pattern di alterazione patologica mediante neuroimaging avanzato e studio neuropsicologico per la definizione di indicatori paraclinici utili al monitoraggio dell'evoluzione o alla verifica di efficacia di trattamento.

Coordinatore : Ch.mo Prof. Giuseppe Basso MD

Supervisore : Ch.mo Prof. Andrea Martinuzzi MD PhD

Dottoranda : Dr.ssa Marinela Vavla MD MSc



UNIVERSITÀ
DEGLI STUDI
DI PADOVA

UNIVERSITY OF PADUA

DIPARTIMENTO DI SALUTE DELLE DONNE E DEI BAMBINI

SUBMITTED FOR THE COMPLETION OF THE
PHD DEGREE IN DEVELOPING MEDICINE AND PROGRAMMING SCIENCES
XXVII CYCLE

TITLE OF THE THESIS:

Early onset hereditary neurodegenerative ataxias: a description of the pathologic modification pattern using advanced neuroimaging techniques and a neuropsychological study for the definition of paraclinical indicators in monitoring the disease progression and verification of treatment efficacy.

Coordinator: Prof. Giuseppe Basso MD

Supervisor: Prof. Andrea Martinuzzi MD, PhD

Candidate: Dr. Marinela Vavla MD, MSc

Started on January 2012.

Expected termination by March 2015

SUMMARY OF THE THESIS

Early onset Hereditary ataxias represent a group of genetically and clinically heterogeneous conditions. The most important clinical presentation symptoms are gait and limb ataxia, dysarthria and eye movement impairment, in addition to other non-neurological involvement. Friedreich's ataxia (FRDA) is the most common autosomal recessive ataxia in terms of frequency and as a form with early onset.

Friedreich's ataxia (FRDA) is a progressive hereditary neurodegenerative condition caused by an autosomal recessively inherited GAA repeat in the FXN gene.

We performed a multidisciplinary overview of FRDA integrating it with an extensive cognitive and neuropsychological assessment. In addition, we used clinical measures and advanced tractography combined to functional MRI (fMRI) to explore white matter (WM) connectivity and motor dysfunction in a cohort of FRDA patients. This study is intended to provide a multidisciplinary overview of the clinical condition integrating it with a comprehensive MRI protocol on FRDA patients compared to controls. We have designed an ongoing longitudinal study in order to be able to describe the disease progression and to search for any potential biomarkers.

METHODS: Twenty one patients with a molecularly confirmed diagnosis of FRDA were recruited. The patients were aged >12 years of age and had an early onset and molecularly defined diagnosis of FRDA. All participants gave their written informed consent. All patients underwent a full clinical (neurological and ataxia scoring scales) and neuropsychological assessment (WISC III, WAIS R), specific tests for the attentive, executive and memory functions and MMPI A for the

personality assessment. Seventeen FRDA patients and 13 healthy controls underwent a neuroimaging study protocol on a 3T MRI scanner that included advanced neuroimaging DTI and fMRI. After the pre-processing, a nonlinear monoexponential model was used to calculate fractional anisotropy (FA), mean, radial and axial diffusivity (MD, RD, AD) maps. Non-parametric voxel-based permutations were performed on the WM maps regions of interest (ROI), considering age and sex via a general linear model (GLM) with critical threshold 0.05 while correcting for multiple tests. An fMRI sequence was acquired during a simple block design finger-tapping task. After a standard pipeline pre-process, intra- and intergroup GLM analysis were conducted, considering age and sex variables and also $p < 0.001$ threshold.

RESULTS: The cohort presents with an early age at onset (AAO) (10.6 ± 4.6 , range 4-20). The F:M ration was 16:5. The age at the visit was 39.9 ± 10.3 years (range 12-50) and disease duration was 16.3 ± 8.8 years (range 3-32). FRDA cohort presented as homozygous for the GAA repeat expansion in 96%. The mean GAA repeat expansion in the short allele was 653.7 ± 221 (range 170-946) that correlated negatively with AAO. In most cases the onset was with ataxia, gait clumsiness, and scoliosis, but few with asymptomatic cardiomyopathy and pes cavus. Vibratory sense was impaired in all the patients, with milder deficits in the other senses. Dysarthria was present in all patients. Muscle strength and tone were impaired in almost all the patients. One of them presented with a spastic ataxia with retained DTR. The pyramidal signs were present in 57%. Nystagmus was present in 61.9%. Half of the patients were wheelchair bound. Few patients developed diabetes mellitus. Cardiac involvement was registered in 76.2%, mostly presented as ventricular, septal or apical hypertrophy, but few with arrhythmias and valve prolapsed. The pulmonary system was involved in 28.6% of the patients

(restricted pulmonary involvement, bronchial asthma and a positive history of ab ingestis pneumonia). Dysphagia was present in 80.9%. In addition, *Helicobacter pylori* positive gastritis and bowel disturbances were reported. The sensory component afferences was involved as three patients complained hearing loss (14.3%) and one of them visual field reduction (4.8%). Interestingly, our cohort presented with a wide of systemic conditions. Half of the patients had normal to superior IQ tot, followed by borderline presentation and few with mental retardation. The motor impairment (dysmetria, slowness) mostly affected the IQ tot scores. And finally only 10.5 % of the cohort presented with IQ tot values that were allocated within the mental retardation range. The neuropsychological profile assessment of the FRDA patients evidenced impairment in attentive functions at around 47.4% of the cohort, the executive function as phonemic (26.3%) and semantic fluency 21.5, and planning and spatial working memory (57.9%). The personality of the FRDA cohort included mostly concern with bodily symptoms, worries and anxiety, depressive symptoms. Few patients complained hypomania, bizarre behaviours and ideas, awareness of family problems, and very few did confirm hypochondria, low self esteem, anger management difficulties and also aggressive behaviour tendency. Here we report our experience of a cohort of FRDA patients after an extensive clinical and neuropsychological assessment.

The cohort included for the MRI study presented with the following clinical features: mean age at onset 10.65 ± 5.08 (range 4-20 years); F/M: 13/4; mean GAA expansion in the smaller repeat was $651,07 \pm 234.39$ (n=16) and one patients with a single base pair deletion and 170 GAA repeat. Mean age at assessment was 27.82 ± 10.51 years (12-51), mean disease duration was 17.17 ± 8.43 (4-33). The mean age of the control group was 23 ± 4.83 years; F/M= 5/8. From both the voxel-based and ROI-based analysis altered FA and MD parameters were

consistently found in the following four Central Nervous System areas: cerebellar WM (superior, median and inferior peduncles), long sensory-motor pathways (corticospinal and lemniscal systems, cerebral peduncles), major commissural fibres (splenium and tapetum of the corpus callosum), the thalamic and the optic radiations. The fMRI data were analyzed from 13 patients (mean age 30.05 ± 11.76 years) and 8 controls (mean age 24.5 ± 3.85 years). The finger-tapping task demonstrated intragroup activation of the contralateral motor cortex and the ipsilateral cerebellar cortex both in patients and healthy controls. Intergroup analysis demonstrated a consistent and significantly higher cerebellar cortex activation, in controls compared to the FRDA patients, in particular in the lobules V and VI.

Discussion: Here we present our experience of 21 FRDA affected patients. We show that a comprehensive MRI protocol consistently discriminates FRDA patients from controls. DTI changes in selected areas and BOLD signal in the ipsilateral cerebellar cortex in response to a simple motor task show strong intergroup discriminating power and may prove to be useful paraclinical disease markers. A longitudinal study is undergoing to explore the sensitivity of these indicators to disease progression.

Our results support the evidence that DTI and fMRI techniques may provide reliable quantitative biomarkers that could be used in longitudinal studies for prognostic and therapeutic clinical trials.

Further work is needed to identify which is the best MRI technique that is more sensitive to detect the most efficient biomarker of FRDA at different stages of disease. Probably, even a composition of MRI techniques might provide an appropriate array of measures suitable to complement the clinical assessment.

Acknowledgements

Dedicated to all my patients

Thank you to the supervisor, Prof. Andrea Martinuzzi, for your expertise and mainly for the mentoring modalities, for the constructive feedbacks, for providing a guided supervision and letting me work independently.

Thank you to Drs Petacchi and Montanaro, for your constant advice, encouragement and expertise.

Thank you to all my collaborators from Conegliano, Pieve di Soligo and Bosisio Parini (colleagues, psychologists, physiotherapists, occupational therapists, speech and language therapists, CUP-programming centre, CED, nurses, engineers and technicians) for patiently putting up with the requests of this project, timelines and for your valuable feedbacks.

Thank you to all the patients that participated in this project.

Thank you to the “Ogni Giorno per Emma – ONLUS” association for funding, and especially to Mrs Bertazzon for your help with the recruitment, for your constant presence and for persistently believing in our efforts.

Thank you to Claudia, Giulia, Pellegrina, Laura, Silvia B, you know why.

Thank you to Egrina, Tanja, Valentina, Tixhe for you were there when I needed the most and I didn't need to ask.

Thank you to my parents and Klajdi, for you didn't complain about my absences, for you gave me strength to keep going.

CHAPTER 1: INTRODUCTION TO HEREDODEGENERATIVE ATAXIAS

Early onset Hereditary ataxias represent a group of genetically and clinically heterogeneous conditions. The most important clinical presentation symptoms are gait and limb ataxia, dysarthria and eye movement impairment, in addition to other non-neurological involvement. The mode of inheritance may be autosomal dominant (AD), autosomal recessive (AR), X-linked or diagenic inheritance. Friedreich's ataxia (FRDA) is the most common autosomal recessive ataxia in terms of frequency and as a form with early onset, is followed by Ataxia-Telenagectasia (A-T), ataxia with Oculomotor Apraxia type 1 (AOA1) and type 2 (AOA2) (Ruano et al., 2014). FRDA is the object of this study.

History of Friedreich's Ataxia

FRDA was initially described by Nicholas Friedreich. He described a cohort of 8 patients, members of 3 families. He published three papers in a cohort of 14 years (1863a, 1863b, 1863c, 1876, 1877). Later on, Brousse proposed to name this condition after Nicholas Friedreich (Brousse, 1882). In 1890 Ladame presented a review on a very large cohort of patients (n=165) pointing out the difficulty of diagnosis (Ladame, 1890). There had been several controversies when diagnosing and reporting FRDA. The atypical forms of FRDA had been described since 1897, when Hodge described 3 siblings with increased DTR (Hodge, 1897), while Sherman (1934) described a spastic component in patients presenting with FRDA. Wilson firmly reported the diagnosis of FRDA with retained DTR (Wilson, 1940). But it was Bell and Carmichael (1939) that had introduced the idea that a loss of DTR was an early sign in FRDA. In 1981, Harding described a large cohort

of 115 patients (Harding, 1981) presenting an extensive elaboration of clinical presentation and course of FRDA patients and two years later (1983) presenting a refined classification and diagnostic criteria.

Epidemiologic studies

The global prevalence of AR ataxias ranges from 0.0-7.2: 100.000, with an average of 3.3: 100.000 (1.8-4.9: 100.000) and highlighting FRDA as the most frequent form (Ruano et al., 2014).

The geographical distribution of FRDA patients is situated mostly in Caucasians areas, rare in sub-Saharan African and very rare in the far East. There is the hypothesis of a founding mutation origin in Western Europe that appears to be to approximately 682 ± 203 generations ago corresponding to the Paleolithic period (Vankan, 2013).

The prevalence values of FRDA are variable, they range in Caucasian population 1:20.000 to 1:50.000. The highest prevalence is reported in Spain (1:21.000); secondly in North Ireland (1:23.000) and the third highest frequency is in France (1:43.000). In East Europe, the prevalence values are extremely small, and they record as follows: Russia 1:330.000; the Scandinavia records are in the range of the minimum FRDA prevalence with Sweden 1:420.000 and Finland 1: 750.000 (Vankan, 2013). The Italian prevalence was estimated in 3 major epidemiological publications that were conducted in North Italy with 1:83.000 (Leone et al., 1990), South Italy 1:90.000 (Filla et al., 1981) and for the whole Italian patients 1:90.909 (Romeo et al., 1983) with an incidence of around 1:25.449 new cases per year. The carrier frequency is reported to be 60-1:100.

The observed FRDA distribution in Europe co-localizes with the a chromosomal marker gradient related to R1b that is believed to be present within West Europe. The chromosomal gradient is apparently due to the paleolithic migrations out of Franco-Cantabrian Ice age refugees and Neolithic migration entering West Europe with the advance of agriculture (Vankan 2013).

Genetics

In 1996 there was a publication by Campuzano et al (1996) reporting a linkage of FXN gene to the FRDA. The FXN gene was reported in the critical region for the FRDA locus on chromosome 9q13-q21.1. The gene contains 5 exons (1, 2, 3, 4, 5a) and two splicing form (exons 5b and 6), and also 4 introns. It codifies for a protein called frataxin, expressed in 2 isomers according to whether either exon 5a (210 amino acids) or exon 5b (170 amino acids) are transcribed. This protein apparently has a high level of expression in the heart, an intermediate level of expression in the liver, skeletal muscle and pancreas, and very low level in the spinal cord, cerebellum and cerebral cortex. Campuzano et al. reported, after a screening of 184 FRDA patients, three point mutations from three families of French, Spanish and Southern Italian origin (1996). They found that in 79 molecularly defined FRDA patients, including 5 with point mutations, there were GAA repeat expansion that appeared to be disease correlated. About 98% of FRDA had GAA repeat expansions. The sizes of GAA repeat were between 200 and 900, mostly containing 700-800 repeats. In the following year, 1997 the latter research group (Campuzano et al., 1997) published the functional work on FXN gene by reporting the reduction of FXN protein levels in FRDA patients and also localizing the protein within the cell giving rise to hypothesis on the probable function of the protein. FRDA appears to be due to a loss of function of the protein.

The FXN gene has its homologous in nematode, yeast and mouse (Campuzano et al., 1996; Koutnikova et al., 1997). The FXN gene exons 3-5 encode for the domain of the protein with the highest level of evolutionary conservation (Campuzano et al., 1996).

The molecular weight of frataxin is a 18 kDa. The N-terminal epitope is not found within the mitochondria, suggesting that the protein goes through a pre-processing through a proteolytic cleavage into its mature form containing the C-terminal that enters the mitochondria. An important finding of the same group, was that the FXN protein was found in the inner mitochondrial membrane, suggesting a rationale for the impairment of cells with a high energy consumption level such as neurons. This finding derived from transfected and non-transfected cells that were overexpressing FXN gene.

These important findings opened the door to a classification of FRDA under the umbrella of mitochondrial disorders, that appeared to be caused by a loss of function of a nuclear encoded protein (Campuzano et al., 1997) due to instability of normal repeats (NR) from which new expanded repeats are generated.

Pathological changes

The clinico-anatomic correlations in FRDA are represented as a combination of the developmental and degenerative processes in dorsal root columns and the sensory nerves, progressive destruction of the dentate nucleus (DN), atrophy of Betz cells and degeneration of the corticospinal tracts (Figure 1) (Koeppen and Mazurkiewitz, 2013).

The frataxin protein is synthesized as a precursor of 210 amino acids imported into the mitochondrion. The mature form is fully functional for cell survival.

Frataxin is an iron-binding and an aggregate formation protein. In addition, frataxin apparently interacts with ferrochelatase, that is involved in the enzymatic reaction that leads to the final step of heme biosynthesis by inserting iron into the porphyrin (Foury

and Cazzalini, 1997; Lesuisse et al., 2003). Lastly, frataxin appears to be linked to the mitochondrial aconitase, subunits of complex II of the respiratory chain and several chaperones (Bulteau et al., 2004; Gonzales-Cabo et al., 2005; Shan et al. 2007).

Frataxin binds iron and is required for the synthesis of iron-sulphur clusters and, thereby, for the synthesis of enzymes in the respiratory chain complexes I – III and aconitase (Pastore and Puccio, 2013).

The CNS involvement is viewed as a dying-back neuropathy of the following: long ascending and descending tracts of spinal cord, large sensory fibres of peripheral nerves, posterior sensory fibres of peripheral nerves. In addition, dentate nucleus and optic nerve tracts are involved.

Classification and diagnosis

The first effort in presenting diagnostic criteria was made from Geoffroy and collaborators (1976). They divided their 50 patients with a diagnosis of FRDA into 4 groups as follows: complete typical FRDA, incomplete atypical FRDA, atypical FRDA and no FRDA. They proposed some commendable diagnostic criteria, but since they were not fully applicable to all the FRDA patients due to the early onset of the cohort and the homogeneity of the study population (10 French-Canadian families from Quebec), were subsequently refined (Harding, 1983). She elaborated a classification from her previous works on 90 families with a total of 115 FRDA diagnosed patients (Harding, 1981).

Harding reported early onset (before 25 years of age) FRDA patients with presentation symptoms mainly limb and truncal ataxia, and absent DTR as consistent diagnostic criteria. In addition, she described other symptoms that would eventually develop during the disease progression such as dysarthria, pyramidal signs, and sensory impairment (sense of position and vibration). With the advent of the gene discovery, the suspected FRDA diagnosis was confirmed by genetic detection of pathogenic variants in the FXN gene in

both alleles. This allowed the confirmation of the cases that presented with atypical symptoms such as very early or very late onset, retained or brisk reflexes spasticity or limited progression (Durr et al., 1996; Filla et al., 2000; McCabe et al., 2000).

The clinical diagnosis of FRDA should be suspected in the presence of the combination of the following findings: progressive ataxia (gait and limbs), absent muscle DTR in LL (inconstant finding), dysarthria, an onset generally before 25 years of age and in an autosomal recessive inheritance manner. In addition, skeletal deformities (scoliosis, pes cavus), corticospinal tract (CST) involvement (LL weakness, Babinski), diabetes mellitus or glucose intolerance, hypertrophic cardiomyopathy, optic atrophy or deafness. In addition, a series of instrumental examinations are important in order to complete the diagnostic process such as cerebral magnetic resonance (MRI) visual evoked potentials, motor and sensory nerve conduction velocities.

Clinical features

The residual amount of FXN protein is reported in the range of 4-29% in patients as compared to the levels of healthy controls, and that these levels were inversely correlated to the GAA repeat size of the short allele (Campuzano et al., 1997).

Early studies reported that the GAA repeat expansion is negatively correlated with the age at onset (AAO) and positively correlated with disease progression (Campuzano et al., 1997, Filla et al., 1996; Durr et al., 1996; Montermini et al., 1997; Lamont et al., 1997; Monros et al., 1997) suggesting a role of GAA repeat expansion in the FXN protein residual levels and subsequently in the disease severity implication. Similarly, positive correlation have been shown between GAA repeat expansion and incidence of cardiomyopathy.

The normal chromosomes have fewer than 33 GAA repeat expansion. The smallest symptomatic GAA repeat expansion has been reported to be 44. FRDA patients present

usually with 600-900 GAA repeat expansion, with minimum and maximum pathogenic repeat expansion reported to be 70 and 1700, respectively (Pandolfo, 2001).

Regarding the AAO, there have been reported two ages of onset in FRDA. Most of the reports allocate the onset to be early, thus before the age of 25 years old. However, the late onset cases have been reported as well.

Generally, FRDA is classified in two different phenotypic representation, the classical and atypical phenotype. The latter incorporates the low-onset FRDA (LOFA) and very-low-onset FRDA (VLOFA), Acadian type and early onset FRDA.

Classical Phenotype.

The AAO is generally around puberty, reported to be 10.5 ± 7.4 years and 15.5 ± 8 years (Harding, 1981; Filla et al., 1990). The same authors reported a modal age at onset at around 10-12 years and 12-15 years, respectively. Harding (1981) described cases with a very early onset, before age of 5 years old, describing those cases of FRDA patients as the ones that rapidly deteriorate, while other associated early AAO with a larger size of the short allele (GAAsr), a more severe phenotype, a faster progression of disability and higher incidence of non-neurological features such as cardiomyopathy, diabetes mellitus (DM) and pes cavus (Durr et al., 1996; Schols et al., 1997).

The presenting symptoms are usually associated with the gait and limb ataxia, clumsiness (Harding, 1981; Filla et al., 1990; Durr et al., 1996; Delatycki et al., 1999). Nevertheless, scoliosis and pes cavus might be the first symptom to be observed by the clinician, leading to a necessary further neurological assessment.

The neurological features are mainly represented by gait and lower limb (LL) ataxia. The ataxic signs are of mixed origin, such as spinocerebellar degeneration, peripheral sensory neuropathy, cerebellar and vestibular pathology (Corben and Delatycki, 2012). The upper limb (UL) ataxia is reflected in the impairment of the manual dexterity, difficulty on

handwriting, use of cutlery, washing, carrying objects. The LL ataxia is observed as impossibility or difficulty in the heel-to-shin task performance. Weakness and muscle wasting are usually noted later in life.

DTR are usually absent in the LL, and mostly absent in the UL. The extensor plantar reaction is an early pyramidal sign. The muscle tone is initially normal or reduced, progressively decreasing. While spasticity appears to be associated to LL and is responsible for associated symptoms, such as pain, contractures and discomfort. The sensory system is almost always involved, predominantly with the vibration and joint position sense impairment. Visual system appears to be involved, with mostly fixation instability, less commonly nystagmus and smooth pursuit movements impairment, decreased visual acuity and increased pattern visual-evoked potential latency (Durr et al., 1996; Fortuna et al., 2009). Dysarthria is a common and early symptom, while dysphagia develops in advanced stages and hearing loss appears to be a common but understated problem. The bladder hyperactivity is common in FRDA, on the contrary the bowel problems cause fewer problems (Parkinson et al., 2013).

The non-neurological features involve heart and pancreas (Figure 2). Hypertrophic cardiomyopathy or left ventricle hypertrophy (LVH) either concentric or asymmetric septal hypertrophy (Goefroy et al., 1974; Filla et al., 1990; Durr et al., 1996; McCabe et al., 2000). Some patient present with EKG alterations such as T wave inversion, ST-segment abnormalities or arrhythmias (Dutka et al., 1999; Bourke and Keane, 2011).

Diabetes mellitus (DM) is another non-neurological feature in FRDA that appears to be either due to insulin-resistance or decrease insulin secretion (Finocchiaro et al., 1988). The incidence of DM in FRDA cohorts was reported to be around 6-32% (1976; Harding, 1981; Filla et al., 1990; Schols et al., 1997; Delatycki et al., 1999; McCabe et al., 2000; Durr et al., 1996).

Importantly, skeletal deformities are present in FRDA. Scoliosis is a common feature, occasionally the presenting symptom. It is commonly mild when the AAO is relatively late (Parkinson et al., 2013).

Foot abnormalities are present in about 55-90% of the cases reported and consist in pes cavus, talipes equinovarus and pes planus as well (Harding, 1981; Geoffroy et al. 1976; Ackroyd et al. 1984; Filla et al. 1990; Durr et al. 1996; Schols et al. 1997; Delatycki et al. 1999; McCabe et al., 2000).

Non classical phenotype

There have been, however, described cases with AAO after 25 years of age. In particular, “Late onset FRDA” (LOFA) form has been reported to have a mean age at onset at around 28.8 years (range of 25.5–48) (Bhidayasiri et al., 2005; Arnold et al., 2006). LOFA appeared to have a milder phenotypic representation with retained LL DTR. The latest AAO reported have been allocated at the seventies (Galliman et al, 2008; Stolle et al., 2008) and to our knowledge at 82 years old (Alvarez et al., 2013). This form is usually classified as “Very late onset FRDA” (VLOFA) with a AAO after 40 years old. Another atypical phenotype is FRDA with retained reflexes, known as FARR (Klockgether et al., 1996; Coppola et al., 1999).

Another atypical clinical representation of FRDA was reported in from Richter et al. (1996) in a series of patients deriving from 10 Acadian families in Canada. Their clinical presentation overlapped the classical phenotype, but lacking cardiomyopathy and DM, and eventually displayed retained or increased DTR.

About 98% of FRDA patients have a GAA repeat expansion in a homozygous pattern (Campuzano et al., 1996). In addition 2-4 % of FRDA patients present with either FXN point mutation or deletion. The former mutations might be either truncating or missense, and appear to be responsible for a milder phenotype (Cossee et al., 1999). The latter

presentation is a rare presentation and usually associated with an earlier onset and a more severe phenotype (Zulke et al., 2004; Anheim et al., 2012).

NPS studies

In 1976, Geoffroy et al. (1976) mentioned decreased IQ as a clinical criteria for FRDA. However, despite slowed information processing in FRDA, cognition does not appear to be affected (Corben et al., 2006). From a study of 13 FRDA patients (Mantovan et al., 2006), the IQ profile was characterised by concrete thinking associated to impairment in concept formation and visuospatial reasoning. Other findings of De Nobrega et al. (2007) that related to impairment in phonemic and action fluency, led the authors to claim primary prefrontal or cerebello-prefrontal dysfunction. Further studies, conducted by Corben and collaborators (Corben et al 2010, 2011a, b, c), hypothesised the disruption of cerebro-ponto-cerebello-thalamo-cerebral loops to explain the cerebellar impairment that were probably causative of the difficulty in accommodating unexpected movements, difficulty in the movement initiation without a direct visual cue, and impairments in the reaction time to incongruent stimuli. Sustained volitional attention and working memory is impaired in FRDA (Klopper et al., 2011). Lately, findings in 36 FRDA patients, confirmed motor and mental speed, conceptual thinking, verbal fluency, acquisition of verbal information, use of semantic strategies in retrieval and action naming deficits. These findings were suggestive of parieto-temporal dysfunction (Nieto et al., 2012). In summary, the cerebro-cerebellar circuits may be functionally important in FRDA, and the eventual interruption is to be regarded as causative in FRDA.

MRI studies

Magnetic resonance imaging (MRI) studies reflect the clinical features. MRI findings show cervical cord atrophy, posterior column atrophy. In early stages, there might be either no involvement of cerebellum or brainstem or minimal atrophy of the superior vermis and

medulla oblongata (De Michele et al., 1995). Additional MRI studies, such as VBM studies conducted by Della Nave et al., (2008) report symmetrical volume loss in the dorsal medulla, inferomedial cerebellar hemispheres, rostral vermis and dentate regions, which appeared to correlated with disease duration and severity. Another study, reported correlations between superior cerebellar peduncle atrophy and clinical severity, AAO and DD (Akhalagi et al., 2011).

Treatment in FRDA

There is no cure for FRDA. There have been many clinical trials that have tried different molecules (Fig. 3). Among them antioxidants have been attempted.

Coenzyme Q10 and vitamin E were used in association, demonstrating an improvement in ATP production for either 6 months (Lodi et al., 2001) and 47 months (Hart et al., 2005). The former findings were oriented toward ATP improvement in the heart and skeletal muscle; the latter confirmed these findings by reporting improvement in bioenergetics and in cardiac function. Conversely, another study high dosage of coenzyme Q10 and vitamine E controlled to low dosage coenzyme Q10 failed to demonstrate any intergroup differences in ICARS score (Cooper et al., 2008).

Idebenone, a short chain analog of coenzyme Q10, was thought lead to left ventricular hypertrophy reduction in some studies (Hausse et al., 2002, Buyse et al., 2003; Mariotti et al., 2003) but it was not confirmed by others (Lagedrost et al., 2011). Likewise, the neurological benefits of idebenone compared to placebo and measured by ICARS from a phase II clinical trial were reported by Di Prospero et al. (2007) and rejected by Lynch et al. (2010) conducted by a phase III study.

Controversial findings were reported in three case reports treated with intra muscle injection of thiamine (Costantini et al., 2013).

Iron chelators, as deferiprone, have been used in an open label study showing apparently reduction of iron in the dentate nucleus (DN) and neurological benefits (Boddaert et al., 2007). Consistently, intraventricular septum thickness reduction was observed from an open label study combining deferiprone and idebeone (Velasco-Sanchez, et al., 2011) but no ataxia score significant change was observed. Attempts to increase the levels of frataxin protein have included studies in cellular models trying different molecules such as hemin, butyric acid, and erythropoietin (Sturm et al., 2005; Sarsero et al., 2003). Clinical studies with erythropoietin as an open label study (Boesch et al., 2007) led to significant decrease levels of oxidative markers, while a six-months placebo-controlled study did not identify any clinical benefit (Mariotti et al., 2012).

An upregulation of FXN expression was tried by using histone deacetylase inhibitors (HDACi) (Herman et al., 2014) as Rai and colleagues (Rai et al., 2008) demonstrated how compound 106, HDACi analogue led to restored frataxin levels in heart and central nervous system (CNS) in FRDA mouse model. A phase I clinical trial of RG2833 was concluded (Gottesfeld et al 2013). Similarly, another molecule, class III HDACi led to increase in frataxin expression in FRDA cell and mouse models (Chan et al., 2013) while a clinical open label study reported findings of increase levels of FXN transcript approximately equivalent to the asymptomatic carriers (Libri et al., 2014). Soragni et al (2014) demonstrated that class I HDACi can induce epigenetic changes, such as increase in FXN mRNA and acetylation of a key residue either in the blood of FRDA patients or in the iPSC-derived neuronal cells and PBMC of treated patients providing proof of concept for epigenetic therapy.

Finally, interferon gamma (γ IFN) seems another molecule important in upregulating frataxin levels in cellular and mouse models of FRDA with prevention of dorsal root ganglion (DRG) in dorsal root ganglia and motor performance improvement (Tomassini et

al., 2012), with ongoing phase I clinical trials. Seyer et al. (2014) published their findings of an open label trial of yIFN for 4 months in 12 children with FRDA, demonstrating small significant changes of frataxin levels in erythrocytes, PBMC and platelets and FARS score changes equivalent to a 18 months improvement.

An attempt to try gene therapy in conditional cardiac FXN deletion mouse model, demonstrated the FXN delivered intravenously via an adeno-associated virus vector prevented and reversed cardiomyopathy (Perdomini et al., 2014).

Lately, Corben et al. (2014) have published recommendations addressing almost all the areas of health issues (neurological, heart, scoliosis, diabetes mellitus, genetic issues, pregnancy and quality of life issues) in patients with FRDA. These recommendations are generated from the evidence of systematic reviews, from randomized clinical trials (RCT), from comparative studies with control group or historical control and from case series.

The purpose of this study

This study is intended to provide a multidisciplinary overview of the clinical condition integrating it with a comprehensive MRI protocol on FRDA patients compared to controls.

We have designed a longitudinal study in order to be able to describe the disease progression and to search for any potential biomarkers.

CHAPTER 2: Clinical and neuropsychological assessment in the cohort of Friedreich's Ataxia patients

Abstract

Friedreich's ataxia (FRDA) is an autosomal recessive (AR) progressive hereditary neurodegenerative disorder. The prevalence is reported 2-5:100.000 in the Caucasian populations. Around 98% of FRDA patients present with GAA repeat expansion. The clinical diagnosis of FRDA should be suspected in the presence of the progressive ataxia, absent muscle deep tendon reflexes, dysarthria, early onset and an AR transmission. In addition, skeletal deformities, pyramidal involvement, diabetes mellitus, cardiac hypertrophy, optic atrophy or deafness can be found. Specific neuropsychological profiles including executive and memory deficits, have been detected in FRDA. We performed a multidisciplinary overview of the clinical condition integrating it with an extensive cognitive and neuropsychological assessment. Twenty one patients with a molecularly confirmed diagnosis of FRDA were recruited. The patients were aged >12 years of age and had an early onset and molecularly defined diagnosis of FRDA. All participants gave their written informed consent. All patients underwent a full clinical (neurological and ataxia scoring scales) and neuropsychological assessment (WISC III, WAIS R), specific tests for the attentive, executive and memory functions and MMPI A for the personality assessment. The cohort presents with an early age at onset (AAO) (10.6 ± 4.6 , range 4-20). The F:M ration was 16:5. The age at the visit was $.9 \pm 10.3$ years (range 12-50) and disease duration was 16.3 ± 8.8 years (range 3-32). FRDA cohort presented as homozygous for the GAA repeat expansion in 96%. The mean GAA repeat expansion in the short allele was 653.7 ± 221 (range 170-946) that correlated negatively with AAO. In most cases the onset was with ataxia, gait clumsiness, and scoliosis, but few with

asymptomatic cardiomyopathy and pes cavus. Vibratory sense was impaired in all the patients, with milder deficits in the other senses. Dysarthria was present in all patients. Muscle strength and tone were impaired in almost all the patients. One of them presented with a spastic ataxia with retained DTR. The pyramidal signs were present in 57%. Nystagmus was present in 61.9%. Half of the patients were wheelchair bound. Few patients developed diabetes mellitus. Cardiac involvement was registered in 76.2%, mostly presented as ventricular, septal or apical hypertrophy, but few with arrhythmias and valve prolapsed. The pulmonary system was involved in 28.6% of the patients (restricted pulmonary involvement, bronchial asthma and a positive history of abdominal ingestis pneumonia). Dysphagia was present in 80.9%. In addition, Helicobacter pylori positive gastritis and bowel disturbances were reported. The sensory component afferences was involved as three patients complained hearing loss (14.3%) and one of them visual field reduction (4.8%). Interestingly, our cohort presented with a wide of systemic conditions. Half of the patients had normal to superior IQ tot, followed by borderline presentation and few with mental retardation. The the motor impairment (dysmetria, slowness) mostly affected the IQ tot scores. And finally only 10.5 % of the cohort presented with IQ tot values that were allocated within the mental retardation range. The neuropsychological profile assessment of the FRDA patients evidenced impairment in attentive functions at around 47.4% of the cohort, the executive function as phonemic (26.3%) and semantic fluency 21.5, and planning and spatial working memory (57.9%). The personality of the FRDA cohort included mostly concern with bodily symptoms, worries and anxiety, depressive symptoms. Few patients complained hypomania, bizarre behaviours and ideas, awareness of family problems, and very few did confirm hypochondria, low self esteem, anger management difficulties and also aggressive behaviour tendency. Here we report our

experience of a cohort of FRDA patients after an extensive clinical and neuropsychological assessment.

Introduction

Friedreich's ataxia (FRDA) is a hereditary neurodegenerative disorder transmitted in an autosomal recessive (AR) manner. FRDA was initially described by Nicholas Friedreich (1863a). The prevalence is reported 2-5:100.000 in the Caucasian populations. The prevalence in the whole Italian population is reported to be 1:90.909 (Romeo et al., 1983) with an incidence of around 1:25.449. The carrier frequency is 60-1:100. Campuzano et al. (1996) discovered that FXN gene is linked to FRDA. Around 98% of FRDA patients present with GAA repeat expansion in both alleles. The pathological repeat size ranges from 66 to 1700. The FXN gene encodes for the frataxin protein which is entangled in the synthesis of enzymes involved in the respiratory chain complexes I – III and aconitase (Pastore and Puccio, 2013). The neuropathological findings are in line with a degeneration in the dorsal root ganglia (DRG), sensory nerves, progressive destruction of the dentate nucleus, atrophy of Betz cells and degeneration of the corticospinal tracts (CST) Koeppen and Mazurkiewitz, 2013). Harding (1981) described a large cohort of patients and subsequently refined the diagnostic criteria for FRDA (Harding et al.,1983).

The clinical diagnosis of FRDA should be suspected in the presence of the combination of the following findings: progressive ataxia of gait and limbs, absent muscle deep tendon reflexes (DTR) in the lower limbs (LL), dysarthria, onset before 25 years and an AR transmission. In addition, skeletal deformities (scoliosis, pes cavus), CST involvement (LL weakness, Babinski sign), diabetes mellitus (DM) or glucose intolerance, hypertrophic cardiomyopathy, optic atrophy or deafness can be found. With the gene discovery, the FRDA can be molecularly confirmed.

Specific neuropsychological profiles including executive and memory deficits, have been detected in FRDA (Mantovan et al. 2006; Nieto et al. 2012) indicating parieto-temporal dysfunctions. The personality of FRDA patients has been characterized by increased irritability, poor impulsive control, reduced defensiveness and a poor-self-presentation (Mantovan et al. 2006).

The aim of this study was to explore the clinical presentation of the FRDA cohort afferent into our centres. We investigated our cohort via a thorough neurological and neuropsychological assessment. This study is intended to provide a multidisciplinary overview of the clinical condition integrating it with an extensive cognitive and neuropsychological assessment.

Methods

Participants

Twenty two patients with a molecularly confirmed diagnosis of FRDA were recruited at the Research Centres “Eugenio Medea” in Conegliano/Pieve di Soligo (Treviso) and Bosisio Parini (Lecco, Drs. Grazia D'Angelo, Erika Brighina) and in Bologna (Dr Valerio Carelli) between 2011 and December 2014. The patients were aged >12 years of age and had an early onset and molecularly defined diagnosis of FRDA. All participants, but two, were native Italians, mostly originating from Central and North Italy. The other two patients were of non-Italian nationality (Albanian and German). One patient had to be excluded from the study due to difficulties in clinical protocol administration as she had undergone orthopaedic surgery for feet deformities.

Ethic committee approval and patients consent

The study has been reviewed and approved by the Institutional Review Board (IRB) on 07/07/2011 (Prot. No 051/11-CE). All participants gave their written informed consent in accordance with the 1964 Declaration of Helsinki.

Measurement tools

All patients underwent a full clinical assessment including neurological examination from a trained neurologist. Disease severity was assessed by three different ataxia rating scales. The Scale for the Assessment and rating of Ataxia (SARA) (Subramony et al., 2005) includes 8 items regarding upright posture, speech and limb kinetic function (range 0-40). The International Cooperative Ataxia Rating Scale (ICARS) (Trouillas et al., 1997) consists of 19 items divided into 4 subgroups assessing posture and gait, limb movements, speech and oculomotor disturbance (range 0-100). The Friedreich Ataxia rating Scale (FARS) (Schmitz-Hubsch et al., 2006) consists of the following sub-scales: functional staging (0-6), activities of daily living (ADL) (0-36), neurological examination (0-117), PATA rate and 9-hole peg test (9-HPT) for the manual dexterity.

Motor function and movement were examined with the 6-Minute Walking Test (6MWT) (Laboratories, 2002), the modified Ashworth scale (MAS) (Bohannon & Smith, 1987), muscle strength assessed with Medical Research Council (MRC) (Compston, 2010) and also articular and sensory assessment was completed.

The independence in activities of daily living was explored with the functional independence measure (FIM) (Keith et al., 1987) (range 7-126).

NEUROPSYCHOLOGICAL PROTOCOL

The patients and healthy controls underwent a complete neuropsychological assessment weighted specifically for the group ages: 12-16 and 16-50 years (and over). The cognitive functions in the subjects aged 12-16 years were studied through the Wechsler Intelligence Scale for Children (WISC) III (Orsini e Picone, 2006) and in the group of adults and older adolescents was used the Wechsler Adult Intelligence Scale (WAIS) R (Wechsler, 1997).

The neuropsychological protocol was designed to specifically investigate the attentive, executive and memory functions. The attentive functions were explored via a software for

the attention and concentration and the Trail Making Test A-B (Mondini et al., 2011). Memory was tested by direct and inverse span tests, memory prose tests and also the recall of the Rey complex figure for the memory functions. In addition, the semantic and categorical verbal fluency and the Tower of London test (Shallice, 1982) were used to detect the executive functions. Finally, the Minnesota Multiphasic Personality Inventory A (MMPI A) was used to test the personality and to explore eventual psychopathological indexes in the adults.

Statistical analysis

Statistical analysis was undertaken using SPSS V. 21. Descriptive variables were presented as means, medians, modes and standard deviation. Bivariate correlations were used by performing Spearman test.

Results

Clinical data

Twenty one patients with a molecularly defined diagnosis of FRDA were examined.

The mean age at the time of the visit (AAV) was 26.9 ± 10.3 years (range 12-50, mode 26 years) (Table 2.1). The mean disease duration was 16.3 ± 8.8 years (range 3-32). The gender ration was F:M 16:5. Patients declared an AAO of about 10.6 ± 4.6 (range 4-20), with a bimodal distribution (10 and 11 years).

All the patients had a molecularly definite diagnosis of FRDA. Twenty of them were heterozygous for the GAA repeat expansion, but one of them had 170 GAA repeat expansion on one allele and a point mutation on the other. The mean GAA repeat expansion in the short allele was 653.7 ± 221 (range 170-946), while the long allele counted for 809.5 ± 245.1 (range 350-1230). GAA repeat expansion correlated negatively with AAO ($r^2 -0.709$, $p= 0.001$).

The symptoms at onset are as follows: ataxia, gait clumsiness, and scoliosis (7 patients, 33.3%). One patient reported to have had an onset with asymptomatic cardiomyopathy (4.8%), another one pes cavus (4.8%) and one of them with tendency to fall (4.8%).

The clinical features of the patients derived from the administration of a series of ataxia scales, from the neurological examination and other complementary assessments. Table 2.3 presents a summary of the ataxia rating scales. The variables include SARA, ICARS and FARS neurological examination full score. In addition, the subitems of ICARS and FARS are reported for a better characterization of each item or group of subitems. The manual dexterity was assessed through 9-HTP. All the patients but two were right handed. Vibratory sense was impaired in 100% of the patients. Other forms of sensory impairments regarded tactile (n=10, 47.6%), proprioception (n=7, 33.3%), pain (n=5, 23.8) and temperature (n=4, 19%).

Dysarthria was present in all patients but with a range of various severity. Most of the patients had a mild dysarthria as measured by FARS ADL score 0.5 to 1 (n=16, 76%). Tremor and dysmetria were present and not always associated in the same case index. Almost all patients had muscle weakness, mainly in LL. Muscle tone was reduced in the majority of patients, but one who presented with a spastic ataxia. Almost 57% presented with pyramidal signs (Babinski positive in 12 of them) and 3 of them had increased deep tendon reflexes (DTR). Nystagmus was present in 61.9%(n=13).

Twelve patients were wheelchair bound. They started using the wheelchair at a mean age of 22.3 ± 10.9 years with the earliest and the latest at 11 and 49 respectively. Five patients were autonomous in performing the 6 MWT with a mean length distance of 241 ± 147.5 meters (range 51-390). One of the patients performed the 6MWT with the use of a walking aid. Three of them were not able to perform the 6MWT as they were not autonomously deambulant, and another one preferred to avoid it due to tendency of falls.

Regarding the different aids used in their everyday life, as mentioned in the previous paragraph, n=13 were regular wheelchair users (57.1%). Five of them used foot plantar (23%). The orthopaedic corset was used from 5 FRDA patients (23%). Ankle foot orthotics (AFO) was used in 3 cases (14.3%) and 1 patient used a walking aid (4.7%) and another one used an index splint to facilitate herself for the computer use.

Functional independence was measured either with FIM or with ADL section of the FARS. The former presented with a mean of 99.6, ranging from a full autonomy in everyday functionality (126) to an almost complete dependence in all the daily activities (53).

Two patients presented with a diagnosis of Diabetes Mellitus (DM) with years after onset 21 and 14 and were both in treatment with oral hypoglycaemic.

Cardiac involvement was registered in 16 patients (76.2%). Patients mostly presented left ventricular hypertrophy (n=5, 23.8%), septal or apical hypertrophy (n=2, 9.5%), arrhythmias (n=2, 9.5%) and mitral prolapsed in one of them (4.8%).

The respiratory system was involved in 6 patients. Two of them had a restrictive pulmonary condition, and another had reduced FVC. One had a diagnosis of bronchial asthma and another had positive history of ab ingestis pneumonia.

The gastrointestinal system was largely involved as 17 FRDA (80.9%) patients complaints dysphagia, mainly for liquids. One patient had a history of Helicobacter pylori positive gastritis (4.8%) and two of them had bowel disturbances (9.5%) (one stipsi and the other bowel incontinence episodes).

The cohort of patients presented other conditions, systematic involvement. One of them presented a D4-D9 hernia (4.8%), two patients had had trauma (hand and fibular epiphysis fractures) (9.5%). Seven patients had undergone surgery for dorsal lumbar arthrodesis (n=2, 9.5%), knee arthroscopy (n=1, 4.8%), appendicectomy (n=2, 9.5%), ovarian cyst removal and tonsillectomy (n=1, 4.8%).

Pain was common and it was complained as headache by 3 patients (14.3%) and as LL pain due to muscle contractures in another (4.8%).

The sensory component afferences appeared affected as three patients complained hearing loss (14.3%) and one of them visual field reduction (4.8%).

Systemic involvement was observed due to the presence of celiac disease (n=1, 4.8%), kidney stone (n=1, 4.8%), acne vulgaris and seborrheic dermatitis (n=2, 9.5%). In addition, other patients had been diagnosed with rheumatoid arthritis (n=1, 4.8%), autoimmune thyroiditis (n=2, 9.5%) and iron-deficiency anaemia (n=1, 4.8%).

Interestingly, one patient complained sleepwalking (4.8%), another one presented with a congenital VII cranial nerve palsy and 3 of them with mood swings, apathy and anxiety (14.3%).

The patients were in treatment with various drugs such as idebenone (n=11, 52.4%), deferiprone (n=2, 9.5%), vitamins (group B, D, E, n=8, 38.1%), antispastics (n=2, 9.5%), oral hypoglycaemics (n=2, 9.5%), acetyl salicylic acid (n=2, 9.5%). In addition, they were in therapy with methotrexate (n=1, 4.8%), levotyroxine (n=1, 4.8%) and citalopram, sertraline and amantadine (n=3, 14.3%).

Nineteen patients underwent the NPS protocol assessment. Two of the patients of the cohort did not undergo the NPS protocol for their first language was not Italian as they were of Albanian and German nationality.

Neuropsychological data

The IQ assessment of the FRDA patients was administered from 3 qualified psychologists. The distribution of the IQ components is evidenced in the figure 2.1. Five patients out of 19 (26.3%) had normal values of the three IQ components: verbal (IQ v), performance (IQ p) and total (IQ tot). Other four patients (21.5%) presented with superior to high cognitive potential IQ v; normal (2), border (1) and superior (1) IQ p, whereas the IQ tot ranged

from normal (1) to superior (3) values. Other two patients (10.5%) had normal IQ tot but disarmonic verbal and performance values. Another 10.5 % of the cohort (2) presented with IQ tot values that were allocated within the mental retardation range, both with border level of IQ v and IQ p <70. Finally, four patients (2) (1.5%) had border IQ tot, with dysarmonic IQ v and IQ p.

The neuropsychological profile assessment of the FRDA patients evidenced impairment in attentive functions CPT in 2 patients (10.5%) and TMT-A and TMT-B in 9 patients (47.4%). Executive functions were impaired as demonstrated from altered results in phonemic in 5 patients (26.3%) and semantic fluency in 4 (21.5%), in addition with 57.9% of ToL impairment values. Memory functioning was impaired as measured from altered direct span in 4 (21.5%), inverse span in one (5.3%), and Rey recall figure in two (10.5%). From the MMPI A administration, we observed that 21% of patients (4) had concerns related to bodily symptoms. Worries and anxiety was found present in 21% (4). Depressive aspects of FRDA patients personality were noticed in 16% of the cohort (3). In addition, the following findings characterize our cohort: hypomania in 11% (2), bizarre behaviours and ideas in 11% (2), family problems awareness in 11% (2), hypochondria in 5% (1), low self esteem in 5% (1), anger management difficulties in 5% (1) and aggressive behaviour tendency in 5% (1).

Discussion

The cohort presents with an early AAO. 10.6 ± 4.6 (range 4-20), with a bimodal distribution (10 and 11 years). This findings are in line either for the AAO or for the mode of onset with the previously published literature (Harding, 1981; Filla et al., 1990). The cases that presented the lowest age at onset had larger GAA repeat expansion in the short allele, a severe phenotype, a fast progression and an important functional impairment as previously reported (Harding, 1981; Durr et al., 1996; Schols et al., 1996). The gender

distribution is weighted more in towards the female end. Although, there is differences in gender prevalence in other reports. The mean AAV was 26.9 ± 10.3 years (range 12-50) and DD was 16.3 ± 8.8 years (range 3-32). All the patients had a molecularly definite diagnosis of FRDA. Almost 96% of them were homozygous for the GAA repeat expansion, but one of them (4%) was heterozygous for GAA repeat expansion and a carrier of point mutation. Interestingly, Campuzano reported that about 98% of FRDA were homozygous for GAA repeat expansion (Campuzano et al., 1996), whereas the remaining of 2-4 % of FRDA patients present with either FXN point mutation or deletion. The heterozygous case index had had an onset at around 18 years old with a wheelchair bound age at around 49 years. The milder point mutation is in fact a good explanation for the milder phenotypes (Cossee et al., 1999). The mean GAA repeat expansion in the short allele was 653.7 ± 221 (range 170-946), while the long allele counted for 809.5 ± 245.1 (range 350-1230) and it correlated negatively with AAO. The GAA repeat correlated negatively with AAO as reported previously (Campuzano et al., 1997, Filla et al., 1996; Durr et al., 1996; Montermini et al., 1997; Lamont et al., 1997; Monros et al., 1997). Most of the FRDA patients had an onset with ataxia, gait clumsiness, and scoliosis, but few of them with asymptomatic cardiomyopathy and pes cavus. These findings are in line with what has been previously published (Harding, 1981; Filla et al., 1990; Durr et al., 1996; Delatycki et al., 1999).

Vibratory sense was impaired in all the patients, whereas in other studies this loss was estimated be around 73-88% (Harding, 1981; Durr et al., 1996; Schols et al., 1997; Delatycky et al., 1999). Other types of sensory deficits such as tactile, temperature and proprioception, were observed but with a smaller impact.

Dysarthria was present in all patients but with a range of various severity, this was reportedly to be in around 90% of previous works (Parkison et al., 2013). Poole et al.

(2015) report a study on nasality in 37 FRDA patients compared to a control group, their findings suggest variability of nasality in FRDA with either hyper- or hyponasality, how perceptual ratings of hypernasality correlate with GGA2 repeat length suggesting probable genetic influence on nasality profile. Vogel et al. (2014) conclude in their review that there is insufficient evidence to determine the effectiveness of any treatment for speech disorder.

Muscle strength and tone were impaired in almost all the patients. One of them presented with a form of spastic ataxia with retained DTR. This was an atypical phenotype known as FARR (Klockgether et al., 1996; Coppola et al., 1999).

The pyramidal signs were present in 57% (Babinski positive) and absent DTR in all but in 14% of them. Other works report DTR presence in ranges from 1-33% (Harding, 1981; Delatycky et al., 1999; Durr et al., 1996).

Nystagmus was present in 61.9% (n=13), and it is usually a common early sign (Parkinson et al., 2013).

Almost half of the patients were wheelchair bound by mean age of 22.3 ± 10.9 years. This is quite similar to the age reported in literature (25 years) (Harding, 1981; Parkinson et al., 2013). Despite the wheelchair, patients used other aids in order to comply with a better residual functioning such as foot plantar, orthopaedic corset, AFOs and finger splints.

Only 9.5% had developed DM. The DM incidence is known to account for 10-30% of the FRDA patients (Parkinson et al., 2013).

Cardiac involvement was registered in 76.2%, mostly presented as ventricular hypertrophy, septal or apical hypertrophy, and also few arrhythmias and valve prolapsed. Usually, the FRDA patients develop hypertrophic cardiomyopathy or LVH (Goeffroy et al., 1974; Filla et al., 1990; Durr et al., 1996; McCabe et al., 2000), in addition to some EKG alteration (Dutka et al., 1999; Bourke and Keane, 2011).

The pulmonary system was involved in 28.6% of the patients. The patients presented with restricted pulmonary involvement, bronchial asthma and a positive history of abdominal ingestis pneumonia.

Dysphagia was present in 80.9%. In addition, other interesting findings such as *Helicobacter pylori* positive gastritis and bowel disturbances were reported and no bladder involvement. Conversely, Parkinson et al. (2013) reports that bladder hyperactivity as a common and rarer bowel problem.

The sensory component afferences appeared affected as three patients complained hearing loss (14.3%) and one of them visual field reduction (4.8%). Dag et al. (2013) studied OCT in 10 FRDA patients reporting a retinal thinning, a generalized reduction of visual field testing and correlation of ICARS score to the retinal nerve fibre thickness. Fortuna et al. (2009) reported an extensive study in 26 FRDA patients, reporting visual pathway involvement as optic radiation ADC impairment in DTI, different patterns of visual field impairment, reduced retinal nerve fibre layer (RNFT) thickness, abnormal VEP and also correlation with clinical variables, ICARS scores, GAA triplet expansion, AAO and DD.

Interestingly, our cohort presented with a wide systemic involvement such as celiac disease, acne vulgaris and seborrheic dermatitis, rheumatoid arthritis, autoimmune thyroiditis, iron-deficiency anaemia and sleepwalking.

We assessed nineteen patients NPS protocol. Around 47.8% of the cohort presented with normal to superior IQ total. Six patients had disarmonic IQ values, nevertheless 2 of them had normal IQ total and 4 were within the border range. We observed, that many of the patients had very good scores in the verbal components, but it was the motor impairment (dysmetria, slowness) that affected the IQ total scores. And finally only 10.5% of the cohort presented with IQ total values that were allocated within the mental retardation range. There are few studies that have dealt with cognitive function in FRDA. Initially, it was mentioned a

decrease in IQ (Geoffroy et al. 1976), but it was not sustained by Harding in her extensive 115 patients in 1981 (Harding, 1981). Conversely, Wollman et al (2002) reported reduced motor functioning and mental retardation.

The neuropsychological profile assessment of the FRDA patients evidenced impairment in attentive functions around 47.4% of the cohort. The executive function appeared altered in 26.3% and 21.5% in the phonemic and semantic fluency respectively. In addition, 57.9% presented with impaired ToL test values. Memory functions were affected as measured by direct span in 21.5%, inverse span in 5.3% and Rey figure in 10.5%. Previous studies, have reported reduced processing speed of information (Mantovan et al., 2006; White et al., 2000). The latter paper reported in addition visuospatial deficits, impaired verbal learning and executive dysfunctions. A reduced verbal span and deficit in letter fluency, impaired acquisition and consolidation of verbal information was reported (Wolman et al. 2000), as well as differential impairments in semantic verbal, phonemic, and action fluency performances (De Nobrega et al.,2007).

The personality traits were variably affected. Mostly they interested concern with bodily symptoms, worries and anxiety. Nevertheless, 16% of the cohort complained depressive symptoms. In addition, few patients complained hypomania, bizarre behaviours and ideas, awareness of family problems, and very few did confirm hypochondria, low self esteem, anger management difficulties and also aggressive behaviour tendency. Flood et al. (1987) reported major depression in FRDA patients, whereas Leclercq et al. (1985) and White et al (2000) failed to show any psycho-organic symptoms and mood disorders. Mantovan et al. (2006) reported that the personality traits of FRDA patients were characterized by increased irritability, poor impulsive control, reduced defensiveness and a poor-self-presentation. Ciancarelli et al (2010) reported 29% of her cohort to have mood disorders.

The same authors report their experience of 1 year neuropsychological rehabilitation in the FRDA cohort which apparently contributed to the reduction of cognitive decline.

Da Silva et al. (2013) investigated 22 FRDA patients and reported reduction of grey matter (GM) volumes in medial and orbital region of frontal lobe and anterior cingulate gyri. The Berg Depression Inventory scores inversely correlated with the GM volume of right superior frontal gyrus. Akhalaghi et al. (2013 cognitive deficits) studied 12 FRDA patients found reduced FA, increased ADC and RD in the dentate-thalamic, thalamo-cortical and dentate-rubral tracts. The white matter (WM) changes in the latter correlated with cognitive impairments as assessed by Simon effect.

Actually, the whole range of cognitive impairments in the FRDA patients could be due to the disruption of different neural circuit that provide connection between cerebellum and other central nervous system (CNS) structures. The cerebellar circuitry consists of prevalently of corticoponto-pontocerebellar tracts, cerebellothalamic-thalamocortical tracts, and also of parieto-cerebellar, prefrontal-cerebellar and hypothalamus-cerebellar connection. Cerebellum is known so far to be an important CNS component involved in neurocognitive development, language function, working memory, executive function and the cerebellar internal control models (Koziol et al., 2014).

CHAPTER 3: NEUROIMAGING FINDINGS IN A COHORT OF FRIEDREICH PATIENTS: DTI AND FUNCTIONAL MAGNETIC RESONANCE

Abstract

Background: Friedreich's ataxia (FRDA) is a progressive hereditary neurodegenerative condition caused by an autosomal recessively inherited GAA repeat in the FXN gene. In this study we used clinical measures and advanced tractography combined to functional MRI (fMRI) to explore white matter (WM) connectivity and motor dysfunction in a cohort of FRDA patients. Methods: Molecularly defined FRDA patients (n=17) were clinically assessed with the specific ataxia scales. Patients and age matched healthy controls underwent a neuroimaging study protocol on a 3T MRI scanner that included advanced neuroimaging DTI and fMRI. After the pre-processing, a nonlinear monoexponential model was used to calculate fractional anisotropy (FA), mean, radial and axial diffusivity (MD, RD, AD) maps. Non-parametric voxel-based permutations were performed on the WM maps regions of interest (ROI), considering age and sex via a general linear model (GLM) with critical threshold 0.05 while correcting for multiple tests. An fMRI sequence was acquired during a simple block design finger-tapping task. After a standard pipeline pre-process, intra- and intergroup GLM analysis were conducted, considering age and sex variables and also $p < 0.001$ threshold. Results: Our cohort included early onset FRDA patients, mean age at onset 10.65 ± 5.08 (range 4-20 years); F/M: 13/4; mean GAA expansion in the smaller repeat was 651.07 ± 234.39 (n=16) and one patients with a single base pair deletion and 170 GAA repeat. Mean age at assessment was 27.82 ± 10.51 years (12-51), mean disease duration was 17.17 ± 8.43 (4-33). The mean age of the control group was 23 ± 4.83 years; F/M= 5/8. From both the voxel-based and ROI-based analysis

altered FA and MD parameters were consistently found in the following four Central Nervous System areas: cerebellar WM (superior, median and inferior peduncles), long sensory-motor pathways (corticospinal and lemniscal systems, cerebral peduncles), major commissural fibres (splenium and tapetum of the corpus callosum), the thalamic and the optic radiations. The fMRI data were analyzed from 13 patients (mean age 30.05 ± 11.76 years) and 8 controls (mean age 24.5 ± 3.85 years). The finger-tapping task demonstrated intragroup activation of the contralateral motor cortex and the ipsilateral cerebellar cortex both in patients and healthy controls. Intergroup analysis demonstrated a consistent and significantly higher cerebellar cortex activation, in controls compared to the FRDA patients, in particular in the lobules V and VI. Discussion: We show that a comprehensive MRI protocol consistently discriminates FRDA patients from controls. DTI changes in selected areas and BOLD signal in the ipsilateral cerebellar cortex in response to a simple motor task show strong intergroup discriminating power and may prove to be useful paraclinical disease markers. A longitudinal study is undergoing to explore the sensitivity of these indicators to disease progression.

INTRODUCTION

Friedreich ataxia (FRDA) is characterized by a set of motor and sensory deficits which result in ataxic behaviour. The disease is caused by the lack of frataxin protein due to intronic GAA trinucleotide repeat expansion in the FXN gene on chromosome 9 (Campuzano et al., 1996). Age of onset, clinical progression and severity are not uniform among patients, but correlate in various ways with the expansion size (Montermini et al. 1997).

In the last years, some in vivo MRI studies have provided information relative to the damage of cerebellar, cerebral and spinal cord areas involved in FRDA and other genetically determined ataxias (Akhlaghi et al. 2012; Akhlaghi et al. 2013; Jayakumar et

al. 2008; Ormerod et al. 1994; Villanueva-Haba et al. 2001) which could be useful to monitor disease progression.

With the advent of the VBM, it was possible to quantify the degree of atrophy, to monitor it in time and to identify various patterns typical of a specific form of ataxia (Della Nave et al. 2008a). Various studies have evidenced a significant correlation between the degree of the cerebellar atrophy, the severity of the clinical picture and also the duration of the disease (Della Nave et al., 2008a; Della Nave et al. 2008b; Mantovan et al. 2006; Ormerod et al. 1994; Prakash et al. 2009).

There are no quantitative objective biomarkers that show strong and reliable correlation with progression rate and severity. To date there is no effective treatment available for FRDA and the few clinical trials carried out so far reveal the weakness of the poor capacity to detect and document promptly and objectively meaningful changes (Di Prospero et al., 2007). Markers of oxidative damage such as 8-hydroxy-2'-deoxyguanosine (Schulz et al., 2000) have been proposed to document the efficacy of treatment, but showed poor correlation with the clinical variables (Di Prospero et al., 2007). On the other side validated and commonly used clinical severity scales don't show the sufficient sensitivity to capture changes in the short term (6 months - 2 years), making them unfit to reliably monitor any expected treatment-induced changes and in a sufficiently short term. These problems, coupled with the rarity of FRDA, are obstacles that make assessment of treatment efficacy slow and inefficient, thus resulting in further procrastination in the development of an effective therapy.

The advanced neuroimaging techniques such as Voxel-Based Morphometry (VBM), Susceptibility Weighted Imaging (SWI), Diffusion Tensor Imaging (DTI) and functional Magnetic Resonance Imaging (fMRI) could offer on one hand the necessary complement to the description of the neuropathological basis of the disease, and on the other could also

represent an objective indicator of the disease progression that could be used even as paraclinical end-point in therapeutic trials. Surrogate end-points based on neuroimaging indicators have been extensively used in other neurological diseases such as Multiple Sclerosis, and their introduction speeded up significantly the recognition of effective treatments and their longitudinal evaluation (Sormani and Bruzzi, 2013).

Modifications of the fMRI pattern in response to specific tasks involving both the motor and the planning ability have also been demonstrated in FRDA patients, and fMRI based protocols could offer an adjunctive indicator of disease progression or of therapy induced modification (Jayakumar et al. 2008; Mantovan et al.2006). Previously, has been reported a heterogenous pattern of cortical activation following a finger tap motor task in fMRI (Mantovan et al.2006). In additions, another study using a cognitive task (Simon effect) demonstrated a reduction of the BOLD effect in FRDA patients (Georgiou-Karistianis et al., 2012).

Neither of these studies however included any follow-up assessment to demonstrate clinical progression.

DTI is a non invasive neuroimaging technique that allows the study of diffusion process in the brain tissue, in particular to sensitize the MRI signal intensity in relation to water diffusion. The pulsed magnetic field gradient is used principally and the precession of the protons is proportional to the magnet field gradient which is in turn related to precession of the protons (Qiu et al., 2015). The final step of events leads to pulsed magnetic field gradient which leads to signal loss due to the amount of water diffusion derived at each of the location of the spatial domains.

The structural MRI is used to study brain structure, and fMRI is used to study brain function. The fMRI studies the blood oxygenation level dependent (BOLD effects). It measures the deoxyemoglobin levels that lead to a perturbation in the local magnetic field.

The result is the brightness which in turn is an fMRI image linked to the level of local magnetic perturbation. fMRI measures the local increase in brain activity as a sign of the initial use of the local pool of oxygen, which is then followed by a larger increase in regional oxygen delivery than needed due to local area flooded by oxyhaemoglobin, less deoxyhaemoglobin, less magnetic perturbation than at rest with a brighter image as an outcome. The data are preprocessed in order to be cleaned up and to increase the signal to noise ratio (SNR). This process is important for the removal of detrimental effects of head motion, background noise, physiological noise, brain anatomy variability. The latter is corrected by smoothing and normalisation to standard template. The noise is usually related to breathing, heartbeat, machine artefacts and also movements that are induced by movement of the subject (or body segments) when the stimulus appear.

The main objectives of this study regard an attempt to To establish an efficient protocol to obtain, from neuroimaging, objective and quantitative biomarkers for FRDA useful to monitor disease progression and response to treatment. This objective was designed to be pursued through: longitudinal analysis of the patterns of cerebral and cerebellar damage in FRDA using advanced neuroimaging techniques (VBM, DTI, fMRI); and eventual correlation of the clinical (motor and cognitive) data with the neuroimaging ones.

The motor task was selected considering the motor impairment in FRDA patients. The finger tapping task was administered to study the motor cortex activation, motor coordination and precision. The cognitive task consists of the Stroop test (color reading frame) which is useful to study the selective attention, the ability to ignore irrelevant details and the conceptual thinking, in addition to be able to measure the reaction time.

Therefore, this study is intended to provide a multidisciplinary overview of the clinical condition integrating it with a comprehensive MRI protocol in FRDA patients compared to

controls. The initial proposal of the project was to comply with a longitudinal design in order to study the disease progression and to search for any potential biomarkers.

METHODS

Participants, informed consent and clinical assessments are described in chapter 2.

A control group of healthy controls was considered, matching age and gender characteristics. The control group underwent the MRI protocol and neuropsychological one. They were all free of any significant pathology that would interfere with the study protocol.

Neuroimaging protocol

All the MRI scans were performed with a Philips Achieva system equipped with a 3.0 Tesla magnet. The MRI protocol included diffusion tensor imaging (DTI), fMRI with motor and cognitive task.

DTI data were acquired by means of a 2D T2-weighted EPI sequence (slice thickness = 2mm, acquired matrix=112x112, field of view= 224x224 mm², final voxel size=2.2x2.2x2.2 mm³, TR=8,645s ,TE=63ms, flip angle= 90°) along 6-15-32 non-collinear directions with repeated acquisitions and multiple b-values (0, 300, 1100 sec/mm²). DTI data were used to characterize the diffusion parameters in the white matter (WM) Moreover, a T2W structural volume was acquired with a 2D Turbo Spin-Echo (TSE) sequence to correct DTI data for the susceptibility artefacts (slice thickness=1.7mm, acquired matrix=112x112, field of view=224x224 mm², final voxel size=2x2x1.7 mm³, TR=3s ,TE=100ms).

DTI data were analysed using TORTOISE software V.2.0.1 (Pierpaoli et al. 2010) (<http://www.tortoisediti.org>), a free set of tools developed by the NIH paediatric neuroimaging group. The analysis pipeline can be divided in three phases: preprocessing, tensor estimate and postprocessing.

In the preprocessing phase the acquired data are prepared for the analysis. Firstly, all images are reoriented to the AC-PC plane in order to achieve a common system of reference. Secondly, a motion correction procedure is performed to eliminate misalignment among volumes due to patient motion during the acquisition. Then, images are corrected for B0 susceptibility and EPI distortion artefacts applying a robust registration analysis (Rohde et al., 2004). In this step the structural T2W image is also used. Finally, a visual inspection of the corrected data is performed to detect remaining artefacts and data corruption. Corrupted data may be discarded from the subsequent analyses.

The diffusion tensor estimate is performed on the preprocessed data using the method described in Chang et al. (2005). This method allows a robust estimate of the diffusion tensor by iteratively identifying outliers on the data and accordingly updating the fit weights.

In the postprocessing phase the diffusion data are prepared for the comparison among subjects and for the statistical analysis. In particular, a study template is built according to Chang et al (2005) and all subject tensors are moved to the study template using the tensor based registration algorithm included in DTI-TK (Zhang et al. 2007) (<http://dti-tk.sourceforge.net>). Once the subject tensor is moved to the template space, several diffusion parameters are derived, such as the Fractional Anisotropy (FA), the Mean Diffusivity (MD), the Axial and Radial Diffusivities (AD, RD). Diffusion maps are analysed using both voxel- and ROI-based approaches. Moreover, the deformation fields computed to move each subject tensor to the template are used to perform a diffeomorphic analysis of the white matter (WM) driven from the diffusion data.

In order to quantify eventual statistical differences between two groups, and to investigate eventual disease-related structural differences, the diffusion data of all the subjects were

aligned in a common space. In order to perform this operation, a reference diffusion tensor atlas was created by use of DTI-TK software, leading to the alignment of all diffusion tensors in all the subjects. Notably, the DTI-TK performs non linear rigid, affine and diffeomorphic registrations in a succession manner on the diffusion tensors. By using the spatial transformations calculated on the diffusion tensors, the FA maps were aligned. Three types of tests were performed: Tract Based Spatial Statistics (TBSS) (Smith et al., 2006), voxel-based statistics on permutations and statistical analysis of the regions of interest (ROI) on WM tracts by means of general linear model (GLM).

TBSS follows an hypothesis on two samples based on permutations using the “Randomise” tool (Winkler et al., 2014) of FSL (Jenkinson et al., 2012) comparing the FA values of both groups of the WM. The test was performed with multiple correction tests and with the “Threshold-Free Cluster Free Enhancement” (TFCE) (Smith & Nichols, 2009), that leads to the automatic elimination of eventual less significative clusters. The significative threshold accepted was 0.05 after 10.000 casual permutations.

For the regional statistics, we used definite ROIs deriving from the WM of the John Hopkins University atlant including FSL (Moriet al., 2005), measuring the mean FA value for every single person. The ROIs used correspond to the principal WM tracts either above or below the cerebellar tentorium. The mean FA values calculated were used as a Y vector, therefore a linear regression was performed following the linear model (Matlab, The MathWorks, Inc., Natick, Massachusetts, United States):

The intergroup statistical significant difference for ROIs values were considered when p-values reached the level of <0.005 with multiple test corrections.

fMRI

Functional data were acquired by means of a T2-weighted EPI sequence of 178 volumes (TR = 2 sec, FOV = 128 x 128 x 40, voxel size 1.875 x 1.875 x 3.5 mm³) covering the whole brain and cerebellum. Functional images were acquired both during cognitive and motor tasks, and also during rest.

The cognitive task was used to investigate brain activation during executive and attentive functions (Stroop test), while the motor stimulus was selected to study brain activation during a task that implies manual coordination and precision (Finger tapping test). Resting state data were processed in order to measure functional connectivity.

During the Finger-tapping task, subjects were asked to press the buttons of an hand-shaped response-pad with a precise order, from thumb to small finger, and with the best possible accuracy. A block-design paradigm with 6 repetitions (20s of stimulus per each hand + 16s of rest) for each hand were used, for a total duration of 5 minutes and 40 seconds. The Endinburg inventory was administered to all patients and healthy controls in order to test the handedness. (Oldfield, 1971).

The block-design task of the Stroop-test consisted in 30 alternating blocks of colour identification trials such as congruent and incongruent colour/word blocks. During colour identification blocks, subjects would view a series of 10 stimuli ('XXXX') and would be instructed to identify the font colour of each stimulus as quickly as possible (e.g., 'XXXX' in blue). Four colours were – red, blue, yellow and green – and mapped to response keys for, respectively, the index and middle fingers of the right and left hand. During congruent and incongruent colour/word blocks, subjects would view a series of 20 colour names presented in a congruent or incongruent font colour and would be asked to identify the font colour. Each stimulus was displayed for 1000 ms; a 12-second rest interval occurred half-way through the task.

Colour identification requests and congruent/incongruent stimuli were randomly presented through MRI compatible goggles. Subjects registered their responses using response pads with their left and right hands. The total paradigm would last 7 minutes.

Before the exam each subject was instructed about how to perform tasks in the correct way with a short training.

The functional data were analysed using Matlab 7.11 (The Mathworks Inc., Natick, MA/USA), and Statistical Parametric Mapping (SPM8) software, Wellcome Department of Imaging Neuroscience, London, UK). Preprocessing of fMRI data will include different steps. A slice timing correction of the shift between slices in the range of $(0, TR)$ seconds, to obtain the time-course desired. In the next step we performed the realignment of the volumes obtaining also a mean volume of the whole sequence; this volume was normalized on the Montreal Neurological Institute (MNI) space using the standard EPI template included in the SPM package. Then we obtained a transformation matrix to apply to all the single volumes to normalize the entire sequence on the standard space, re-sampled at the voxel size of $2 \times 2 \times 2$ mm³. To check the activations on the morphological T1-weighted volume we also performed the segmentation process with the use of segmentation parameters to normalize morphological data. Finally we smoothed functional data with 6-mm isotropic FWHM Gaussian kernel, in order to attain and to compensate for the residual macro-anatomical variations among the subjects. A random effect analysis was used (single-case analysis) at the point when we collected a sufficient number of patients. The experimental conditions were specified as interest regressors. Linear contrasts to the parameter estimates of the experimental conditions was applied at the level of each single subject in order to obtain a t-statistic for every voxel. The Random Effects Analysis at the level of the group analysis occurred, when the linear contrast images were inserted in a one-sample t-test analysis in order to create SPM{T} maps, indicating the

specific and significant activations for every contrast at the level of group analysis. A statistical cut off value of $p < 0.05$ was used, corrected for multiple contrasts at cluster levels with a height threshold at the level of each voxel of $p < 0.001$ (not corrected).

T1-WEIGHTED IMAGES

Anatomical images were acquired with a T1-weighted 3D Turbo Field Echo (TFE) sequence (TR=8.3 ms, TE=3.9 ms, 150 sagittal slices with no gap, FOV=240x240 mm², voxel size 1x1x1 mm³) as anatomical reference for fMRI data and for gray/white matter (GM/WM) segmentation and volumes calculation.

T1 image analysis include several preprocessing and quantification steps. Firstly, intensity artefacts due to the bias field inhomogeneities are corrected using N4ITK tool (Tustison et al., 2010) included in ANTs (<http://stnava.github.io/ANTs/>, Advanced Normalization Tools). Then, the brain is extracted from the images and it is segmented into WM, GM and cerebro-spinal fluid (CSF) using the ATROPOS (Avants et al., 2011) tool included in ANTs. From the segmented images of the brain, WM and GM volumes are derived.

Subsequently, images are elaborated using the tools included in FreeSurfer software suite (<http://surfer.nmr.mgh.harvard.edu>). More precisely, the following steps are performed: surface generation, topology correction, surface inflation, registration to a spherical atlas, cortical parcellation and thickness calculation (Fischl et al. 2000).

Voxel-based morphometry (VBM)

The VBM was performed to assess eventual intergroup differences in the cortical thickness of patients and healthy controls. We have faced some problems due to the volume registration and segmentation, which le to difficulties in preliminary analysis.

RESULTS

In this study we report the MRI findings regarding the MRI data acquired from 30 subjects who voluntarily underwent MRI scan at the Scientific Institute “Eugenio Medea” in Bosisio Parini (Lecco).

Our cohort included early onset FRDA patients with a mean age at onset 10.65 ± 5.08 years (range 4-20 years); F/M gender ratio: 13/4; mean GAA expansion in the smaller repeat was 651.07 ± 234.39 (n=16) and one patients with a single base pair deletion and 170 GAA repeat. The mean age at assessment was 27.82 ± 10.51 years (range 12-50), mean disease duration was 17.17 ± 8.43 years (range 4-33). The mean age of the control group was 23 ± 4.83 years; F/M gender ratio = 5/8. The fMRI data were analyzed from 13 patients (mean age 30.05 ± 11.76 years) and 8 controls (mean age 24.5 ± 3.85 years).

ROI-based analysis

From an initial analysis of the FA values, significant differences in FRDA patients compared to healthy controls were found (Table 3.1). The FA values of controls are significantly higher when compared to the FRDA patients.

We further analysed the WM of the bundles by considering the MD values. Significant differences found in FRDA patients compared to healthy controls are demonstrated in table 3.2. The statistical analysis has taken into account the differences in age and gender distribution of both cohorts.

In summary, the areas that showed FA and MD impairment are assembled as follows:

- Cerebellar WM (superior, middle and inferior peduncles)
- Motor and sensory long tracts (lemniscus, CST and cerebral peduncles)
- Major commissural bundles (splenium of corpus callosum, tapetum)
- Thalamic and optic radiations

Voxel-based analysis

The voxel-based analysis has confirmed the ROI-based analysis, demonstrating FA and MD variations corresponding to the above mentioned bundle voxels. The principal differences were evidenced at the corpus callosum, that demonstrated diffusive WM structural alterations. However, this finding should be cautiously analysed due to the possible partial volume influx on the data. Figures 3.1-3.5 demonstrate voxels corresponding to the FA impaired areas such as optic radiation, the CST, and cerebellar involvement (middle and superior peduncles).

Finger tapping data

In this section of the study, the two groups consisted of 13 FRDA patients (mean age = 30.05 ± 11.76 years) and 8 healthy controls (mean age = $24,5 \pm 3,85$ years).

An initial Fixed Effect analysis was performed on each subject via GLM by using the movement parameters as confounds. These data were subsequently used to perform the group Random Effect Analysis. Age and gender were used as regressors. The intergroup differences were calculated through a two-tailed test.

By considering the FRDA group we have demonstrated that the finger tapping task led to the expected and evident cortical activation in line with the healthy control group, the controlateral motor cortex and ipsilateral cerebellar cortex. The figures demonstrates activation of controlateral motor cortical and omolateral cerebellar areas activated during Right (Figure 3.6 and 3.7) and Left hand (Figure 3.8 and 3.9) finger tapping task in FRDA patients and healthy controls.

By considering an intergroup analysis of the differences in cortical activation between FRDA patients and healthy controls, emerged that the cerebellar cortex activation, in particular lobules V and VI, was higher in the patients group when compared to the healthy control one (Figure 3.10 and 3.11).

Stroop test

We performed the analysis of data derived from Stroop test with analogous methods to the previous task.

Unfortunately, the small number of patients and due to the presence of movement artefacts in a consistent part of the cohort did not allow to generate any data. The good quality data were distributed as follows: 9 FRDA patients and 6 healthy controls. Both groups were small enough to produce significant results. Therefore, it is necessary to provide a larger sample in order to be able to perform valid intra- and intergroup analysis.

Resting state data

The resting state fMRI data analysis is ongoing by means of ICA.

TBSS

The TBSS statistical analysis are ongoing.

Voxel-Based Morphometry (VBM)

The main hypothesis to test is whether there is any differences in the intergroup cortical thickness. The VBM analysis is ongoing.

DISCUSSION

We report the DTI and fMRI data from a cohort of FRDA patients confronted to a control group. The patients were all homozygous for GAA triplet repeat, but one that was heterozygous for the expansion and presented with a deletion.

The cohort of patients had an early onset of FRDA, with an age at MRI that ranged from 12 to 50 years but with a mean age at around 27 years old. The disease duration ranged from 4 to 33 years. The control group younger than the patients had a mean age of 23 years. Regarding the DTI, we analysed 17 FRDA patients, whereas for the fMRI analysis only 13 of them. The control group size was 8 adult subjects.

From the DTI analysis (either ROI-based or voxel-based) emerged that there is a significant reduction of FA and MD values in FRDA patients in 4 major CNS areas. There

is a prevalent involvement of cerebellar peduncles (SCP, MCP and ICP) (FA/MD). The long sensory tracts FA is prevalently impaired in the medial lemniscuses, CST and cerebral peduncles, with MD additionally impaired in the medial lemniscuses. The FA and MD are impaired as well in the major commissural bundles such as corpus callosum (CC) (body, splenium and tapetum). And finally, FA and MD values regarding thalamic and optic radiation are impaired in FRDA patients compared to healthy controls. Prakash et al. (2009) studied a group of SCA1 patients finding out significantly decreased FA in all the three cerebellar peduncles and this decrease correlated with disease severity. Akhalaghi et al., 2011 demonstrates that the cross-sectional area of SCP was significantly reduced in FRDA patients and correlates positively to AAO, and negatively to FARS score and DD. Other studies reported atrophic CNS areas in FRDA patients. Pagani et al. (2010) reported WM atrophy in their 16 FRDA patients in the following areas: central portion of the medulla oblongata, dorsal upper pons, SCPs, the central portion of the midbrain, the medial portion of the right cerebral peduncle, the peridentate region, bilaterally, and the optic chiasm. These findings were found to correlate with the clinical status of the patients. Chevis et al. (2013) demonstrated that spinal cord area in their 33 FRDA patients was smaller than the healthy controls and negatively correlated with the FARS scores. Della Nave et al (2008) by mean of TBSS found decreased FA in medulla, cerebellar hemispheres and small segments of occipitofrontal and inferior longitudinal fasciculus in 14 FRDA patients. In addition, Della Nave et al. (2011) reported increased MD in 14 FRDA patients in the decussation of the SCPs. Zalesky et al. (2013) reported an extended study in 13 FRDA patients indicating the WM connectivity disruptions of the cerebello-cerebral circuitry, either in motor areas (supplementary motor area, putamen and pallidum) or in non-motor areas (cingulated cortex, hippocampus and frontal cortex). Additionally, they imply for the disruption of the connectivity between brainstem and cerebellum. While

Fortuna et al. (2009) reported an increased ADC in the optic radiations. Rizzo et al. (2011) reported increased MD in medulla, cerebellar hemispheres, vermis and peduncles, brainstem and optic radiations. Corben et al. (2014) reported that the reduction in the magnetization transfer imaging ratio in the SCP and no alteration in the CC in their cohort of 10 FRDA patients, was indicative of SCP myelination scarcity. Synofzik et al (2011) reports hyperechogenicity of the dentate nucleus in a cohort of 34 FRDA in most of the patients and observe this finding even in the patients with a short DD.

The fMRI findings with the finger tapping task evidenced, from an intragroup analysis, a high activation of the contralateral motor cortex and ipsilateral cerebellar cortex. This finding was consistent either with left or right hand, and also consistently present in both cohorts. An intergroup analysis compared the activated areas in both groups during the finger tapping task. From this analysis emerges that there is a higher cerebellar cortex activation in FRDA patients, and in particular in the lobules V and VI. The lobule V is involved in sensorymotor tasks, in motor activation and somatosensory activation. In addition, the lobule VI is involved in sensorymotor tasks, language, spatial tasks, executive functions, emotions (Grimaldi and Manto, 2012).

Previously published functional works report a variety of findings.

Jayakumar et al. (2008) have performed a fMRI study with a set of supination/pronation tasks in SCA1 patients, suggesting a decoupling of sensorimotor cortical and cerebellar areas, therefore a probable rupture of

cortico-cerebellar loops. Interestingly, from an fMRI study in healthy volunteers (Liu et al., 2011) with a finger tapping task found out three regions involved in sustained negative BOLD response, mainly frontal, somatosensory and occipital. They suggested that the findings imply more of a suppression of neuronal activity rather than blood steal event.

Mantovan et al. (2006) report heterogeneous cortical activation in FRDA during self-paced

finger movements. Other groups have provided even cognitive tasks. In particular, Georgiou-Karistianis et al. (2012) by using the Simon effect in fMRI implied a reduction in functional brain activation, reduced functional connectivity between cortical and subcortical regions. This implies a possible disruption of cortico-cerebellar loops and ineffective engagement of cognitive and attention regions.

A limitation of this study is the sample size. This is due to the fact that FRDA is a rare condition and despite the not indifferent number of patients recruited (n=22), some of them were in a very advanced stage of their disease which explains why their MRI scan data were almost “dirty” of movement artefacts. An insufficient sample size did not allow a statistical analysis for the fMRI cognitive task data. In addition, the cognitive task provided within the MRI protocol appeared to be not easy to all the patients. Some of them stated that they did not understand the task despite they were provided with a pre-MRI training. The recruited patients ranged either in severity of disease (FARS stage 2-6) or in AAV (12-50 years). In addition, the DTI and fMRI analysis lack of the clinical scales correlation.

Von Hohenberg et al. (2013) performed DTI in 12 FRDA and found out significant correlations between radial diffusivity (RD) and FARS scores and also with the number of GAA repeat expansion, suggesting the DTI as an informative biomarker in this condition. Mascalchi, (2013) in Letters writes in response to Vedolin et al. (2012) pointing out that visually assessed MRI in early onset FRDA are normal, no atrophy or reduction in cerebellar size can be found and this is confirmed by Della Nave et al. 2008 (Brain WM....) by VBM study. Nevertheless, Mascalchi points out the occurrence of microstructural changes in FRDA. These changes could be figured out with morphometry or DTI computational measures which lead to the findings that superior cerebellar peduncles and this correlate to neurological severity, in addition damage in the

deep cerebellar nuclei such as dentate nuclei are observed and confirmed. Probably SCP could be a good biomarker for FRDA but however it required proper computational tools, and in addition even the iron deposition in the dentate nuclei observed in T2 acquisition and postprocessing. Santner et al. (2014) have tested the effect of two months treatment rhuEPO in 9 FRDA patients with scans pre- and post-treatment. They found out an increase in VBM in the grey matter of the thalami (pulvinar) in post when compared to pre, and this correlated with ataxia scores. In addition there was an increase in the posterior parietal cortex. But this study has a small sample and it is still difficult to generalize or compare these findings to others due to the fact that images are acquired in different scanners. Solbach et al. (2014) suggest to cautiously consider iron content in DN as a biomarker in FRDA trials, due to the fact that they found atrophy of the cerebellum and DN in their cohort (14FRDA/14controls) but normal iron content.

Our results support the evidence that DTI and fMRI techniques may provide reliable quantitative biomarkers that could be used in longitudinal studies for prognostic and therapeutic clinical trials.

Further work is needed to identify which is the best MRI technique that is more sensitive to detect the most efficient biomarker of FRDA at different stages of disease. Probably, even a composition of MRI techniques might provide an appropriate array of measures suitable to complement the clinical assessment.

REFERENCES

- Ackroyd RS, Finnegan JA, Green SH. Friedreich's ataxia. A clinical review with neurophysiological and echocardiographic findings. *Arch Dis Child*. 1984 Mar;59(3):217-21.
- Arnold P, Boulat O, Maire R, Kuntzer T (2006) Expanding view of phenotype and oxidative stress in Friedreich's ataxia patients with and without odebnone. *Schweiz Arch Neurol Psychiatr* 157:169–176.
- Akhlaghi H, Yu J, Corben L, Georgiou-Karistianis N, Bradshaw JL, Storey E, Delatycki MB, Egan GF. Cognitive Deficits In Friedreich Ataxia Correlate with Micro-structural Changes in Dentatorubral Tract. *Cerebellum*. 2013 Oct 2.
- Akhlaghi H, Corben L, Georgiou-Karistianis N, Bradshaw J, Delatycki MB, Storey E, Egan GF. A functional MRI study of motor dysfunction in Friedreich's ataxia. *Brain Res*. 2012 Aug 30;1471:138-54.
- Akhlaghi H, Yu J, Corben L, Georgiou-Karistianis N, Bradshaw JL, Storey E, Delatycki MB, Egan GF. Cognitive deficits in Friedreich ataxia correlate with micro-structural changes in dentatorubral tract. *Cerebellum*. 2014 Apr;13(2):187-98. doi: 10.1007/s12311-013-0525-4. PMID: 24085646

Akhlaghi H., Corben L., Georgiou-Karistianis N., Bradshaw J., Storey E., Delatycki M. B. and Egan G. F. Superior cerebellar peduncle atrophy in Friedreich's ataxia correlates with disease symptoms. *Cerebellum* (2011) 10, 81–87.

Anheim M, Mariani LL, Calvas P, Cheuret E, Zagnoli F, Odent S, Seguela C, Marelli C, Fritsch M, Delaunoy JP, Brice A, Dürr A, Koenig M. Exonic deletions of FXN and early-onset Friedreich ataxia. *Arch Neurol*. 2012 Jul;69(7):912-6. PMID: 22409940

Alvarez V, Arnold P, Kuntzer T. Very late-onset Friedreich ataxia: later than life expectancy? *J Neurol*. 2013 May;260(5):1408-9. doi: 10.1007/s00415-013-6874-6. Epub 2013 Feb 22. No abstract available. PMID: 23430166

Bell J. and Carmichael EA. (1939) On hereditary ataxia and spastic paraplegia. In: *Treasury of Volume IV, Part III*, pp. 141-281.

Brousse M. (1882) De l'ataxie hereditaire. These de Montpellier (quoted by Ladame (1890)).

Bulteau AL, O'Neill HA, Kennedy MC, Ikeda-Saito M, Isaya G, Szweda LI. Frataxin acts as an iron chaperone protein to modulate mitochondrial aconitase activity. *Science*. 2004 Jul 9;305(5681):242-5.

Campuzano V, Montermini L, Moltò MD, Pianese L, Cossée M, Cavalcanti F, Monros E, Rodius F, Duclos F, Monticelli A, Zara F, Cañizares J, Koutnikova H, Bidichandani SI, Gellera C, Brice A, Trouillas P, De Michele G, Filla A, De Frutos R, Palau F, Patel PI, Di Donato S, Mandel JL, Coccozza S, Koenig M, Pandolfo M. Friedreich's ataxia: autosomal recessive disease caused by an intronic GAA triplet repeat expansion. *Science*. 1996 Mar 8;271(5254):1423-7. PMID: 8596916

Campuzano V, Montermini L, Lutz Y, Cova L, Hindelang C, Jiralerspong S, Trottier Y, Kish SJ, Faucheux B, Trouillas P, Authier FJ, Dürr A, Mandel JL, Vescovi A, Pandolfo M, Koenig M. Frataxin is reduced in Dürr A, Cossee M, Agid Y, Campuzano V, Mignard C,

Penet C, Mandel JL, Brice A, Koenig M. Clinical and genetic abnormalities in patients with Friedreich's ataxia. *N Engl J Med*. 1996 Oct 17;335(16):1169-75.

Delatycki MB, Paris DB, Gardner RJ, Nicholson GA, Nassif N, Storey E, MacMillan JC, Collins V, Williamson R, Forrest SM. Clinical and genetic study of Friedreich ataxia in an Australian population. *Am J Med Genet*. 1999 Nov 19;87(2):168-74. PMID: 10533031.

Delatycki MB, Corben LA. Clinical features of Friedreich ataxia. *J Child Neurol*. 2012 Sep;27(9):1133-7. doi: 10.1177/08830738124448230. Epub 2012 Jun 29. Review. PMID: 22752493

Filla A, DeMichele G, Caruso G, Marconi R, Campanella G. Genetic data and natural history of Friedreich's disease: a study of 80 Italian patients. *J Neurol*. 1990 Oct;237(6):345-51. PMID: 2277267

Filla A, De Michele G, Cavalcanti F, Pianese L, Monticelli A, Campanella G, Coccozza S. The relationship between trinucleotide (GAA) repeat length and clinical features in Friedreich ataxia. *Am J Hum Genet*. 1996 Sep;59(3):554-60.

Filla A, De Michele G, Coppola G, Federico A, Vita G, Toscano A, Uncini A, Pisanelli P, Barone P, Scarano V, Perretti A, Santoro L, Monticelli A, Cavalcanti F, Caruso G, Coccozza S. Accuracy of clinical diagnostic criteria for Friedreich's ataxia. *Mov Disord*. 2000 Nov;15(6):1255-8. PMID: 11104216

Filla A., Carlomagno S, Di Iorio G, Federico A, Guadagnino M. and Campanella G. Epidemiological study of inherited ataxia in Campania (a region of southern Italy). *Pharmacology* (1981) 22, 66–67

Foury F, Cazzalini O. Deletion of the yeast homologue of the human gene associated with Friedreich's ataxia elicits iron accumulation in mitochondria. *FEBS Lett*. 1997 Jul 14;411(2-3):373-7.

Friedreich N. Uber degenerative Atrophie der spinalen Hinterstrange. Virchow's Archiv fur Pathologische Anatomie und Physiologie und fur Klinische Medicin, (1863a) 26, 391-419.

Friedreich N. Uber degenerative Atrophie der spinalen Hinterstrange. Virchow's Archiv fur Pathologische Anatomie und Physiologie und fur Klinische Medicin, (1863b) 26, 433-459.

Friedreich N. Uber degenerative Atrophie der spinalen Hinterstrange. Virchow's Archiv fur Pathologische Anatomie und Physiologie und fur Klinische Medicin, (1863C) 27, 1-26.

Friedreich N. Uber ataxie mit besonderer beriicksichtigung der hereditaren formen. Virchow's Archiv fur Pathologische Anatomie und Physiologie und fur Klinische Medicin, (1876) 68, 145-245.

Friedreich N. Uber ataxie mit besonderer beriicksichtigung der hereditaren formen. Virchow's Archiv fur Pathologische Anatomie und Physiologie und fur Klinische Medicin, (1877) 70, 140-152.

Geoffroy G, Barbeau A, Breton G, Lemieux B, Aube M, Leger C, Bouchard JP. Clinical description and roentgenologic evaluation of patients with Friedreich's ataxia. Can J Neurol Sci. 1976 Nov;3(4):279-86. PMID: 1087179

González-Cabo P, Vázquez-Manrique RP, García-Gimeno MA, Sanz P, Palau F. Frataxin interacts functionally with mitochondrial electron transport chain proteins. Hum Mol Genet. 2005 Aug 1;14(15):2091-8. Epub 2005 Jun 16.

Harding AE. Friedreich's ataxia: a clinical and genetic study of 90 families with an analysis of early diagnostic criteria and intrafamilial clustering of clinical features. Brain. 1981 Sep;104(3):589-620. PMID: 7272714.

Harding AE. Classification of the hereditary ataxias and paraplegias. Lancet. 1983 May 21;1(8334):1151-5. No abstract available. PMID: 6133167.

Hodge G. Three cases of Friedreich's disease all presenting marked increase of the knee jerk. British Medical Journal, (1897) 1, 1405-1406.

Koeppen AH, Mazurkiewicz JE. Friedreich ataxia: neuropathology revised. *J Neuropathol Exp Neurol.* 2013 Feb;72(2):78-90. doi: 10.1097/NEN.0b013e31827e5762. Review. PMID: 23334592

Koutnikova H, Campuzano V, Foury F, Dollé P, Cazzalini O, Koenig M. Studies of human, mouse and yeast homologues indicate a mitochondrial function for frataxin. *Nat Genet.* 1997 Aug;16(4):345-51.

Ladame P. Friedreich's disease. *Brain,* (1890) 13, 467-537.

Lamont PJ, Davis MB, Wood NW. Identification and sizing of the GAA trinucleotide repeat expansion of Friedreich's ataxia in 56 patients. Clinical and genetic correlates. *Brain.* 1997 Apr;120 (Pt 4):673-80.

Leone M, Brignolio F, Rosso MG, Curtoni ES, Moroni A, Tribolo A, Schiffer D. Friedreich's ataxia: a descriptive epidemiological study in an Italian population. *Clin Genet.* 1990 Sep;38(3):161-9.

Lesuisse E, Santos R, Matzanke BF, Knight SA, Camadro JM, Dancis A. Iron use for haeme synthesis is under control of the yeast frataxin homologue (Yfh1). *Hum Mol Genet.* 2003 Apr 15;12(8):879-89. PMID: 12668611.

Monrós E, Moltó MD, Martínez F, Cañizares J, Blanca J, Vílchez JJ, Prieto F, de Frutos R, Palau F. Phenotype correlation and intergenerational dynamics of the Friedreich ataxia GAA trinucleotide repeat. *Am J Hum Genet.* 1997 Jul;61(1):101-10.

McCabe DJ, Ryan F, Moore DP, McQuaid S, King MD, Kelly A, Daly K, Barton DE, Murphy RP. Typical Friedreich's ataxia without GAA expansions and GAA expansion without typical Friedreich's ataxia. *J Neurol.* 2000 May;247(5):346-55.

Montermini L, Richter A, Morgan K, Justice CM, Julien D, Castellotti B, Mercier J, Poirier J, Capozzoli F, Bouchard JP, Lemieux B, Mathieu J, Vanasse M, Seni MH, Graham G, Andermann F, Andermann E, Melançon SB, Keats BJ, Di Donato S, Pandolfo M.

Phenotypic variability in Friedreich ataxia: role of the associated GAA triplet repeat expansion. *Ann Neurol.* 1997 May;41(5):675-82. PMID: 9153531.

Pandolfo M. Molecular basis of Friedreich ataxia. *Mov Disord.* 2001 Sep;16(5):815-21.

Pastore A, Puccio H. Frataxin: a protein in search for a function. *J Neurochem.* 2013 Aug;126 Suppl 1:43-52. doi: 10.1111/jnc.12220.

Romeo G, Menozzi P, Ferlini A, Fadda S, Di Donato S, Uziel G, Lucci B, Capodaglio L, Filla A, Campanella G. Incidence of Friedreich ataxia in Italy estimated from consanguineous marriages. *Am J Hum Genet.* 1983 May;35(3):523-9.

Ruano L, Melo C, Silva MC, Coutinho P. The global epidemiology of hereditary ataxia and spastic paraplegia: a systematic review of prevalence studies. *Neuroepidemiology.* 2014;42(3):174-83. doi: 10.1159/000358801. Epub 2014 Mar 5. Review. PMID: 24603320.

Shan Y, Napoli E, Cortopassi G. Mitochondrial frataxin interacts with ISD11 of the NFS1/ISCU complex and multiple mitochondrial chaperones. *Hum Mol Genet.* 2007 Apr 15;16(8):929-41. Epub 2007 Mar 1.

Sherman I. Friedreich's disease. A report of 2 unusual cases. *Archives of Neurology and Psychiatry Chicago,* (1934) 32, 1282-1285.

Schöls L, Amoiridis G, Przuntek H, Frank G, Epplen JT, Epplen C. Friedreich's ataxia. Revision of the phenotype according to molecular genetics. *Brain.* 1997 Dec;120 (Pt 12):2131-40. PMID: 9448568

Vankan P. Prevalence gradients of Friedreich's ataxia and R1b haplotype in Europe co-localize, suggesting a common Palaeolithic origin in the Franco-Cantabrian ice age refuge. *J Neurochem.* 2013 Aug;126 Suppl 1:11-20. doi: 10.1111/jnc.12215.

Wilson SAK. (1940) *Neurology.* Edited by A. N. Bruce. London: Arnold, pp. 943-946.

Bhidayasiri R, Perlman SL, Pulst SM, Geschwind DH. Late-onset Friedreich ataxia: phenotypic analysis, magnetic resonance imaging findings, and review of the literature. *Arch Neurol*. 2005 Dec;62(12):1865-9.

Bourke T, Keane D. Friedreich's Ataxia: a review from a cardiology perspective. *Ir J Med Sci*. 2011 Dec;180(4):799-805. doi: 10.1007/s11845-011-0744-y. Epub 2011 Aug 7.

Finocchiaro G, Baio G, Micossi P, Pozza G, di Donato S. Glucose metabolism alterations in Friedreich's ataxia. *Neurology*. 1988 Aug;38(8):1292-6. PMID: 3041313.

Fortuna F, Barboni P, Liguori R, Valentino ML, Savini G, Gellera C, Mariotti C, Rizzo G, Tonon C, Manners D, Lodi R, Sadun AA, Carelli V. Visual system involvement in patients with Friedreich's ataxia. *Brain*. 2009 Jan;132(Pt 1):116-23. doi: 10.1093/brain/awn269. Epub 2008 Oct 18.

Parkinson MH, Boesch S, Nachbauer W, Mariotti C, Giunti P. Clinical features of Friedreich's ataxia: classical and atypical phenotypes. *J Neurochem*. 2013 Aug;126 Suppl 1:103-17. doi: 10.1111/jnc.12317. Review. PMID: 23859346

Dutka DP, Donnelly JE, Nihoyannopoulos P, Oakley CM, Nunez DJ. Marked variation in the cardiomyopathy associated with Friedreich's ataxia. *Heart*. 1999 Feb;81(2):141-7.

Galimanis A, Glutz L, Spiegel R, Burgunder JM, Kaelin-Lang A. Very-late-onset Friedreich ataxia with disturbing head tremor and without spinal atrophy--a case report. *Mov Disord*. 2008 May 15;23(7):1058-9. doi: 10.1002/mds.21946. PMID: 18361475

Stolle CA, Frackelton EC, McCallum J, Farmer JM, Tsou A, Wilson RB, Lynch DR. Novel, complex interruptions of the GAA repeat in small, expanded alleles of two affected siblings with late-onset Friedreich ataxia. *Mov Disord*. 2008 Jul 15;23(9):1303-6. doi: 10.1002/mds.22012.

Klockgether T, Zühlke C, Schulz JB, Bürk K, Fetter M, Dittmann H, Skalej M, Dichgans J. Friedreich's ataxia with retained tendon reflexes: molecular genetics, clinical neurophysiology, and magnetic resonance imaging. *Neurology*. 1996 Jan;46(1):118-21.

Coppola G, De Michele G, Cavalcanti F, Pianese L, Perretti A, Santoro L, Vita G, Toscano A, Amboni M, Grimaldi G, Salvatore E, Caruso G, Filla A. Why do some Friedreich's ataxia patients retain tendon reflexes? A clinical, neurophysiological and molecular study. *J Neurol*. 1999 May;246(5):353-7. PMID: 10399865

Richter A, Poirier J, Mercier J, Julien D, Morgan K, Roy M, Gosselin F, Bouchard JP, Melançon SB. Friedreich ataxia in Acadian families from eastern Canada: clinical diversity with conserved haplotypes. *Am J Med Genet*. 1996 Sep 6;64(4):594-601. PMID: 8870928

Cossée M, Dürr A, Schmitt M, Dahl N, Trouillas P, Allinson P, Kostrzewa M, Nivelon-Chevallier A, Gustavson KH, Kohlschütter A, Müller U, Mandel JL, Brice A, Koenig M, Cavalcanti F, Tammara A, De Michele G, Filla A, Coccozza S, Labuda M, Montermini L, Poirier J, Pandolfo M. Friedreich's ataxia: point mutations and clinical presentation of compound heterozygotes. *Ann Neurol*. 1999 Feb;45(2):200-6. PMID: 9989622

Corben L. A., Akhlaghi H., Georgiou-Karistianis N., Bradshaw J. L., Egan G. F., Storey E., Churchyard A. J. and Delatycki M. B. Impaired inhibition of prepotent motor tendencies in Friedreich ataxia demonstrated by the Simon interference task. *Brain Cogn*. 2011a, 76, 140–145.

Corben L. A., Georgiou-Karistianis N., Bradshaw J. L., Hocking D. R., Churchyard A. J. and Delatycki M. B. The Fitts task reveals impairments in planning and online control of movement in Friedreich ataxia: reduced cerebellar-cortico connectivity? *Neuroscience* (2011b) 192, 382–390.

Corben L. A., Delatycki M. B., Bradshaw J. L., Churchyard A. J. And Georgiou-Karistianis N. Utilization of advance motor information is impaired in Friedreich ataxia. *Cerebellum* (2011c) 10, 793–803.

Corben L. A., Georgiou-Karistianis N., Fahey M., Storey E., Churchyard A., Horne M., Bradshaw J. L. and Delatycki M. B. Towards an understanding of cognitive function in Friedreich ataxia. *Brain Res. Bull.* (2006) 70, 197–202.

Mantovan M. C., Martinuzzi A., Squarzanti F., Bolla A., Silvestri I., Liessi G., Macchi C., Ruzza G., Trevisan C. P. and Angelini C. Exploring mental status in Friedreich's ataxia : a combined neuropsychological, behavioural and neuroimaging study. *Eur. J. Neurol.* (2006) 13, 827–835.

De Nobrega E., Nieto A., Barroso J. and Montón F. Differential impairment in semantic, phonemic, and action fluency performance in Friedreich's ataxia: possible evidence of prefrontal dysfunction. *J. Int. Neuropsychol. Soc.* (2007) 13, 944–952.

Klopper F, Delatycki MB, Corben LA, Bradshaw JL, Rance G, Georgiou-Karistianis N. *J Int Neuropsychol Soc.* 2011 Jan;17(1):196-200. doi: 10.1017/S1355617710001347. Epub 2010 Nov 17. The test of everyday attention reveals significant sustained volitional attention and working memory deficits in friedreich ataxia.

Nieto A, Correia R, de Nóbrega E, Montón F, Hess S, Barroso J. Cognition in Friedreich ataxia.

Cerebellum. 2012 Dec;11(4):834-44. doi: 10.1007/s12311-012-0363-9.

De Michele G., Di Salle F., Filla A., D'Alessio G., Ambrosio G., Viscardi L., Scala R. and Campanella G. Magnetic resonance imaging in “typical” and “late onset” Friedreich's disease and early onset cerebellar ataxia with retained tendon reflexes. *Ital. J. Neurol. Sci.* (1995) 16, 303–308.

Della N. R., Ginestroni A., Giannelli M., Tessa C., Salvatore E., Salvi F., Dotti M. T., De Michele G., Piacentini S. and Mascalchi M. Brain structural damage in Friedreich's ataxia. *J. Neurol. Neurosurg. Psychiatry* (2008)79, 82–85.

Lodi R, Hart PE, Rajagopalan B, Taylor DJ, Crilley JG, Bradley JL, Blamire AM, Manners D, Styles P, Schapira AH, Cooper JM. Antioxidant treatment improves in vivo cardiac and skeletal muscle bioenergetics in patients with Friedreich's ataxia. *Ann Neurol*. 2001;49:590–6.

Hart PE, Lodi R, Rajagopalan B, Bradley JL, Crilley JG, Turner C, Blamire AM, Manners D, Styles P, Schapira AH, Cooper JM. Antioxidant treatment of patients with Friedreich ataxia: four-year follow-up. *Arch Neurol*. 2005;62:621–6.

Cooper JM, Korlipara LV, Hart PE, Bradley JL, Schapira AH. Coenzyme Q10 and vitamin E deficiency in Friedreich's ataxia: predictor of efficacy of vitamin E and coenzyme Q10 therapy. *Eur J Neurol*. 2008;15:1371–9.

Hausse AO, Aggoun Y, Bonnet D, Sidi D, Munnich A, Rotig A, Rustin P. Idebenone and reduced cardiac hypertrophy in Friedreich's ataxia. *Heart*. 2002;87:346–9.

Buyse G, Mertens L, Di Salvo G, Matthijs I, Weidemann F, Eyskens B, Goossens W, Goemans N, Sutherland GR, Van Hove JL. Idebenone treatment in Friedreich's ataxia: neurological, cardiac, and biochemical monitoring. *Neurology*. 2003;60:1679–81.

Mariotti C, Solari A, Torta D, Marano L, Fiorentini C, Di Donato S. Idebenone treatment in Friedreich patients: one-year-long randomized placebo-controlled trial. *Neurology*. 2003;60:1676–9.

Lagedrost SJ, Sutton MS, Cohen MS, Satou GM, Kaufman BD, Perlman SL, Rummey C, Meier T, Lynch DR. Idebenone in Friedreich ataxia cardiomyopathy-results from a 6-month phase III study (IONIA). *Am Heart J*. 2011;161:639–45.

Di Prospero NA, Baker A, Jeffries N, Fischbeck KH. Neurological effects of high-dose idebenone in patients with Friedreich's ataxia: a randomised, placebo-controlled trial. *Lancet Neurol.* 2007;6:878–86.

Perdomini M, Belbellaa B, Monassier L, Reutenauer L, Messaddeq N, Cartier N, Crystal RG, Aubourg P, Puccio H. Prevention and reversal of severe mitochondrial cardiomyopathy by gene therapy in a mouse model of Friedreich's ataxia. *Nat Med.* 2014;2:542–7.

Lynch DR, Perlman SL, Meier T. A phase 3, double-blind, placebo-controlled trial of idebenone in friedreich ataxia. *Arch Neurol.* 2010;67:941–7.

Costantini A, Giorgi R, Agostino S, Pala MI. High-dose thiamine improves the symptoms of Friedreich's ataxia. *BMJ Case Rep.* 2013 May 22;2013. pii: bcr2013009424. doi: 10.1136/bcr-2013-009424.

Boddaert N, Le Quan Sang KH, Rötig A, Leroy-Willig A, Gallet S, Brunelle F, Sidi D, Thalabard JC, Munnich A, Cabantchik ZI. Selective iron chelation in Friedreich ataxia: biologic and clinical implications. *Blood.* 2007;110:401–8. [PubMed]

Chan PK, Torres R, Yandim C, Law PP, Khadayate S, Mauri M, Grosan C, Chapman-Rothe N, Giunti P, Pook M, Festenstein R. Heterochromatinization induced by GAA-repeat hyperexpansion in Friedreich's ataxia can be reduced upon HDAC inhibition by vitamin B3. *Hum Mol Genet.* 2013;22:2662–75.

Velasco-Sánchez D, Aracil A, Montero R, Mas A, Jiménez L, O'Callaghan M, Tondo M, Capdevila A, Blanch J, Artuch R, Pineda M. Combined therapy with idebenone and deferiprone in patients with Friedreich's ataxia. *Cerebellum.* 2011;10:1–8.

Sturm B, Stupphann D, Kaun C, Boesch S, Schranzhofer M, Wojta J, Goldenberg H, Scheiber-Mojdehkar B. Recombinant human erythropoietin: effects on frataxin expression in vitro. *Eur J Clin Invest.* 2005;35:711–7.

Sarsero JP, Li L, Wardan H, Sitte K, Williamson R, Ioannou PA. Upregulation of expression from the FRDA genomic locus for the therapy of Friedreich ataxia. *J Gene Med.* 2003;5:72–81.

Libri V, Yandim C, Athanasopoulos S, Loyse N, Natisvili T, Law PP, Chan PK, Mohammad T, Mauri M, Tam KT, Leiper J, Piper S, Ramesh A, Parkinson MH, Huson L, Giunti P, Festenstein R. Epigenetic and neurological effects and safety of high-dose nicotinamide in patients with Friedreich's ataxia: an exploratory, open-label, dose-escalation study. *Lancet.* 2014 Apr 30. pii: S0140-6736(14)60382-2.

Mariotti C, Fancellu R, Caldarazzo S, Nanetti L, Di Bella D, Plumari M, Lauria G, Cappellini MD, Duca L, Solari A, Taroni F. Erythropoietin in Friedreich ataxia: no effect on frataxin in a randomized controlled trial. *Mov Disord.* 2012;27:446–9.

Boesch S, Sturm B, Hering S, Goldenberg H, Poewe W, Scheiber-Mojdehkar B. Friedreich's ataxia: clinical pilot trial with recombinant human erythropoietin. *Ann Neurol.* 2007;62:521–4.

Gottesfeld JM, Rusche JR, Pandolfo M. Increasing frataxin gene expression with histone deacetylase inhibitors as a therapeutic approach for Friedreich's ataxia. *J Neurochem.* 2013;126 Suppl 1:147–54.

Herman D, Jenssen K, Burnett R, Soragni E, Perlman SL, Gottesfeld JM. Histone deacetylase inhibitors reverse gene silencing in Friedreich's ataxia. *Nat Chem Biol.* 2006;2:551–8.

Rai M, Soragni E, Jenssen K, Burnett R, Herman D, Coppola G, Geschwind DH, Gottesfeld JM, Pandolfo M (2008) HDAC inhibitors correct frataxin deficiency in a Friedreich ataxia mouse model. *PLoS One.* 3:e1958.

Tomassini B, Arcuri G, Fortuni S, Sandi C, Ezzatizadeh V, Casali C, Condò I, Malisan F, Al-Mahdawi S, Pook M, Testi R. Interferon gamma upregulates frataxin and corrects the functional deficits in a Friedreich ataxia model. *Hum Mol Genet.* 2012;21:2855–61.

Chan PK, Torres R, Yandim C, Law PP, Khadayate S, Mauri M, Grosan C, Chapman-Rothe N, Giunti P, Pook M, Festenstein R. Heterochromatinization induced by GAA-repeat hyperexpansion in Friedreich's ataxia can be reduced upon HDAC inhibition by vitamin B3. *Hum Mol Genet.* 2013 Jul 1;22(13):2662-75. doi: 10.1093/hmg/ddt115. Epub 2013 Mar 7.

Corben LA, Lynch L, Pandolfo M, Schulz JB, Delatycki MB, and On behalf of the Clinical Management Guidelines Writing Group Consensus clinical management guidelines for Friedreich ataxia *Orphanet Journal of Rare Diseases* 2014, 9:184 doi:10.1186/s13023-014-0184-0184-

Schmitz-Hübbsch T, du Montcel ST, Baliko L et al Scale for the assessment and rating of ataxia: development of a new clinical scale. *Neurology* (2006) 66:1717–1720

Subramony SH, May W, Lynch D, Gomez C, Fischbeck K et al. Measuring Friedreich ataxia: Interrater reliability of a neurologic rating scale. *Neurology* 2005;64:1261-1262.

Trouillas P, Takayanagi T, Hallett M, Currier RD, Subramony SH, Wessel K, Bryer A, Diener HC, Massaquoi S, Gomez CM, Coutinho P, Ben Hamida M, Campanella G, Filla A, Schut L, Timann D, Honnorat J, Nighoghossian N, Manyam B. International Cooperative Ataxia Rating Scale for pharmacological assessment of the cerebellar syndrome. The Ataxia Neuropharmacology Committee of the World Federation of Neurology. *J Neurol Sci.* 1997 Feb 12;145(2):205-11. PMID: 9094050.

Bohannon, R.W. & Smith, M.B. (1987) Interrater reliability of a modified Ashworth scale of muscle spasticity. *Physical therapy*, 67, 206-207.

Compston, A. (2010) Aids to the investigation of peripheral nerve injuries. Medical Research Council: Nerve Injuries Research Committee. His Majesty's Stationery Office: 1942; pp. 48 (iii) and 74 figures and 7 diagrams; with aids to the examination of the peripheral nervous system. By Michael O'Brien for the Guarantors of Brain. Saunders Elsevier: 2010; pp. [8] 64 and 94 Figures. *Brain : a journal of neurology*, 133, 2838-2844.

Keith, R.A., Granger, C.V., Hamilton, B.B. & Sherwin, F.S. (1987) The functional independence measure: a new tool for rehabilitation. *Advances in clinical rehabilitation*, 1, 6-18.

Laboratories, A.T.S.C.o.P.S.f.C.P.F. (2002) ATS statement: guidelines for the six-minute walk test. *American journal of respiratory and critical care medicine*, 166, 111-117.

Wechsler, D. (1997). Wechsler Adult Intelligence Scale—third edition . San Antonio, TX: The Psychological Corporation.

SHALLICE, T. (1982). Specific Impairment of Planning. *Philosophical Transactions of the Royal Society of London B*, 298, 199-209, Krikorian R. et al., 1994 Tower of London procedure *Journal of Clinical and Experimental Psychology* 16: 840-850.

Mondini S, Mappelli D, Vestri A, Arcara G, Bisiacchi PS, editors. *Esame Neuropsicologico Breve 2 (ENB 2)*. Raffaello Cortina Editore; 2011.

Orsini A, Picone L, editors. *WISC-III. Contributo alla taratura italiana*. Firenze: Giunti OS. ISBN: 8809047273; 2006.

Vogel AP, Folker J, Poole ML. Treatment for speech disorder in Friedreich ataxia and other hereditary ataxia syndromes. *Cochrane Database Syst Rev*. 2014 Oct 28;10:CD008953. doi: 10.1002/14651858.CD008953.pub2. Review. PMID: 25348587

Poole ML, Wee JS, Folker JE, Corben LA, Delatycki MB, Vogel AP. Nasality in Friedreich ataxia. *Clin Linguist Phon*. 2015 Jan;29(1):46-58. doi: 10.3109/02699206.2014.954734. Epub 2014 Sep 10. PMID: 25207996

Dağ E, Örnek N, Örnek K, Erbahçeci-Timur IE. Optical coherence tomography and visual field findings in patients with Friedreich ataxia. *J Neuroophthalmol*. 2014 Jun;34(2):118-21. doi: 10.1097/WNO.0000000000000068. PMID: 24275983

de Nóbrega E1, Nieto A, Barroso J, Montón F. Differential impairment in semantic, phonemic, and action fluency performance in Friedreich's ataxia: possible evidence of prefrontal dysfunction. *J Int Neuropsychol Soc*. 2007 Nov;13(6):944-52.

Flood MK1, Perlman SL. The mental status of patients with Friedreich's ataxia. *J Neurosci Nurs*. 1987 Oct;19(5):251-5.

Leclercq M, Harmant J, de Barys T. Psychometric studies in Friedreich's ataxia. *Acta Neurol Belg*. 1985 Aug-Oct;85(4):202-21.

Ciancarelli I1, Cofini V, Carolei A. Evaluation of neuropsychological functions in patients with Friedreich ataxia before and after cognitive therapy. *Funct Neurol*. 2010 Apr-Jun;25(2):81-5.

Silva CB, Yasuda CL, D'Abreu A, Cendes F, Lopes-Cendes I, França MC Jr. Neuroanatomical correlates of depression in Friedreich's ataxia: a voxel-based morphometry study. *Cerebellum*. 2013 Jun;12(3):429-36. doi: 10.1007/s12311-012-0424-0.

Koziol LF, Budding D, Andreasen N, D'Arrigo S, Bulgheroni S, Imamizu H, Ito M, Manto M, Marvel C, Parker K, Pezzulo G, Ramnani N, Riva D, Schmahmann J, Vandervert L, Yamazaki T. Consensus paper: the cerebellum's role in movement and cognition. *Cerebellum*. 2014 Feb;13(1):151-77. doi: 10.1007/s12311-013-0511-x. PMID: 23996631

Jayakumar PN, Desai S, Pal PK, Balivada S, Ellika S, Kalladka D. Functional correlates of incoordination in patients with spinocerebellar ataxia 1: a preliminary fMRI study. *J Clin Neurosci*. 2008 Mar;15(3):269-77. doi: 10.1016/j.jocn.2007.06.021. Epub 2008 Jan 10.

Ormerod IE, Harding AE, Miller DH, Johnson G, MacManus D, du Boulay EP, Kendall BE, Moseley IF, McDonald WI. Magnetic resonance imaging in degenerative ataxic disorders. *J Neurol Neurosurg Psychiatry*. 1994 Jan;57(1):51-7. Review.

Villanueva-Haba V, Garcés-Sánchez M, Bataller L, Palau F, Vílchez J. Neuroimaging study with morphometric analysis of hereditary and idiopathic ataxia. *Neurologia*. 2001 Mar;16(3):105-11.

Della Nave R, Ginestroni A, Tessa C, Salvatore E, Bartolomei I, Salvi F, Dotti MT, De Michele G, Piacentini S, Mascalchi M. Brain white matter tracts degeneration in Friedreich ataxia. An in vivo MRI study using tract-based spatial statistics and voxel-based morphometry. *Neuroimage*. 2008a Mar 1;40(1):19-25.

Della Nave R, Ginestroni A, Tessa C, Cosottini M, Giannelli M, Salvatore E, Sartucci F, De Michele G, Dotti MT, Piacentini S, Mascalchi M. Brain structural damage in spinocerebellar ataxia type 2. A voxel-based morphometry study. *Mov Disord*. 2008b Apr 30;23(6):899-903. doi: 10.1002/mds.21982.

Prakash N, Hageman N, Hua X, Toga AW, Perlman SL, Salamon N. Patterns of fractional anisotropy changes in white matter of cerebellar peduncles distinguish spinocerebellar ataxia-1 from multiple system atrophy and other ataxia syndromes. *Neuroimage*. 2009 Aug;47 Suppl 2:T72-81. doi: 10.1016/j.neuroimage.2009.05.013. Epub 2009 May 14.

Di Prospero NA, Baker A, Jeffries N, Fischbeck KH. Neurological effects of high-dose idebenone in patients with Friedreich's ataxia: a randomised, placebo-controlled trial. *Lancet Neurol*. 2007 Oct;6(10):878-86.

Georgiou-Karistianis N, Akhlaghi H, Corben LA, Delatycki MB, Storey E, Bradshaw JL, Egan GF. Decreased functional brain activation in Friedreich ataxia using the Simon effect

task. *Brain Cogn.* 2012 Aug;79(3):200-8. doi: 10.1016/j.bandc.2012.02.011. Epub 2012 Apr 28.

Pierpaoli, C., Walker, L., Irfanoglu, M. O., Barnett, A. S., Basser, P. J., Chang, L.-C., Wu, M. T. (2010). TORTOISE: an integrated software package for processing of diffusion MRI data. ISMRM 18th Annual Meeting, 1597

Jenkinson, M., Beckmann, C. F., Behrens, T. E. J., Woolrich, M. W., & Smith, S. M. (2012). *FSL. NeuroImage*, 62(2), 782–90. doi:10.1016/j.neuroimage.2011.09.015

Mori, S., Wakana, S., van Zijl, P. C. M., & Nagae-Poetscher, L. M. (2005). *MRI Atlas of Human White Matter*. Elsevier Science. Retrieved from <http://books.google.ca/books?id=ltwRY1vFNLIC>.

Smith, S. M., Jenkinson, M., Johansen-Berg, H., Rueckert, D., Nichols, T. E., Mackay, C. E., ... Behrens, T. E. J. (2006). Tract-based spatial statistics: voxelwise analysis of multi-subject diffusion data. *NeuroImage*, 31(4), 1487–505. doi:10.1016/j.neuroimage.2006.02.024

Smith, S. M., & Nichols, T. E. (2009). Threshold-free cluster enhancement: addressing problems of smoothing, threshold dependence and localisation in cluster inference. *NeuroImage*, 44(1), 83–98. doi:10.1016/j.neuroimage.2008.03.061

Mascalchi M. The cerebellum looks normal in Friedreich ataxia. *AJNR Am J Neuroradiol.* 2013 Feb;34(2):E22. doi: 10.3174/ajnr.A3480. Epub 2013 Jan 17.

Solbach K, Kraff O2, Minnerop M3, Beck A4, Schöls L5, Gizewski ER6, Ladd ME7, Timmann D. Cerebellar pathology in Friedreich's ataxia: atrophied dentate nuclei with normal iron content. *Neuroimage Clin.* 2014 Aug 23;6:93-9. doi: 10.1016/j.nicl.2014.08.018. eCollection 2014.

Grimaldi G1, Manto M. Topography of cerebellar deficits in humans. *Cerebellum*. 2012 Jun;11(2):336-51. doi: 10.1007/s12311-011-0247-4.

Oldfield RC. The assessment and analysis of handedness: the Edinburgh inventory. *Neuropsychologia*. 1971 Mar;9(1):97-113. No abstract available. PMID: 5146491

Santner W, Schocke M, Boesch S, Nachbauer W, Egger K. A longitudinal VBM study monitoring treatment with erythropoietin in patients with Friedreich ataxia. *Acta Radiol Short Rep*. 2014 May 12;3(4):2047981614531573. doi: 10.1177/2047981614531573. eCollection 2014.

Synofzik M, Godau J, Lindig T, Schöls L, Berg D. Transcranial sonography reveals cerebellar, nigral, and forebrain abnormalities in Friedreich's ataxia. *Neurodegener Dis*. 2011;8(6):470-5. doi: 10.1159/000327751. Epub 2011 Jun 9. PMID: 21659723

Chevis CF1, da Silva CB, D'Abreu A, Lopes-Cendes I, Cendes F, Bergo FP, França MC Jr. Spinal cord atrophy correlates with disability in Friedreich's ataxia. *Cerebellum*. 2013 Feb;12(1):43-7. doi: 10.1007/s12311-012-0390-6.

Clemm von Hohenberg C1, Schocke MF, Wigand MC, Nachbauer W, Guttmann CR, Kubicki M, Shenton ME, Boesch S, Egger K. Radial diffusivity in the cerebellar peduncles correlates with clinical severity in Friedreich ataxia. *Neurol Sci*. 2013 Aug;34(8):1459-62. doi: 10.1007/s10072-013-1402-0. Epub 2013 May 3.

Corben LA, Kashuk SR, Akhlaghi H, Jamadar S, Delatycki MB, Fielding J, Johnson B, Georgiou-Karistianis N, Egan GF. Myelin paucity of the superior cerebellar peduncle in individuals with Friedreich ataxia: an MRI magnetization transfer imaging study. *J Neurol Sci*. 2014 Aug 15;343(1-2):138-43. doi: 10.1016/j.jns.2014.05.057. Epub 2014 Jun 2. PMID: 24930398

Liu Y, Shen H, Zhou Z, Hu D. Sustained negative BOLD response in human fMRI finger tapping task. *PLoS One*. 2011;6(8):e23839. doi: 10.1371/journal.pone.0023839. Epub 2011 Aug 24. PMID: 21887329

Pagani E, Ginestroni A, Della Nave R, Agosta F, Salvi F, De Michele G, Piacentini S, Filippi M, Mascalchi M. Assessment of brain white matter fiber bundle atrophy in patients with Friedreich ataxia. *Radiology*. 2010 Jun;255(3):882-9. doi: 10.1148/radiol.10091742.

Wollmann T1, Barroso J, Monton F, Nieto A. Neuropsychological test performance of patients with Friedreich's ataxia. *J Clin Exp Neuropsychol*. 2002 Aug;24(5):677-86.

White M, Lalonde R, Botez-Marquard T. Neuropsychologic and neuropsychiatric characteristics of patients with Friedreich's ataxia. *Acta Neurol Scand*. 2000 Oct;102(4):222-6. PMID: 11071106

Winkler, A. M., Ridgway, G. R., Webster, M. A., Smith, S. M., & Nichols, T. E. (2014). Permutation inference for the general linear model. *NeuroImage*, 92, 381–97. doi:10.1016/j.neuroimage.2014.01.060

Zalesky A1, Akhlaghi H, Corben LA, Bradshaw JL, Delatycki MB, Storey E, Georgiou-Karistianis N, Egan GF. Cerebello-cerebral connectivity deficits in Friedreich ataxia. *Brain Struct Funct*. 2014 May;219(3):969-81. doi: 10.1007/s00429-013-0547-1. Epub 2013 Apr 7.

Zühlke CH, Dalski A, Habeck M, Straube K, Hedrich K, Hoeltzenbein M, Konstanzer A, Hellenbroich Y, Schwinger E. Extension of the mutation spectrum in Friedreich's ataxia: detection of an exon deletion and novel missense mutations. *Eur J Hum Genet*. 2004 Nov;12(11):979-82.

Figures of chapter 1

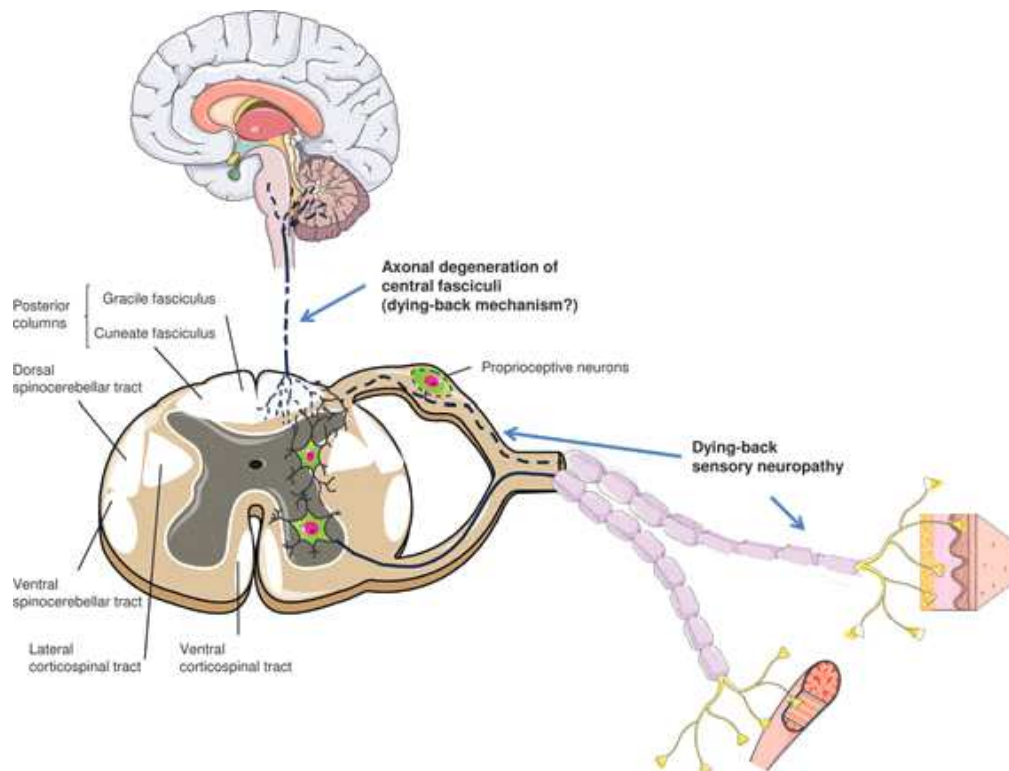


Figure 1: Schematic representation of the central and peripheral nervous system involvement in FRDA (Gonzales-Cabo and Palau, 2013).

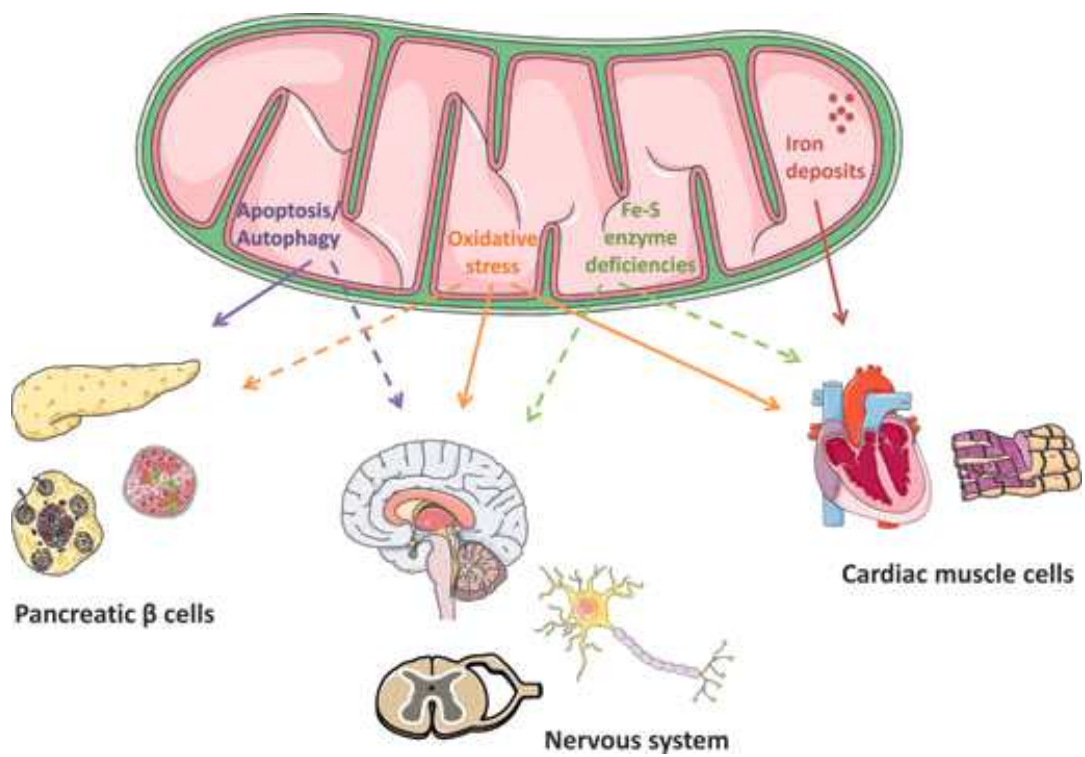


Figure 2: Schematic representation of pathological mechanisms of damage and the corresponding organ damage (Gonzales-Cabo and Palau, 2013).

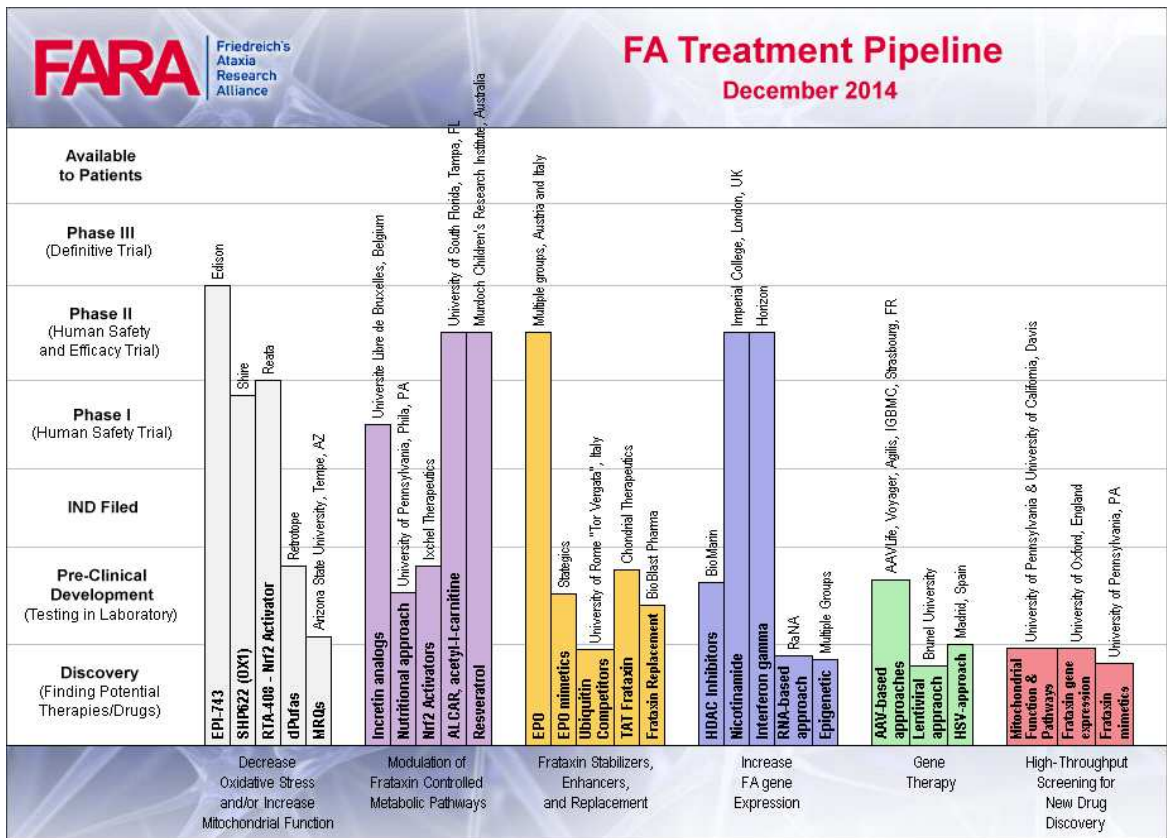
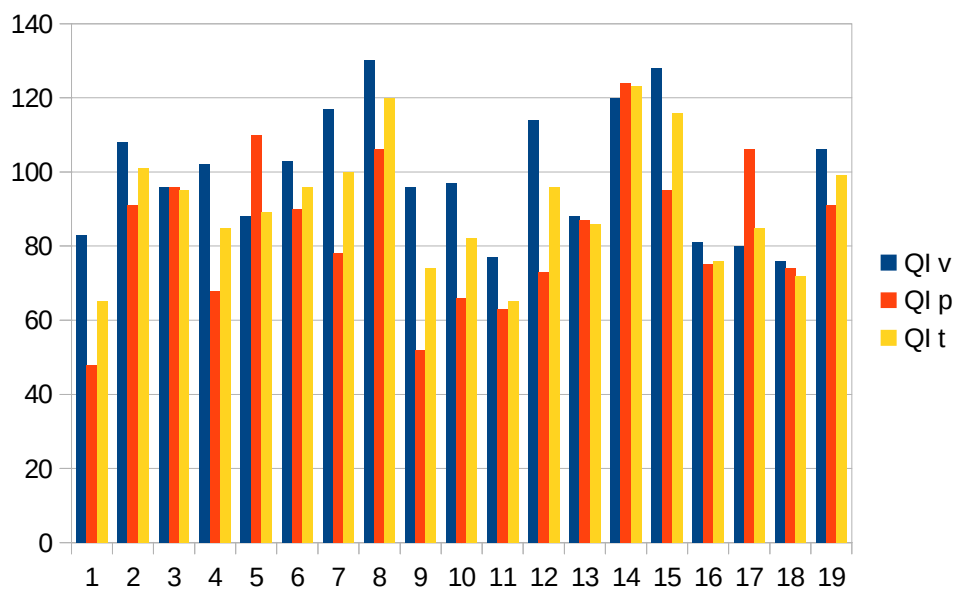


Figure 3 FRDA treatment pipeline. (<http://www.curefa.org/pipeline.html>).

Figures chapter 2.

Figure 2.1. IQ distribution in the FRDA cohort.



Tables chapter 2.

Table 2.1: participants clinical and genetic features.

Legend: NA: non applicable, GI: Gastrointestinal, NY: nystagmus, DTR: deep tendon reflexes (- absent, + present, ++ brisk), DM: diabetes mellitus (years after onset), W-d-a: Wheelchair dependency age, Heart involvement: (+ hypertrophy), R: Right, L: left, AFO: ankle foot orthosis, V ventricle.

Table 2.2. (Continues)

Patient's code	Presenting Symptoms	Babinski	DTR	NY	6MWT (m)	W-d-age	Aid	Skeletal	DM	Heart	Respiratory (+)	GI	Other	Drugs
P.12.c	Tendency to fall	+	+ + (clonus)	-	NA	12	Wheelchair, AFO	Pes cavus, Hammer toes, Hump, Scoliosis	+ (14)	+		Dysphagia,	R LL pain	Idebeneone, Baclofen, Sitagliptin, Niacin,
P.13.b	Gait clumsiness	+	-	+	NA	11	Wheelchair, Orthopedic corset	Pes cavus, Kyphosis, Lordosis		+	+ (restrictive)	Dysphagia,	Arthrodesis	Idebeneone, Calcitonin, Calcitriol
P.14.c	Ataxia	+	-	-	NA	NA	Wheelchair, Foot plantar	Pes cavus, Mild scoliosis, Kyphosis, Lordosis				Dysphagia, Bowel incontinence	Acne vulgaris (face, trunk), D4-D9 hernia	
P.15.c	Scoliosis	+	++	+	51(walking aid)	NA	Walking aid	Scoliosis		+		Dysphagia,	Spastic-Ataxia, Spina Anomaly, Spina Anomaly hearing loss, Spina Anomaly, P. Tonsillectomy	Idebeneone, Tizandine, Vanflaxins
P.16.b	Ataxia	+	-	-	NA	49	Wheelchair	Pes cavus, Scoliosis, Kyphosis			Dyspnea	Dysphagia, Stomatitis, Dyspepsia	Rheumatoid Arthritis, Autoimmune thyroiditis, Mood swings, anemia	Idebeneone, Toxophenol, Oxybutrin, Acetylsalicylic acid
P.17.b	Scoliosis	-	-	+	NA	34	Wheelchair	Pes cavus, Hammer toes, Kypho-scoliosis		Arythmias		Dysphagia,	Rheumatoid Arthritis, Autoimmune thyroiditis, Mood swings, anemia	Idebeneone, Methotrexate, Omeprazole, Folic Acid, Thiamine, Cholecalciferol, Acetylsalicylic acid
P.18.c	Ataxia	+	-	-	NA	25	Wheelchair	Pes cavus, Moderate scoliosis		+	Bronchial asthma	Dysphagia,	Hypothyroidism, Hypoaacusis	Idebeneone, Amitriptyline, Levothyroxine, Terfenadine, Acetylsalicylic acid,
P.19.c	Ataxia, Pes Scoliosis	+	-	-	NA	NA	AFO, Foot plantar, Orthopedic corset	Pes cavus, Scoliosis, LL heterometry		+ (Septal, V)		Dysphagia,	Folliculitis (trunk), Acne vulgaris, Dermatitis	Idebeneone, Toxophenol
P.20.c	Cardiac hypertrophy	+	-	+	NA	18	Wheelchair	Scoliosis		+ (Septal, Apical, LV)	Ab ingestis Pneumonia	Dysphagia, Inadequate consistency		
P.21.c	Clumsiness	-	-	+	126	NA	Foot plantar	Pes cavus, Scoliosis, Hump				Dysphagia,		Idebeneone

Table 2.3 Ataxia rating scales scores.

Table 2.3

Clinical scale measurements			
	mean (SD)	median (range)	mode
SARA	21.4 (7.8)	23 (8-32)	8
ICARS posture	25.9 (9.3)	31 (8-34)	33
ICARS kin func	22.3 (9.2)	24 (9-43)	14
ICARS speech	2.5 (1.2)	2 (1-5)	2
ICARS oculomot	2.2 (1.4)	2 (0-5)	3
FARS stage	4 (1.3)	5 (2-6)	5
FARS ADL	17.3 (7.3)	17.5 (3-32.5)	17,5
FARS kin func	23 (8.6)	25 (8-34.5)	25
FARS stab	22 (5.8)	24 (10.5-28)	27
FARS NE	62.7 (18.4)	69 (31.33-92.5)	69,5
9-HPT R	130 (135.6)	80.2 (43.4-613.1)	43,38
9-HPT L	138.2 (153.1)	90 (40.4-719)	40,42
FIM (n=17)	99.6 (21.4)	103 (53-126)	103

TABLES CHAPTER 3

Table 3.1 Significant differences of FA.

White Matter bundle	Group(p)
Middle cerebellar peduncle	0,000754
Body of corpus callosum	0,000074
Splenium of corpus callosum	0,000011
Corticospinal tract R	0,000094
Corticospinal tract L	0,000047
Medial lemniscus R	0,001008
Medial lemniscus L	0,00002
Inferior cerebellar peduncle R	0
Inferior cerebellar peduncle L	0
Superior cerebellar peduncle R	0
Superior cerebellar peduncle L	0
Cerebral peduncle R	0,00027
Cerebral peduncle L	0,000726
Posterior thalamic radiation (include optic radiation) R	0,000267
Posterior thalamic radiation (include optic radiation) L	0,000022
Sagittal stratum (include inferior longitudinal fasciculus and inferior fronto-occipital fasciculus) L	0,00044
Tapetum R	0,00021
Tapetum L	0,000001

L: left, R: right.

Table 3.2. Significant differences of MD.

White Matter Bundle	Group(p)
Middle cerebellar peduncle	0.000083
Body of corpus callosum	0.000061
Splenium of corpus callosum	0.000001

Medial lemniscus R	0.000099
Medial lemniscus L	0.000028
Inferior cerebellar peduncle R	0.000007
Inferior cerebellar peduncle L	0.000003
Superior cerebellar peduncle R	0.000000
Superior cerebellar peduncle L	0.000000
Posterior thalamic radiation (include optic radiation) R	0.000045
Posterior thalamic radiation (include optic radiation) L	0.000023
Tapetum R	0.000004
Tapetum L	0.000001

L: left, R: right.

FIGURES CHAPTER 3

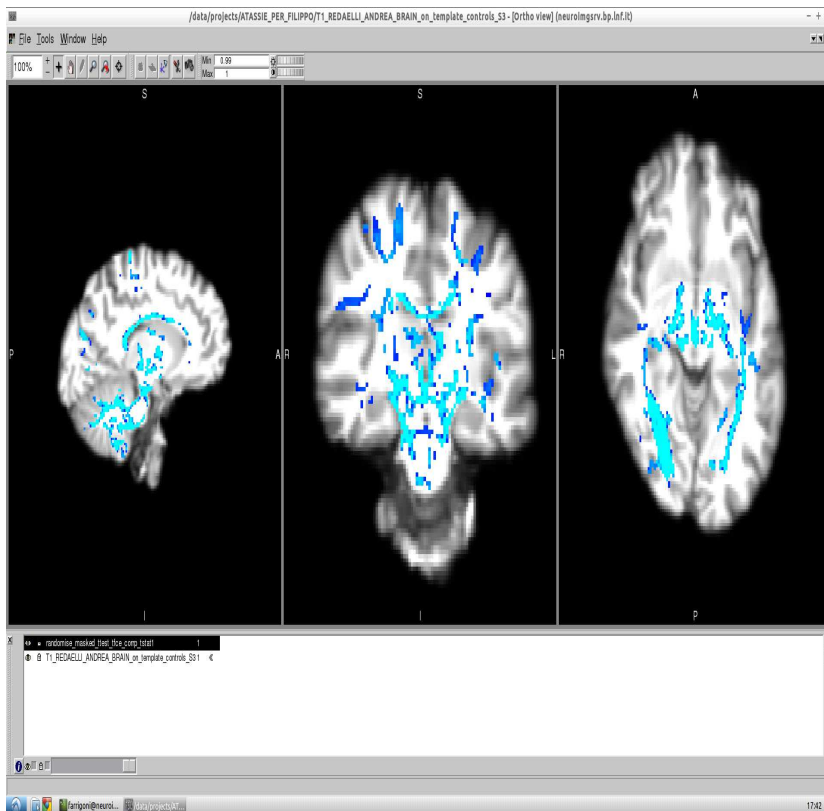


Figure 3.1. Optic radiations.

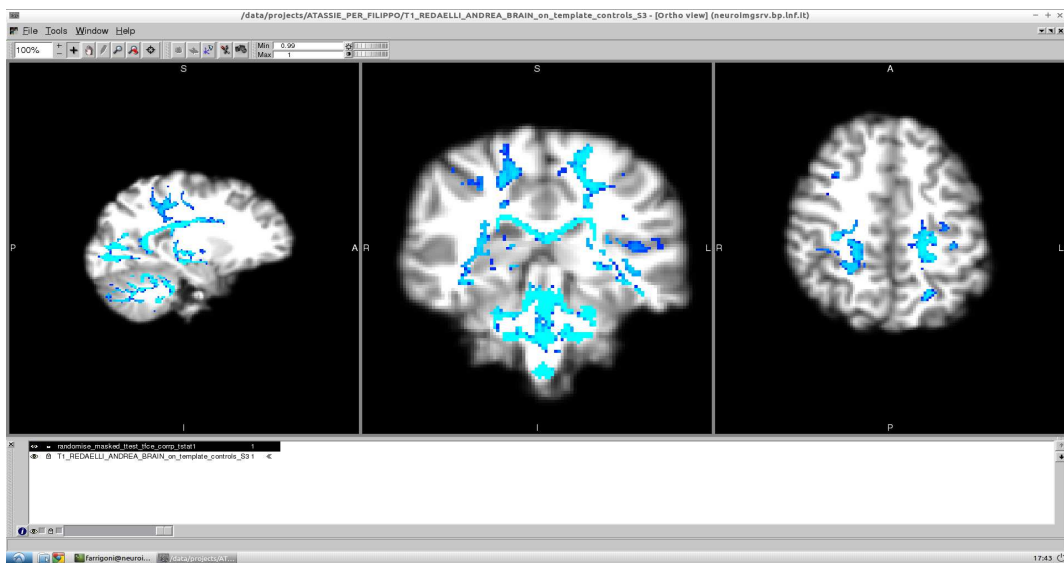


Figure 3.2. Corticospinal tracts.

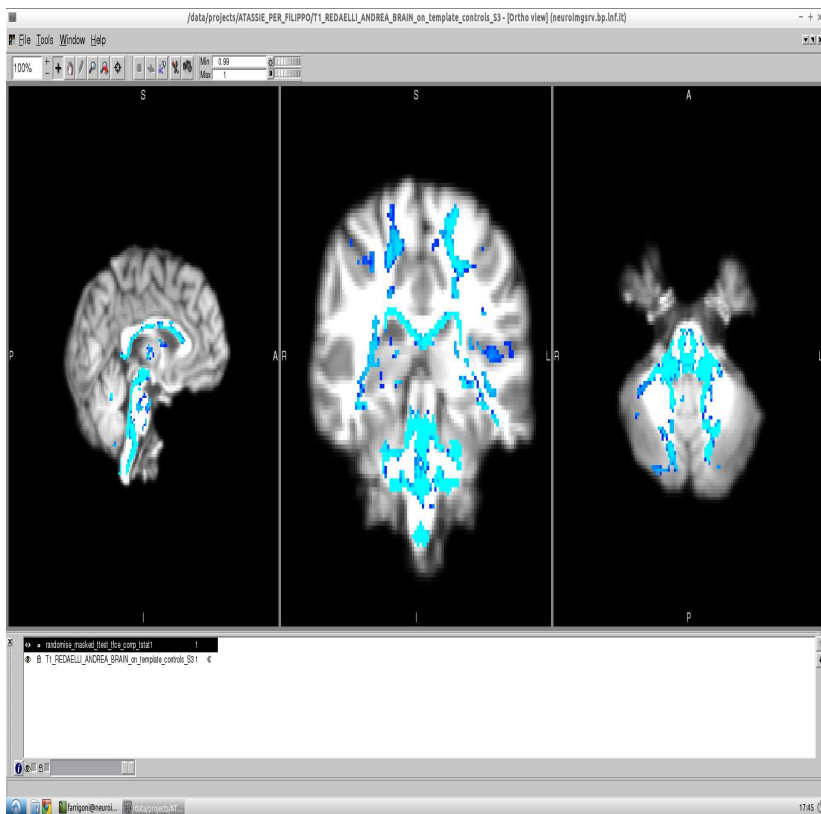


Figure 3.3 Corticospinal tracts.

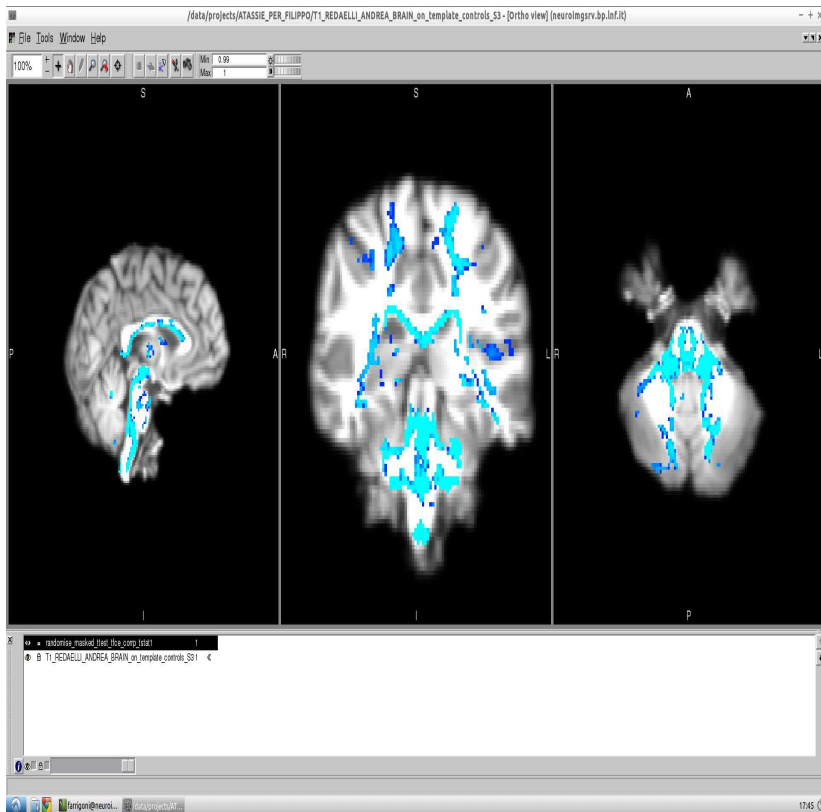


Figure 3.4. Median cerebellar peduncles.

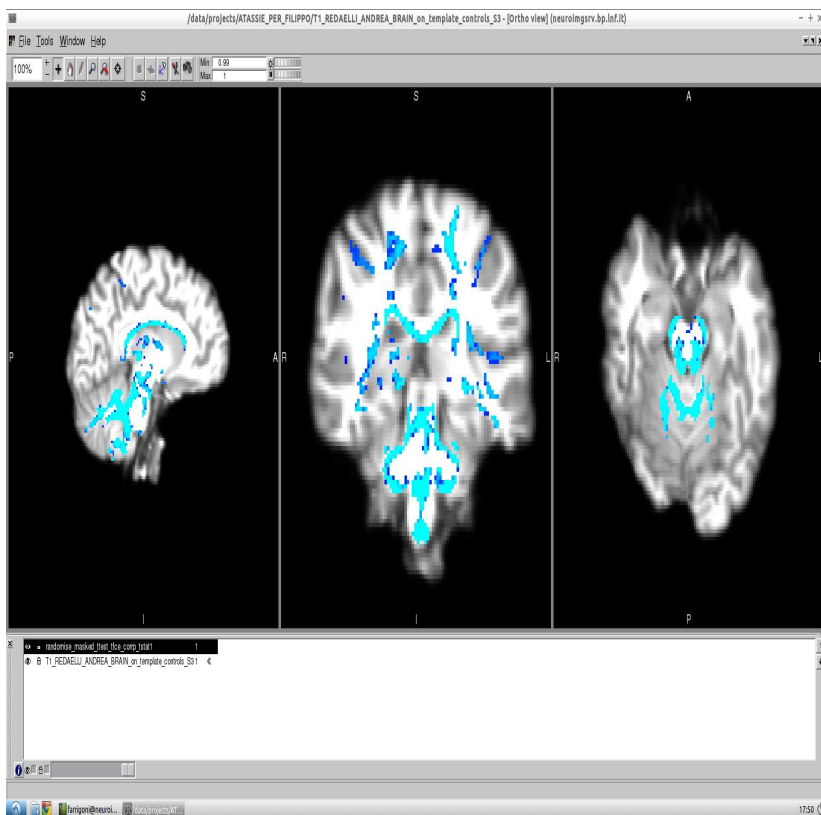


Figure 3.5. Superior cerebellar peduncles

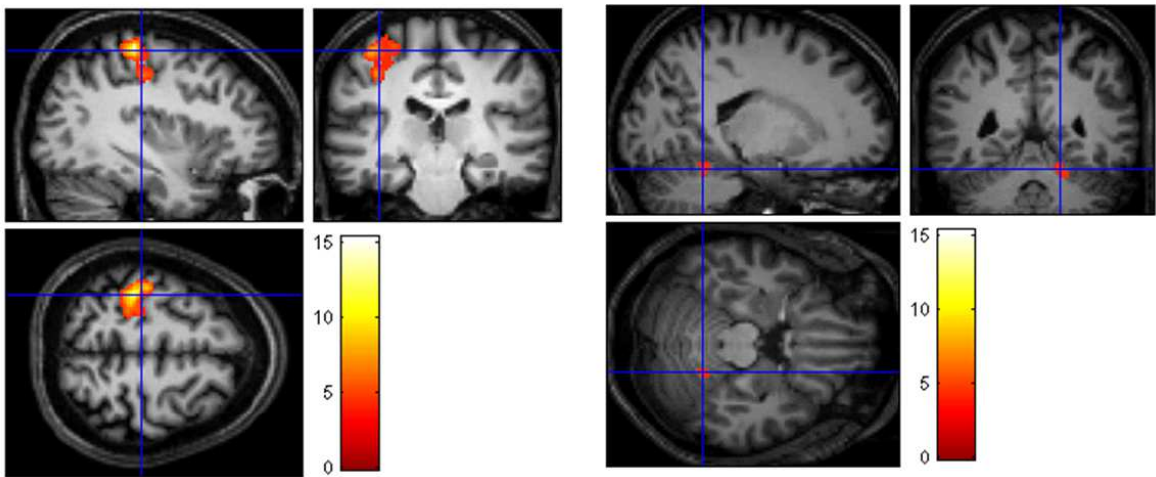


Figure 3.6. The figure demonstrates activation of contralateral motor cortical and ipsilateral cerebellar areas activated during Right hand finger tapping task in FRDA patients.

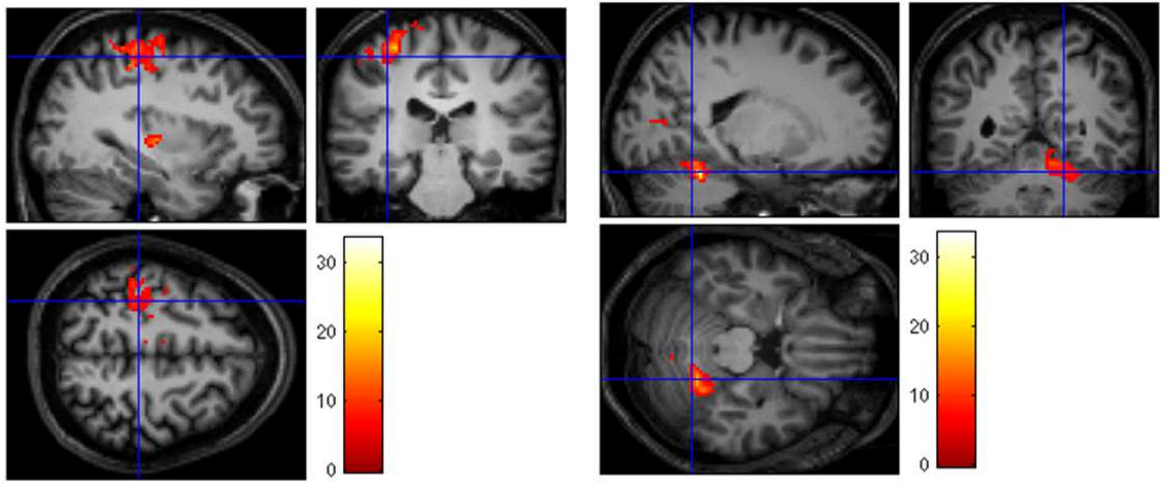


Figure 3.7. The figure demonstrates activation of controlateral motor cortical and omolateral cerebellar areas activated during Right hand finger tapping task in healthy controls.

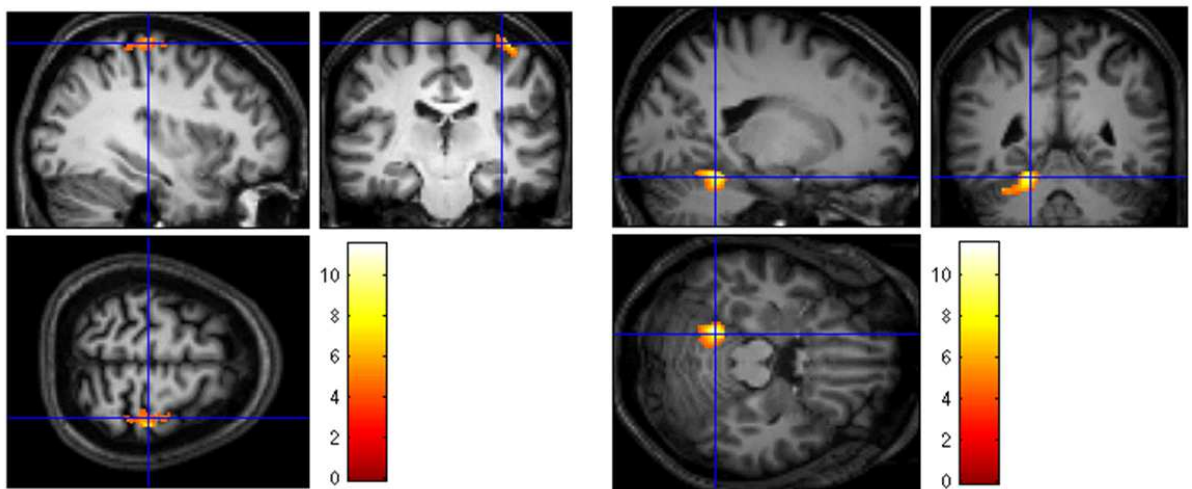


Figure 3.8. The figure demonstrates activation of controlateral motor cortical and omolateral cerebellar areas activated during Left hand finger tapping task in FRDA patients.

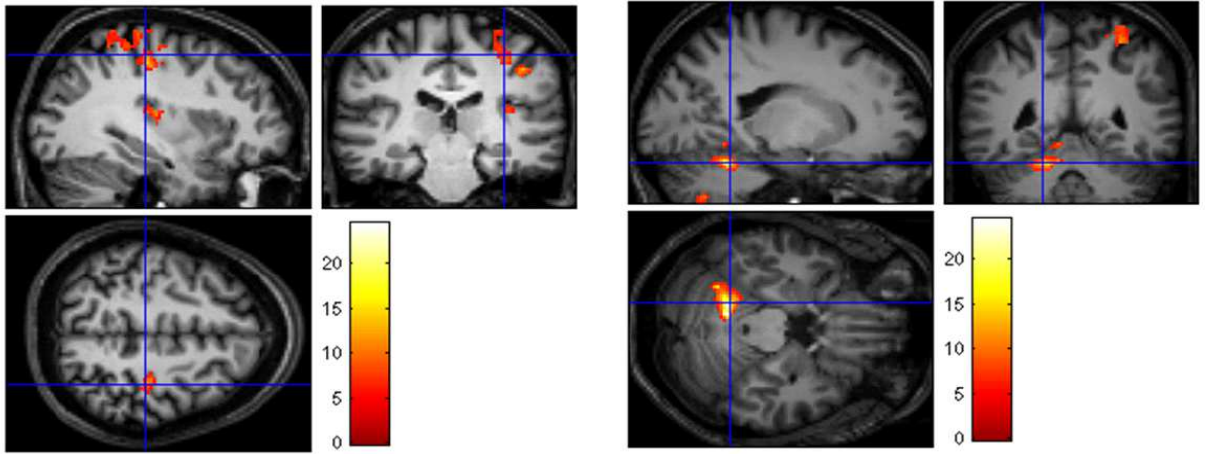


Figure 3.9. The figure demonstrates activation of contralateral motor cortical and ipsilateral cerebellar areas activated during Left hand finger tapping task in healthy controls.

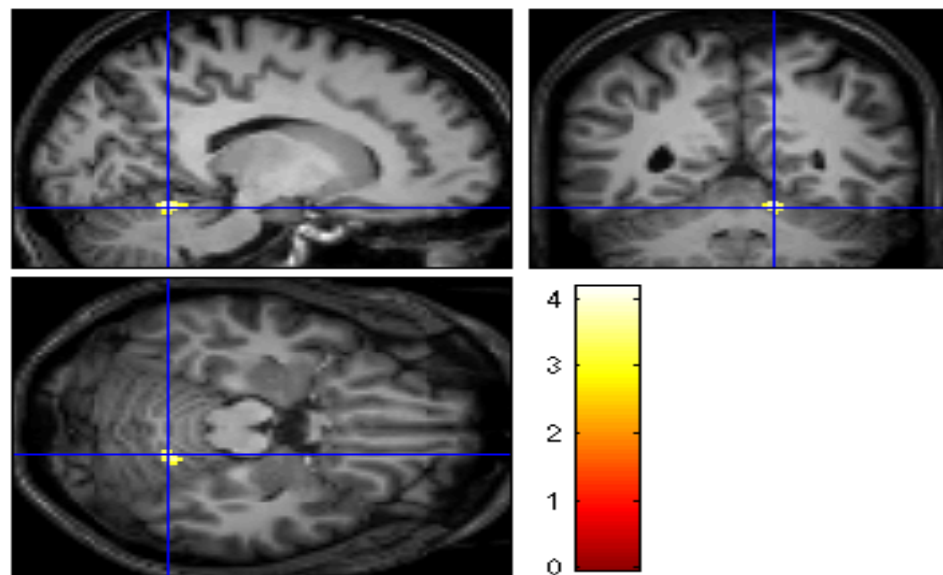
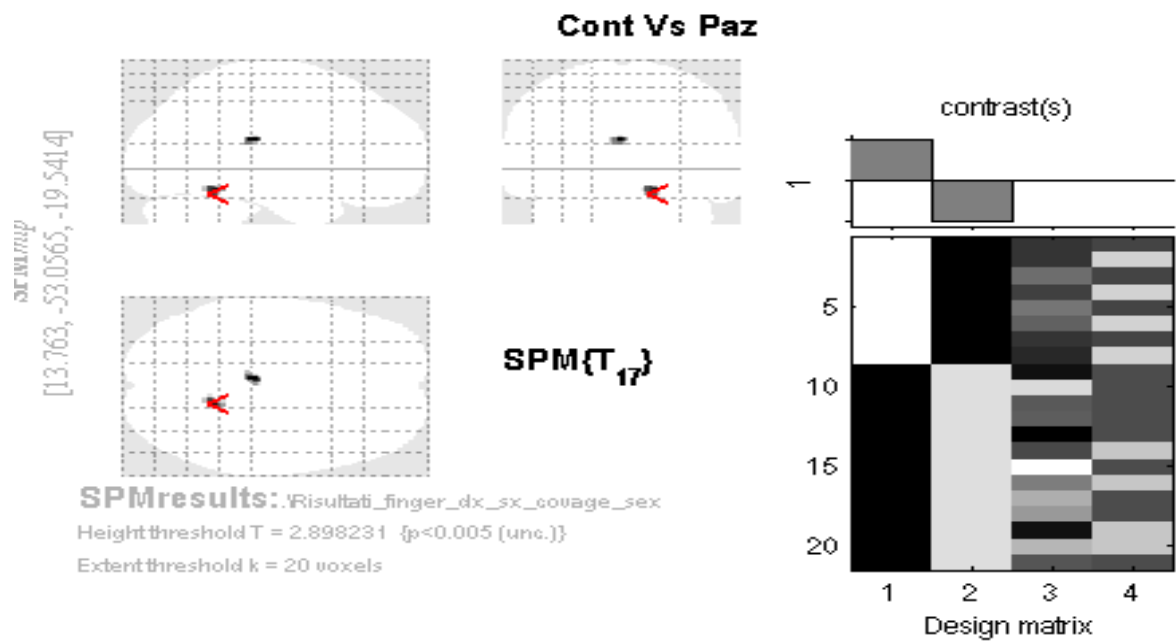


Figure 3.10. Right hand finger tapping task. The figure demonstrates areas more active in healthy controls compared to the FRDA patients.

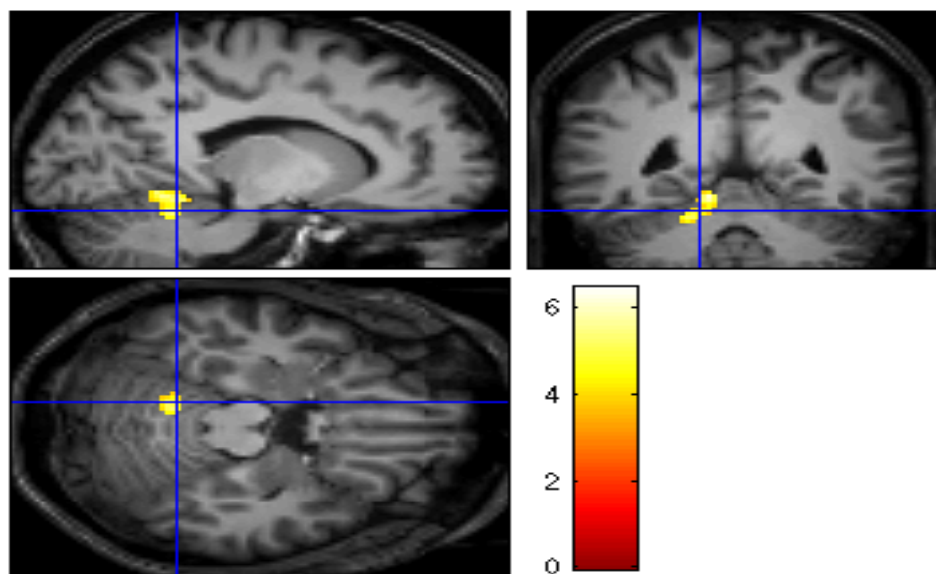
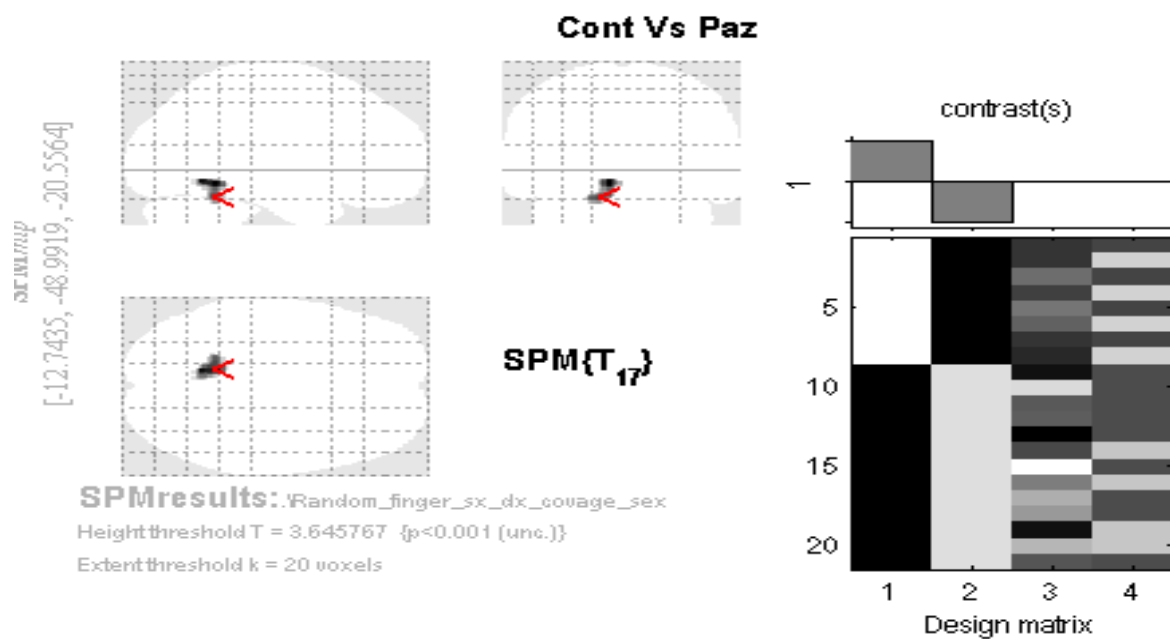


Figure 3.11. Left hand finger tapping task. The figure demonstrates areas more active in healthy controls compared to the FRDA patients.