

Università degli Studi di Padova

Padua Research Archive - Institutional Repository

Leukocytoclastic vasculitis associated with multifocal sensory neuropathy responsive to intravenous immunoglobulins: a case report

Original Citation:

Availability:

This version is available at: 11577/3410258 since: 2021-12-29T20:16:47Z

Publisher:

MATTIOLI 1885

Published version:

DOI: 10.36141/svdlid.v38i3.10883

Terms of use:

Open Access

This article is made available under terms and conditions applicable to Open Access Guidelines, as described at <http://www.unipd.it/download/file/fid/55401> (Italian only)

(Article begins on next page)

LEUKOCYTOCLASTIC VASCULITIS ASSOCIATED WITH MULTIFOCAL SENSORY NEUROPATHY RESPONSIVE TO INTRAVENOUS IMMUNOGLOBULINS: A CASE REPORT

Martina Ferranti¹, Elena Cama¹, Mario Cacciavillani², Franco Schiavon³, Mara Felicetti³, Chiara Briani⁴, Mauro Alaibac

¹Unit of Dermatology, Department of Medicine DIMED, University of Padua, Padua, Italy ²CEMES, Padua, Italy; ³Unit of Rheumatology, Department of Medicine DIMED, University of Padua, Padua, Italy; ⁴ Unit of Neurology, Department of Neurosciences, University of Padua, Padua, Italy

ABSTRACT. Leukocytoclastic vasculitis (LCV) is a common form of small-vessel vasculitis, which commonly presents as palpable purpura or petechiae, caused by deposition of circulating immune complexes on vessels walls that attracts granulocytes which damage the vascular endothelium and leading to erythrocytes extravasation. The skin is the most commonly involved organ, but also renal, gastrointestinal, pulmonary, cardiovascular and neurological systems may be affected. Skin lesions may be the initial signs of systemic vasculitis. Systemic symptoms may be present, such as fever, myalgia, abdominal pain and arthralgia. The presence of neuropathy/mononeuritis multiplex is expression of severe vasculitic involvement. Herein, we describe the case of a patient with leukocytoclastic vasculitis associated to sensitive neuropathy, responsive to intravenous immunoglobulins (IVIg) therapy, after the failure of classic systemic treatments.

KEY WORDS: Leukocytoclastic vasculitis, Sensory neuropathy, Intravenous immunoglobulins.

INTRODUCTION

Leukocytoclastic vasculitis (LCV) is a common form of small-vessel vasculitis, which commonly presents as palpable purpura or petechiae. The term leukocytoclastic is based on the histological characteristic of leukocytoclastic or apoptotic degeneration of granulocytic cell nucleus. It is caused by deposition of circulating immune complexes on vessels walls that attracts granulocytes which damage the vascular

endothelium and leading to erythrocytes extravasation (1-3). The etiology of LCV is unknown in half of the cases. Based on current data, LCV may be associated with infections (HBV, HCV, HIV), inflammatory diseases, drugs intake, neoplasms, or could be idiopathic. LCV traditionally manifests clinically as either single or recurrent episodes of palpable purpura, primarily affecting the lower limbs. Involvement of frictional and pressure areas is frequently observed. Purpuric lesions are frequently symptomatic, with tenderness, burning, stinging and/or pruritus. Each disease flare traditionally resolves over 3-4 weeks and frequently leaves ecchymotic stains or hyperpigmentation. The extent of disease can be aggravated by exercises, sun exposure, extreme temperatures and prolonged stasis (4).

The skin is the most commonly involved organ, but also renal, gastrointestinal, pulmonary,

Received: 1 November 2020

Accepted after revision: 14 May 2021

Correspondence: Mauro Alaibac, MD, PhD, Unit of Dermatology, University of Padua, Via Gallucci 4, 35128 Padua, Italy
Tel: + 39 0498212901; fax + 0498218891,
E-mail: mauro.alaibac@unipd.it

cardiovascular and neurological systems may be affected. Skin lesions may be the initial signs of systemic vasculitis. Systemic symptoms may be present, such as fever, myalgia, abdominal pain and arthralgia. The presence of neuropathy/mononeuritis multiplex is expression of a severe systemic vasculitic involvement (5-7).

CASE REPORT

A 35-year-old woman came to our attention for the occurrence of small reddish lesions on the back of the feet, then extended to the ankles and proximally to the knees. She reported that the lesions had appeared four months before and that she had been treated with topical steroids without benefit. The patient wasn't taking any medication or recreational drug.

Physical examination revealed palpable petechial and purpuric lesions on the legs and feet. In the right pretibial region there were confluent lesions in necrotic areas (figure 1).

Close to the knees there were also erythematous macules. The right leg was slightly edematous. Patient's vital signs were normal and she had no fever.

Laboratory tests showed normal hemoglobin levels (12,5 mg/dL, normal values: 12-15,5 mg/dL), a normal platelets count ($250 \times 10^9/L$, normal values $150-400 \times 10^9/L$), but a neutrophilic leukocytosis with white blood cells $11,42 \times 10^9/L$ (normal values: $4,5-11 \times 10^9/L$) and neutrophils $10,9 \times 10^9/L$ (normal values: $2-8 \times 10^9/L$), and serum C reactive protein (PCR) was 19 mg/L (normal values: $< 8\text{mg/L}$). Hepatorenal function tests were normal. A low anti-nuclear antibodies (ANA) titer was observed (1:80) with a speckled nuclear pattern (IFI su HEp-2), ENA screen, rheumatoid factors, cryoglobulins and anti-neutrophil cytoplasmic antibodies (ANCA) were negative. Complements levels were within the normal ranges. Serological markers for hepatitis B virus, hepatitis C virus, Epstein-Barr virus, cytomegalovirus and HIV were negative. A chest X-rays was executed and resulted negative. A lower limbs echocolor doppler of the veins was performed but showed no alterations.

A skin punch-biopsy was performed on one of the most recent purpuric lesions of the right lower limb. The histologic findings revealed a leukocytoclastic vasculitis with a perivascular inflammatory infiltrate (mainly of polymorphonuclear leucocytes) and fragments of granulocytes' nucleus (leukocytoclasia).

There were also endoluminal thrombosis and thickening of the blood vessels wall (figure 2).

A treatment with prednisone 25 mg/day and dapsone 50 mg/day was started. Nevertheless, the patient gradually worsened with necrotic hemorrhagic evolution of the lesions of lower limbs (figure 3) and new onset of erythematous macules on the wrists and forearms.

The patient also reported the onset of hypoesthesia of the first three digits of the left hand associated

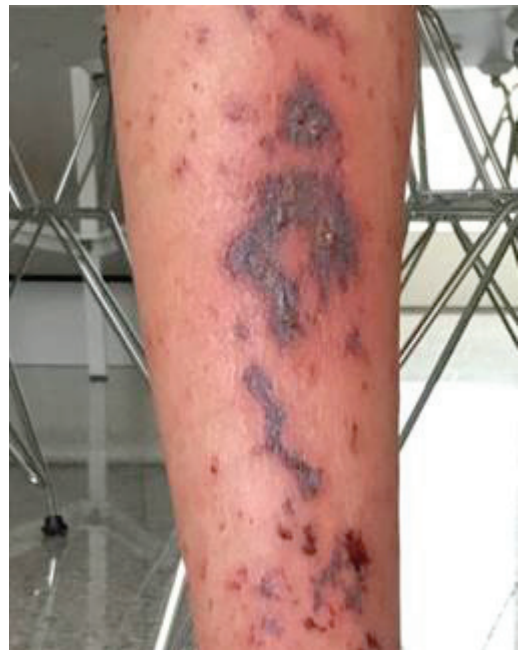

Figure 1. Necrotic lesions on the right pretibial region.

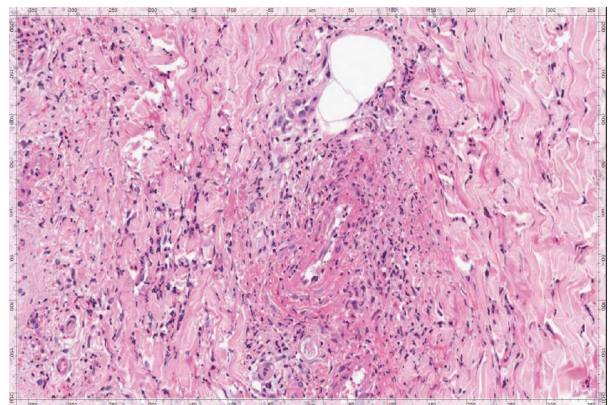


Figure 2. Histologic findings: leukocytoclastic vasculitis with perivascular inflammatory infiltrate, endoluminal thrombosis and thickening of the blood vessels wall.

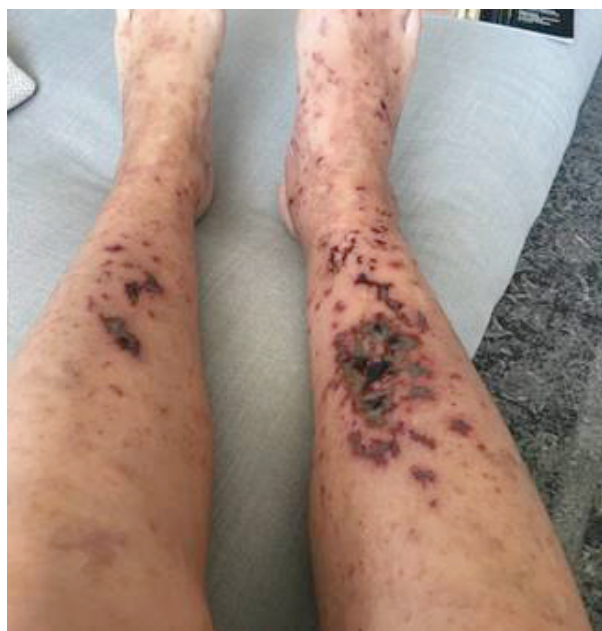

Figure 3. Necrotic hemorrhagic evolution of the lesions of lower limbs.

with stiffness and tremor. She also reported hypoesthesia on the lateral side of the left ankle and foot, as well as widespread arthromyalgias. Thus, electromyography and electroneurography (EMG/ENG) of the upper and lower limbs was performed, but resulted negative.

After a rheumatologic evaluation, dapsone 50 mg/day was stopped and azathioprine 100 mg/day was started.

Two months later, the patient was admitted to the hospital for an important worsening of the skin conditions. The cutaneous examination of lower limbs showed widespread purpuric lesions and palpable petechiae, associated with exuding necrotic lesions on the right pretibial region. A slight edema of lower limbs and fovea sign were present. On the wrists and forearms there were isolated erythematous macules. Moreover, hypoesthesia and arthralgia of upper and lower limbs were still present.

Another EMG/ENG of the upper and lower limbs was performed, and showed signs of sensory axonal multineuropathy, with mild damage of the distal sensory fibers of the left median nerve and severe damage of the sensitive fibers of the left sural nerve. Furthermore, high-resolution ultrasound revealed the increased left sural nerve cross sectional area (CSA).

During the hospitalization, 25 mg/day of prednisone, 100 mg/day of azathioprine and a single infusion of 2 g/kg (for a total of 120 g) of IVIg distributed over two days were administrated to the patient, with a dramatic improvement of the skin lesions (figure 4).

After discharge, the patient underwent other six infusions of IVIg (2 g/kg over two days once a month for six months) associated with prednisone 25 mg/day, gradually tapered, and azathioprine 100 mg/day, with a progressive clinical improvement.

Three months after the last IVIg infusion, the patient was asymptomatic and neurological examination was negative, so oral prednisone was stopped and but azathioprine 100 mg/day was maintained.

Actually, one year after the hospitalization, the patient continues the therapy with azathioprine 100 mg/day, but her clinical conditions are in stable remission, with occasional flare-ups on the skin, but no more signs of sensory neuropathy.

DISCUSSION

The treatment of LCV depends on two major factors: the etiology and the extent of disease, especially in the cases of a systemic involvement. When LCV is the manifestation of a systemic vasculitis process, the

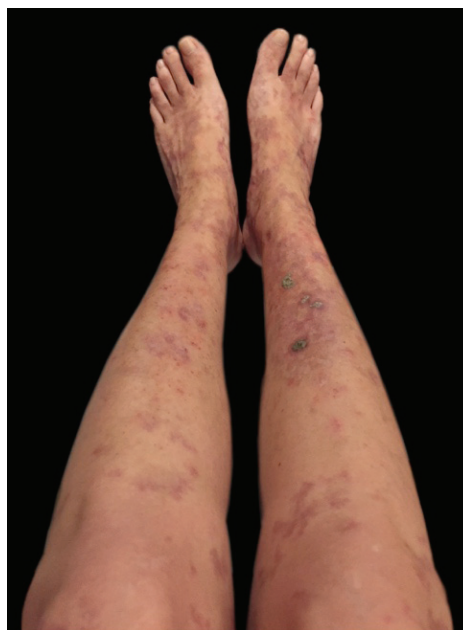

Figure 4. Improvement of the skin lesions after a single infusion of IVIg (2 g/kg).

treatment generally requires a combination of steroids and immunosuppressive drugs. Systemic prednisone is the most widely used treatment. It may be very effective to treat acute or single episodic LCV, but it is not recommended for recurrent or chronic LCV. Dapsone is primarily an anti-inflammatory medication with a predominantly antineutrophilic effect that is frequently used in various vasculitic diseases and neutrophilic dermatoses. Azathioprine has been shown to be effective in preventing clinical recurrence, either as monotherapy or associated with a low-dose of prednisone (8-10). IVIg administration has shown to be effective in isolated severe cases with persistent ulcerations, suspected comorbid infection, or common variable immune deficiency, when added to traditional therapies.

IVIg is a purified product of normal polyspecific IgG obtained from the pooled blood of several healthy donors and it has been used for over 20 years to treat a wide variety of dermatologic autoimmune disorders, such as pemphigus vulgaris and foliaceus, bullous and mucous membrane pemphigoid, epidermolysis bullosa acquisita, dermatomyositis, systemic vasculitis, systemic lupus erythematosus and scleromyxedema. IVIg is usually administered at a dosage of 2g/kg bodyweight distributed over 2-5 days every 4 weeks (11).

Its mechanism of action is still unclear, but several hypothesis have been proposed. Its immunomodulatory effect depends on both the Fc portion and the variable regions of infused antibodies (Fab), which are able of competitive inhibition of the reticuloendothelial system, neutralisation of pathogenic antibodies, anaphylotoxins and cytokines, complement scavenging, saturation of protective neonatal Fc receptors (FcRn), inhibition of B-cell functions, inhibition of Th17 differentiation and functions, expansion of regulatory T-cells and upregulation of inhibitory FC γ RIIB or downregulation of activating FC γ RIIB (12).

IVIg has been used successfully as a single agent and also as an adjuvant treatment in several autoimmune diseases. The first documented application of IVIg was reported in 1981 in a child with an idiopathic thrombocytopenic purpura (13).

Later, IVIg was used to successfully treat some cases of Kawasaki disease (14,15), of livedoid vasculitis (16, 17), and in 1993 Dalakas et al. reported the first randomized controlled clinical trial of IVIg in dermatomyositis (18).

Recently, clinical guidelines for the use of IVIg in dermatology, first published in the European Dermatology Forum in 2009, were updated (19).

Regarding systemic vasculitis, data on IVIg in ANCA-associated vasculitis and in other several cases of different vasculitis reported beneficial effects of IVIg (20, 21).

Actually, European guidelines promote the use of IVIg in Kawasaki's disease as a first-line treatment. In all the other systemic vasculitis the use of IVIg is intended for severe and recalcitrant cases, unresponsive to the classical therapies or if other therapeutic options are contraindicated (22).

The use of IVIg may be associated with mild systemic side-effects such as headache, backache, myalgia, chills, fever, nausea or vomiting, wheezing and, less often, changes in blood pressure and tachycardia. Less common side-effects include aseptic meningitis, anaphylactic reactions, renal failure and haemolytic anaemia (10-12).

In our patient, the use of IVIg healed a severe form of LCV, after the failure of the classical treatments.

In conclusion, we suggest to begin early IVIg therapy in patients with extensive disease associated to neurologic involvement with the aim to prevent permanent sequelae.

Conflicts of interest: Each author declares that he or she has no commercial associations (e.g. consultancies, stock ownership, equity interest, patent/licensing arrangement etc.) that might pose a conflict of interest in connection with the submitted article.

REFERENCES

1. Watts RA, Robson J. Introduction, epidemiology and classification of vasculitis. *Best Pract Res Clin Rheumatol* 2018;32(1):3-20. doi: 10.1016/j.berh.2018.10.003.
2. Koutkia P, Mylonakis E, Rounds S, Erickson A. Leucocytoclastic vasculitis: an update for the clinician. *Scand J Rheumatol* 2001;30(6):315-22. doi: 10.1080/030097401317148499.
3. Aounallah A, Arouss A, Ghariani N, Saidi W, Sriha B, Denguezli M, et al. Vascularites cutanées leucocytoclastiques: à propos de 85 cas. *Pan Afr Med J* 2017;26:138. doi:10.11604/pamj.2017.26.138.9721.
4. Elefante E, Bond M, Monti S, Lepri G, Cavallaro E, Felicetti M, et al. One year in review 2018: systemic vasculitis. *Clin Exp Rheumatol* 2018;36 Suppl 111(2):12-32. PMID: 29799395.
5. Marzano AV, Vezzoli P, Berti E. Skin involvement in cutaneous and systemic vasculitis. *Autoimmun Rev* 2013;12(4):467-476. doi:10.1016/j.autrev.2012.08.005.
6. Seo JH, Ryan HF, Claussen GC, Thomas TD, Oh SJ. Sensory neuropathy in vasculitis: a clinical, pathologic, and electrophysiologic study. *Neurology* 2004;63(5):874-878. doi:10.1212/01.wnl.0000137017.45065.3e.

7. Younger DS, Carlson A. Dermatologic Aspects of Systemic Vasculitis. *Neurol Clin* 2019;37(2):465-473. doi:10.1016/j.ncl.2019.01.017.
8. Sunderkötter C, Bonsmann G, Sindrilaru A, Luger T. Management of leukocytoclastic vasculitis. *J Dermatolog Treat* 2005;16(4):193-206. doi:10.1080/09546630500277971
9. Younger DS. Treatment of Vasculitis of the Nervous System. *Neurol Clin* 2019;37(2):399-423. doi:10.1016/j.ncl.2019.01.014.
10. Eleftheriou D, Brogan PA. Therapeutic advances in the treatment of vasculitis. *Pediatr Rheumatol Online J* 2016 Apr 26;14(1):26. doi: 10.1186/s12969-016-0082-8.
11. Jordan SC, Toyoda M. Treatment of autoimmune diseases and systemic vasculitis with pooled human intravenous immune globulin. *Clin Exp Immunol* 1994; 97 (Suppl. 1): 31-8.
12. Ballou M. Mechanisms of immune regulation by IVIG. *Curr Opin Allergy Clin Immunol* 2014; 14(6):509-515. doi: 10.1097/ACI.0000000000000116.
13. Imbach P, Barandun S, d'Apuzzo V, Baumgartner C, Hirt A, Morrell A, et al. High-dose intravenous gammaglobulin for idiopathic thrombocytopenic purpura in childhood. *Lancet* 1981;1:1228-1231. doi: 10.1016/S0140-6736(81)92400-4.
14. Furusho K, Kamiya T, Nakano H, Kiyosawa N, Shinomiya K, Hayashidera T, et al. High-dose intravenous gammaglobulin for Kawasaki disease. *Lancet* 1984;2:1055-1558. doi: 10.1016/S0140-6736(84)91504-6.
15. Newburger JW, Takahashi M, Burns JC, Beiser AS, Chung KJ, Duffy CE, et al. The treatment of Kawasaki syndrome with intravenous gamma globulin. *N Engl J Med* 1986; 315:341-347. doi: 10.1056/NEJM1986080731 50601.
16. Amital H, Levy Y, Shoenfeld Y. Use of intravenous immuno- globulin in livedo vasculitis. *Clin Exp Rheumatol* 2000; 18: 404-406.
17. Ravat FE, Evans AV, Russell-Jones R. Response of livedoid vasculitis to intravenous immunoglobulin. *Br J Dermatol* 2002 Jul;147(1):166-916. doi: 10.1046/j.1365-2133.2002.04755.x.
18. Dalakas MC, Illa I, Dambrosia JM, Soueidan SA, Stein DP, Otero C, et al. A controlled trial of high-dose intravenous immune globulin infusions as treatment for dermatomyositis. *N Engl J Med* 1993; 329:1993-2000. doi: 10.1056/NEJM199312303292704
19. Hadaschik E, Eming R, French LE, Girolomoni G, Hertl M, Jolles S, et al. Europäische Leitlinien (S1) für die Verwendung von hoch dosierten intravenösen Immunglobulinen in der Dermatologie [European Guidelines (S1) on the use of high-dose intravenous immunoglobulin in dermatology]. *Hautarzt* 2020 Jul;71(7):542-552. German. doi: 10.1007/s00105-020-04610-6.
20. Jayne DR, Chapel H, Adu D, Misbah S, O'Donoghue D, Scott D, et al. Intravenous immunoglobulin for ANCA-associated systemic vasculitis with persistent disease activity. *QJM* 2000; 93:433-439. doi: 10.1093/qjmed/93. 7.433.
21. Fortin PM, Tejani AM, Bassett K, Musini VM. Intravenous immunoglobulin as adjuvant therapy for Wegener's granulomatosis. *Cochrane Database Syst Rev* 2013; 1:CD007057. doi: 10.1002/14651858.CD007057.pub3.
22. Enk A, Hadaschik E, Eming R, Fierlbeck G, French L, Girolomoni G, et al. European Guidelines (S1) on the use of high-dose intravenous immunoglobulin in dermatology. *J Eur Acad Dermatol Venereol* 2016; 30: 1657-1669. doi.org/10.1111/jdv.13725.