

# Single coronary artery originating from right sinus. Role of MDCT and a review of literature

Valeria Pergola<sup>1</sup>, Giulio Cabrelle<sup>2</sup>, Giulio Barbiero<sup>2</sup>, Carlo Maria Dellino<sup>1</sup>, Elena Reffo<sup>3</sup>, Giovanni Di Salvo<sup>3</sup>, Raffaella Motta<sup>2</sup>

<sup>1</sup>Department of Cardiac, Thoracic and Vascular Sciences and Public Health; <sup>2</sup>Department of Medicine, Institute of Radiology; <sup>3</sup>Department of Women's and Children's Health, University of Padua, Italy

## Abstract

Single coronary artery (SCA) from the right sinus is the rarest coronary anomaly. We describe 2 cases: 1 with SCA type-1RI; 2 with SCA type-2RII-A. Appropriate and successful treatment (CABG in case-1; PTCA in case-2) was chosen relying on accurate morphological description provided by MDCT, in order to recognize all the possible mechanisms of myocardial ischemia.

## Introduction

Coronary artery anomalies (CAA) represent the second most common cause of sudden cardiac death in young competitive

athletes. Patients are usually asymptomatic and, in most of the cases, CAA are incidentally discovered [1]. There are several types of CAA according to their origination and course (e.g., separate ostia of left anterior descending (LAD) and left circumflex (LCX), intrinsic anatomy (e.g., ostial stenosis, atresia, ectasia, hypoplasia), coronary termination (e.g., fistulas) and anomalous collateral vessels. Among them, single coronary artery (SCA) is the rarest, with a prevalence of 0.02-0.06% in the general population [1,2]. As historical note, in one of the two vascular anatomical models in "Sansevero Chapel" in Naples (Italy), an origin of single coronary artery from the right aortic coronary sinus is showed in detail [3].

In the current, ECG-gated multi-detector CT (MDCT) is becoming a widespread technique for the detection of CAA, with an increasingly solid evidence-based role [4]. Its multi-planar capability allows a precise visualization of the origin, course, and termination of vessels.

In patients with coronary artery disease, the detection of coronary anomalies, and above all SCA, may affect treatment (e.g., medical therapy over percutaneous intervention) even if no recent treatment guidelines or follow-up recommendations exist at the moment [5,6].

We report two cases of right-SCA confirmed by MDCT after development of ischemic cardiopathy. Treatment was different, with good result in both of them: percutaneous revascularization (PTCA) vs coronary artery bypass graft (CABG)

## Case Series

CT was performed with axial imaging using a second-generation, 320×0.5-mm detector row CT unit (Aquilion ONE ViSION Edition; Toshiba Medical Systems, Otawara, Japan). Gantry rotation time: 350 msec. Automatic exposure control (SURE bExposure 3D, Toshiba Medical Systems, SD 150 for non-contrast and SD 110 for contrast-enhanced images); 512 × 512 matrix. Thickness sections 0.5 mm with 0.25-mm increments using kernel FC03. Iterative reconstruction AIDR3D standard (Toshiba Medical Systems). Intravenous contrast: 50-80 ml Iomeron® 400 mg/ml (Bracco Imaging Italy s.r.l., Milan Italy) with 5 ml/s flow. Intravenous beta blocker (Propranolol) was used to reduce heart rate (target range: 50-60 b.p.m.). Data were transferred to an external workstation (Vitrea2 FX version 6.3, Vital Images, Plymouth, MN, USA) providing multi-planar reformation (MPR), volume rendering technique (VRT) and cine view reconstructions.

Correspondence: Giulio Cabrelle MD, Institute of Radiology, Department of Medicine, Padua University Hospital, Via Nicolò Giustiniani 2, 35128 Padua, Italy.  
Mobile: +39.3494.361936.  
E-mail: giulio.cabrelle@gmail.com

Key words: ECG-gated multidetector computed tomography (MDCT); coronary artery anomaly; single coronary artery; coronary stenosis; coronary artery bypass graft.

Contributions: GB, GC, study concept; GC, CMD, data acquisition, analysis and/or interpretation; GB, VP, RM, ER, GDS, manuscript drafting and reviewing. All the authors have read and approved the final version of the manuscript and agreed to be accountable for all aspects of the work.

Conflict of interest: The authors declare that they have no competing interests, and all authors confirm accuracy.

Conference presentation: These cases were orally presented at the congress ICNC-CT in May 2021 in the section "Interesting clinical cases, session one".

Received for publication: 5 May 2021.

Accepted for publication: 9 September 2021.

©Copyright: the Author(s), 2021

Licensee PAGEPress, Italy

Monaldi Archives for Chest Disease 2022; 92:1915

doi: 10.4081/monaldi.2021.1915

This article is distributed under the terms of the Creative Commons Attribution Noncommercial License (by-nc 4.0) which permits any noncommercial use, distribution, and reproduction in any medium, provided the original author(s) and source are credited.

## Case #1

80-year-old (y/o) male with hypertension and hyperuricemia. He accessed for vertigo and vomiting. Because of slight troponin elevation, he was scheduled for a cardiologic evaluation. Electrocardiogram (EKG) and echocardiography were unremarkable [ejection fraction (EF)= 58%]. A VRT reformation provided by MDCT (Videos 1 and 2) showed a SCA type 1 according to Lipton *et al.* Significant stenosis at the bifurcation between posterior-lateral (PL) and left circumflex artery (LCx) (95%; Figure 1) and in the first and second tract (77%) of left anterior descending artery (LAD) (Figure 2) were also confirmed by MDCT. Coronary angiography confirmed these findings. The patient was then scheduled for double CABG which was performed 2 months later (left anterior mammary artery-LAD and great saphenous-obtuse marginal branch GS-MO) with good result. Post-operative course was unremarkable. At the moment the patient is asymptomatic with normal biventricular function.

## Case #2

79-y/o male with hypertension and active smoking. He was admitted because of worsening epigastric pain with nausea and

weakness. EKG showed ST depression and negative T waves in inferior leads. Given these signs, compatible with NSTEMI, coronary angiography was performed. It showed a SCA originating from the right sinus with a critical stenosis (95%) in the second tract of the right coronary artery (RCA) and a moderate stenosis (50%) in the left main (LM). A drug eluting stent (Xiene Sierra) was then placed in the tract of critical stenosis providing good angiographic results. VRT reformation provided by MDCT allowed to classify this SCA like a type 2 RII-A according to Lipton *et al.* (Videos 3 and 4) moreover, an anomalous course of LAD anterior to the right ventricular outflow tract as a "T vessel" (Videos 3 and 4) was highlighted by CT. Stent was patent and well positioned (Figure 3). Also in this case MDCT showed multiple eccentric calcific plaques involving the whole vessels' course determining a residual moderate stenosis in the LM (58%; Figure 4). During post-operative course, the patient progressively recovered his physical performance and, at the moment, he is asymptomatic with normal biventricular function.

## Discussion

Several classifications of coronary anomalies are present in literature and the most suitable for SCA detected by MDCT was proposed by Lipton *et al.* [5,7], according to location of the ostium, anatomical distribution, course of the transverse trunk.

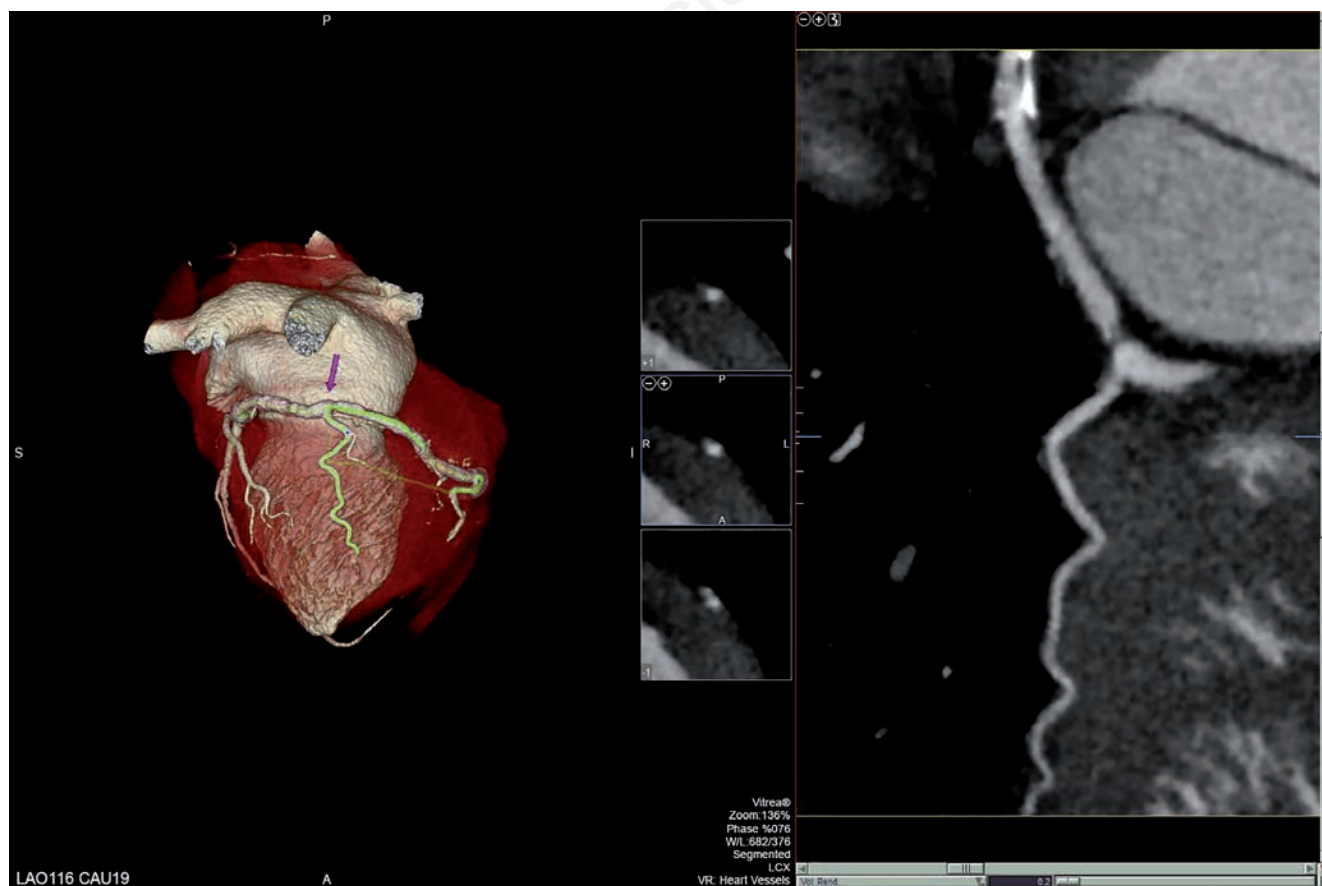

Figure 1. VRT reformation showing severe stenosis of the tract PL-CX (arrow).

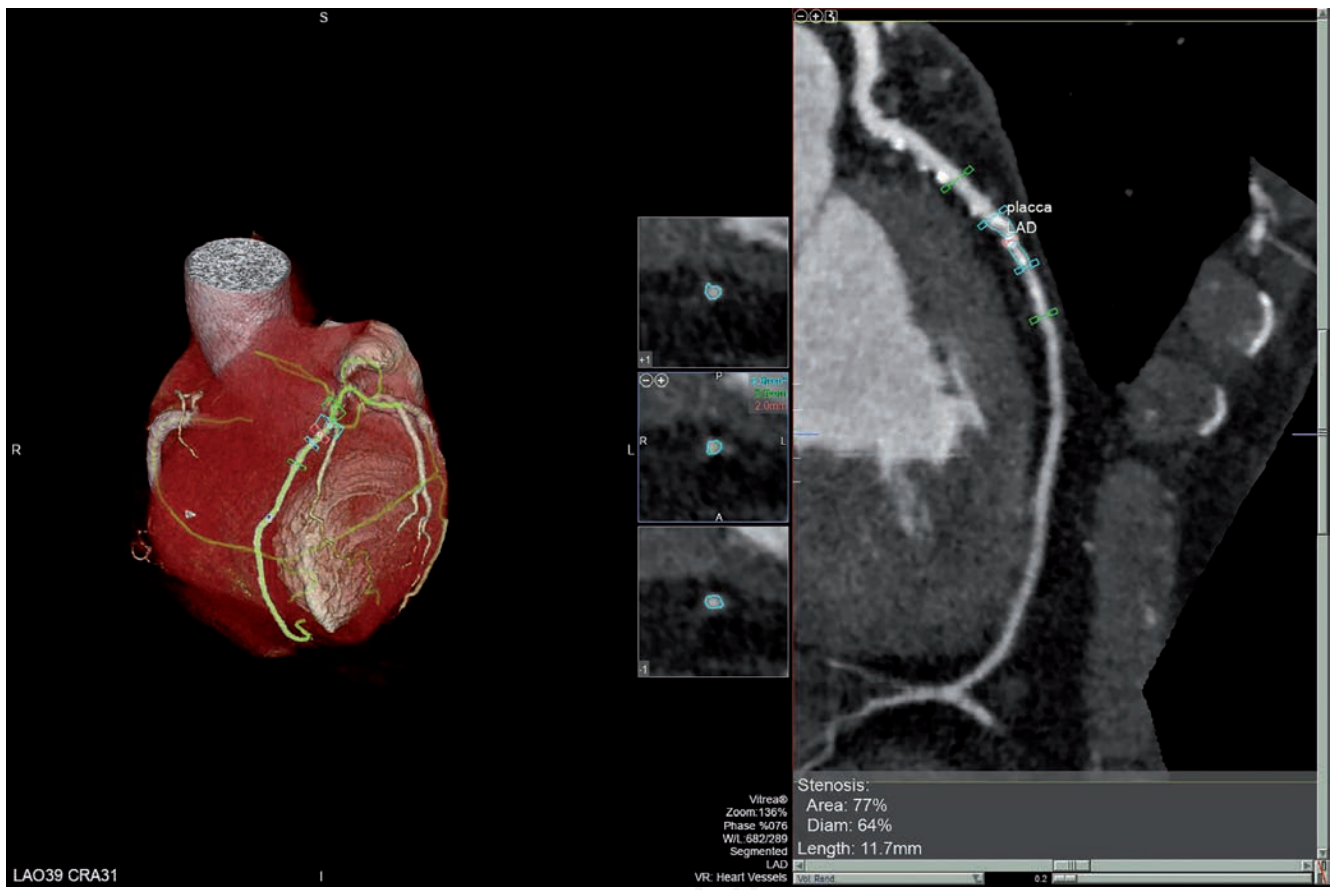


Figure 2. VRT reformation showing moderate-severe stenosis of LAD, second tract.

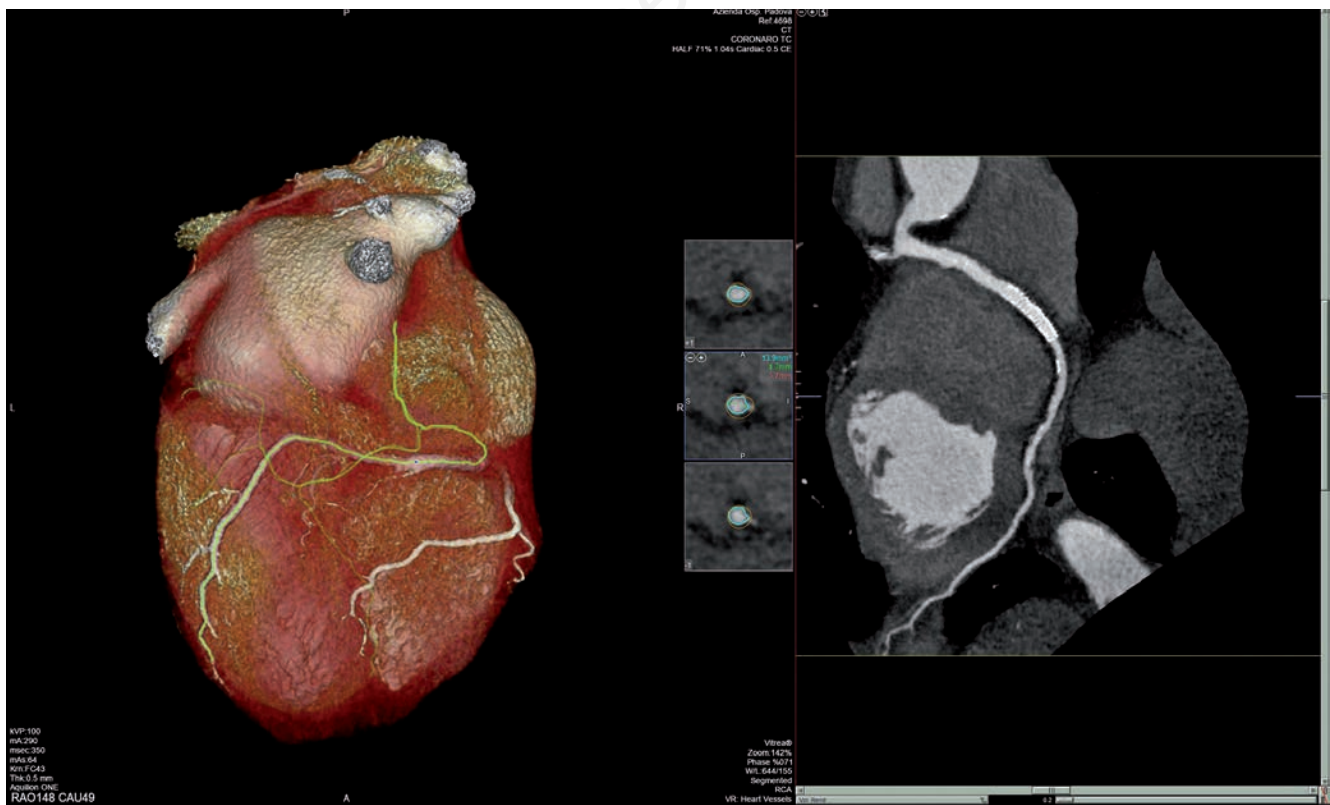

Figure 3. VRT reformation showing the patency of the stent placed.

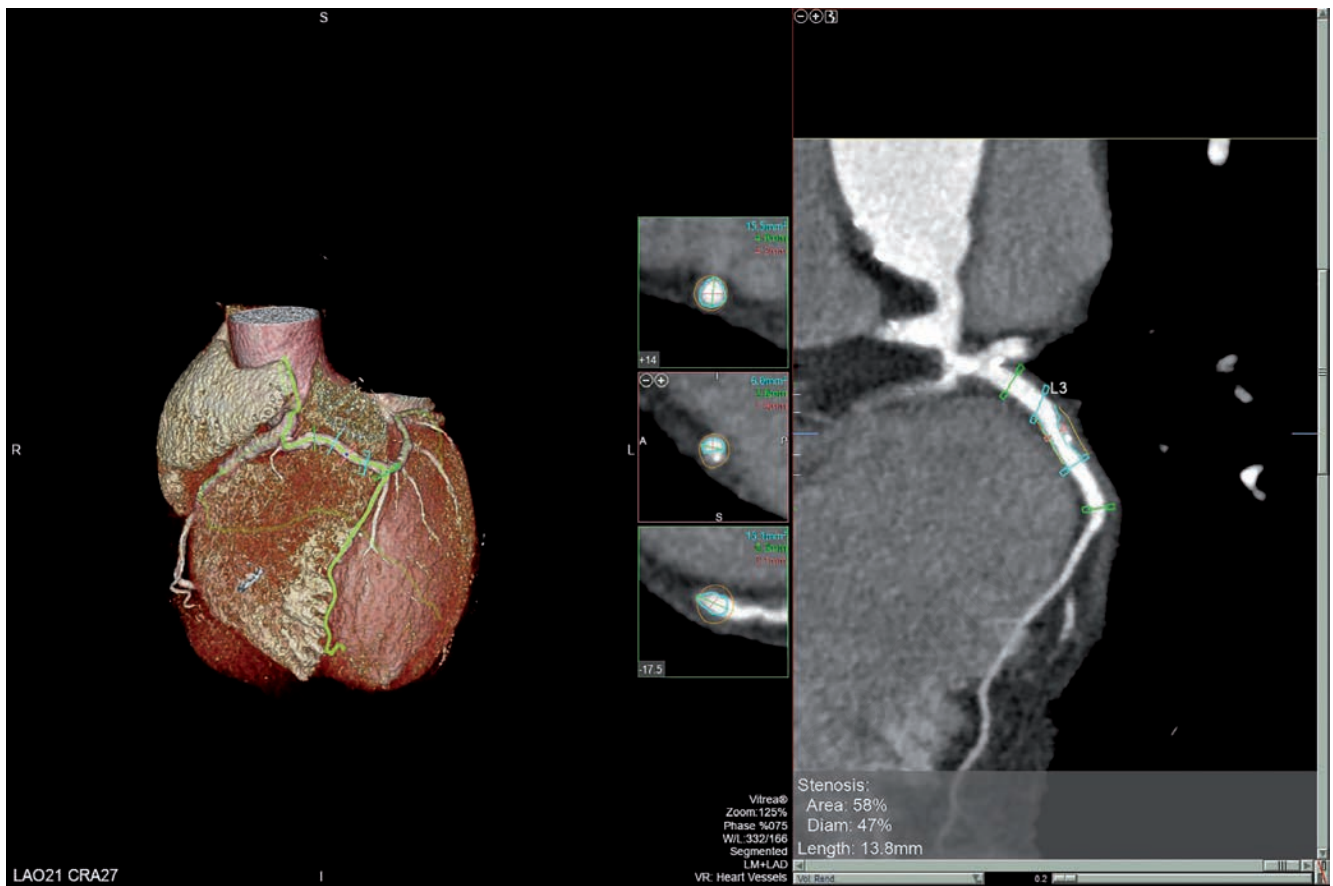


Figure 4. VRT reformation showing moderate stenosis of LM, focusing on “T vessel”.

These two patients, whose SCA originates from the right sinuses, have the rarest coronary anomaly, with a prevalence around 0.02-0.05% in general population [1]. Moreover, the configuration of coronary anatomy of patient 2, with an anomalous course of LAD anterior to the right ventricular outflow tract trunk as a “T vessel”, was described only in one case by Prifti *et al.* [8]. Although SCA detection is often an incidental finding, diagnosis is important, and its recognition is more common today because of increasing use of MDCT [1]. Coronary CT angiography is even more considered a non-invasive fundamental tool for the diagnosis of coronary artery anomalies. In fact, its multiplanar capability provide precise visualization of the origin, course, and termination of the vessels, clarifying their configurations [1,5]. The high spatial and temporal resolution are also able to determine locations and the characteristic of the atherosclerotic plaques (e.g., soft, calcific, eccentric), quantifying the severity of the stenosis. The most frequent complications occurring in patients with SCA are sudden cardiac death (SCD) and cardiac ischemia [1,7]. SCD is significantly higher in patients with inter-arterial course of SCA (between aorta and pulmonary trunk), where the “kinking” of the coronary at its origin caused by the distention of the aorta during exercise has been advocated as the principal pathogenic mechanism [8,9]. Anyway, in our two cases inter-arterial course of SCA was carefully ruled out by MDCT. The pathogenic mechanism at the basis of ischemic cardiopathy in patients with this rarer type of SCA is more complex and not well determined. It could be functional, when the single coronary artery becomes insufficient to support

myocardial oxygen consumption during exercise, or it could be caused by coronary atherosclerosis [8]. The patients described above had multiple cardiovascular risk factors which justify the finding of diffuse calcific plaques by MDCT. However, it is not clear if the presence of an anomalous vessel increases or not the chances of coronary artery disease [8]. Some studies suggest that anomalous arteries are relatively protected from stenotic disease except for anomalous vessels arising from the right side with a retro-aortic course, which seem to have a greater risk seem to develop earlier and greater atherosclerotic lesions than normal [10]. In our series, coronary angiography and MDCT detected multiple coronary plaques causing vessel stenosis, but atypical cardiovascular symptoms developed at an older age.

## Conclusions

There is no general agreement and definite indications that favorite surgery vs percutaneous interventions in SCA are lacking. In literature there are only few cases about stenting or CABG in R-SCA patients [8]. In these patients, invasive approaches are more hazardous. Anyway, their success relies on an accurate morphologic description of the anomalous arteries provided by MDCT, in order to recognize all the possible mechanisms of myocardial ischemia and to choose the most appropriate type of treatment [9].

## VIDEO LEGENDS

---

Videos 1-2. VRT reformation with (1) and without (2) heart chambers of the SCA type 1.

---



---

Videos 3-4. VRT reformation with (1) and without (2) heart chambers of the SCA type 2 RII-A.

---



---

## References

1. Kastellanos S, Aznaouridis K, Vlachopoulos C, et al. Overview of coronary artery variants, aberrations and anomalies. *World J Cardiol* 2018;10:127-40.
2. Angelini P. Coronary artery anomalies: an entity in search of an identity. *Circulation* 2007;115:1296-305.
3. Della Monica M, Galzerano D, Di Michele S, et al. Science, art, and mystery in the Statues and in the Anatomical Machines of the Prince of Sansevero: The masterpieces of the "Sansevero Chapel". *Am J Med Genet* 2013;161:S2920-9.
4. Annabi MS, Salaun E, Cosyns B, et al. Multimodality imaging assessment of prosthetic aortic valve. In: K Fattouch, P Lancellotti, MA Vannan and G Speziale, Editors. *Advances in treatments for aortic valve and root diseases*. Cham: Springer; 2017. p. 95-123.
5. Sepulveda NA, Restrepo CS, Kimura-Hayama E. Single coronary artery: Spectrum of imaging findings with multidetector CT. *J Cardiovasc Comput Tomogr* 2013;7:391-9.
6. Brothers JA, Frommelt MA, Jaquiss RDB, et al. Expert consensus guidelines: Anomalous aortic origin of a coronary artery. *J Thorac Cardiovasc Surg* 2017;153:1440-57.
7. Lipton MJ, Barry WH, Obrez I, et al. Isolated single coronary artery: diagnosis, angiographic classification and clinical significance. *Radiology* 1979;130:39-47.
8. Prifti E, Ademaj F, Krakulli K, et al. A rare coronary anomaly consisting of a single right coronary ostium in an adult undergoing surgical coronary revascularization: a case report and review of the literature. *J Med Case Rep* 2016;10:190.
9. Raddino R, Pedrinazzi C, Zanini G, et al. Percutaneous coronary angioplasty in a patient with anomalous single coronary artery arising from the right sinus of Valsalva. *Int J Cardiol* 2006;112:e60-2.
10. Eid AH, Itani Z, Al-Tannir M, et al. Primary congenital anomalies of the coronary arteries and relation to atherosclerosis: an angiographic study in Lebanon. *J Cardiothor Surg* 2009;4:58.