

HEAD AND NECK

Reconstruction of the lower lip after broad oncologic resection by Colmenero flap: a reliable option

Ricostruzione del labbro inferiore mediante lembo di Colmenero dopo ampia chirurgia demolitiva: una opzione affidabile

José-Miguel Costa-Gonzalez¹, Anna Sumarroca², Jordi Aguilera-Saez³, María Martel-Martin⁴, Andreas Leidinger⁵, María-Pilar Machin⁶, Rosa-Delia Ramirez-Ruiz¹

¹ Department of Otorhinolaryngology, Hospital Clinic de Barcelona, Universitat de Barcelona, Barcelona, Spain; ² Department of Otorhinolaryngology, Hospital del Mar – Parc de Salut Mar de Barcelona, Universitat Pompeu Fabra, Barcelona, Spain;

³ Department of Plastic Surgery and Burns, Hospital Universitari Vall d'Hebron, Universitat Autònoma de Barcelona, Barcelona, Spain; ⁴ Department of Otorhinolaryngology, Hospital Sant Joan Despí Moisès Broggi, Universitat de Barcelona, Barcelona, Spain;

⁵ Department of Neurosurgery, Hospital Mútua de Terrassa, Universitat de Barcelona, Barcelona, Spain; ⁶ Anatomical Pathology Department, Hospital de Sant Joan Despí Moisès Broggi, Universitat de Barcelona, Barcelona, Spain

SUMMARY

Objective. Reconstruction of the lower lip is complex. The Colmenero flap is an effective albeit rarely described method for the repair of medium- to large-sized defects of the lower lip.

Methods. A retrospective review was carried out using data gathered from patients who had undergone Colmenero flap reconstruction of the lower lip at our centre between 2015 and 2020. We analysed demographic, histologic and anatomic variables as well as surgical results. This review assessed flap functionality based on proper mouth closure, absence of microstomia and oral competence.

Results. Thirteen Colmenero flaps were performed in 9 patients, with the flap being used bilaterally in four cases. All patients had squamous cell carcinoma of the lower lip. The mean length of the reconstructed defect was 4.1 cm (ranging between 3-7.5 cm). None of the flaps exhibited signs of necrosis. Five patients required minor surgical touch up during the second procedure: two for dehiscence, two for oral leakage and one for esthetic improvement. All patients had excellent functional and aesthetic final outcomes.

Conclusions. The Colmenero flap is a good resource for medium- and large-sized lower lip reconstructions due to its reliability, limited complications, and good aesthetic and functional results.

KEY WORDS: Colmenero flap, lower lip reconstruction, lip carcinoma, squamous cell carcinoma, sentinel node

RIASSUNTO

Obiettivo. La ricostruzione del labbro inferiore è complessa. Il lembo di Colmenero è un metodo efficace anche se raramente descritto per la riparazione di difetti medio-grandi del labbro inferiore.

Metodi. È stata effettuata una revisione retrospettiva utilizzando i dati raccolti da pazienti sottoposti a ricostruzione del labbro inferiore mediante lembo di Colmenero presso il nostro centro tra il 2015 e il 2020. Abbiamo analizzato le variabili demografiche, istologiche e anatomiche nonché i risultati chirurgici ottenuti. Questa revisione ha valutato la funzionalità del lembo in base alla corretta chiusura della bocca, all'assenza di microstomia e ripristino della competenza orale.

Risultati. Tredici lembi di Colmenero sono stati eseguiti in 9 pazienti, in quattro dei quali bilateramente. Tutti i pazienti erano affetti da carcinoma a cellule squamose del labbro inferiore. La lunghezza media del difetto ricostruito è risultata di 4,1 cm (compresa tra 3-7,5 cm). Nessuno dei lembi ha manifestato segni di necrosi. Cinque pazienti hanno richiesto piccoli ritocchi chirurgici mediante una seconda procedura: due per deiscenza, due per incontinenza orale e uno per miglioramento estetico. Tutti i pazienti hanno avuto ottimi risultati finali funzionali ed estetici.

Received: February 4, 2021

Accepted: March 26, 2021

Published online: November 26, 2021

Correspondence

Anna Sumarroca

Department of Otorhinolaryngology, Hospital del Mar – Parc de Salut Mar de Barcelona, Universitat Pompeu Fabra, Passeig Marítim de la Barceloneta, 25, 29, 08003 Barcelona, Spain
Tel. +34 932 48 30 00. Fax +34 932 48 32 54
E-mail: annasumarroca@gmail.com

Funding

None.

Conflict of interest

The Authors declare no conflict of interest.

How to cite this article: Costa-Gonzalez JM, Sumarroca A, Aguilera-Saez J, et al. Reconstruction of the lower lip after broad oncologic resection by Colmenero flap: a reliable option. Acta Otorhinolaryngol Ital 2021;41:507-513. <https://doi.org/10.14639/0392-100X-N1458>

© Società Italiana di Otorinolaringoiatria e Chirurgia Cervico-Facciale



OPEN ACCESS

This is an open access article distributed in accordance with the CC-BY-NC-ND (Creative Commons Attribution-Non-Commercial-NoDerivatives 4.0 International) license. The article can be used by giving appropriate credit and mentioning the license, but only for non-commercial purposes and only in the original version. For further information: <https://creativecommons.org/licenses/by-nc-nd/4.0/deed.en>

Conclusioni. Il lembo Colmenero è una buona risorsa per ricostruzioni del labbro inferiore di medie e grandi dimensioni grazie alla sua affidabilità, alle modeste complicazioni e ai buoni risultati estetici e funzionali.

PAROLE CHIAVE: *lembo di Colmenero, ricostruzione del labbro inferiore, carcinoma del labbro, carcinoma a cellule squamose, linfonodo sentinella*

Introduction

The lower lip performs various functions, such as ensuring proper mouth closure during swallowing, oral competence for saliva containment, speech, facial mimicry and aesthetic harmony¹. Squamous cell carcinoma is the most common malignancy of the lower lip². Its prognosis depends on the tumour size, degree of invasion³ and lymph node involvement², and its treatment is mainly surgical⁴. There are many reconstructive options after excision of tumours of the lower lip, and their use depends on the size, location and type of defect. Smaller lesions (less than one third of the lip) can be resolved with direct closure after wedge excision⁵, while larger defects (affecting the entire lip, including the vermilion) can be reconstructed using a free flap¹. Medium- and large-sized defects, involving between one-third and the entire lower lip, can be repaired with pedicled local flaps, such as the Abbe flap⁶, the Karapandzic flap⁷, the flap designed by Yu⁸, or the gate flap described by Fujimori⁹. The Colmenero flap¹⁰, first described in 1981 and named after its creator, is a local transposition flap that is pedicled to the inferior labial artery. Although there has been little documentation of this flap, it has been reported to be a useful method to repair medium- and large-sized lower lip defects due to its ease of use, use of defect-like tissue, reliability and the possibility to create a neo-vermilion.

The objective of this study was to document our series of reconstructions of the lower lip after tumour resection using the Colmenero flap, thereby providing an update of its indications, surgical technique and aesthetic and functional results achieved, as well as its complications and suggested resolutions.

Materials and methods

A retrospective review was carried out in patients who had undergone lower lip resection and Colmenero flap reconstruction at our centre between 2015 and 2020. We collected data from the registry of patients with head and neck tumours treated at our hospital during admission and outpatient follow up. Gender, age, smoking history, cTNM and pTNM classification, defect size, treatments performed, complications, reoperations, final result and follow-up time were analysed. The follow-up time was measured from the date of the surgery to the date of the last visit. All surgical

procedures were performed by the same surgical team. This study was carried out in accordance with the Declaration of Helsinki.

Oncologic management

The overall oncologic management (surgical indication and lymph nodes management) of patients was individualised and agreed by the Functional Oncology Care Unit. The results of histopathology for all lesions corresponded to infiltrating squamous cell carcinomas of the lower lip was performed, and were classified or reclassified according to the 8th Edition of the TNM³. The tumour excision was performed with macroscopic margins of 1 cm. The patients with suspected regional lymph node involvement and those with cT3 tumours underwent simultaneous homolateral or bilateral functional cervical lymph node dissection, depending on the location of the primary tumour and the results of imaging tests. Patients with cT1N0 or cT2N0 tumors underwent sentinel node detection in the same surgical procedure. The cases which, after histopathological assessment, were classified as pT3 or in which the sentinel node testing revealed positive results, underwent a second cervical lymph node dissection. In one cT2 patient, the sentinel lymph node was not detected due to very extensive anterior cervical lipomatosis, and the surgical treatment was not decided until the final histopathological results of the tumour (pT2) became available. The second case, which was first classified as cT2N0 and reclassified after resection and assessment of the sentinel node as pT3N3b (due to capsular rupture), refused cervical treatment and was closely monitored by clinical and imaging exams. None of the patients received chemotherapy or adjuvant radiation therapy.

Surgical technique

The accepted surgical technique at our Unit is as follows: first, a complete “V” wedge excision of the primary lip lesion is performed, with macroscopic margins of 1 cm (Fig. 1 A-B). Secondly, the diameter of the defect is measured and the flap is designed. The donor area is usually homolateral for defects of less than two-thirds of the lower lip, and bilateral for defects greater than two-thirds of the lower lip or for very central defects, to improve postoperative facial symmetry. The flap design is full thickness, including skin, muscle and mucosa. The first incision begins at the corner of the lip and is proportional to the length of

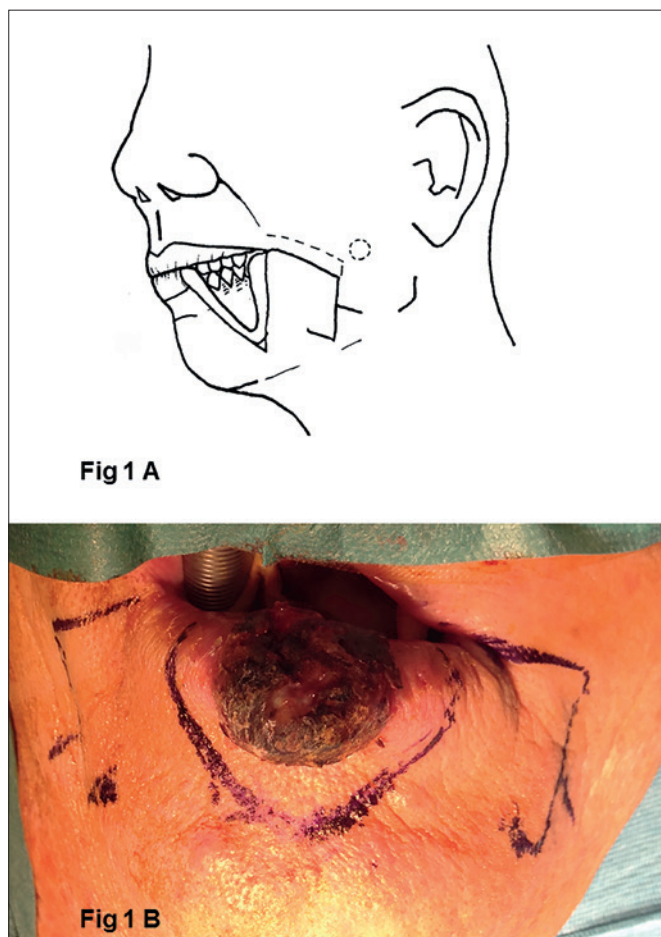


Figure 1. Design of the Colmenero flap. (A) Diagram of the flap design. The discontinuous line reflects the need to cut the jugal mucosa 1 cm higher than the cut of the skin to revert the mucosa and facilitate creation of the neo-vermilion. The design should allow the integrity of the Stensen duct papilla (circle) in the mucosa to be maintained. (B) Photograph of the design of tumour resection and design of the bilateral Colmenero flap.

the defect. The second incision starts at the distal point of the first incision, and continues down towards the mandibular bar, without reaching it. At the lower end of the second incision, a Z-plasty is designed to facilitate tension-free closure of the donor area.

Once the skin cuts are made, a blunt dissection is performed until the main arteriovenous pedicles of the flap are located and preserved. The main flap vascular supply depends primarily on the inferior labial artery – a branch of the facial artery – and secondarily on the submental artery (Fig. 2A). The inferior labial artery is located 2.58 cm (SD 0.70) and 1.54 cm (SD 0.45) inferior to the lip commissure. It traverses between the muscular and glandular layers of the lip, about 8 mm parallel to the free edge of the lower lip¹¹. The concomitant arteries and veins are located and protected with Vaseloops® for added safety (Fig. 2B). Once the

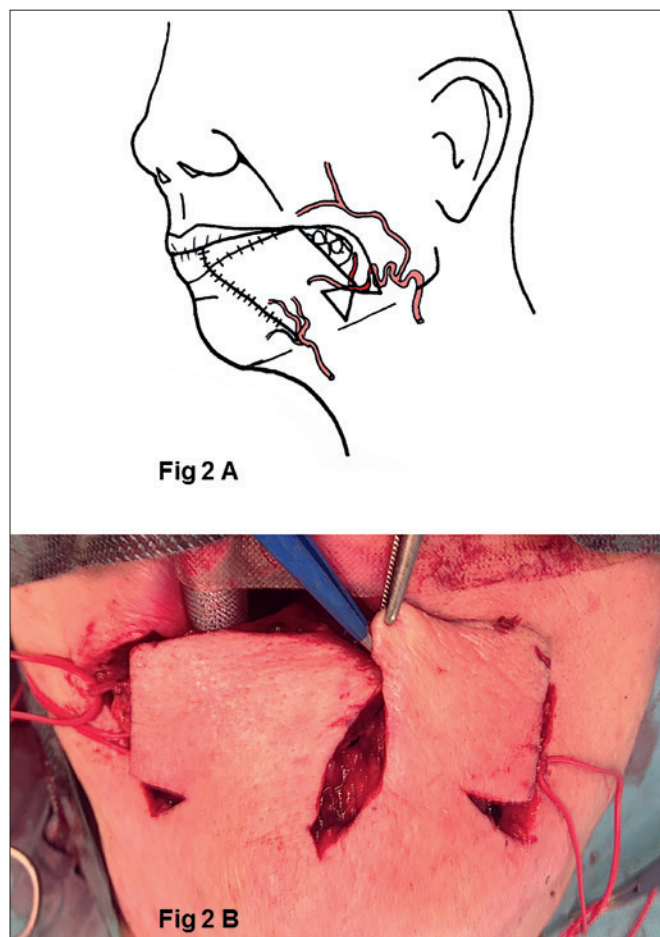


Figure 2. Creation and tailoring of the flap. (A) Diagram of the tailoring and blood supply of the flap. The flap depends mainly on the inferior labial artery, which is a branch of the facial artery (on the right). It is supplied secondarily by another arterial tributary from the submental artery, which is more medial and inferior. Source: A. Leidinger. (B) Photograph of the tailoring of the bilateral flap to the defect. The pedicles are located and preserved with Vaseloops®.

pedicles are identified, dissection of the flap edges to the mucosa is completed. Subsequently, the upper incision is transfixed by cutting the mucosa 1 cm higher than the skin incision, in order to be able to reverse it to the outside and, thereby, serve as a neo-vermilion. The inferior Z-plasty can be performed with or without preservation of the mucosa. Third, the flap is rotated and tailored to fit the defect and the closure (Fig. 3 A-B). It is possible to perform an island flap, leaving it attached by the vascular pedicle only, which allows better mobilisation and more precise repositioning of the flap. In one patient, the procedure yielded good results (Fig. 4). To provide greater functionality to the lower lip, a muscle band is removed from the upper lip (Fig. 5 A-B) and inserted into the submucosa of the lower lip. Finally, all wounds were sutured in three layers: interrupted stitches of resorbable material (Vycril® 3-0) were used for the mucosa

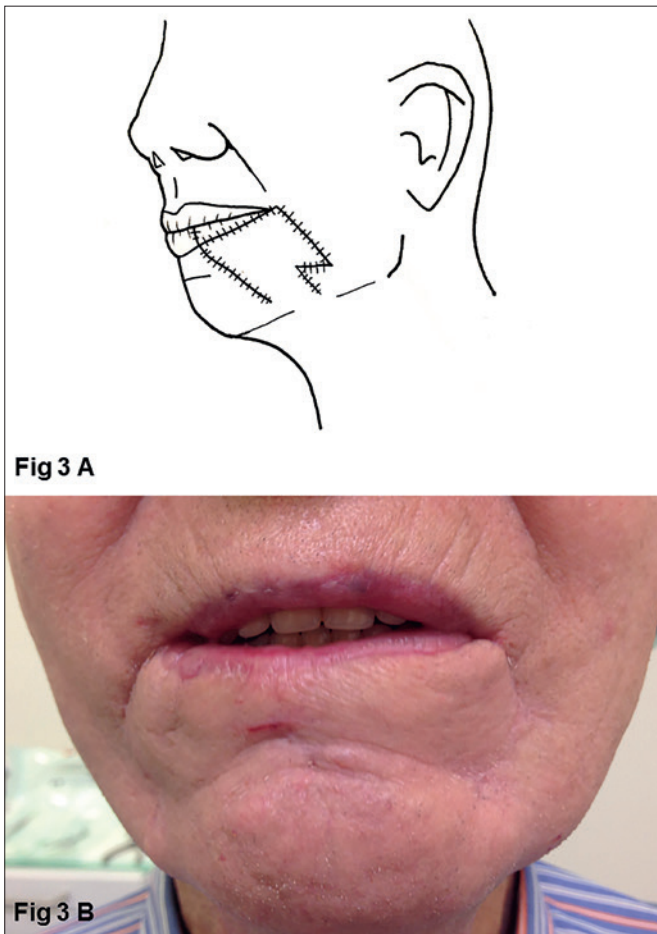


Figure 3. The final outcome of the lower lip reconstruction. (A) The final design of the reconstructed lip. Source: A. Leidinger. (B) Photograph of the patient's lip at six months after the surgery.

and submucosa, and single stitches of monofilament thread (Prolene® 4-0) were used for the skin. Cutaneous healing can be optimised with epithelialisation ointment.

The anatomic course of the inferior labial artery is fairly constant, and thus we perform this flap guided by anatomic landmarks. Nevertheless, the use of preoperative vascular study with Doppler ultrasound could provide more reliability and safety. We acknowledge its utility especially during the early cases of a surgeon's learning curve.

Results

Patient characteristics

Nine patients were operated on, which included seven men and two women, with a mean age of 77 years (ranging between 71-88 years). The mean follow-up time was 30 months (range 6-70 months). Eight of the nine patients had

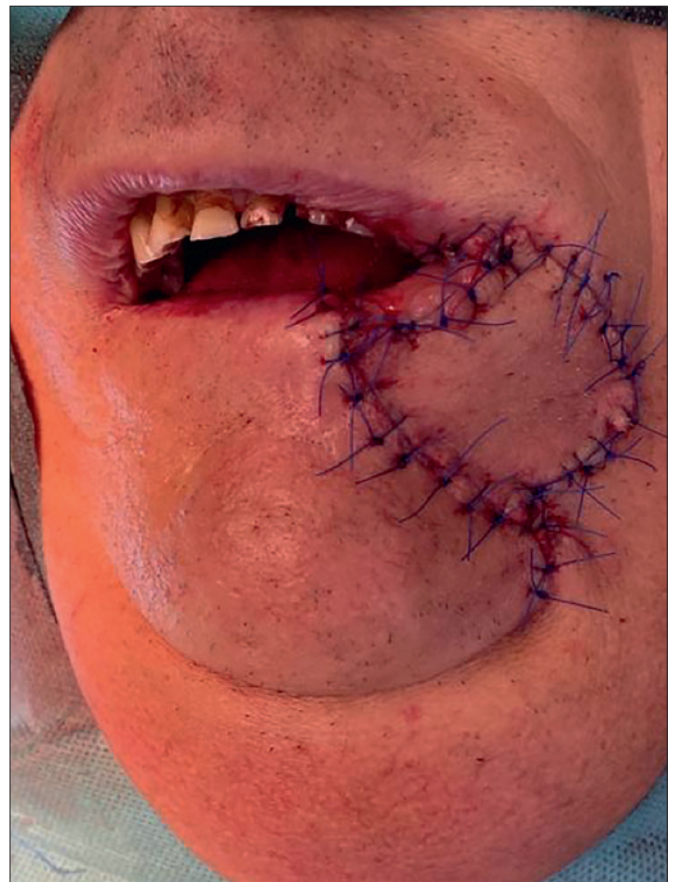

Figure 4. Result of the Colmenero flap made on an island.

previous history of use of tobacco at the time of diagnosis. One patient was staged pT1, five patients were staged pT2 and three patients were staged pT3. The mean length of the defect created in the lip by the excision of the tumour lesion was 4.1 cm (ranging between 3-7.5 cm). In four patients, the flaps were performed bilaterally as part of the same surgical procedure; thus, a total of 13 Colmenero flaps were used: 7 on the right side and 6 on the left. During follow-up, no cases of local, regional, or distant tumour recurrence were observed. Table I summarises these results.

Flap viability

All Colmenero-type flaps were viable and were performed in a single surgical procedure; no partial or total necrosis was observed in any patient. The inferior labial artery could be identified in all cases, in addition to other secondary pedicles. All flaps fulfilled their reconstructive function. Four patients required bilateral flaps due to the large size and central location of the defect. The facial artery was preserved during cervical lymph node dissection.

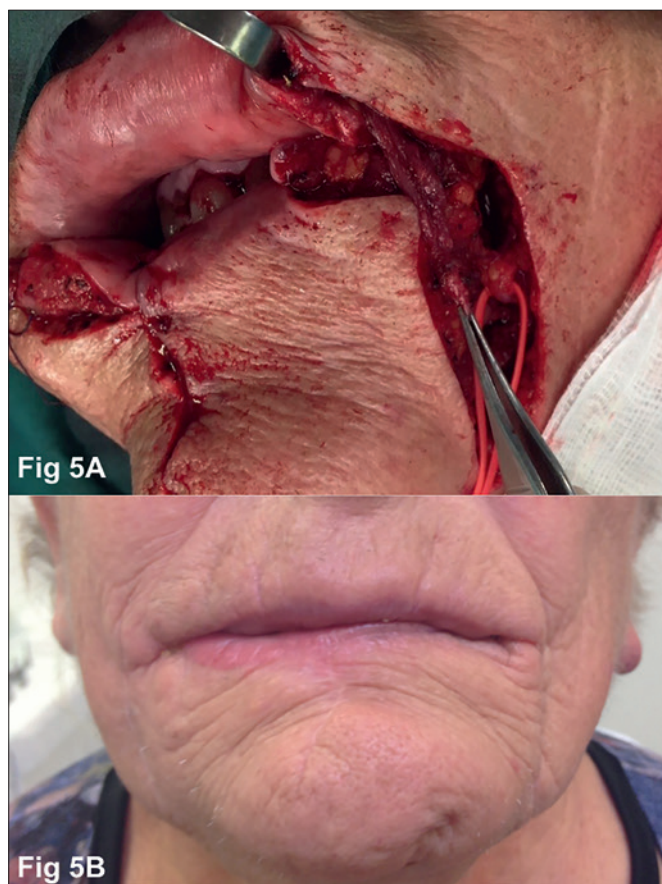


Figure 5. Placement of an upper lip muscle band for the lower lip. (A) Photograph of the surgical muscle band technique. (B) Photograph of the patient's lip at six months after the surgery.

Complications

Four of the 9 operated patients presented minor complications; however, they were all readily rectified. Two patients presented with surgical wound dehiscence. The first patient had undergone bilateral treatment and presented with de-

hiscence in the midline suture between both Colmenero flaps. The second patient presented a surgical dehiscence at the area of the flap suture, with the medial end of the lower lip preserved. On both occasions, the defect was resolved by refreshing the margins and suture under local anaesthesia in the outpatient clinic, 20 days after the surgery in the first case and one month after the surgery in the second case. Both patients healed well, with no new dehiscence being observed.

Lip incompetence that translated into fluid leakage while drinking was observed in two patients who consequently required surgical correction under local anaesthesia in the operating room. In one case, the flap was unilateral and the leakage was corrected, with improved lip closure at 20 months after the first surgery. Placement of a muscular upper lip band in the submucosa of the lower lip was repeated. In the second case, operated with bilateral flaps, the mucosa suture area was retouched with a Z-plasty to decrease the tension exerted by retractable flanges. Both patients achieved complete lip competence after healing.

On one patient, surgical procedure was performed two times because he was histopathologically recategorised as pT3N0. During the second time, the patient underwent cervical lymph node dissection and an aesthetic lip touch-up, reducing a redundant fold of neolabial mucosa.

None of the flaps or cervical surgeries required urgent surgical revision, nor did they result in any major complications.

Functionality and aesthetics

The functionality of the flaps was assessed based on three items: correct mouth closure, absence of a microstomia based on the ability to eat with normal eating utensils and oral competence with the absence of fluid leakage while drinking. These aspects were reviewed during follow-up, and the flaps were found to have excellent functionality in

Table I. Characteristics of patients treated with a Colmenero flap.

Patient	pTNM	Unilateral/ bilateral	Lower lip percentage sacrificed	Complications	Retouching	Final competence and functionality	Follow-up period (months)
1	T2N0	Bilateral	90%	Dehiscence	Friedrich	Yes	70
2	T2N0	Unilateral	75%	Leakage	Lip band	Yes	52
3	T3N0	Bilateral	60%	No	Aesthetic	Yes	50
4	T2N0	Bilateral	75%	Leakage	Z-plasty	Yes	34
5	T1N0	Unilateral	50%	No	No	Yes	30
6	T2N0	Unilateral	60%	Dehiscence	Friedrich	Yes	13
7	T3N3b	Unilateral	60%	No	No	Yes	12
8	T2N0	Unilateral	50%	No	No	Yes	7
9	T3N0	Bilateral	90%	No	No	Yes	6

all cases. All patients maintained proper lip mobility that allowed them to blow and fully close their mouths. None of the cases exhibited microstomies or mouth opening problems stemming from the lip reconstruction. In addition, none of the patients were found to exhibit fluid leakage or alterations in speech, facial animation, or the oral phase of swallowing.

At the aesthetic level, patients were asked about their satisfaction or desire to improve the surgical result. Only one patient requested a reduction of the redundant labial mucosa.

Discussion

Reconstruction of facial defects owes its complexity to the wide variety of anatomical subunits¹, and this is especially the case for the lip. The vermilion is a mucosa specifically adapted to external exposure, and the mobility of the entire lower lip assembly enables speech, swallowing, oral competence, facial mimicry and correct aesthetics, all of which are key elements for the patient's psychosocial well-being. The Colmenero flap is an axial type of flap that uses the skin, muscle and mucosa adjacent to the lower lip defect, thereby providing a tissue similar to that resected; it is also performed as part of the same surgical procedure as tumour resection¹⁰. This similarity of the tissue, the possibility of creating a neo-vermilion and the muscular band of the upper lip results in fewer functional repercussions and a good aesthetic result. All patients achieved complete lip competence and there were no limitations during feeding or the oral phase of swallowing. The need for a bilateral flap for lesions exceeding 60-70% of the lip can be replaced by a unilateral flap for patients with loose skin, especially with older patients.

Its straightforward design and the constant location of a vascular pedicle of sufficient caliber, such as the inferior labial artery, make it a reliable flap. Indeed, no signs of necrosis were noted in any of our patients. Furthermore, the possibility to perform a single unilateral flap in most cases considerably reduces surgical time. Moreover, this flap is recognised for its versatility, as it allows good mobilisation and tailoring to the defect, which can be increased if designed on an island flap.

Venous drainage occurs in the veins adjacent to the feeding artery, and it is highly recommended that the integrity of the facial artery is preserved, especially in patients requiring cervical lymph node dissection.

Other reconstructive options have been extensively described in the literature. Direct closure is the most straightforward approach, although it is reserved for defects of less than one-third of the lower lip⁵ due to the risk of oral func-

tionality being limited due to the resulting microstomia. In contrast, free flap microanastomosis is the preferred option for reconstruction of the entire lip, including the vermilion¹, because it provides a greater contribution of tissue. The aesthetic result is inferior, however, due to the use of tissue with characteristics other than the recipient area, it requires a higher level of technical expertise and is less reliable. Medium- and large-sized lower lip defects can be resolved with various pedicled flaps of facial tissue. For instance, the inverted Karapandzic flap is easy to perform, but its design entails a risk of microstomia in defects larger than 50% of the lip. This limitation can be resolved by the addition of an inverted Abbe flap¹², although this increases the technical difficulty and involves a second surgery. Few flaps allow reconstruction of the entire lip without causing a lip microstomia. The Yu flap is one of the most complete pedicle flaps for lower lip defects. Its compliance with the lines of tension of the lower one-third of the face, the creation of a neo-vermilion and its wide design provide a satisfactory and symmetric esthetic result that is also functional, while avoiding the risk of microstomia. Compared to the Colmenero flap, the Yu flap involves a higher level of technical difficulty and a smaller supply of tissue, but better aesthetic acceptance and equal or greater lip closure¹³. In our experience, the final functional and aesthetic results of the Colmenero flap were satisfactory in all cases, even if half of patients required surgical retouching at a second stage. Retouching can, however, readily be performed with local anaesthesia in patients with high surgical risk.

The 8th Edition of the TNM³ includes the depth of infiltration of the lesion as criteria, and hence, the length of the lip lesion is not proportional to the T classification in all cases. In our series of patients, we only treated T1, T2, and T3 tumours, although it should also be possible to use this flap with T4 tumours.

One of the supposed limitations of the Colmenero flap is that it does not match facial tension lines. Despite this, we achieved good aesthetic results in our patients. One of the drawbacks of this technique is that it is not a flap specifically designed for lip commissure defects, which, therefore, reduces its indications. Another limitation is that half of the patients required a touch-up of the surgical suture to increase oral competence or to resolve a dehiscence, although all touch-ups performed were minor and could be completed successfully.

Conclusions

The Colmenero flap is a good method for medium- and large-sized lower lip reconstructions due to its reliability, limited complications and good aesthetic and functional

results. The ease of performing the procedure and of tailoring it to the defect, the large contribution of tissue similar to that resected, the simple location of the pedicle and the possibility of creating a neo-vermilion make it a useful and suitable technique for lower lip repairs.

Acknowledgements

We would like to thank Dr. Sancho for his advice and teachings.

References

- ¹ Vanison C, Beckmann N, Smith A. Recent advances in lip reconstruction. *Curr Opin Otolaryngol Head Neck Surg* 2019;27:219-226. <https://doi.org/10.1097/MOO.0000000000000531>
- ² Cerezo L, Liu FF, Tsang R, et al. Squamous cell carcinoma of the lip: analysis of the Princess Margaret Hospital experience. *Radiother Oncol* 1993;28:142-147. [https://doi.org/10.1016/0167-8140\(93\)90006-t](https://doi.org/10.1016/0167-8140(93)90006-t)
- ³ Brierley J, Gospodarowicz MK, Wittekind CH, editors. *TNM classification of malignant tumours*. Eighth edition. Oxford, UK, Hoboken, NJ: John Wiley & Sons Inc.; 2017.
- ⁴ Baker SR. Current management of cancer of the lip. *Oncology* 1990;4:107-120.
- ⁵ Calhoun KH. Reconstruction of small- and medium-sized defects of the lower lip. *Am J Otolaryngol* 1992;13:16-22. [https://doi.org/10.1016/0196-0709\(92\)90093-9](https://doi.org/10.1016/0196-0709(92)90093-9)
- ⁶ Abbe R. A new plastic operation for the relief of deformity due to double harelip. *Plast Reconstr Surg* 1968;42:481-483.
- ⁷ Karapandzic M. Reconstruction of lip defects with local arterial flaps. *Br J Plast Surg* 1974;27:93-97. [https://doi.org/10.1016/0007-1226\(74\)90068-x](https://doi.org/10.1016/0007-1226(74)90068-x)
- ⁸ Yu, J.M. A new method for reconstruction of the lower lip after tumor resection. *Eur J Plast Surg* 1989;2:155-159. <https://doi.org/10.1007/BF00214349>
- ⁹ Fujimori R. "Gate flap" for the total reconstruction of the lower lip. *Br J Plast Surg* 1980;33:340-345. [https://doi.org/10.1016/s0007-1226\(80\)90079-x](https://doi.org/10.1016/s0007-1226(80)90079-x)
- ¹⁰ Colmenero B. Reconstrucción del labio inferior en cirugía oncológica. *Tiempos Médicos* 1981;182:101-110.
- ¹¹ Whetzel TP, Mathes SJ. Arterial anatomy of the face: an analysis of vascular territories and perforating cutaneous vessels. *Plast Reconstr Surg* 1992;89:591-603.
- ¹² Uglesic V, Amin K, Dediol E, et al. Combined Karapandzic-Abbé/Estlander/Stein flap for subtotal and total lower lip reconstruction. *J Plast Reconstr Aesthet Surg* 2019;72:484-490. <https://doi.org/10.1016/j.bjps.2018.11.005>
- ¹³ López AC, Ruiz PC, Campo FJ, et al. Reconstruction of lower lip defects after tumor excision: an aesthetic and functional evaluation. *Otolaryngol Head Neck Surg* 2000;123:317-323. <https://doi.org/10.1067/mhn.2000.104949>