

ORIGINAL ARTICLE

Safety and biodegradability of a synthetic dural sealant patch (Liqoseal) in a porcine cranial model

Ahmet Kinaci^{1,2}  | Wilhelmina Bergmann³ | Sander van Thoor² | Saskia Redegeld² | Albert van der Zwan^{1,2} | Tristan P. C. van Doormaal^{1,2,4}

¹Department of Neurology and Neurosurgery, Brain Center, University Medical Centre Utrecht, Utrecht, The Netherlands

²Brain Technology Institute, Utrecht, The Netherlands

³Division of Pathology, Faculty of Veterinary Medicine, Utrecht University, Utrecht, The Netherlands

⁴Department of Neurosurgery, Clinical Neuroscience Center, University Hospital Zurich, Zurich, Switzerland

Correspondence

Tristan P. C. van Doormaal, Department of Neurosurgery, University Medical Centre Utrecht, G.03.124, Heidelberglaan 100, 3584 CX Utrecht, The Netherlands.
Email: T.P.C.vandoormaal@umcutrecht.nl

Funding information

Polyganics BV funded all experiments.

Abstract

Background: Liqoseal consists of a watertight layer of poly(ester)ether urethane and an adhesive layer containing polyethylene glycol-*N*-hydroxysuccinimide (PEG-NHS). It is designed to prevent cerebrospinal fluid (CSF) leakage after intradural surgery. This study assessed the safety and biodegradability of Liqoseal in a porcine craniotomy model.

Methods: In 32 pigs a craniotomy plus durotomy was performed. In 15 pigs Liqoseal was implanted, in 11 control pigs no sealant was implanted and in 6 control pigs a control dural sealant (Duraseal or Tachosil) was implanted. The safety of Liqoseal was evaluated by clinical, MRI and histological assessment. The degradation of Liqoseal was histologically estimated.

Results: Liqoseal, 2 mm thick before application, did not swell and significantly was at maximum mean thickness of 2.14 (\pm 0.37) mm at one month. The foreign body reaction induced by Liqoseal, Duraseal and Tachosil were comparable. Liqoseal showed no adherence to the arachnoid layer and was completely resorbed between 6 and 12 months postoperatively. In one animal with Liqoseal, an epidural fluid collection containing CSF could not be excluded.

Conclusion: Liqoseal seems to be safe for intracranial use and is biodegradable. The safety and performance in humans needs to be further assessed in clinical trials.

KEYWORDS

cerebrospinal fluid leakage, craniotomy, dura, in vivo model, sealant

1 | INTRODUCTION

When the dura is opened during a cranial or spinal surgical procedure, a potential risk for postoperative cerebrospinal fluid (CSF) leakage arises. The risk of CSF leakage after cranial surgery is between 8.2% and 8.4% in general, with a higher incidence in patients that underwent posterior fossa surgery.¹ Persistent CSF leakage is associated with secondary complications such as compromised

wound healing, wound infection and meningitis.² Besides, CSF leakage is associated with prolonged hospitalization and increased healthcare costs.³⁻⁵ Watertight closure of the dura is widely regarded as the first step in preventing CSF leakage. However, primary watertight closure is a difficult task and often not achievable. Therefore, sealants are often used to augment dural closure, eventually in combination with a dural substitute when primary closure is not possible.

This is an open access article under the terms of the Creative Commons Attribution-NonCommercial-NoDerivs License, which permits use and distribution in any medium, provided the original work is properly cited, the use is non-commercial and no modifications or adaptations are made.

© 2021 The Authors. *Animal Models and Experimental Medicine* published by John Wiley & Sons Australia, Ltd on behalf of The Chinese Association for Laboratory Animal Sciences.

Meta-analyses showed that currently approved sealants seem not to be effective in preventing CSF leakage after cranial and spinal surgery.^{1,6} *Ex vivo* evaluation of these same sealants showed concerning results regarding adhesion strength to dura.⁷ Only 3 out of the 9 commonly used sealants had a mean burst pressure above mean physiological intracranial pressure and only two of them (Duraseal and Adherus) could remain attached in physiological conditions for 72 h.⁷ Duraseal and Adherus are both liquid sealants missing the advantages of patch sealants such as minimal preparation time, easy application and consistent thickness. Thus the development of a new dural sealant patch is needed. Liqoseal (Polyganics bv, Groningen, The Netherlands) is a patch designed for adherence to dural tissue that is ready to use directly. It consists of two layers; a watertight layer consisting of biodegradable poly(ester) ether urethane and an adhesive layer consisting of a biodegradable poly(DL-lactide-co- ϵ -caprolactone) copolymer and multiarmed NHS functionalized polyethylene glycol (PEG-NHS).⁸ *Ex vivo* tests showed strong adherence of Liqoseal to the dura.⁸ However, application in patients is considered unsuitable before safety and biodegradability evaluation. In this study, we assessed the safety and biodegradability of Liqoseal in a porcine model. We hypothesized that Liqoseal swells within safe margin, induces comparable foreign body reaction as current sealants and is completely biodegradable.

2 | METHODS

2.1 | Ethical approval

This study was approved by the local ethical review board and Central Animal Testing Committee affiliated to the Dutch National Institute for Public Health and the Environment (Approval No. AVD115002016457). The animals were treated in accordance with the guidelines of the Association for Assessment and Accreditation of Laboratory Animal Care (AAALAC) and ISO 10993-2.

2.2 | Animals

Domestic pigs (Norsvin Topings) were used for this study. The gross anatomy of the cranium, microanatomy of the dura mater and relative easy housing highly qualified the pigs for this study.⁹ The mean weight of the animals was 66 (\pm 5.7) kg and mean age was 4.3 (1.2) months on the day of surgery. The animals were acclimatized before surgery for at least 1 week and kept in groups of three in neighboring pens on straw.

2.3 | Procedure

A transdermal buprenorphine patch (5 g/h) was applied on the abdominal skin 1 day before surgery and remained in place for 7 days. General anesthesia was induced with intramuscular injection of a

mixture containing midazolam (0.7 mg/kg), ketamine (13 mg/kg) and atropine (0.05 mg/kg). The animals were intubated orotracheally and placed in a prone position on the operating table. Anesthesia was continued with a bolus of propofol (3 mg/kg) and maintained with intravenous propofol (4.5 mg/kg/h) and remifentanyl (0.0066 mg//kg/h). Intravenous amoxicillin/clavulanic acid (500 mg) and a bolus of meloxicam (0.4 mg/kg) were administered before incision. A continuous saline infusion at a rate of 1.5 ml/kg/h was given during surgery. A jugular cannula was inserted because of frequent blood sampling. Subsequently, the incision area of the craniotomy was injected with lidocaine HCL (10 ml) subcutaneously just before incision. A craniotomy of 4 × 4 cm over the midline was performed. After hemostasis, the dura was opened and closed. On the left side the dura was linearly opened (3 cm) and closed with 4 interrupted sutures using Vicryl 5-0 (Johnson & Johnson, New Jersey, USA) and on the right side it was opened with two interrupted incisions 1 cm long that were not sutured (Figure 1A). If the blood pressure was below 150/100 mmHg, it was raised above 150/100 mmHg with noradrenaline to test hemostasis. The bone flap was subsequently fixated using sutures. Tranexamic acid (500 mg) was administered intravenously in all cases. All wounds were dripped with neomycin and procaine benzylpenicillin.

All animals were observed daily during the first 2 weeks post-operatively to evaluate general condition, neurological status and wound healing. Intravenous meloxicam (0.4 mg/kg once a daily for 5 days) was administered as postoperative analgesia, together with the transdermal buprenorphine patch. After the designated survival time, an MRI scan of the cranium was performed. The animals were terminated directly after MRI by an overdose of intravenous pentobarbital (200 mg/kg).

2.4 | Experimental subgroups

Thirty-two animals were assigned to one of three groups: the Liqoseal group, the control unsealed group and the control sealant group. To assess the degradation of the patches over time (Table 1), the animals in each group were terminated at different intervals from 3 days to 12 months. In the control sealant group, three animals were implanted with Tachosil and three animals with Duraseal. Both sealants were CE approved for dural closure and Duraseal was also FDA approved. Figure 1B shows the Liqoseal patch, Figure 1C the Tachosil patch and Figure 1D the Duraseal patch. The Liqoseal and Tachosil patches were centered on the dura and gently pressed onto the dura with moistened gauze for 1 min. Using tweezers we confirmed that the sealant patches were firmly attached. We aimed to apply Duraseal to the same thickness (2 mm) on the dura as described in the instructions for use. The surgical procedure is shown in brief in Video S1. Animals with implanted Liqoseal were allowed to survive for a maximum of 12 months as data from the manufacturer indicated complete degradation in 12 months. Animals with Duraseal and Tachosil implants were allowed to survive for a maximum of 3 months, because prior studies showed that Tachosil and Duraseal completely resorb within 3 months.^{10,11}

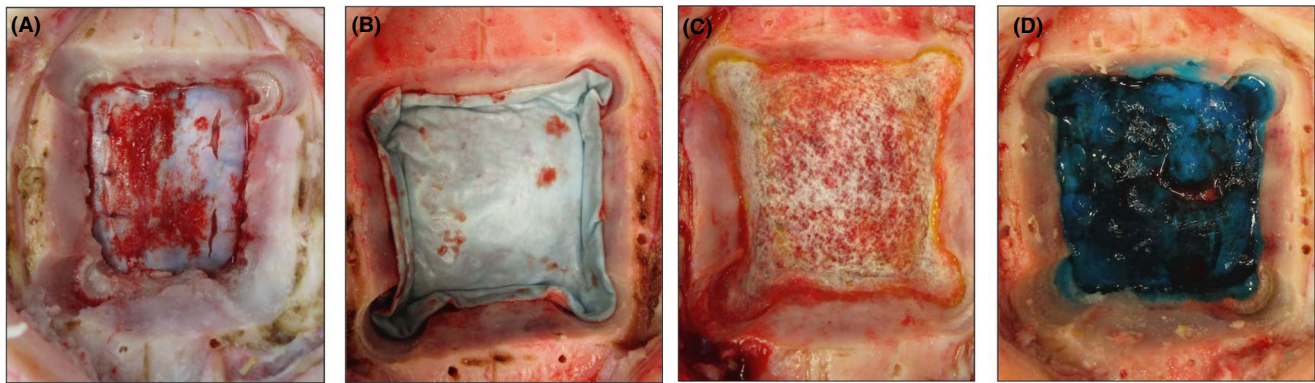


FIGURE 1 (A) One sutured incision of 3 cm at the left side and two incisions of 1 cm at the right side, were created. (B) Dura sealed with Liqoseal. (C) Defect sealed with Tachosil. (D) Dura sealed with Duraseal

TABLE 1 Number of animals per experimental group and survival

Experimental group	3 days	7 days	14 days	1 month	3 months	6 months	12 months	Total
Liqoseal group	2	2	2	3	2	2	2	15
Control unsealed group	2	2	2	2	1	1	1	11
Control sealant group								
Tachosil	1	x	1	x	1	x	x	3
Duraseal	1	x	1	x	1	x	x	3
Total	6	4	6	5	5	3	3	32

2.5 | Assessment

The safety of Liqoseal was evaluated by clinical, imaging and histological assessment. The general condition, neurological status, and wound healing of the pigs were examined twice daily for 2 weeks by a caretaker and the primary researcher (A. K.). For the general conditions, daily intake, defecation, and social behavior were noted. Neurological status was assessed by observing the alertness of the pig, the symmetry of the face and tongue, and the symmetric movement of the limbs without ataxia. The wound was inspected for leakage, redness, swelling, and warmth. Any suspicious behaviors of the pigs were discussed with the neurosurgeon and the veterinarian. Blood samples were taken for leucocyte count and leucocyte differentiation at standard intervals until the day of termination (day of surgery, 1, 3, 7, 14 days and 1, 3, 6, 12 months postoperatively) to ensure timely detection of infection.

MRI (Ingenia 1.5T, Philips) was performed before termination to assess sealant swelling and the presence of intracranial pathology such as abscesses, empyema and pseudomeningocele.

Dura and sealant swelling was measured using cranial MRI (Ingenia 1.5T, Philips) performed before termination in all animals. Dura and sealant were measured together because they became indistinguishable on MRI and macroscopic examination. Volumetric measurements were performed with Osirix 9.0 (Pixmeo, Switzerland) using T2-weighted series.

For histological analyses the calvaria, with a 1 cm margin around the bone flap, including the underlying brain, dura, and sealant was cut out *en bloc* (Figure 2). The block was then fixed in 10% neutral buffered

formalin for a week. Subsequently, coronal sections of 5–8 mm thickness were made from this block and decalcified with Formical-4[®] (Statlab, McKinney, USA) at room temperature. The degree of decalcification was evaluated daily by X-ray (Pathvision 23x29, Faxitron bioptics, LLC) analysis. Hereafter, the tissue was routinely processed for histological evaluation with the use of isopropanol for dehydration and stained with hematoxylin and eosin. A board-certified veterinary pathologist (W. B.) made a histological report and compared the samples regarding extent of foreign body reaction. The degradation rate of Liqoseal was also histologically estimated.

3 | RESULTS

All 32 pigs tolerated the anesthesia and surgery and no intraoperative complication occurred in the pigs included in the study. Shortly after surgery all pigs could be extubated and transported to the pen.

3.1 | Clinical assessment

An adverse event occurred in two pigs: one pig developed superficial jugular cannula wound infection which was treated with antibiotics. Another animal (Liqoseal implanted, 3-month survival) developed a small fistula without fluid leakage of 5 mm in the most cranial part of the wound that closed spontaneously within 8 weeks. The postoperative course and follow-up of all other animals was uneventful.

No animals showed signs of percutaneous CSF leakage. Analyses of the blood samples showed an acute increase in leukocyte count in all animals on day 3 postoperatively, which slowly decreased over time (Figure 3). No differences were found regarding leukocyte count and differentiation between subgroups.

3.2 | MRI follow-up

Measurements showed that Liqoseal does not swell significantly. Liqoseal thickness at application was 2 mm before compression. Pig dura is $0.30 (\pm 0.08)$ mm thick on average.⁹ MRI measurements of dura plus sealant showed a mean thickness of $0.9 (\pm 0.3)$ mm at 3 days, $2.0 (\pm 1.2)$ mm at 14 days and $2.1 (\pm 0.4)$ mm at 1 month. At 6 and 12 months no sealant was visible anymore on MRI.

In one animal (Liqoseal implanted, 1-month survival) an epidural fluid pocket suspected to be CSF leakage was present. In this animal, MRI showed an hyperintense area above the sealant and there was partial detachment of the watertight blue layer observed after section (Figure 4). The fluid collection was located between the adhesive and watertight layer of Liqoseal. MRI showed no lesions suspected for intracranial pathology in all other animals.




FIGURE 2 The bone flap, cerebrum, dura and sealant were cut out the skull as en bloc. (A) Frontal lobe. (B) Temporal lobe. (C) Bone flap

3.3 | Histological follow up

In all animals, including the unsealed control group, large amounts of bone dust, hemorrhages of different sizes, fibrin, proliferating fibroblasts and histiocytes were observed at the cranial side of the dura at 3 days postoperatively. In all animals, thrombi and a cell-poor vasculitis were observed in blood vessels of the dura and leptomeninges. Multifocally, ischemic infarcts and a few hemorrhagic infarcts were present in the cortex in all subgroups.

In the animals with sealants (Liqoseal, Duraseal and Tachosil), an identical foreign body reaction was visible. Liqoseal was shown to resorb slower (6–12 months) than control sealants (3 months). In the unsealed control animals, there was a foreign body reaction to the sutures at 3 days postoperatively.

In animals with a sealant, the number of inflammatory cells increased severely at 7 days and 1 month (Figure 5A,B) and these cells were now also visible within the sealant. This granulomatous foreign body reaction and formation of collagenous fibrous tissue caused thickening of the sealant in all animals. In the unsealed control animals, there was a foreign body reaction to the sutures only at 7 days and 1 month, comparable as the unsealed 3-days survival animals. Also in these control animals the dura thickened due to fibroblast proliferation and multifocal infiltration of moderate amounts of lymphocytes. The leptomeninges thickened slightly at the surgical area in all animals, with and without sealant, due to mild proliferation of fibroblasts and infiltration of moderate amounts of eosinophils, macrophages, lymphocytes and plasma cells.

In the animals surviving 1 month, only small pieces of the Duraseal and Tachosil and an estimated 40% of the Liqoseal patch were still visible. The granulomatous foreign body reaction decreased in line with the degradation of the sealant (Figure 5C,D). In the unsealed control animals, the granulomatous foreign body reaction to suture material was still present.

At three months, Duraseal and Tachosil were completely resorbed and only a mild granulomatous foreign body reaction to the sutures was observed. In the animals with Liqoseal, a moderate granulomatous foreign body reaction could still be observed to the sealant and suture remnants. In the control animals without sealant, a mild granulomatous foreign body reaction to the suture remnants was still visible. The leptomeninges and dura were still thickened in all animals due to inflammation and the presence of excess fibrous tissue. At 3 months survival, remnants of chronic cortical infarcts were characterized by mild wedge-shaped loss of nervous tissue with mild gliosis of the remaining tissue in all subgroups.

Liqoseal was almost completely resorbed, although a moderate granulomatous foreign body reaction to sealant and suture remnants was still present at 6 months (Figure 5E,F). In the animals surviving 12 months, Liqoseal was not histologically visible anymore. A very mild granulomatous foreign body reaction to the suture remnants could still be observed in the animals with Liqoseal and without sealant (Figure 5G,H). In none of the animals was adhesion of Liqoseal through the dural defect to the underlying tissue observed. The dura and leptomeninges remained thickened in all animals with and without sealant.

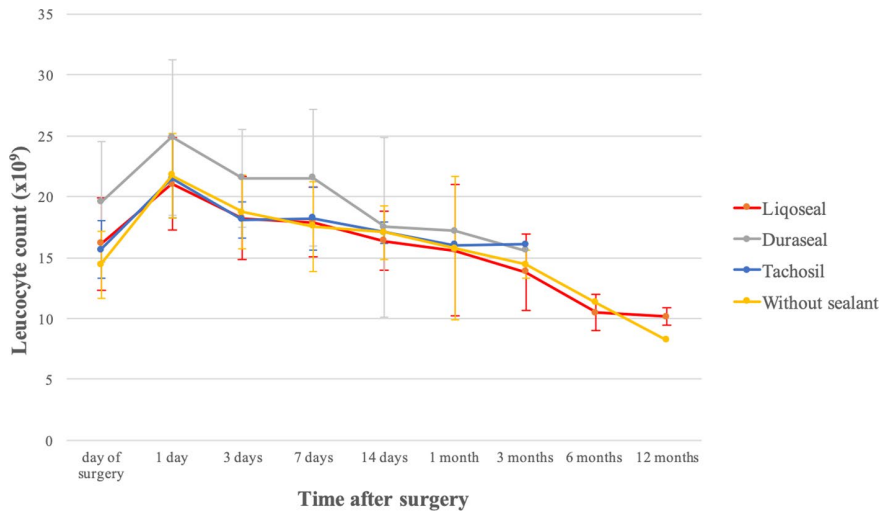


FIGURE 3 Mean leucocyte count during follow-up per subgroup

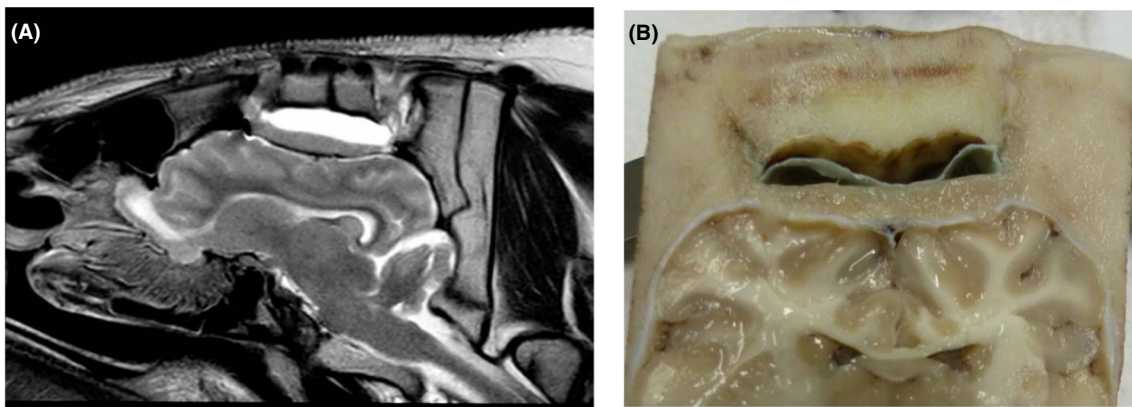


FIGURE 4 (A) 1-month survival animal with Liqoseal implantation. MRI T2 weighted image. Hyperintense area is visible, CSF is not excluded. (B) Macroscopical assessment of the same pig. The watertight blue layer was partially detached from the adhesive layer. The collection was most probably located under the blue layer

The histologically estimated degradation rate of Liqoseal was 60% at 1 month, 85% at 3 months, 90% at 6 months and 100% at 12 months.

4 | DISCUSSION

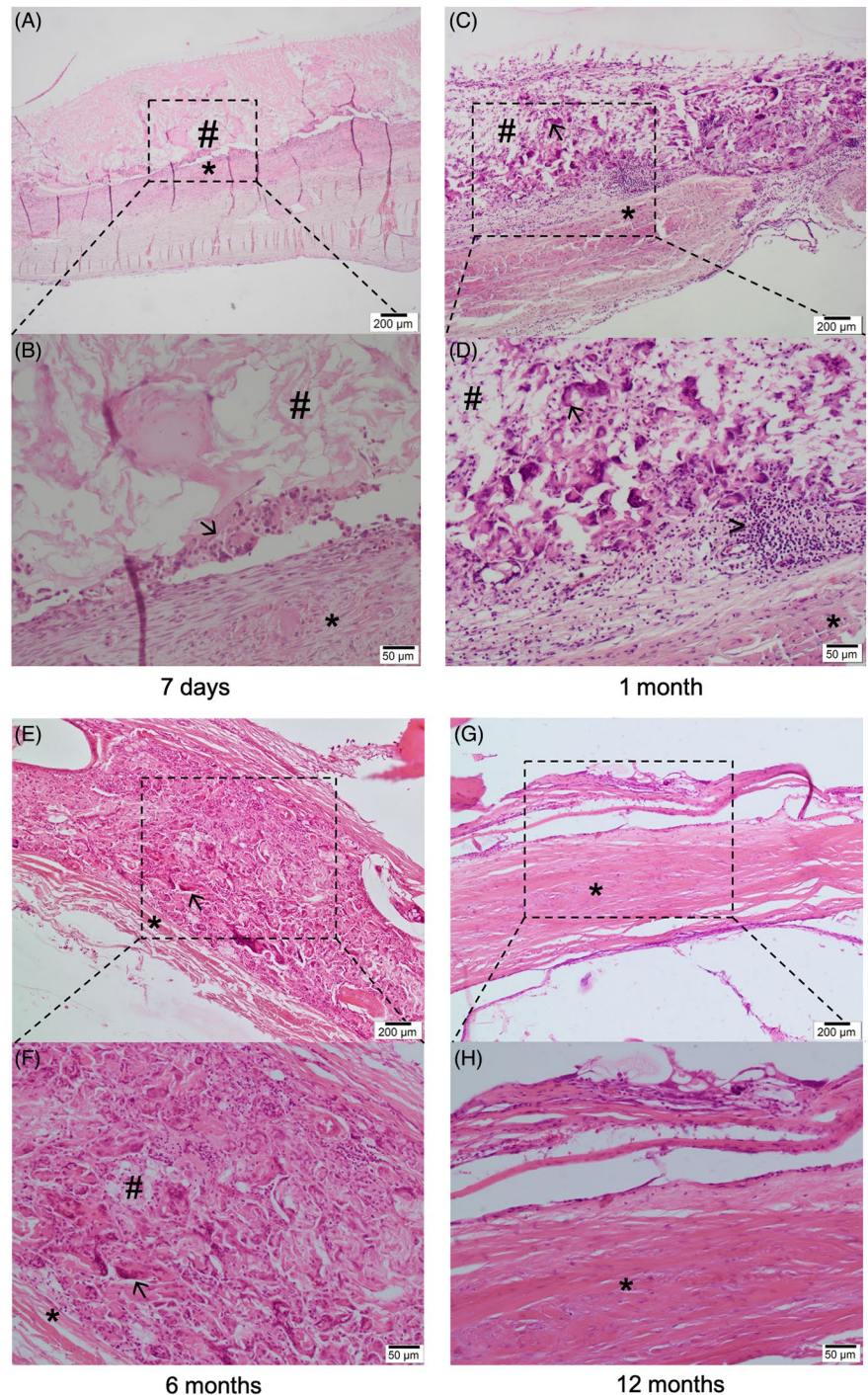
In this *in vivo* porcine study, we assessed the safety and biodegradability of a new dural sealant patch, Liqoseal (Polyganics B.V. Groningen, The Netherlands). Clinical, MRI and histological assessments of Liqoseal showed no swelling, a comparable foreign body reaction compared to Tachosil and Duraseal and complete resorption between 6 and 12 months after implantation. The slow degradation rate of Liqoseal ensures sufficient time for dural recovery, especially in large durotomies and dural defects. A disadvantage of the prolonged degradation of Liqoseal might be the concomitant prolonged foreign body reaction it induces. However, this reaction was not excessive compared to control groups. Other advantages of Liqoseal are the minimal preparation time, consistent thickness and its capacity of achieving a strong watertight seal over the dural defect.⁸

The cortical reaction in all animals, with and without sealant, seems to be induced by the craniotomy itself, since this reaction was also observed in the unsealed control animals. This reaction might be induced by compression of the footplate of the craniotome, use of suction and diathermy and cortical presence of bone dust.

Liqoseal is intended to be used as an adjunct to primary dural closure. However, no adhesion of Liqoseal to the arachnoid layer was observed on the side without sutural closure of the dura, suggesting that Liqoseal can be applied on larger dural defects. This should be confirmed by future *in vivo* studies that may evaluate the recovery rate of large dural defects when Liqoseal is applied.

In vivo studies evaluating dural sealants are limited. Manufacturers are not obliged to publish their preclinical data, but these data are useful for further studies. Moreover, these *in vivo* studies, until now mostly performed in dogs, are expensive and have ethical downsides.¹²⁻¹⁶ Preul et al. previously evaluated Duraseal in an *in vivo* canine model,¹³ and their findings were comparable to those of our study. In both studies, postoperative granulomatous foreign body reaction disappeared in tandem with the degradation of Duraseal, which appeared to be completely degraded in 3 months. Preul et al.

FIGURE 5 Histology of the dura mater of animals with Liqoseal at 7 days, 1 month, 6 months and 12 months postoperatively. The rectangles indicate the enlarged area of dura mater. * Dura mater, # sealant, → multinucleated giant cell, > lymphocytes. At 7 days, an increasing granulomatous foreign body reaction is visible in the periphery of the sealant (A and B). At 1 month, a granulomatous foreign body reaction is now visible in the sealant (C and D). The foreign body reaction to the sealant remnants is still present at 6 months (E and F). The amount of sealant material at 6 months is significantly decreased compared to survival pigs up 1 month. At 12 months, the Liqoseal is completely resorbed. The dura mater is thickened by a fibrous layer (G and H)



assessed also the burst pressure of Duraseal. We did not perform *in vivo* burst pressure tests, since we evaluated the burst pressure of Duraseal, Tachosil and Liqoseal in standardized *ex vivo* models.^{7,8} Moreover, a burst pressure assessment could disturb the histological preservation of the sealant and dura.

The current study has multiple strengths. First the model is very representative. Histological assessment of the dura of different species showed that porcine dura closely resembles the human dura.⁹ We therefore performed a relatively large bilateral craniotomy with a large exposure of the dura in which a representative amount of sealant was applied. A second strength was the strict protocol

adherence and objective results evaluation; the surgery was performed by a full trained neurosurgeon, the MRI follow up was done by a veterinary radiologist and the histological follow up was done by a veterinary pathologist.

The current study also has some limitations. First, not all clinically available sealants were included. We selected Duraseal and Tachosil because they had regulatory approval and represent both types of sealant groups, synthetic and fibrin sealants respectively. As we included both types of sealants and the number of animals per control sealant group was small, we did not include more control animals and followed the control animals up to three months only to minimise

expenditure and animal use. However, the small number of control animals may cause some bias. Second, it was impossible to exclude with certainty CSF in the epidural hematoma and fluid collection, since the β -transferrine test used in humans cannot be used in pigs. Although in the animals with epidural hematoma Liqoseal was tightly attached to the dura, the presence of CSF in the liquefied hematoma could not be excluded by a laboratory test. Third, although 3 sections from different parts of the dura and cortex were taken for histological evaluation, there is a chance that histological characteristics such as sealant remnant and durocortical adhesions were not sampled. Finally, the 4 different subgroups formed made it possible to compare Liqoseal with two different type of sealants and surgery without sealant at different time points and assess degradation profile. However, despite the relatively large total number of animals included in this study, this led to relative small numbers of animals per subgroup.

This study showed no Liqoseal related safety issues in an animal model. However, this porcine craniotomy model has its limitations and cannot replace a human trial. First, although the immune system of the pig highly resembles that of humans (>80%), there are differences which may have led to a different foreign body reaction compared to humans.^{17,18} In addition, this study cannot replace human studies regarding the performance of Liqoseal, because the craniotomies and durotomies that can be performed in the pigs are relatively small compared to humans. This may lead to a smaller risk of CSF leakage. Besides, although the pigs were monitored for their movements and appetite, small and transient behavioral changes could have been missed. In contrast, humans can be monitored more accurately.

Therefore, clinical trials are needed to further confirm the safety and performance of Liqoseal before routine clinical application. Although an *ex vivo* study of Liqoseal showed strong adhesion to the dura,⁸ clinical trials are needed to study the effectiveness of Liqoseal in preventing postoperative CSF leakage.

5 | CONCLUSION

In this *in vivo* study, we confirmed the safety of Liqoseal in a pig craniotomy model. Liqoseal was completely resorbed between 6 and 12 months. The dural reaction induced by Liqoseal was comparable with the reaction induced by Duraseal and Tachosil. A first in-human clinical trial should further investigate the safety and effectiveness of Liqoseal for intracranial application in humans.

ACKNOWLEDGMENTS

None.

CONFLICT OF INTEREST

T.P.C. van Doormaal, MD PhD is consultant for Polyganics B.V. A. Kinaci's PhD position was funded by Polyganics B.V.

AUTHOR CONTRIBUTIONS

AK: contributed to the conception and design, acquisition of data, analysis and interpretation of data, drafting and revising the

manuscript. WB: acquisition of data, analysis and interpretation of data, drafting and revising the manuscript. SVT: contributed to the conception and design, acquisition of data, drafting and revising the manuscript. SR: contributed to the conception and design, acquisition of data, drafting and revising the manuscript. AvZ: contributed to the conception and design, drafting and revising the manuscript. TvD: contributed to the conception and design, analysis and interpretation of data, drafting and revising the manuscript.

ORCID

Ahmet Kinaci  <https://orcid.org/0000-0002-6098-5935>

REFERENCES

- Kinaci A, Algra A, Heuts S, O'Donnell D, van der Zwan A, van Doormaal T. Effectiveness of dural sealants in prevention of cerebrospinal fluid leakage after craniotomy: a systematic review. *World Neurosurg.* 2018;118:368-376.e1. doi:10.1016/j.wneu.2018.06.196
- Chauvet D, Tran V, Mutlu G, George B, Allain J-M. Study of dural suture watertightness: an in vitro comparison of different sealants. *Acta Neurochir.* 2011;153(12):2465-2472. doi:10.1007/s00701-011-1197-9
- Giovanni S, Della Pepa GM, La Rocca G, et al. Galea-pericranium dural closure: can we safely avoid sealants? *Clin Neurol Neurosurg.* 2014;123:50-54. doi:10.1016/j.clineuro.2014.05.005
- Green AL, Arnaud A, Batiller J, et al. A multicentre, prospective, randomized, controlled study to evaluate the use of a fibrin sealant as an adjunct to sutured dural repair. *Br J Neurosurg.* 2015;29(1):11-17. doi:10.3109/02688697.2014.948808
- Grotenhuis JA. Costs of postoperative cerebrospinal fluid leakage: 1-year, retrospective analysis of 412 consecutive nontrauma cases. *Surg Neurol.* 2005;64(6):490-493, discussion 493-494. doi:10.1016/j.surneu.2005.03.041
- Kinaci A, Moayeri N, van der Zwan A, van Doormaal TPC. Effectiveness of sealants in prevention of cerebrospinal fluid leakage after spine surgery: a systematic review. *World Neurosurg.* 2019;127:567-575.e1. doi:10.1016/j.wneu.2019.02.236
- van Doormaal T, Kinaci A, van Thoor S, Redegeld S, Bergmann W, Van Der Zwan A. Usefulness of sealants for dural closure: evaluation in an in vitro model. *Oper Neurosurg.* 2018;15(4):425-432.
- Kinaci A, van Thoor S, Redegeld S, Tooren M, van Doormaal TPC. Ex vivo evaluation of a multilayered sealant patch for watertight dural closure: cranial and spinal models. *J Mater Sci Mater Med.* 2021;32(8):85. doi:10.1007/s10856-021-06552-4
- Kinaci A, Bergmann W, Bleyers RL, van der Zwan A, van Doormaal TP. Histologic comparison of the dura mater among species. *Comp Med.* 2020;70(2):170-175. doi:10.30802/AALAS-CM-19-000022
- Kacher DF, Frerichs K, Pettit J, Campbell PK, Meunch T, Norbash AM. DuraSeal magnetic resonance and computed tomography imaging: evaluation in a canine craniotomy model. *Neurosurgery.* 2006;58(1 Suppl):ONS140-ONS-147; discussion ONS140-147. doi:10.1227/01.NEU.0000193518.71825.D7
- Toro A, Mannino M, Reale G, Di Carlo I. TachoSil use in abdominal surgery: a review. *J Blood Med.* 2011;2:31-36. doi:10.2147/JBM.S13061
- Alleyne CH, Cawley CM, Barrow DL, et al. Efficacy and biocompatibility of a photopolymerized, synthetic, absorbable hydrogel as a dural sealant in a canine craniotomy model. *J Neurosurg.* 1998;88(2):308-313. doi:10.3171/jns.1998.88.2.0308
- Preul MC, Bichard WD, Muench TR, Spetzler RF. Toward optimal tissue sealants for neurosurgery: use of a novel hydrogel sealant in a canine durotomy repair model. *Neurosurgery.* 2003;53(5):1189-1198; discussion 1198-1199. doi:10.1227/01.neu.0000089481.87226.f7

14. Preul MC, Campbell PK, Bichard WD, Spetzler RF. Application of a hydrogel sealant improves watertight closures of duraplasty onlay grafts in a canine craniotomy model. *J Neurosurg.* 2007;107(3):642-650. doi:10.3171/JNS-07/09/0642
15. Hutchinson RW, Mendenhall V, Abutin RM, Muench T, Hart J. Evaluation of fibrin sealants for central nervous system sealing in the mongrel dog durotomy model. *Neurosurgery.* 2011;69(4):921-928; discussion 929. doi:10.1227/NEU.0b013e318222ad63
16. Lewis KM, Sweet J, Wilson ST, Rousselle S, Gulle H, Baumgartner B. Safety and efficacy of a novel, self-adhering dural substitute in a canine supratentorial durotomy model. *Neurosurgery.* 2018;82(3):397-406. doi:10.1093/neuros/nyx216
17. Pabst R. The pig as a model for immunology research. *Cell Tissue Res.* 2020;380(2):287-304. doi:10.1007/s00441-020-03206-9
18. Dawson H. A comparative assessment of the pig, mouse and human genomes: structural and functional analysis of genes involved in immunity and inflammation. In: McAnulty PA, Dayan A, Hastings KH,

Ganderup NC, eds. *The Minipig in Biomedical Research.* CRC Press; 2011: 323-342. doi:10.1201/b11356-28

SUPPORTING INFORMATION

Additional supporting information may be found in the online version of the article at the publisher's website.

How to cite this article: Kinaci A, Bergmann W, van Thoor S, Redegeld S, van der Zwan A, van Doormaal TPC. Safety and biodegradability of a synthetic dural sealant patch (Liqoseal) in a porcine cranial model. *Anim Models Exp Med.* 2021;4:398-405. doi:[10.1002/ame2.12184](https://doi.org/10.1002/ame2.12184)