



Case report

Reduced corneal endothelial cell density after toxic anterior segment syndrome (TASS) caused by inadvertent intraocular ointment migration: A case report

Karim Mohamed-Noriega^{*}, Fernando Guerra-Lorenzo, Jibrán Mohamed-Noriega, Gerardo Villarreal-Mendez, Fernando Morales-Wong, Jesús Mohamed-Hamsho

Department of Ophthalmology, University Hospital and Faculty of Medicine, Autonomous University of Nuevo León (UANL), Monterrey, 64460, Mexico

ARTICLE INFO

Keywords:

TASS
Cataract complication
Phacoemulsification
Endothelial corneal density
Case report

ABSTRACT

Introduction and importance: Toxic anterior segment syndrome (TASS) is an acute sterile inflammation of the anterior segment which may occur after surgery. This case presents endothelial cell density (ECD) loss due to months of TASS caused by intraocular migration of ocular ointment. The chronicity of this case and the clinical consequences are rare in the literature.

Case presentation: A Colombian 71-year-old man developed TASS secondary to intraocular ointment migration after uneventful cataract surgery with phacoemulsification and intraocular lens placement in the capsular bag. The main complaint for the patient was a chronic red eye, no pain or visual disturbance were reported, rheumatologic diseases were discarded. It was documented the presence of intraocular ointment in the anterior chamber, over the iris and in the anterior chamber angle. The ECD was reduced secondary to TASS and the long-term presence of ointment moving in the anterior chamber, so it had to be removed.

Clinical discussion: It is important to avoid using ocular ointment after intraocular surgeries to avoid the risk of ointment migration into the anterior chamber. Intraocular ointments should be removed promptly to reduce ECD loss as documented in the present case report in which after ointment elimination ECD remains stable for 7 years.

Conclusion: Topical ointments should not be used after routine cataract surgery because of the risk of intraocular ointment migration and subsequent risk of developing TASS and reduced ECD.

1. Introduction and importance

Toxic anterior segment syndrome (TASS) is a noninfectious condition that presents itself as anterior segment inflammation within days of surgery and is responsive to topical steroids [1]. TASS most often occurs after cataract surgery [2]. 3 main categories that can cause TASS have been identified: extraocular substances that enter the anterior chamber during or after surgery, products introduced into the anterior chamber as part of the surgery, and irritants on instruments surfaces [3]. Most cases will respond to topical steroids given every 30–60 min for the first 3 days, with gradual tapering [4]. This case occurred in the Department of Ophthalmology from the University Hospital and Faculty of Medicine

at the Autonomous University of Nuevo Leon (UANL), Monterrey, Mexico. It is an example of the long-term consequences of intraocular ointment retention with an emphasis on corneal endothelial cell reduction after cataract surgery, a similar case with a chronic presentation was not found in the literature. This is an interesting case because it shows a rare presentation of TASS.

2. Method

This case report has been reported in line with the SCARE 2020 guidelines [5].

Abbreviations: AC, Anterior Chamber; BSS, Balance salt solution; BCVA, Best corrected visual acuity; CRP, C-reactive protein; ECD, Endothelial cell density; ESR, erythrocyte sedimentation rate; OD, Oculus Dexter; OS, Oculus Sinister; q.1.h/q.h, Every hour; q.3.h, Every 3 h; q.6.h, Every 6 h; q.h.s, each night at bedtime; q.i.d, four times a day; TASS, Toxic anterior segment syndrome; UANL, Autonomous University of Nuevo León; UCVA, Uncorrected distance visual acuity.

^{*} Corresponding author at: Avenida Francisco I Madero 3501 y Avenida José Eleuterio González (Gonzalitos) S/N, Colonia Mitras Centro, Monterrey, Nuevo León 64460, Mexico.

E-mail address: karim.mohamednrg@uanl.edu.mx (K. Mohamed-Noriega).

<https://doi.org/10.1016/j.ijscr.2022.107029>

Received 13 February 2022; Received in revised form 29 March 2022; Accepted 31 March 2022

Available online 3 April 2022

2210-2612/© 2022 The Authors. Published by Elsevier Ltd on behalf of IJS Publishing Group Ltd. This is an open access article under the CC BY-NC-ND license (<http://creativecommons.org/licenses/by-nc-nd/4.0/>).

3. Case presentation

A Colombian 71-year-old man was referred to the ophthalmology department for right eye cataract surgery. Best-corrected visual acuity (BCVA) was 20/100 and 20/20 in his right and left eye respectively. Except for the presence of a cataract, the eye was otherwise normal. No systemic diseases or medication were reported, no surgical procedure was performed before. The patient denied any allergies, no relevant genetic or family history was documented. The patient was mentally healthy, denied use of tobacco, alcohol, or recreational drug use. The patient underwent uneventful phacoemulsification cataract extraction with in-the-bag intraocular lens placement performed by an experienced ophthalmologist (GVM). The main port was performed nasally at 11 o'clock with a 3.0 mm keratome, side port was performed temporally with a 15° blade. Phacoemulsification was performed with Infiniti Phaco System (Alcon, TX, USA). A foldable 1-piece intraocular lens (Bausch & Lomb, ADAPT-AO) was placed in the capsular bag, viscoelastic was removed, the anterior chamber was formed with balanced salt solution (BSS), and incisions were self-sealed with BSS. Surgery time was 13 min, reported ultrasound time was 6:04 s. Topical dexamethasone and tobramycin ointment (Trazidex®, Sophia, Mexico) and an eye patch were applied. No complications were reported.

On the first postoperative day, uncorrected distance visual acuity (UDVA) was 20/40, intraocular pressure (IOP) was 10 mmHg. At slit lamp examination, moderate inflammation was observed with diffuse conjunctival hyperemia and anterior chamber cells. An unknown intraocular foreign body was observed in the anterior chamber at 12 o'clock. The initial thought was that there were clumps of inflammatory cells or debris attached. The cornea was clear with mild Descemet folds and medium keratic precipitates. Dexamethasone eye drops (Dexafirin ofteno, Sophia, Mexico) q.1.h.; Ciprofloxacin ophthalmic 0.03% eye drops (Sophixin, Sophia, Mexico), 4 times a day and Dexamethasone and

tobramycin ointment (Trazidex 0.1%/0.3%, Sophia, Mexico) daily at bedtime were prescribed.

One week after surgery, UDVA was 20/25. Anterior segment inflammation improved to 1 + cells in the anterior chamber. Ciprofloxacin drops were suspended two weeks after surgery, Dexamethasone was tapered for 1 month and ointment continued for 1 month. Re-inflammation was observed in posterior visits every time steroid drops were tapered and got better when they were restarted. Removal of the foreign body was proposed, but the patient refused the procedure because of the good visual acuity (20/25) and absence of symptoms, the only complaint was a mild red eye. Topical steroids were on and off modulated depending on the inflammation for 6 months. Non-granulomatous anterior uveitis was the main differential diagnosis. Erythrocyte sedimentation rate (ESR) was 24 mm/h, C-reactive protein (CRP) and antinuclear antibodies were between normal limits. Rheumatological diseases were discarded after laboratories (besides ESR) and physical exam was normal.

At 6 months after surgery, the foreign body in the anterior chamber was explored with detail: gonioscopy revealed a freely mobile encapsulated material in the angle, and when the patient was in supine position the foreign body moved to the apex of the cornea (Figs. 1–2 and supplemental video 1). The foreign body was touching continuously the endothelium. It was concluded that the foreign bodies in the anterior chamber and angle were retained ointment. The patient was diagnosed with TASS secondary to Dexamethasone and Tobramycin ointment migration into the anterior chamber, an adverse event classified as grade IIIa in the Clavien-Dindo Classification. Endothelial cell density (ECD) was measured, it was 799 cells/mm² in the right eye and 2639 in the left eye. Surgery was proposed again.

After a preoperative assessment by an anesthesiologist, medical history had no notable findings. The surgery was performed by another experienced surgeon (KMN) in the ambulatory operating room. The

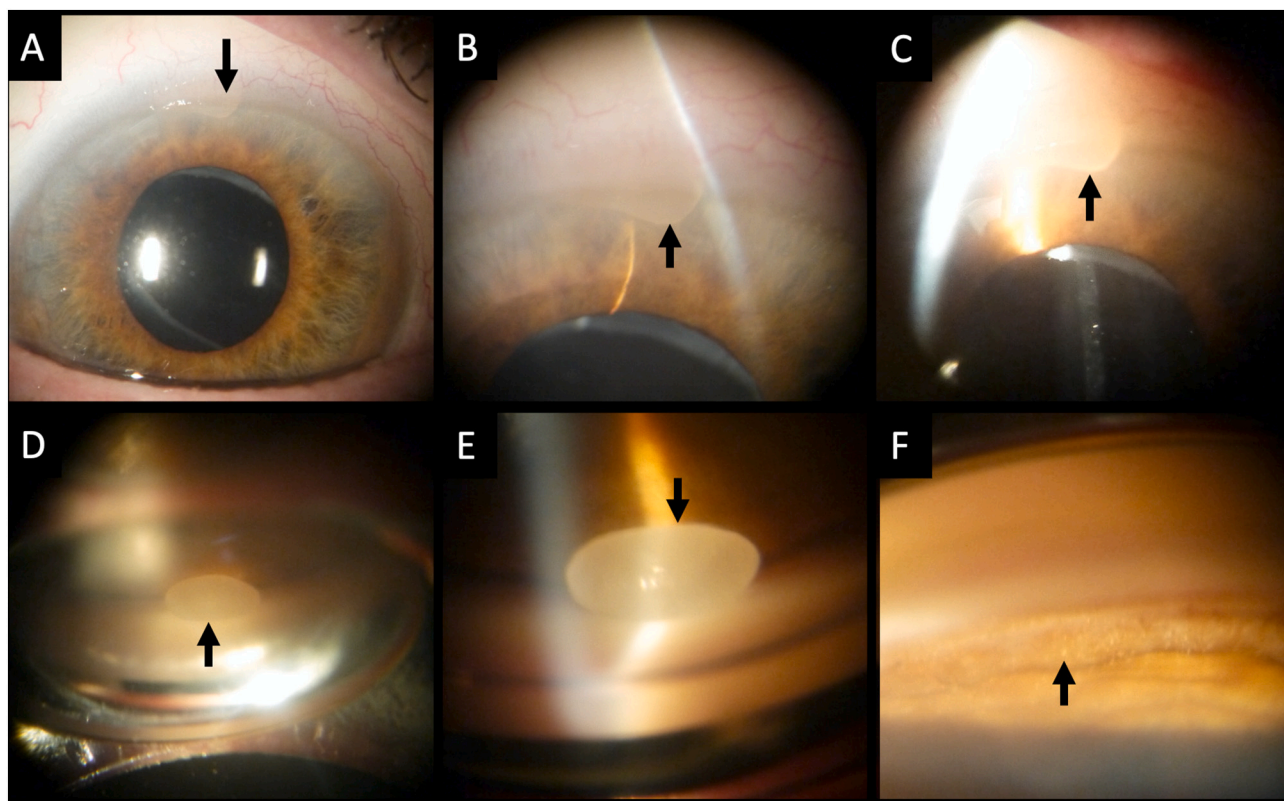


Fig. 1. Retained ointment in anterior chamber observed in slit lamp and gonioscopy.

A: Barely visible ointment in the anterior chamber at 12 o'clock. B–C: Ointment in the anterior chamber with round shape. D–E: The ointment in the iridocorneal angle is in contact with the corneal endothelium. F: Small ointment particles over the iris blocking trabecular meshwork.

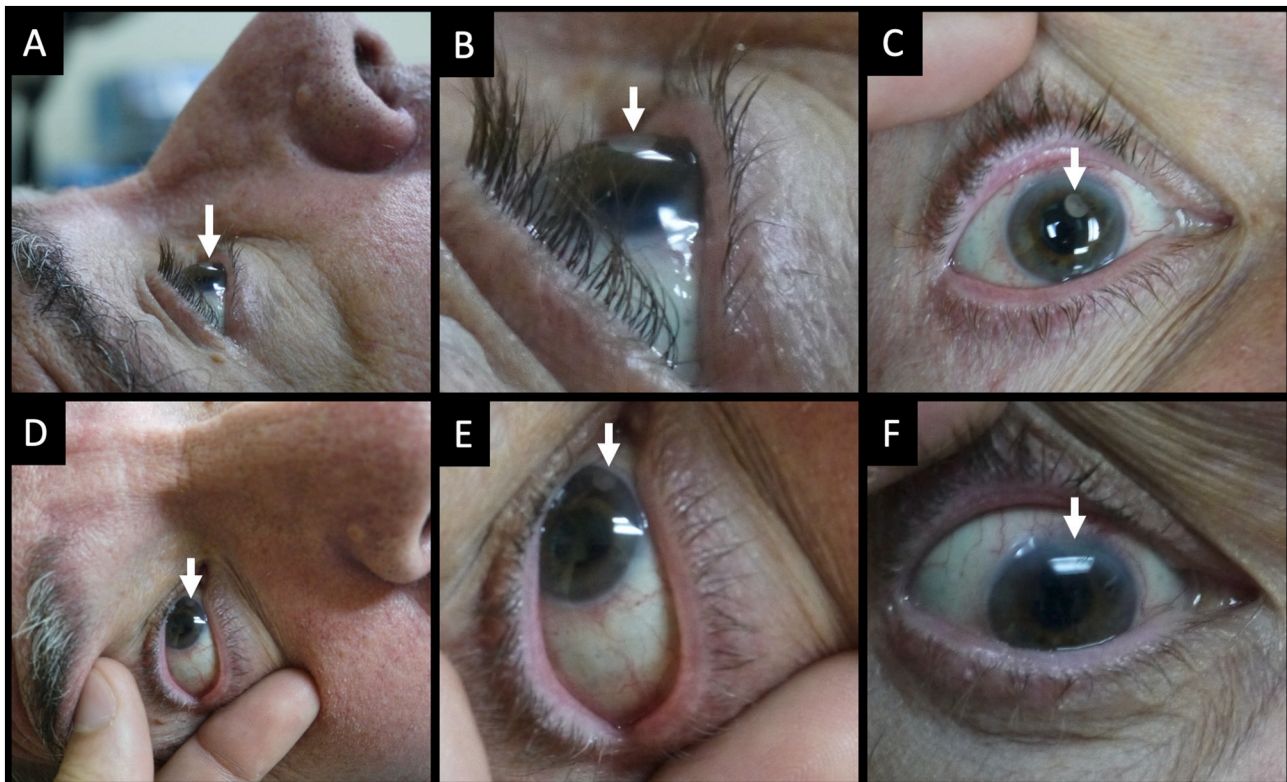

Fig. 2. Patient in supine position showing the free movement of the ointment in the anterior chamber.

A–B: Side pictures of the patient in supine position showing the ointment at the top of the anterior chamber touching the endothelium. B: High magnification of panel A. C: Frontal picture of the patient in supine position with gaze at primary position. D: When the patient is in supine position looking to the left, the ointment moves to the nasal side. E: High magnification of panel E, F: when the patient is in fowler position with gaze at primary position, the ointment moves to 12 o'clock. White arrows: ointment.

patient was prepared in supine position, with pharmacological sedation with midazolam and fentanyl (no dose recorded) and retrobulbar block (3 ml of 50 mg/10 ml bupivacaine and 2 ml of 20 mg/ml xylocaine). Anterior chamber ointment was eliminated by irrigation and aspiration seven months after cataract surgery. No changes in the surgical plan or adverse events were reported.

On the first post-operative day, UDVA was 20/160. Dexamethasone drops (Dexafirin ofteno, Sophia, Mexico), 1 drop q.h; Ciprofloxacin ophthalmic 0.03% eye drops (Sophixin, Sophia, Mexico), 1 drop q.6 h for 2 weeks were prescribed. The steroids were slowly tapered for 6 weeks. One month after ointment removal, BCVA was 20/20, no anterior chamber inflammation was observed, no anterior chamber cells were observed, no hyperemia and no keratic precipitates were observed, the patient was discharged at this point.

ECD before ointment removal was 799 cells/mm² in the right eye and 2639 in the left eye. The ECD remained stable after ointment removal. After 1, 2, 4 and 7 years was 718, 808, 777 and 781 cells/mm² respectively (Fig. 3). These tests were made in the annual ophthalmologic examination.

4. Clinical discussion

Toxic anterior segment syndrome (TASS) is an acute and noninfectious inflammation of the anterior segment [6]. Depending on the severity of inflammation, other symptoms may be present, such as pain, conjunctival injection or chemosis, hypopyon, corneal edema, keratic precipitates, anterior vitreous opacities and visual deterioration [7], or can course uneventful, with no apparent reaction [8]. Most cases have been reported as occurring after cataract surgery. Many substances can cause TASS, which includes residues left behind by items used during cleaning and sterilization of surgical instruments, irrigating solutions

with incorrect pH, osmolarity or ionic composition, preservatives, stabilizing agents, denatured ophthalmic viscosurgical devices, endotoxins, intraocular medications at toxic doses, and ointments [9]. The most identified risk factors for TASS arise from problems with the instrument-cleaning process, of these, inadequate flushing of the handpieces, the use of enzymatic detergents, and the use of ultrasonic baths are the most prevalent. The reuse of cannulas is also frequently reported and can increase the risk for TASS [3].

Antibiotics and steroid ointments are used topically at the end of intraocular surgery, and inadvertent entry into the eye has been reported [10]. Dispersed ointment droplets or consolidated globules in the anterior chamber (AC) can sometimes be visualized on the clinical examination [10]. In the present case, the ointment entered the anterior chamber through the clear corneal wound. Factors that may have contributed to the migration of ointment include pressure patching, eye rubbing, and eyelid squeezing. It took 7 months for the patient to accept the removal of the ointment from the anterior chamber. The patient did not want the surgery because he had good visual acuity (20/25) at the beginning. From the patient's perspective, he preferred to wait if topical drops were enough to recover. The patient had good application adherence and tolerance to the topical treatment, but it was not enough. When the ECD loss was documented, it was strongly recommended the surgery, due to the risk of further endothelial loss and the patient accepted it. After removal of the ointment, ECD remained stable. A limitation of this case report is that ECD is not documented before cataract surgery, but if we compared ECD of OD and OS, it was remarkably asymmetrical (Fig. 3). The strengths of this case are the well-documented clinical information during the inflammation period and 7 years after the surgery.

The usual treatment for toxicity from retained ointment is the removal of it [11]. In this case, episodes of flare-up recurred after

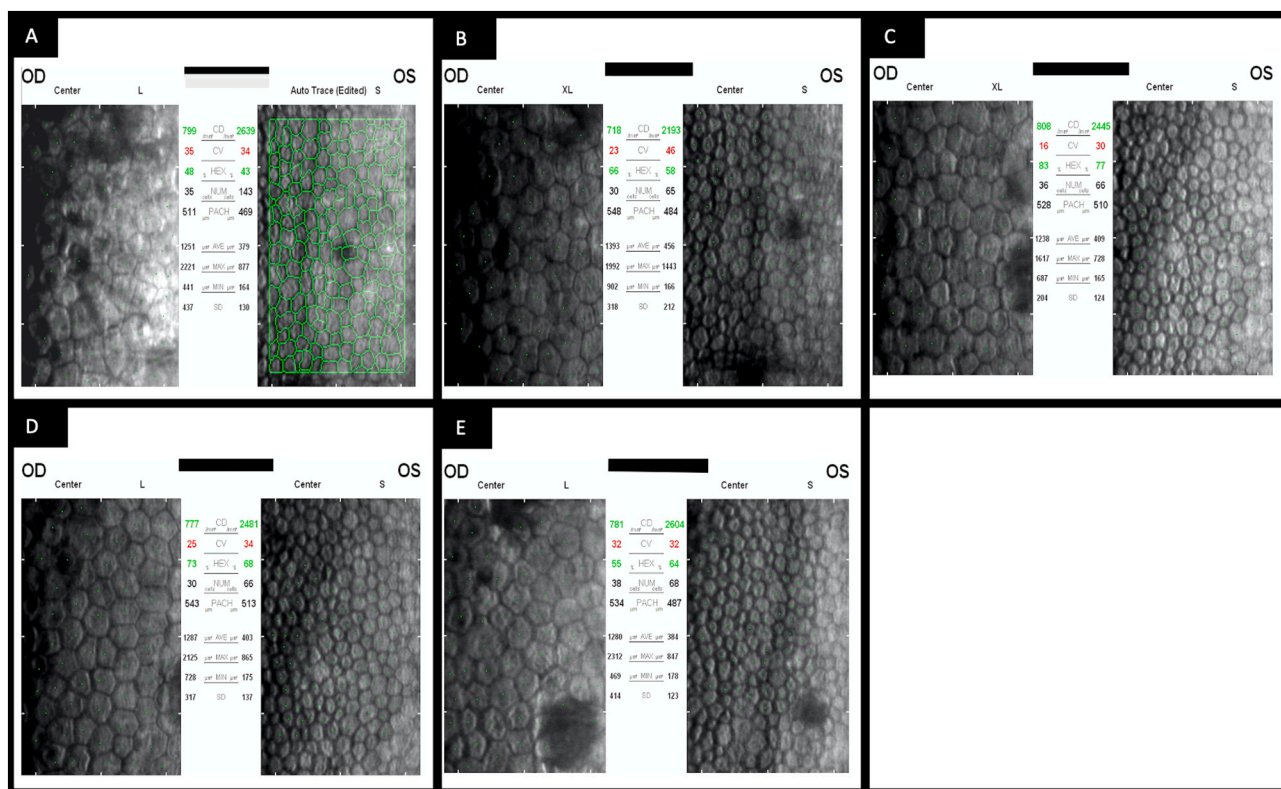


Fig. 3. Long-term endothelial cell density (ECD) stability after anterior segment ointment removal. A: ECD before ointment removal. B, C, D, E: ECD after ointment removal at 1, 2, 4 and 7 years respectively.

months on topical steroids. However, no more flare-ups appear after the ointment removal. This case highlights the importance of prompt surgical removal of any ointment irrespective of the symptoms or level of inflammation.

Because of the risk of intraocular migration, ointments should not be used after cataract surgery. At the time of the patient's surgery, it was standard practice to use ointments after cataract surgery, but from this case, we discontinued this practice because of the risk of intraocular migration and subsequent TASS and ECD loss.

5. Conclusion

Topical ointment after cataract surgery can inadvertently migrate to the anterior chamber, with subsequent TASS development and corneal endothelial cell damage. Therefore, topical ointments should not be used after routine cataract surgery.

Supplementary data to this article can be found online at <https://doi.org/10.1016/j.ijscr.2022.107029>.

Sources of funding

None.

Ethical approval

All procedures performed were in accordance with the ethical standards of the institutional committee and with the 1964 Helsinki declaration and its later amendments or comparable ethical standards.

Informed consent

Written informed consent was obtained from the patient for publication of this case report and accompanying images. A copy of the

written consent is available for review by the Editor-in-Chief of this journal on request.

Research registration

N/a.

Guarantor

Professor Karim Mohamed-Noriega, MD, Dr. Med Ophthalmology Department, University Hospital and Faculty of Medicine Autonomous University of Nuevo Leon (UANL).

Address: Avenida Francisco i Madero 3501 y Avenida José Eleuterio González (Gonzalitos) S/N, Colonia Mitras Centro. Monterrey, Nuevo León, 64460, México.

Telephone: +52 (81) 8346 9259

Email: karim.mohamednrg@uanl.edu.mx

Provenance and peer review

Not commissioned, externally peer-reviewed.

CRediT authorship contribution statement

Karim Mohamed-Noriega: Conceptualization, patient evaluation, formal analysis, investigation, methodology, project administration, supervision,

original draft; writing, review, and editing; data curation, supervision and validation.

Fernando Guerra-Lorenzo: Conceptualization, data curation, formal analysis, investigation, methodology, writing original draft, writing, review and editing.

Jibrán Mohamed-Noriega: Conceptualization, patient evaluation,

formal analysis, investigation, methodology, supervision, validation, visualization, review and editing.

Gerardo Villarreal-Méndez: Patient evaluation, review and editing.

Fernando Morales-Wong: Investigation, validation, review and editing.

Jesús Mohamed-Hamsho: Project administration, resources, investigation, methodology, supervision, validation, review and editing.

Declaration of competing interest

None.

Acknowledgments

None.

References

- [1] E.J. Jun, S.K. Chung, Toxic anterior segment syndrome after cataract surgery, *J Cataract Refract Surg* 36 (2) (2010) 344–346, <https://doi.org/10.1016/j.jcrs.2009.07.052>.
- [2] C.Y. Park, J.K. Lee, R.S. Chuck, Toxic anterior segment syndrome-an updated review, *BMC Ophthalmol.* 18 (1) (2018) 1–9, <https://doi.org/10.1186/s12886-018-0939-3>.
- [3] A.N. Shukla, M.K. Daly, C.J. McKnight, T. Freddo, Intraocular ophthalmic ointment following anterior segment surgery, *J Cataract Refract Surg* 37 (12) (2011) 2218–2221, <https://doi.org/10.1016/j.jcrs.2011.09.015>.
- [4] S.P. Holland, D.W. Morck, T.L. Lee, Update on toxic anterior segment syndrome, *Curr. Opin. Ophthalmol.* 18 (1) (2007) 4–8, <https://doi.org/10.1097/ICU.0b013e3280117d0c>.
- [5] R.A. Agha, T. Franchi, C. Sohrabi, et al., The SCARE 2020 guideline: updating consensus surgical CASE REport (SCARE) guidelines, *Int. J. Surg.* 84 (2020) 226–230, <https://doi.org/10.1016/j.ijsu.2020.10.034>.
- [6] N. Sevimli, R. Karadag, O. Cakici, H. Bayramlar, S. Okumus, U. Sari, Toxic anterior segment syndrome following deep anterior lamellar keratoplasty, *Arq. Bras. Oftalmol.* 79 (5) (2016) 330–332, <https://doi.org/10.5935/0004-2749.20160094>.
- [7] N.Y. Kim, Y.C. Yoo, H. Park, Y.D. Choi, C.Y. Kim, S.J. Bai, The effect of dexmedetomidine on intraocular pressure increase in patients during robot-assisted laparoscopic radical prostatectomy in the steep trendelenburg position, *J. Endourol.* 29 (3) (2015) 310–316, <https://doi.org/10.1089/end.2014.0381>.
- [8] M. Humayun, C.C. Gottlieb, P.E. Rafuse, Intraocular ophthalmic ointment following clear corneal phacoemulsification: clinical implications, *J Cataract Refract Surg* 32 (12) (2006) 2135–2138, <https://doi.org/10.1016/j.jcrs.2006.08.034>.
- [9] S. Cetinkaya, Z. Dadaci, H. Aksoy, N.O. Acir, H.I. Yener, E. Kadioglu, Toxic anterior-segment syndrome (TASS), *Clin. Ophthalmol.* 8 (2014) 2065–2069, <https://doi.org/10.2147/OPTH.S71541>.
- [10] R.S. Haddad, H.I. Salti, Z. Habbal, A.M. Mansour, Optical coherence tomography findings in anterior chamber ointment globule after phacoemulsification, *Case Rep. Ophthalmol.* 6 (3) (2015) 469–476, <https://doi.org/10.1159/000442970>.
- [11] R.N. Sanders, D.B. Warner, L.R. Adams, A.A. Sallam, S.H. Uwaydat, Ocular complications from retained intraocular ointment discovered 33 months after cataract surgery, *Case Rep. Ophthalmol.* 9 (3) (2018) 487–492, <https://doi.org/10.1159/000495002>.