

# Bilateral Pectoralis Minor Muscle Variant.

Anton Alder<sup>1</sup>, Kevin Kelliher<sup>2</sup>, and David Terfera<sup>1</sup>

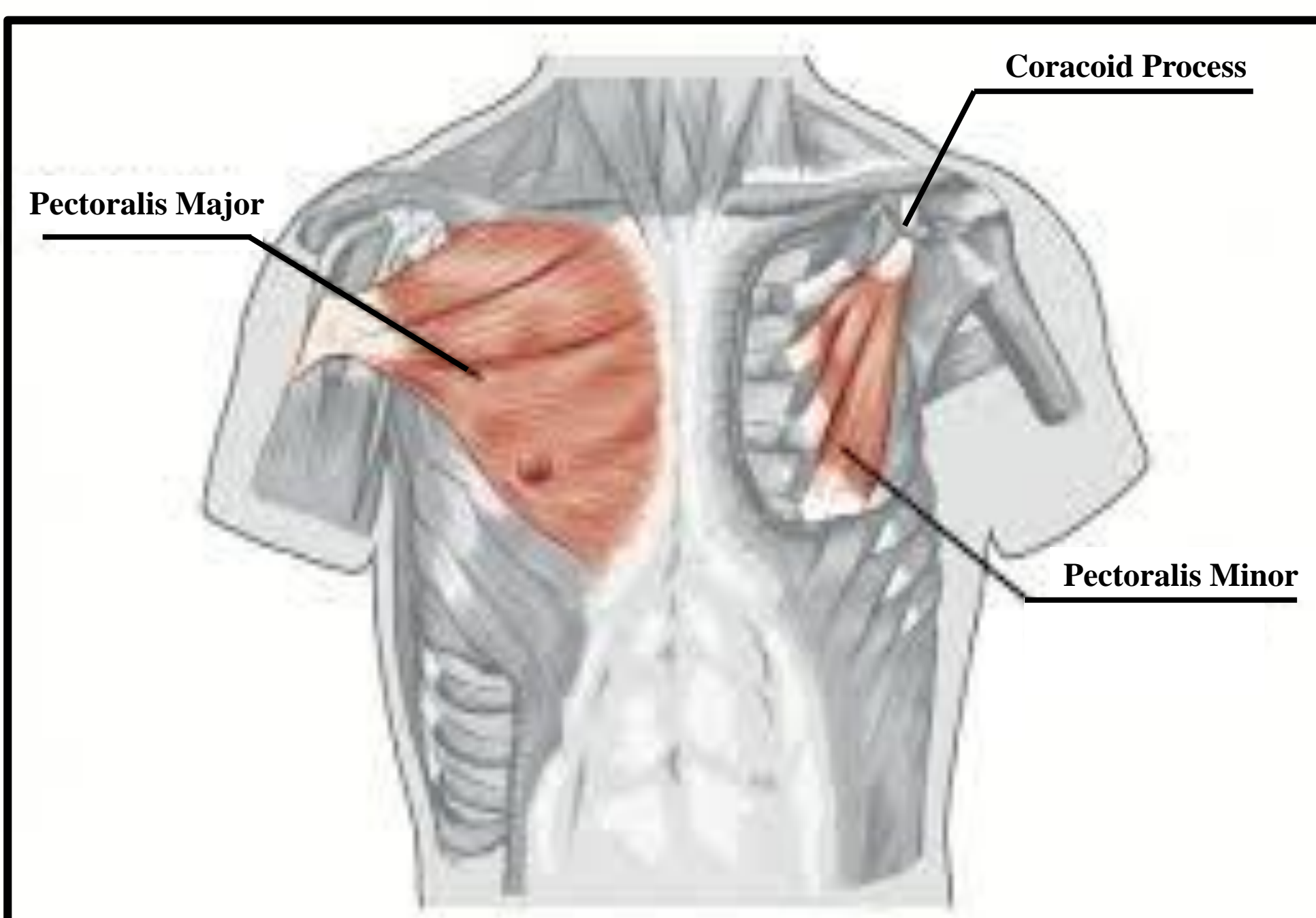
<sup>1</sup> College of Naturopathic Medicine, University of Bridgeport, Bridgeport, CT ; <sup>2</sup> College of Chiropractic, University of Bridgeport, Bridgeport CT.

## Abstract

During a routine anatomical dissection we discovered an aberrant muscle slip associated with the pectoralis minor muscle that occurred bilaterally. The muscle slips originated from ribs five or six and inserted into the tendon of the coracobrachialis in close proximity to the coracoid process of the scapula. Fibers of the muscle slip also blended with the pectoralis minor muscle on its lateral border and were innervated by the medial pectoral nerve. Many of the muscular variants reported in the literature are discovered during routine cadaveric dissection and are of great interest to anatomists and developmental biologists. However, recognizing and understanding both normal and variant anatomy of the anterior thorax and axilla is of critical importance to health care professionals when diagnosing, imaging, or surgically treating these areas. It is not uncommon to observe known anatomical variants during cadaveric dissection, however many of these variants are not commonly discussed during the regular clinical coursework of health care professionals. The result is a gap of knowledge for clinicians who are more likely to confuse the variant with some form of pathology. This may result in improper or delayed treatment. For this reason it is important to add variants such as the one in this case to the anatomical record.

## Background

The pectoralis major and minor are the two primary muscles of the pectoral region. The figure below depicts how these muscles would typically present in most people. The pectoralis minor lies underneath the pectoralis major and typically courses from the 3rd-5th rib to the coracoid process, though a normal variant of this could originate from the 2<sup>nd</sup>-4<sup>th</sup> rib. On the right the pectoralis major muscle has been removed to reveal the pectoralis minor muscle underneath, attaching to ribs 3, 4 and 5 near the costochondral junctions. The pectoralis minor serves as a major anatomical landmark useful in locating branches of an important nervous complex called the brachial plexus as well as defining parts of the axillary artery and levels of pectoral axillary lymph nodes. While variants to the pectoralis major are somewhat common, variants to the pectoralis minor are considerably more rare.



## Method and Results

During a routine dissection of the anterior thorax of a female cadaver, bilateral musculotendinous slips associated with the pectoralis minor muscles were observed. Both the left and right pectoralis minor muscles originated from ribs two through four and inserted on the fascia of the coracobrachialis (Figure 1A). Lateral to both the right and left pectoralis minor muscles, a thin long musculotendinous slip attached to the ribs (Figure 1A). The left musculotendinous slip originated from ribs five and six and measured 21 cm. The musculotendinous slip on the right side originated from rib five and measured 18 cm. Due to the lack of preservation during the dissection process, it is unclear if the right musculotendinous slip also extended to rib six. The insertion of the right and left tendinous portion of the musculotendinous slips was to the fascia of the coracobrachialis near its attachment to the coracoid process (Figure 1B). Fibers from each musculotendinous slip blended with the adjacent belly of the pectoralis minor muscles along its lateral border (Figure 1A and B). The pectoralis minor muscles were innervated by the medial pectoral nerve. Branches of the medial pectoral nerve extended beyond the pectoralis minor muscles and innervated the musculotendinous slips (Figure 1C).

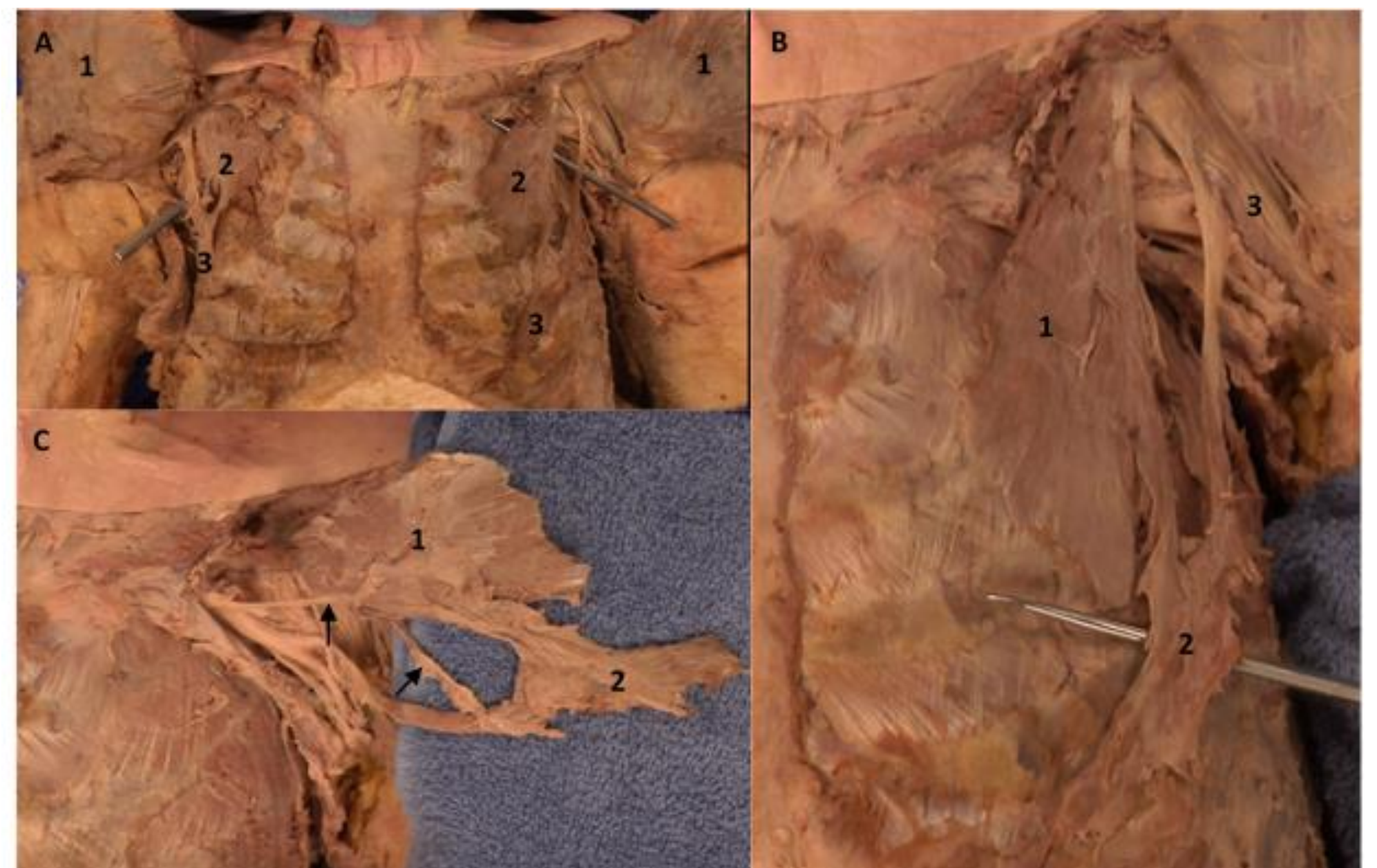


Figure 1 A: Anterior view of the pectoral region with pectoralis major muscle (1) reflected. Pectoralis minor muscle (2), anomalous muscular slips (3). B: Anterior view of left pectoralis minor muscle (1) and ligamentous blending of anomalous muscular slip (2) with coracobrachialis muscle (3) prior to coracoid insertion. C: Reflection of the pectoralis minor (1) and the anomalous muscular slip (2) innervated by branches of the medial pectoral nerve (arrows).

## Discussion

In this case, we describe the occurrence of bilateral variants of the pectoralis minor muscle discovered during a routine dissection of a female cadaver. These variants consisted of a musculotendinous slips that originated on the ribs and blended with the lateral border of the pectoralis minor muscles. Interestingly, these musculotendinous slips also possessed tendons that inserted onto the fascia of the coracobrachialis muscles. The musculotendinous slips in our case may be due to an incomplete separation of the major and minor muscles as they developed. Many pectoral muscle variants are discovered during routine dissection and are recognized by surgeons but their impact on shoulder function is considered negligible. However, knowledge of pectoralis muscle variants allows surgeons to be better prepared to adapt procedures and properly incorporate or utilize the variant to the benefit of the patient.