

Electrode Fixation with Bone Cement or Stimloc (R) in Deep Brain Stimulation Surgery: A Comparative Study

Citation for published version (APA):

Taskin, O., Kocabicak, E., Ozturk, S., Yildiz, O., & Temel, Y. (2022). Electrode Fixation with Bone Cement or Stimloc (R) in Deep Brain Stimulation Surgery: A Comparative Study. *Turkish Neurosurgery*, 32(3), 449-458. <https://doi.org/10.5137/1019-5149.jtn.35635-21.2>

Document status and date:

Published: 01/01/2022

DOI:

[10.5137/1019-5149.jtn.35635-21.2](https://doi.org/10.5137/1019-5149.jtn.35635-21.2)

Document Version:

Publisher's PDF, also known as Version of record

Document license:

Taverne

Please check the document version of this publication:

- A submitted manuscript is the version of the article upon submission and before peer-review. There can be important differences between the submitted version and the official published version of record. People interested in the research are advised to contact the author for the final version of the publication, or visit the DOI to the publisher's website.
- The final author version and the galley proof are versions of the publication after peer review.
- The final published version features the final layout of the paper including the volume, issue and page numbers.

[Link to publication](#)

General rights

Copyright and moral rights for the publications made accessible in the public portal are retained by the authors and/or other copyright owners and it is a condition of accessing publications that users recognise and abide by the legal requirements associated with these rights.

- Users may download and print one copy of any publication from the public portal for the purpose of private study or research.
- You may not further distribute the material or use it for any profit-making activity or commercial gain
- You may freely distribute the URL identifying the publication in the public portal.

If the publication is distributed under the terms of Article 25fa of the Dutch Copyright Act, indicated by the "Taverne" license above, please follow below link for the End User Agreement:

www.umlib.nl/taverne-license

Take down policy

If you believe that this document breaches copyright please contact us at:

repository@maastrichtuniversity.nl

providing details and we will investigate your claim.



Electrode Fixation with Bone Cement or Stimloc® in Deep Brain Stimulation Surgery: A Comparative Study

Onder TASKIN¹, Ersoy KOCABICAK², Sait OZTURK³, Onur YILDIZ⁴, Yasin TEMEL⁵

¹Ministry of Health, Carsamba Government Hospital, Neurosurgery Clinic, Samsun, Turkey

²Ondokuz Mayıs University, School of Medicine, Department of Neurosurgery & Neuromodulation Center, Samsun, Turkey

³Altınbaş University, Medical Park Bahçelievler Hospital, Department of Neurosurgery, Istanbul, Turkey

⁴Ondokuz Mayıs University, School of Medicine, Department of Neurology, Samsun, Turkey

⁵Maastricht University Medical Center, Departments of Neurosurgery and Neuroscience, Maastricht, The Netherlands

Corresponding author: Sait OZTURK ✉ drsaitozturk@yahoo.com

ABSTRACT

AIM: To examine the postoperative outcomes of electrode fixation using bone cement and Stimloc® in patients with Parkinson's disease (PD) who underwent subthalamic nucleus (STN) deep brain stimulation (DBS).

MATERIAL and METHODS: Between 2016 and 2018, permanent electrode fixation was performed in 30 patients with PD, of which 15 received bone cement and the remaining 15 received Stimloc®. Data regarding preoperative Unified Parkinson's Disease Rating Scale (UPDRS) III scores, levodopa equivalent daily dose (LEDD) values, surgery duration, and the fixation technique used were recorded. Brain computed tomography was performed for early postoperative evaluation of pneumocephalus and possible hematoma as well as for the determination of migration 1 year postoperatively. UPDRS III scores and LEDD values were re-evaluated 1 year postoperatively; surgery duration, clinical effectiveness, and complication rates were compared between the two fixation techniques.

RESULTS: A statistically significant difference in application time was observed between the two techniques (bone cement: 21 min, Stimloc®: 6 min). After 1 year from surgery, 0.92- and 0.88-mm migrations were observed in the bone cement and Stimloc® groups, respectively. A significant correlation between migration and the pneumocephalus volume was observed in both groups. No differences were observed between the groups regarding infection, migration, pneumocephalus volume, wound erosion, and clinical outcomes.

CONCLUSION: Stimloc® is preferred over bone cement for electrode fixation in DBS surgeries as it is associated with shorter application duration; this increases patient comfort and tolerance during awake surgery. Clinical efficacy and complication rates associated with both techniques are similar.

KEYWORDS: Deep brain stimulation, Parkinson's disease, Subthalamic nucleus, Stimloc®, Bone cement

INTRODUCTION

For over three decades, deep brain stimulation (DBS) has been the surgical treatment of choice for patients with Parkinson's disease (PD) (4,9), with the subthalamic nucleus (STN) being the most frequently used target point. DBS success largely depends on proper surgical technique, appropriate patient selection, meticulous surgical planning,

and the accurate implantation of electrodes in the small deep brain nuclei. Incorrect fixation of electrodes may compromise clinical outcomes by causing electrode displacement, and the methods used most commonly to achieve proper fixation include bone cement, mini-plates, plastic caps, and other materials developed by companies producing DBS systems for electrode fixation (20).

Onder TASKIN : 0000-0002-3423-2331
Ersoy KOCABICAK : 0000-0003-3445-1734
Sait OZTURK : 0000-0002-7655-0127

Onur YILDIZ : 0000-0002-2796-8770
Yasin TEMEL : 0000-0002-3589-5604

The present study compares the clinical outcomes, surgical duration, and postoperative long-term complications associated with the use of bone cement and Stimloc® for electrode fixation in patients undergoing STN-DBS surgery.

■ MATERIAL and METHODS

This study was approved by the hospital institutional review board (IRB No. SMC 2016-04-173), and conducted in accordance with the ethical guidelines of the Declaration of Helsinki; the informed consent requirement was waived.

Patients

This prospective study included 30 patients with PD who underwent bilateral STN-DBS surgery between 2016 and 2018. Patient demographics were recorded preoperatively. In addition, Unified PD Rating Scale (UPDRS) III and Hoehn-Yahr stage scores were recorded preoperatively and 1 year postoperatively. Pre- and postoperative levodopa equivalent daily dose (LEDD) values were also noted, and surgical and hardware-related complications were recorded in the early postoperative period and 1 year thereafter. Patients (or their parents/guardians) provided written informed consent. The study protocol was approved by the institute's committee on human research.

Surgical Technique

A day before surgery, 3.0 Tesla magnetic resonance (MR) imaging (Philips Ingenia 3.0 T®) was used to perform T1W and T2W axial brain MR imaging of patients using a single dose at 1- and 2-mm slice thickness. In the stereotactic planning station (Framelink 5, Medtronic, Minneapolis, USA), a combination of indirect-direct targeting was used to identify the dorsolateral region of the STN on MR imaging and the number of microelectrode traces that could be used for microelectrode recording (MER) during surgery was noted. In the morning of the surgery, a stereotactic frame was inserted (Leksell G frame, Sweden) under local anesthesia and a stereotactic axial computed tomography (CT; General Electric Discovery CT750 HD®) was performed using 1-mm slice thickness. Thereafter, MR-CT fusion was performed at the planning station and the stereotactic coordinates were recorded. Surgery was performed under local anesthesia, starting on the side of the body contralateral to where the

PD symptoms were predominant. Using stereotaxic frame, a burr hole was created in the precoronal area of the frontal region using a hand perforator with a diameter of 14 mm. The base of the Stimloc® on the burr hole was fixed to the cranium using micro screws (Figure 1A) in the Stimloc® group, whereas the inverted funnel bone defect was enlarged with a Kerrison in the inner tubular part of the burr hole in the bone cement group using cement (acrylic-based, poly-methyl-metacrylate PMMA, genta cement oligo 1®) for fixation. Following durotomy and corticotomy, MER and macrostimulation were performed in all patients using a microdrive (Star® Drive, FHC Inc., ME, USA) (Figure 2) and the results and side effects were recorded by the neurologist. Thereafter, a permanent electrode was implanted in the most efficient trace (model 3389, Medtronic®, Minneapolis, MN) using either Stimloc® (Figures 1B, C) or bone cement.

In patients receiving bone cement, Spongostan® was laid on the dura mater followed by two layers (Figure 3) of antibiotic bone cement (poly-methyl-meth-acrylate PMMA, genta cement oligo 1®). The time spent on Stimloc® and bone cement application was recorded separately for each patient. The abovementioned procedures were repeated on the other side of the brain. The second part of the surgery was performed under general anesthesia, and the permanent electrodes were connected via extension cables to a neurostimulator placed in the subcutaneous area under the clavicle.

After the implantation of the permanent electrodes, early postoperative cerebral CTs were performed in all patients to detect any possible intracranial pathologies (e.g., contusion and hematoma) or changes in electrode position. The location of the permanent electrode was confirmed using a combination of CT and preoperative MRI at the planning station. Brain CT scans were repeated 1 year postoperatively in all patients to detect possible electrode migration. This was performed by fusing the early and late postoperative CTs at the planning station and measuring the migration (in mm), which is defined as the difference between the last sections where the tip of the electrode could be observed using the probe's eye view mode. These evaluations were performed and compared at different points in time by two physicians to ensure reliability.

Brain CT was performed to measure the pneumocephalus volume in the early postoperative period using the following formula (Figure 4) reported by Broderick et al. (7):

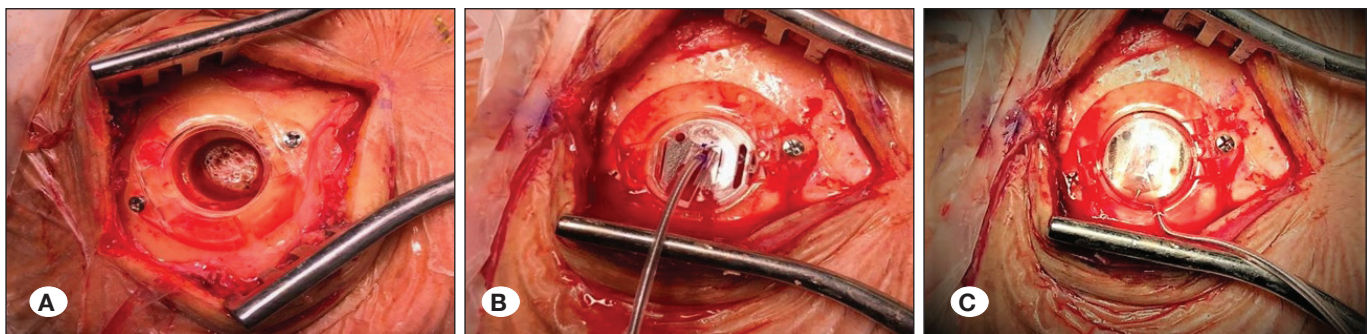


Figure 1: Fixation of Stimloc® system to the cranium. **A)** Fixation of the burr-hole using micro screws; **B)** fixation of the implanted electrode using supporter clip; **C)** view after placement of the cover cap.

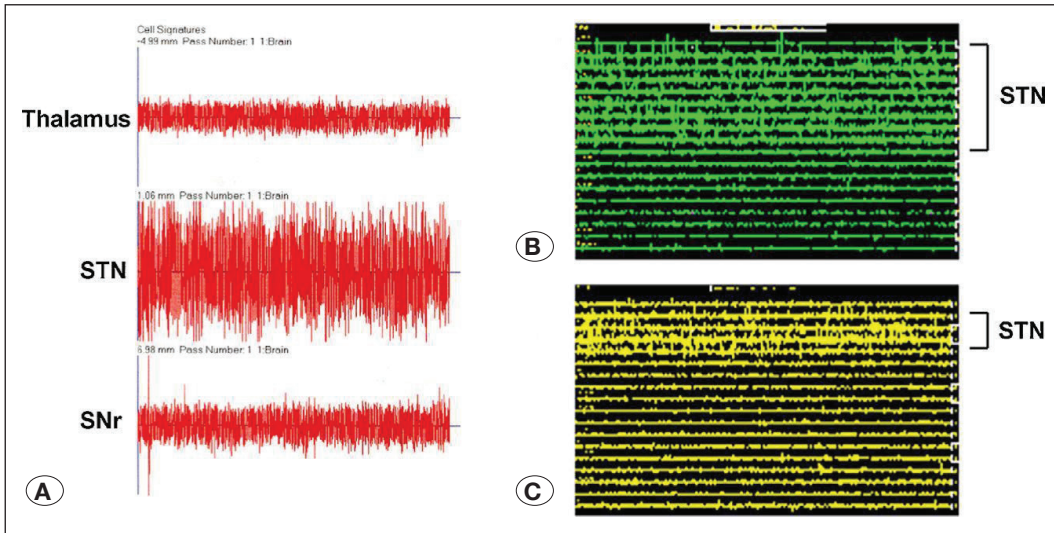


Figure 2: Typical electrophysiological findings of subthalamic nucleus during microelectrode recording (Images courtesy of Temel et al.).

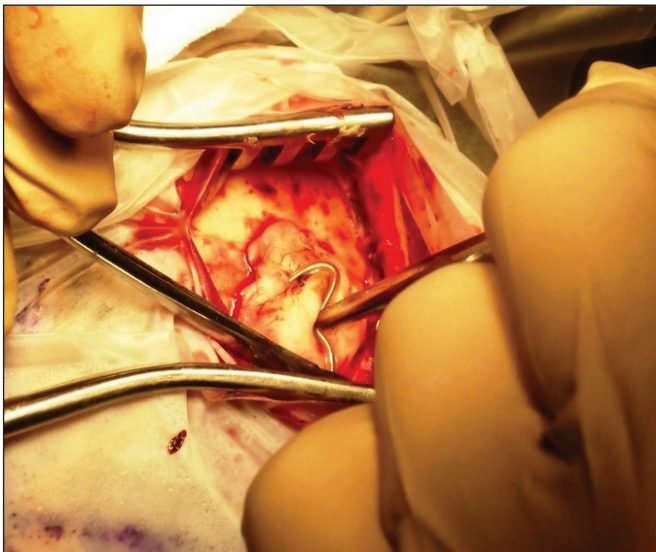


Figure 3: View of the permanent electrode fixed with bone cement.

$$\text{Volume} = (A \times B \times C)/2$$

where A = the number of air pockets noted \times section thickness, B: diameter of the section where the air pocket is widest in axial section, and C: the widest diameter drawn perpendicular to B.

The right- and left-side pneumocephalus volumes were measured in addition to the total volume along the midline falx cerebri. Early postoperative brain CT was performed for measuring the pneumocephalus volume, whereas the 1-year postoperative brain CT was performed to evaluate electrode migration.

Statistical Analysis

Fisher’s exact or Pearson’s chi-square test was used to analyze the correlations among categorical variables. Measurement

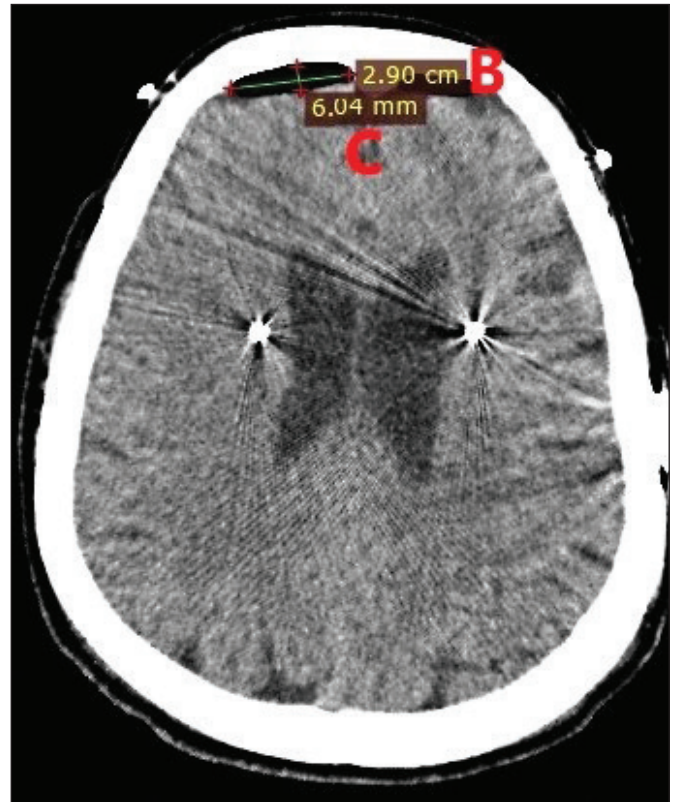

Figure 4: Measurement of pneumocephalus volume in axial section of computerized tomography (B: diameter of the section where the air pocket is widest in the axial sections; C: largest diameter drawn perpendicular to B).

differences between the two groups were analyzed using Student’s *t*-test if the data were normally distributed and Mann–Whitney U test if the values of at least one group did not follow the normal distribution. When analyzing the differences in measurements between >2 groups, one-way analysis of variance was used for normally distributed data, followed by

Tukey's post hoc test for paired comparisons. The Kruskal-Wallis H test was used in case of nonparametric comparison of >2 groups. The correlation between ordinal or continuous variables was analyzed using Spearman's correlation test; p-values of <0.05 were considered significant. All analyses were performed using SPSS 22.0.

■ RESULTS

Table I shows the patient demographics, including mean age at the time of surgery, sex, additional metabolic disease status, and preoperative disease duration. In total, 59 permanent electrodes were implanted in 30 patients (right side: 29; left side: 30). The mean distance of overall migration 1 year postoperatively was 0.9 mm. The corresponding value for the 29 permanent electrodes implanted on the first side was 0.87 mm (bone cement group: 0.9 mm; Stimloc® group: 0.86 mm), whereas that of the 30 permanent electrodes implanted on the second side was 0.92 mm (bone cement group: 0.94 mm; Stimloc® group: 0.9 mm) (Table II).

The mean pneumocephalus volume was 13 cc (bone cement group: 13.9 cc; Stimloc® group: 12.1 cc). Comparison of the

total and the right- and left-side pneumocephalus volumes revealed no statistically significant differences between the two groups (Table II). A statistically significant correlation between migration and the pneumocephalus volume was observed. When the right- and left-side pneumocephalus volumes were evaluated separately, migration was noted to be directly associated with pneumocephalus, considering the dominant side during surgery, with the stronger on the second placed side (Table II).

In total, 97 temporary microelectrodes (3.23/patient) were used for recording purposes, of which 50 (mean, 1.72) were on the first side and 47 (mean, 1.56) were on the second side. Moreover, 56 (mean, 3.73) and 41 (mean, 2.73) microelectrodes were used in the bone cement and Stimloc® groups, respectively (Table II). No correlation was observed among the temporary microelectrode numbers, surgery duration, and pneumocephalus volume ($p>0.05$).

The mean preoperative Med-off UPDRS III score was 47 (bone cement group: 48; Stimloc® group: 46), whereas the corresponding Med-on UPDRS III score was 20 (bone cement group: 18; Stimloc® group: 23) (Table III). The preoperative and first year postoperative levodopa daily dose (LEED) values of

Table I: Patient Demographics: Presence and Duration of Comorbidities

	Bone cement group	Stimloc® group	p
Age (year)	53.6 ± 9.1	55.33 ± 9.79	0.418
Gender	8 female, 7 male	7 female, 8 male	0.720
Diabetes	3	1	0.291
Duration of disease (year)	9.73 ± 2.65	11 ± 3.8	0.277

Table II: Distribution of the Number of Implanted Permanent Electrodes, Migration Values, Volumes of Pneumocephalus, Fixation Time During Surgery, and Number of Electrodes Used for Microelectrode Recording by Group

	All Patients	Bone Cement Group	Stimloc® Group	p
Permanent electrodes (n)	59	30	29	
Mean migration values one year after surgery (mm)	0.9	0.92	0.88	>0.05
Permanent electrodes implanted to the first side	0.87	0.91	0.86	>0.05
Permanent electrodes implanted to the second side	0.92	0.94	0.9	>0.05
Permanent electrodes implanted to the right side	0.86	0.9	0.82	>0.05
Permanent electrodes implanted to the left side	0.93	0.96	0.91	>0.05
Mean pneumocephalus volumes (cc)				
Total	13	13.9	12.1	>0.05
Right side		7.17	4.62	>0.05
Left Side		2.21	7.51	>0.05
Fixation time in the surgery (minute)	13	21	6	<0.001
Number of used microelectrodes for MER	97			
First side	50			
Second Side	47	56	41	>0.05

MER: Microelectrode recording, **mm:** Millimeter, **n:** Number, **%:** Percent.

patients decreased by 46% (bone cement group: 45.33%; Stimloc® group: 47.06%; $p > 0.05$). The mean postoperative Med-on/Stim-on UPDRS III score was 13.4 (bone cement group: 12.8; Stimloc® group: 14; Table III). The mean Stim-off/Med-off UPDRS III score 1 year postoperatively was 47.06 (bone cement group: 46.8; Stimloc® group: 47.3), whereas the mean Stim-on/Med-off UPDRS III score 1 year postoperatively was 19.4 (bone cement group: 18.2; Stimloc® group: 20.5). No significant differences were noted between the groups (Table III), and no correlation was observed between migration and the clinical UPDRS scores and LEDD values ($p > 0.05$).

The mean duration for electrode fixation was 21 min in the bone cement group and 6 min in the Stimloc® group ($p < 0.05$) (Table II). Table IV presents the statistical comparison of the pneumocephalus volume and migration between the two groups, which were obtained using Tukey's post hoc HSD test.

Although no perioperative complications were observed in any of the patients, one patient from each group developed infections. The patient in the Stimloc® group presented with cerebrospinal fluid (CSF) accumulation in the burr hole and meningitis within the first month postoperatively, whereas the patient in the bone cement group presented with superficial tissue infection. Patients who developed both infections were treated with intravenous antibiotics, and no clinical conditions that potentially required removal of the DBS system were observed in any of the patients. No correlation was observed between the groups in terms of between surgery duration and age, sex, diabetes, pneumocephalus, and microelectrode numbers.

In the 12th month of follow-up, high impedance was observed in six contacts in four patients, two in each group. No significant correlation was observed between migration and the number of contacts with high impedance between the two groups (bone cement group: $p = 0.678$; Stimloc® group: $p = 0.551$). Moreover, high impedance did not exhibit any significant correlation ($p > 0.05$) with decreases in the UPDRS III scores and LEDD values between the preoperative period and 1-year postoperative follow-up.

DISCUSSION

In the present study, the mean duration for bone cement and Stimloc® application were 21 and 6 min, respectively, and this difference had a statistically significant effect on surgery duration. This extra 15 min may be considered additional time that the patient will have to spend uncomfortably in an awake surgery. DBS surgeries in patients with PD are usually performed in two sessions, with the first session including an awake craniotomy under local anesthesia. The key reason for this is to allow intraoperative electrophysiological mapping of deeper structures in the brain using MER and the determination of nucleus boundaries by detecting the typical neurophysiological activity in the STN. Awake craniotomy under local anesthesia also allows directly observing disease symptoms, the healing rate of high-frequency electrical stimulation, and possible side effects during surgery. This, in turn, allows adjusting the trace location for the implantation of permanent electrodes in patients who fail to show satisfactory clinical response and present with side effects (19).

Table III: Comparison of Preoperative UPDRS III Scores, LEDD Values, and Postoperative UPDRS III Scores Between Groups

	All Patients	Bone Cement Group	Stimloc® Group	p
Preoperative UPDRS III scores				
Med-off	47	48	46	>0.05
Med-on	20	18	23	>0.05
Decrease of LEDD at the end of first year after surgery (%)	46	45	47	>0.05
Postoperative 1. year UPDRS III scores				
Med-on/Stim-on	13.4	12.8	14	>0.05
Med-off/Stim-on	19.4	18.2	20.5	>0.05
Med-off/Stim-off	47	46.8	47.3	>0.05

LEDD: Levodopa equivalent daily dose, **UPDRS:** Unified Parkinson's Disease Rating Scale, %: percent.

Table IV: Statistical Comparison of Pneumocephalus and Migration Values Between the Groups Using Tukey's Post Hoc HSD Test

	Bone cement group (p)	Stimloc® group (p)
Comparison of pneumocephalus and migration value where the electrodes implanted to the first side	0.044	0.01
Comparison of pneumocephalus and migration value where the electrodes implanted to the second side	0.01	0.02
Comparison of mean pneumocephalus and migration	0.01	0.02

Current literature suggests that the use of bone cement is more limited than that of Stimloc®. To our knowledge, no studies till date have examined the effects of these methods on surgery duration. The application time is longer with bone cement as it typically involves laying the Spongostan on the dura, followed by two layers of bone cement to minimize the risk of migration of the permanent electrode. Ensuring the applicability of bone cement also increases the surgery duration. Although previous studies have focused on the application of Stimloc® and similar plastic caps, very few have examined its effects on surgery duration and the shape, variety, reliability, and type of the material used (25). In the present study, the difference in application time between the two fixation techniques did not have any statistically significant effects on complication risks and clinical outcomes observed intraoperatively, early postoperatively, late postoperatively, and 1 year postoperatively.

In the present study, no statistically significant differences in electrode migration were observed between the two groups. The bone cement group exhibited a mean migration of 0.92 mm, whereas the corresponding value in the Stimloc® group was 0.88 mm. The maximum migration observed in both groups was 1.7 mm. No statistical intra-group difference in the variables compared were noted between the first and second sides.

To the best of our knowledge, the current literature presents limited evidence on the migration of electrodes fixed using bone cement. However, despite the lack of a significant difference in migration between the two groups, electrode revision may be inevitable in case of possible migration and technical errors during bone cement fixation. In such situations, re-planning of the workstation, reattachment of the stereotactic frame, and repeat CT scans and fusion of the images on the workstation are necessary to obtain new coordinates. Furthermore, as bone cement must be drilled using a high-speed motor during surgery, re-use of the permanent electrode is not possible, which results in additional costs. Although repeat surgeries were not required in patients included in this study, this might be considered a potential limitation of the bone cement fixation technique. In contrast, repeat surgeries are

more easily managed when using Stimloc® as the electrode can be re-used, particularly in the early postoperative period. Moreover, in case of faulty fixation, the Z axis can be easily eliminated using a scope during surgery and without requiring the reattachment of a stereotactic frame, re-planning of the workstation, and fusion of the CT scans. However, one limitation of fixation using Stimloc® is that electrode loss is inevitable because of the granulation around the valve; repeat surgeries may be necessary owing to migration. Similar difficulties and additional costs are also likely if using bone cement for revision.

Table V summarizes various studies that focused on electrode migration (2,6,10,15,22,31,36). Wharen et al. compared electrode migration between Stimloc® and basecap® (Medtronic Model 7495-51) techniques and reported mean migrations 1.7 and 3.3 mm, respectively (38). Morishita et al. reported a mean migration of 2.2 mm in their study using Stimloc®, and this value was greater than that observed in the present study (0.9 mm) (25). These studies used the Medtronic 3387 electrode model where the distance between the two contacts was 3 mm (contact: 1.5 mm; plastic gap: 1.5 mm; total contact length: 12 mm); therefore, migrations greater than this were considered serious and significant (37). Morishita et al., reported the rate of migration above 3 mm to be 12.3% (25), while Boviatsis et al (6) reported the rate of migration requiring a second surgery to be 4.4%. In the above mentioned studies, the direction of migration was either inferior or superior. Medtronic's 3389 electrodes (total contact length: 8 mm; contact: 1.5 mm; plastic gap: 0.5 mm) are routinely used for patients undergoing STN-DBS surgery at our clinic. Because both groups exhibited a mean migration of 0.9 mm inferiorly, a revision surgery was unnecessary. Moreover, because the patients did not exhibit clinical worsening due to migration postoperatively and after 1 year of follow-up, contact change was also unnecessary.

The most common risk factors for fixation-induced migration are excessive tension applied to the electrode while connecting the internal pulse generator and repetitive contractive neck movements (39). However, leaving an allowance for stretching by rotating the electrode by one or two turns under the galea

Table V: Summary of Literature on Electrode Migration Following Deep Brain Stimulation Surgery

Author / Publication Year	Number of operated patients and implanted electrodes	Number of patients requiring revision due to migration (%)	Number of electrodes requiring revision due to migration (%)
Baizabal Carvallo et al., 2012 (2)	512/856	9 (1.8)	10 (1.2)
Doshi et al., 2011 (10)	153/298	4 (2.5)	4
Boviatsis et al., 2010 (6)	106/208	1 (0.94)	1 (0.5)
Voges et al., 2006 (36)	180/352	5 (2.8)	5 (1.4)
Oh et al., 2002 (31)	79/124	4 (5.1)	4 (3.2)
Lyons et al., 2004 (22)	80/155	5 (6.3)	5 (1.4)
Joint et al., 2002 (15)	39/79	2 (5)	2 (2.5)

after fixation may reduce migration; this information is based on the experience of the neurosurgeon. The risk of electrode breakage and migration after DBS surgery are common in patients with cervical dystonia compared with those with other movement disorders. Some studies have suggested that migration can be reduced by means of more advanced fixation systems (39) or by strengthening the Stimloc® system using additional mini-plate screws (32). Ng and Thomas also reported favorable results after using both plastic caps and cement for electrode fixation (29).

In case of Stimloc® fixation, burr holes should be created using a hand perforator with a diameter of 14 mm or a high-speed electric dura stopper drill. However, as this is typically an awake surgery, the loud noise and severe cranial vibrations caused by the high-speed motor may trigger anxiety in patients. In addition, inadvertent excessive movement by the surgeon may increase the diameter of the burr hole, thus compromising Stimloc® insertion. These limitations may be overcome by using a 14-mm hand perforator, which is preferable for DBS surgeries.

Possible complications due to the heat emitted while laying the first layer of bone cement with an injector include damage to the physical structure of the electrode or the cerebral cortex and increased risk of epileptic seizures. Murpy et al. used a thermal camera during cement application with polymethylmethacrylate (PMMA) and reported a mean temperature of 47°C (maximum 55°C) for >1 min (26). Although this thermal energy has been reported to be beneficial in orthopedic bone tumor surgeries as it efficiently destroys the remaining tumor cells and reduces recurrence rates, it can also lead to bone necrosis, chondrocyte damage, and even skin damage (28). Experimental animal studies have demonstrated that the extent of thermal damage to nerve tissues is associated with the temperature and duration of exposure, with studies reporting severe neural degeneration in rat models upon exposure to temperatures of 43°C–45°C and in porcine nerve tissues upon exposure to temperatures of 60°C–70°C for 5 min (21). Therefore, care should be taken to minimize heat transmission to neural tissues during cement application. Moreover, the evaluation of possible thermal damage to the electrodes by measuring the impedance values intraoperatively showed no abnormalities. The Maastricht group previously used the same technique to implant >600 electrodes and observed impairment in electrode impedance values because of bone cement application, epileptic seizures, etc. However, the group reported no associated clinical complications (20). On the basis of the abovementioned finding, we believe that thermal damage may be acceptable if necessary precautions are taken during cement application. In this study, impedance values were measured using the Medtronic N-vision in 30 patients in the first year of follow-up and, although high values (4,000–10,000) were observed in six contacts in four patients (two in each group), associated contact changes or clinical complications were not noted.

The accuracy of stereotactic surgeries is affected by CSF leakage after durotomy and air entry into the subdural region, leading to posterior shifting of the brain and movement of the subcortical structures up to 4 mm (5,13,16,30). The

pneumocephalus volume in DBS surgeries has been reported to vary; Matias et al reported a volume of 0–32 cc (median = 6 cc) (23), Sharim et al., 60.8 ± 15.5 cc (33), and Nazarro et al., 0–7 cc (27). In the present study, a mean pneumocephalus volume of 6.62 cc was observed in both groups based on the formula reported by Broderick et al. (7), however, no statistically significant differences were observed between the two groups. In agreement with the findings of previous studies, in this study, electrode migration in the late postoperative period was directly associated with increased early postoperative pneumocephalus volume in both groups; this correlation was significant (12,16,17). However, this was not accompanied by any clinical deterioration, and the pneumocephalus volume was independent of surgery duration, fixation method, and microelectrode numbers. Previous studies reported similar outcomes (23), with Nazarro et al. observed no correlation between the pneumocephalus volume and age, the degree of atrophy, the angle of sagittal surgical approach, the number of microelectrodes used, distance between the parenchyma and bone, or surgical side (27).

In the present study, the head height was fixed at a maximum of 30° to reduce pneumocephalus; CSF leakage and air entry after durotomy was prevented by placing cotton pads on the burr hole after implanting the microelectrodes. Additional methods include the use of tissue glue. Takumi et al. reported that the pneumocephalus volume significantly reduced in a comparative study where the burr hole was covered using polyethylene glycol hydrogel (35). In our clinic, multiple or individual electrophysiological recording is preferred over fixed MER as the number of microelectrodes used depends on the vascular bed observed on a patient's brain MR imaging. Although the use of tissue glue is effective in reducing pneumocephalus, this method is not adopted in our clinic because the tissue glue may prevent the microelectrode from landing on the brain, especially in patients with electrophysiological recordings indicating the potential need for a second trace.

Sharim et al. investigated the correlation between the volume of pneumocephalus and the diameter of the burr hole and found no statistically significant correlation between the two. Larger (14 mm) burr holes tend to provide more security than smaller ones as they allow direct visualization of the cortical surface and vessels. The current literature suggests no increased risk of pneumocephalus with this approach (33).

Burciel et al. compared surgeries performed under general anesthesia with awake craniotomy and found a lower risk of pneumocephalus after DBS surgeries performed under general anesthesia (18). During neurosurgeries, the head is usually fixed at 30°–45° to increase venous return and reduce bleeding risks. Previous studies have suggested that this increases the amount of pneumocephalus (16) and the risk and frequency of venous air embolism (24). Nazarro et al. reported that the pneumocephalus volume decreased and no evidence of bleeding was noted during DBS surgeries performed with the head in a neutral position (27).

STN-DBS is an effective treatment for moderate to severe PD, improving both motor symptoms and levodopa-induced

motor complications (9). Previous large randomized controlled clinical trials have shown that STN-DBS is superior to the best available medical treatments in terms of controlling motor symptoms, minimizing PH complications, and improving the quality of life in short-term follow-up (37). In their meta-analysis, Artusi et al. demonstrated that STN-DBS reduced the UPDRS III scores by 50% in the long term and was also associated with clinical improvement (1), the findings of the present study are consistent with those of Artusi et al.

Electrode breakage is a rare complication associated with DBS surgery; it has a particularly high incidence in patients with dystonia because of sudden and involuntary contractions of the head and neck (39). No electrode breakage was observed in either group in this study. Moreover, as previous literature suggests that breakage typically occurs in the distal area instead of the cranial parts, it is unlikely to be associated with the method of fixation.

Another common complication associated with DBS surgery is the occurrence of infections and skin erosions. In the present study, two patients (one in each group; 6%) developed infections and were treated with conventional wound care and antibiotic therapy. In the bone cement group, infection occurred unilaterally in the cranial incision area, exhibited no evidence of growth in the tissue culture, and was not associated with any skin erosion. The patient was treated using intravenous ampicillin-sulbactam without incisional intervention for 14 days. In the Stimloc® group, unilateral CSF discharge in the cranial incision was observed in one patient in the first month of follow-up. These symptoms improved after lumbar drainage, and the patient was treated with IV vancomycin for 14 days after developing aureus meningitis. The current literature suggests infection rates are between 1.5% and 22%. In the study conducted Jitkriksadukul et al. 5.12% (460/8,983) patients developed infections with skin erosion, whereas 0.48% exhibited skin erosions without infection (14). The most common pathogens isolated were *Staphylococcus aureus*, *S. epidermidis*, and bacteria present in the normal flora of the skin (14). In the study conducted by Bjerknes et al., 8.7% of the patients who underwent DBS surgery were treated for infection (5). In the present study, 52% (n=17) patients developed infections in the first month and 79% (n=26) the first 3 months. Of these, 12% exhibited an increased number of normal skin flora and the culture results were negative for 24% (1). Bjerknes et al., reported that 21% of patients who developed infections were cured using antibiotic therapy, 67% were treated by the partial removal of the hardware, and 12% required complete removal of the hardware (5). Previous literature suggests that bone cement may act as a barrier to the spread of superficial infections into the brain tissue (20), and this effect can be further enhanced by the administration of cement that contains antibiotics reported to decrease infection rates (11). Considering skin erosion and aesthetics, cement application may be associated with more risk than Stimloc® application because it results in a greater height build-up on the calvarium. Skin erosions are frequently reported complications associated with the DBS hardware, particularly in patients with PD with autonomic and nutritional

disorders (3). Methods to limit the occurrence of skin erosion include C-shaped or sinus-wave-shaped skin incisions (8,34) as well as the placement of an acellular dermal matrix under the incision during revision surgery, as reported by Wharen et al. (38). The preferred method used in our clinic is the creation of a bilateral linear incision of approximately 3 cm.

■ CONCLUSION

During DBS surgeries, electrode fixation using Stimloc® is more advantageous in terms of application time than that using bone cement because the former increases patient comfort and tolerance during awake surgery. The two methods exhibit no differences in terms of electrode migration, postoperative clinical improvement, and complication risks. Furthermore, both techniques are safe and effective for electrode fixation in the long term.

■ ACKNOWLEDGEMENT

Preparation for publication of this article is partly supported by Turkish Neurosurgical Society.

■ AUTHORSHIP CONTRIBUTION

Study conception and design: YT

Data collection: OT, SO, OY, YT

Analysis and interpretation of results: OT, SO, EK, YT

Draft manuscript preparation: OT, SO, EK

Critical revision of the article: YT

Other (study supervision, fundings, materials, etc...): YT

All authors (OT, EK, SO, OY, YT) reviewed the results and approved the final version of the manuscript.

■ REFERENCES

1. Artusi CA, Dwivedi AK, Romagnolo A, Pal G, Kauffman M, Mata I, Patel D, Vizcarra JA, Duker A, Marsili L, Cheeran B, Woo D, Contarino MF, Verhagen L, Lopiano L, Espay AJ, Fasano A, Merola A: Association of subthalamic deep brain stimulation with motor, functional, and pharmacologic outcomes in patients with monogenic parkinson disease: A systematic review and meta-analysis. *JAMA Netw Open* 2: e187800, 2019
2. Baizabal Carvallo JF, Mostile G, Almaguer M, Davidson A, Simpson R, Jankovic J: Deep brain stimulation hardware complications in patients with movement disorders: Risk factors and clinical correlations. *Stereotact Funct Neurosurg* 90:300-306, 2012
3. Barrett TF, Rasouli JJ, Taub P, Kopell BH: Technical note: Preemptive surgical revision of impending deep brain stimulation hardware erosion. *World Neurosurg* 111:41-46, 2018
4. Benabid AL, Pollak P, Louveau A, Henry S, de Rougemont J: Combined (thalamotomy and stimulation) stereotactic surgery of the VIM thalamic nucleus for bilateral Parkinson disease. *Appl Neurophysiol* 50:344-346, 1987

5. Bjerknes S, Skogseid IM, Sæhle T, Dietrichs E, Toft M: Surgical site infections after deep brain stimulation surgery: Frequency, characteristics and management in a 10-year period. *PLoS One* 9:e105288, 2014
6. Boviatsis EJ, Stavrinou LC, Themistocleous M, Kouyialis AT, Sakas DE: Surgical and hardware complications of deep brain stimulation. A seven-year experience and review of the literature. *Acta Neurochir (Wien)* 152:2053-2062, 2010
7. Broderick JP, Brott TG, Grotta JC: Intracerebral hemorrhage volume measurement. *Stroke* 25:1081, 1994
8. Constantoyannis C, Berk C, Honey CR, Mendez I, Brownstone RM: Reducing hardware-related complications of deep brain stimulation. *Can J Neurol Sci* 32:194-200, 2005
9. Deuschl G, Schade-Brittinger C, Krack P, Volkmann J, Schäfer H, Bötzel K, Daniels C, Deutschländer A, Dillmann U, Eisner W, Gruber D, Hamel W, Herzog J, Hilker R, Klebe S, Kloss M, Koy J, Krause M, Kupsch A, Lorenz D, Lorenzl S, Mehdorn HM, Moringlane JR, Oertel W, Pinski MO, Reichmann H, Reuss A, Schneider GH, Schnitzler A, Steude U, Sturm V, Timmermann L, Tronnier V, Trottenberg T, Wojtecki L, Wolf E, Poewe W, Voges J, German Parkinson Study Group, Neurostimulation Section: A randomized trial of deep-brain stimulation for Parkinson's disease. *N Engl J Med* 355:896-908, 2006
10. Doshi PK: Long-term surgical and hardware-related complications of deep brain stimulation. *Stereotact Funct Neurosurg* 89:89-95, 2011
11. Eveillard M, Mertl P, Tramier B, Eb F: Effectiveness of gentamicin-impregnated cement in the prevention of deep wound infection after primary total knee arthroplasty. *Infect Control Hosp Epidemiol* 24:778-780, 2003
12. Fenoy AJ, Simpson RK: Risks of common complications in deep brain stimulation surgery: Management and avoidance. *J Neurosurg* 120:132-139, 2014
13. Halpern CH, Danish SF, Baltuch GH, Jaggi JL: Brain shift during deep brain stimulation surgery for Parkinson's disease. *Stereotact Funct Neurosurg* 86:37-43, 2008
14. Jitkriksadukul O, Bhidayasiri R, Kalia SK, Hodaie M, Lozano AM, Fasano A: Systematic review of hardware-related complications of Deep Brain Stimulation: Do new indications pose an increased risk? *Brain Stimul* 10:967-976, 2017
15. Joint C, Nandi D, Parkin S, Gregory R, Aziz T: Hardware-related problems of deep brain stimulation. *Mov Disord* 17 Suppl 3:S175-180, 2002
16. Khan MF, Mewes K, Gross RE, Skrinjar O: Assessment of brain shift related to deep brain stimulation surgery. *Stereotact Funct Neurosurg* 86:44-53, 2008
17. Kim YH, Kim HJ, Kim C, Kim DG, Jeon BS, Paek SH: Comparison of electrode location between immediate postoperative day and 6 months after bilateral subthalamic nucleus deep brain stimulation. *Acta Neurochir (Wien)* 152: 2037-2045, 2010
18. Ko AL, Magown P, Ozpınar A, Hamzaoglu V, Burchiel KJ: Asleep deep brain stimulation reduces incidence of intracranial air during electrode implantation. *Stereotact Funct Neurosurg* 96:83-90, 2018
19. Kocabicak E, Alptekin O, Ackermans L, Kubben P, Kuijff M, Kurt E, Esselink R, Temel Y: Is there still need for microelectrode recording now the subthalamic nucleus can be well visualized with high field and ultrahigh MR imaging? *Front Integr Neurosci* 9:46, 2015
20. Kocabicak E, Temel Y: Deep brain stimulation of the subthalamic nucleus in Parkinson's disease: Surgical technique, tips, tricks and complications. *Clin Neurol Neurosurg* 115:2318-2323, 2013
21. Konno S, Olmarker K, Byröd G, Nordborg C, Strömqvist B, Rydevik B: Acute thermal nerve root injury. *Eur Spine J* 3:299-302, 1994
22. Lyons KE, Wilkinson SB, Overman J, Pahwa R: Surgical and hardware complications of subthalamic stimulation: A series of 160 procedures. *Neurology* 63:612-616, 2004
23. Matias CM, Frizon LA, Asfahan F, Uribe JD, Machado AG: Brain shift and pneumocephalus assessment during frame-based deep brain stimulation implantation with intraoperative magnetic resonance imaging. *Oper Neurosurg (Hagerstown)* 14:668-674, 2018
24. Miyagi Y, Shima F, Sasaki T: Brain shift: An error factor during implantation of deep brain stimulation electrodes. *J Neurosurg* 107:989-997, 2007
25. Morishita T, Hilliard JD, Okun MS, Neal D, Nestor KA, Peace D, Hozouri AA, Davidson MR, Bova FJ, Sporrer JM, Oyama G, Foote KD: Postoperative lead migration in deep brain stimulation surgery: Incidence, risk factors, and clinical impact. *PLoS One* 12: e0183711, 2017
26. Murphy TA, Mathews JA, Whitehouse MR, Baker RP: Investigation of thermally induced damage to surrounding nerve tissue when using curettage and cementation of long bone tumours, modelled in cadaveric porcine femurs. *Arch Orthop Trauma Surg* 139:1033-1038, 2019
27. Nazzaro JM, Lyons KE, Honea RA, Mayo MS, Cook-Wiens G, Harsha A, Burns JM, Pahwa R: Head positioning and risk of pneumocephalus, air embolism, and hemorrhage during subthalamic deep brain stimulation surgery. *Acta Neurochir (Wien)* 152:2047-2052, 2010
28. Nelson DA, Barker ME, Hamlin BH: Thermal effects of acrylic cementation at bone tumour sites. *Int J Hyperthermia* 13:287-306, 1997
29. Ng WH, Thomas J: A simple and cost-effective method of fixation of deep brain stimulation (DBS) electrode. *Acta Neurochir (Wien)* 150:387-389, 2008
30. Obuchi T, Katayama Y, Kobayashi K, Oshima H, Fukaya C, Yamamoto T: Direction and predictive factors for the shift of brain structure during deep brain stimulation electrode implantation for advanced Parkinson's disease. *Neuromodulation* 11:302-310, 2008
31. Oh MY, Abosch A, Kim SH, Lang AE, Lozano AM: Long-term hardware-related complications of deep brain stimulation. *Neurosurgery* 50:1268-1274; discussion 1274-1276, 2002
32. Patel AJ, Sarwar AI, Jankovic J, Viswanathan A: Bilateral pallidal deep brain stimulation for X-linked dystonia-parkinsonism. *World Neurosurg* 82:241.e1-244, 2014

33. Sharim J, Pezeshkian P, DeSalles A, Pouratian N: Effect of cranial window diameter during deep brain stimulation surgery on volume of pneumocephalus. *Neuromodulation* 18:574-578; discussion 578-579, 2015
34. Solmaz B, Tatarli N, Ceylan D, Bayri Y, Ziyal MI, Seker A: A sine-wave-shaped skin incision for inserting deep-brain stimulators. *Acta Neurochir (Wien)* 156:1523-1525, 2014
35. Takumi I, Mishina M, Hironaka K, Oyama K, Yamada A, Adachi K, Hamamoto M, Kitamura S, Yoshida D, Teramoto A: Simple solution for preventing cerebrospinal fluid loss and brain shift during multitrack deep brain stimulation surgery in the semisupine position: Polyethylene glycol hydrogel dural sealant capping: Rapid communication. *Neurol Med Chir (Tokyo)* 53:1-6, 2013
36. Voges J, Waerzeggers Y, Maarouf M, Lehrke R, Koulousakis A, Lenartz D, Sturm V: Deep-brain stimulation: Long-term analysis of complications caused by hardware and surgery-experiences from a single centre. *J Neurol Neurosurg Psychiatry* 77:868-872, 2006
37. Weaver FM, Follett K, Stern M, Hur K, Harris C, Marks WJ, Rothlind J, Sagher O, Reda D, Moy CS, Pahwa R, Burchiel K, Hogarth P, Lai EC, Duda JE, Holloway K, Samii A, Horn S, Bronstein J, Stoner G, Heemskerk J, Huang GD, CSP 468 Study Group: Bilateral deep brain stimulation vs best medical therapy for patients with advanced Parkinson disease: A randomized controlled trial. *JAMA* 301:63-73, 2009
38. Wharen RE, Putzke JD, Uitti RJ: Deep brain stimulation lead fixation: A comparative study of the Navigus and Medtronic burr hole fixation device. *Clin Neurol Neurosurg* 107:393-395, 2005
39. Yianni J, Bain P, Giladi N, Auca M, Gregory R, Joint C, Nandi D, Stein J, Scott R, Aziz T: Globus pallidus internus deep brain stimulation for dystonic conditions: A prospective audit. *Mov Disord* 18:436-442, 2003