

Elongated styloid process: literature review and morphometric data on a collection of dried skulls

Massimo Guarna*, Paola Lorenzoni, Nila Volpi, Margherita Aglianò

Dipartimento di Scienze mediche, chirurgiche e Neuroscienze, Università degli studi di Siena, Siena, Italy

Abstract

The styloid process is a subtle process of variable length that originates from the petrous part of temporal bone. From the process originate three muscles: the stylopharyngeus, the styloglossus, the stylohyoideus and two ligaments: stylohyoid and stylomandibular. The styled process of the temporal bone has a variable length as demonstrated for studies conducted in three-dimensional computed tomography or dental panoramic three-dimensional scanning, and in dried skulls. The normal length of the styloid process is particularly important to establish for the relations of closeness with vascular and nervous structures and their possible compression by an elongated styloid process. Several studies have focused on the effects of changes in length and course of the styloid process, highlighting the relations of the carotid artery and the glossopharyngeal nerve to explain cerebrovascular symptoms or Eagle's syndrome characterized by neck pain and dysphagia. However the association for the abnormal length of styloid process and Eagle's syndrome is not always present and many cases are asymptomatic. In the present study we propose a review of the studies performed with different *in vivo* radiological techniques and on dried skull collections on the normal and pathological length of the styloid process and on its association with the Eagle's syndrome. We also present a morphometric study carried out in dried skulls of our museum collection. The results are discussed in light of the possible variations in the muscular and ligamentous structures consequent to the elongation of the styloid process.

Keywords

Elongated styloid process, Eagle's syndrome.

Introduction

The styloid process (SP) is a subtle pointed process of variable length that originates from the petrous portion of temporal bone and is localized anteriorly to the stylomastoid foramen.

From the process originate three muscles: the stylopharyngeus, the styloglossus, the stylohyoideus and two ligaments: stylohyoid and stylomandibular. The SP projects inferiorly and anteriorly into the parapharyngeal space and it is in relationship with the internal carotid artery medially and with various encephalic nerves as glossopharyngeal, vagus, accessory, hypoglossal. The SP of the temporal bone has a variable length as demonstrated for studies conducted in: three-dimensional computed tomography (3dct) or dental panoramic three-dimensional scanning. Sötkler

* Corresponding author. E-mail: guarna@unisi.it

and Sandev (2001) reported an average value of about 22 mms and a limit of 30 mms for normality. Gozil et al. (2001) considered elongated a process of 40 mms. Sudhakar et al. (2013) on 600 digital panoramic radiographs found that the mean average length of elongated styloid processes was 3.67 ± 0.62 cms. Jung et al. (2004) with the study of panoramic radiographs had found an average value of 28 mms in length and suggested that the SP should be considered to be elongated, when its length exceeds 45 mms. Keur et al. (2001) stated that, if the length of the process or the mineralized part of ligaments which appeared in radiography was 30 mms or more, this could be considered an elongated SP. Basekim et al. (2005) examined the length of the styloid process of 138 subjects with 3dct finding an average length of 28.3 mms and considered the maximum normal length of the process 40 mms. De Andrade et al. (2012) measured the styloid length in cephalometric radiography finding a mean value of 32.39 mms. Data onto the osteometric values of the SP is scanty with significant length differences existing on the studies attributed to different races or ethnicities (De Paz et al. ,2012; Rathva et al., 2013; Natsis et al. ,2014). Natsis et al. (2014) in a study carried out on an one hundred and forty-nine adult dried skull ,classified the SP in three types according to their lengths. The processes were classified as short <18 mms, normal 18–33 mms and elongated 33 mms. The majority of the processes were normal (45.8 %), 27.5 % were short and 26.7 % elongated. In another study by Custodio et al. (2016) on a population of 15 dried skulls, the authors found an average of 19.25 or 24.98 mms depending on the measurement made with a lateral or posterior view of the styloid process. Vadgaonkar et al. (2015) reported in a morphometric study on a collection of 110 dried skulls a length of 17.8 ± 9.3 mms for the right process and 18.2 ± 5.6 mms for the left process. Several studies have been limited to reports on isolated cases of excessively long processes (Prabhu et al. , 2007; Magotra et al. ,2008; Paraskevas et al., 2009; Akhaddar et al., 2010; Lins et al. , 2010) which curve medially and anteriorly with variable length up to 140 mm. (Kubíkova and Varga, 2009). An excessive length of the styloid process may be due to calcification - ossification of the styloid ligament which may be bilateral (Jagadish et al. 2010) or more rarely unilateral (Guarna and Aglianò, 2018), less than 0.9 % according to (Vougiouklakis ,2006). In a review of 1215 autopsies ,Langlais et al. (1986) recognizes three types of elongated and ossified styloid processes: the first two are interrupted and have pseudo-articulations, the third is an uninterrupted segment formed by the ossified SL. Campos et al. (2011) reported that the etiology of styloid bone elongation can be explained by a genetic alteration or according to several theories. The ossification of the SL may be the consequence of a pharyngeal trauma which causes metaplastic change . According to the anatomic variance theory ,the elongated SP and the ossified SL are anatomical variations that occur without any trauma.

The abnormal length can be in some cases accompanied by a set of symptoms, characterized by neck pain , dysphagia, headache, sore throat, ear pain , mandibular dysfunction clinically framed in Eagle's syndrome (Eagle 1937, 1948). Yavuz et al. (2008) stressed that length in isolation is not a risk factor, but that its combination with increased acuity in deviation from the norm, both anteriorly and medially, makes the elongated styloid processes the cause of the syndrome. Stylocarotid syndrome, the less common vascular variant of the Eagle syndrome, can present as headache, transient ischemic attack (TIA), or stroke (Chang et al., 2007). Stylocarotid syndrome results from the styloid process compressing the internal carotid artery

(ICA) or external carotid artery.(David et al., 2014) .The abnormal length of styloid process raises questions about the anatomical changes that can come to be established for a change of length and insertion of the stylohyoid and stylomandibular ligaments(called the bouchet's white flowers) , as well as the muscles styloglossus , stylopharyngeus , stylohyoid (the so called Riolo's bouchet). (Fini et al.,2000).

Furthermore literature does not contain information regarding how these changes may affect the processes of swallowing, phonation, breathing and chewing. We present an osteometric study on the length of the styloid process of collection of over 250 dried skulls belonging to the museum of Anatomy "Leonetto Comparini " at the University of Siena, collected over a period from 1900 to 1960. All skulls came from the local psychiatric hospital. Univariate analysis provides mean values and standard deviations of the main variable length. A Mann Whitney test was applied for the analysis of significant differences between the averages of the groups of skulls .

Materials and methods

We carried out measuring the length of the styloid process on a sample of 153 skulls of the entire collection of 250 of the local anatomical museum, having chosen the skulls in which at least one of the two processes was intact . The skulls of children, damaged skulls and skulls with pathological conditions were excluded from the study.Furthermore the skull with the styloid process which had the completely ossified stiloyd ligament of 7 cms in length was not considered for statistical purposes. The lengths of the right or left styloid processes were measured by choosing the side that appeared the best preserved for measurement purposes.The measuring starts from the sheath at the point where this became accessible below the external acoustic meatus .We employed a digital caliper with the following technical characteristics. Measuring range: 0-150 mm; resolution: 0.01 mm; accuracy: + / - 0.02mm; measurement repeatability: + / - 0.01 mm; .The data were analyzed trough a free statistical software (Salstat 2) .Average and standard deviation (sd) were calculated. A Mann-Whitney test for significance level of 0,5 was used for detecting differences between the distributions of both genders.The test was carried out on two groups of 19 male skulls and 26 female skulls , having chosen only those skulls of which the sex of belonging was certain.

Results

Univariate analysis of the length of the styloid process gave the following results: average: 26,57 mms ; sd : 7,40 mms ; median 25 mms , normal range : average +/- 2 sd : 41-7 mms.The histogram of the elements (fig 1) shows a large class of 48% (73) elements, with a length of the styloid process of 18-26 mms . A second class smaller as elements 37% has a styled process with a length of 27-35 mms.(fig. 1). The longest styloid process observed was 52 mms (fig. 2) and the shortest had a length of 5 mms .

In one case we discovered a skull with stylohyoid calcified ligaments on one side. The styloid process was long 50 mms on the right and 70 mms on the left where is the tip calcified (not shown).There were no significative differences between lengths

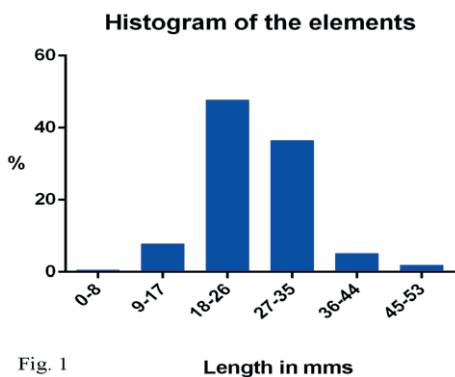


Fig. 1

Figure 1. histogram representing the distribution frequency of the length of the styloid processes.

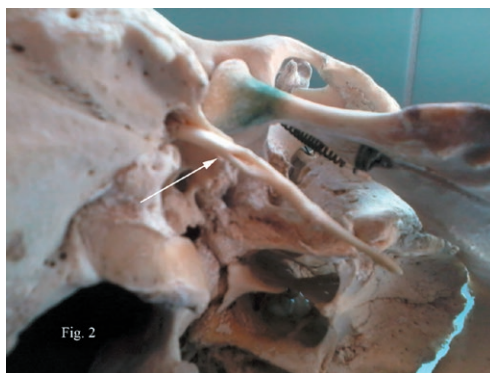

Fig. 2

Figure 2. Elongated styloid process (52 mm) in a skull from the Leonetto Comparini Museum collection.

in male e female subjects. Considering that the Range of Normal Lengths was taken as ± 2 standard deviations from the mean, the percentage of elongated styloid processes was 3.9%

Discussion

The length of the styloid process has an average value of 26,57 mms in our biometric study .This value is in accordance with those ones established by other authors (Baskim et al. ,2005; Joung et al.,2004).Patil et al.(2014) in 114 dried skulls reported a mean of 2,58 cms for SP length. An abnormal long styloid process >41 mm is present in 3,9% of items . Vadgaonkar et al. (2015) reported that the prevalence of elongated styloid processes in 110 dried skulls was 4.5%. Other authors provide higher percentages of elongated styloid processes but place the value of 30 mm as the limit of normality. Gracco et al.(2017) in a north Italian population evaluated elongated styled process by digital panoramic radiographs and found that 33% of population has an elongated styled process with a length of the process more than 30 mms.The prevalence of the elongated styloid process is between 4% and 28% of the population (Silva et al., 2002). The pathogenesis of the elongation of styloid process is still debated .It was believed that there is an association with previous surgical trauma or local irritation of stylohyo-deus ligament which could cause hyperplasia and reactive ossification of the process. Later the cause was believed to be a variation in development of second arch derivatives (Fini et al. ,2000) .It could be a mutation in the genes implicated in the correct development of the components of branchial arches. Future genetic studies will be needed to prove this issue.Only in a case we found a calcified tip of the abnormal lengthy styloid process,70 mms long on the left.Unfortunately we have no information about the subject to search the presence in the past of surgical trauma or local irritation .Several studies have focused on the effects of changes in length and course of the styloid process,(Thot et al.,2000 ; Yavuz et al.,2008) highlighting the relations of the carotid artery and the glossopharyngeal nerve(Shin et al .,2009) to explain cerebrovascular

symptoms or Eagle's syndrome characterized by neck pain and dysphagia (Eagle,1937). However the association for the abnormal length of styloid process and Eagle's syndrome is not always present and many cases are asymptomatic (Fini et al. ,2000). Anatomical variation in length of styloid process could have effects on ligaments and muscles which origin from it and insert on mandible and os hyoid . The stylohyoid ligament originates from the tip of the styloid process and is attached inferiorly to the lesser horn of the hyoid bone. Likewise the stylomandibular ligament originates near the apex of the styloid and is inserted medially into the mandibular angle. The shortening of the stylomandibular ligament could cause difficult in the protrusion of mandible and in mastication (Costantinides et al.,2013). The shortening of stylohyoid ligament which originates from the apex of the styloid process and is attached inferiorly to the lesser horn of the hyoid bone or its calcification-ossification could cause difficult in movement of os hyoid and in raising or lowering of larynx during swallowing(Desrhaj et al., 2011). This could be an explanation for the disturbance reported in these processes by several patients. Likewise the excessive shortening of styloglossus muscles which originates close to the apex of the styloid process and from the upper part of the stylomandibular ligament and is inserted in the septum of the tongue (Fini et al., 2000) could disturb the tongue movement . The stylohyoid muscle which originates from the base of the styloid process and is inserting on the hyoid bone near the greater horn will be longer in case of abnormal length of styloid process and so the muscle stylopharyngeus which originates from the medial aspect of the styloid process close to its base and is inserted into the lateral wall of the pharynx and elevates the pharynx during the first phase of swallowing(Tubbs et al.,2010)

To avoid the shortening of ligament and muscles the elongation of styloid process could be accompanied by a dislocation in a lower position of os hyoid with laryngeal cartilage and trachea .Lowering of hyoid happens to children with atypical deglutition. Atypical deglutition is the persistence of deciduous dentition deglutition, and in this case os hyoid is lowered about 5mm from mandible plane (Machado and Crespo, 2012). Similarly in obstructive sleep apnea and hypopnoea syndrome(OSAHS), the hyoid bone is more distant from the mandible plane as reported in cephalometric studies ,(Riha et al., 2005; Tsai et al., 2007).However, in all these cases there is no information on the presence of an elongated styloid process by which we can infer a modification of the muscular and ligamentous structures that are placed on it. Moreover possibly hypertonia of the infrahyoid and hypotonia of the suprahyoid muscles as a consequence of the different position of hyoid bone could cause change in the voice and a greater difficulty during intubation.(Kaway et al. ,1990) Our study on the length of styloid process in a population Italian confirmed the low frequency of an abnormally long process , highlights a case of ligamentum styloideus ossified and discuss the possible consequences on the muscles and ligaments which arise from the styloideus process in case of abnormally length of the same .

References

- Akhaddar A., Elasri A., Zalagh M., Boucetta M.(2010) Eagle's syndrome (elongated styloid process). *Intern.Med* 49, (12):1259.
- Başekim CC., Mutlu H., Güngör A., Silit E., Pekkaşali Z., Kutlay M., Colak A., Oztürk E., Kizilkaya E.(2005) Evaluation of styloid process by three-dimensional comput-

- ed tomography. *Eur. Radiol.* 15, (1):134-9
- Campos D., Silva T.H., Kipper J.F., Piazza J., Kraether N. (2011) Ossification of styloid ligament and its clinical implication: a report of human cases. *J. Morphol. Sci.* 28, (2):137-139
- Chuang WC., Short JH., McKinney AM., Anker L., Knoll B., McKinney Z.J. (2007) Reversible left hemispheric ischemia secondary to carotid compression in Eagle syndrome: Surgical and CT angiographic correlation. *Am. J. Neuroradiol.* 28 : 143–145.
- Costantinides F., Vidoni G., Bodin C., Di Lenarda R. 2013 Eagle's Syndrome: Signs and Symptoms, *CRANI*, 31, (1): 56-60,
- Custodio A.L., Silva M.R., Abreu M.H., Araújo L.R., de Oliveira L. J. (2016) Styloid Process of the Temporal Bone: Morphometric Analysis and Clinical Implications. *BioMed. Res. Int.* 7:1-5
- David J., Lieb M., Rahimi S.A. 2014 Stylocarotid artery syndrome *J. Vasc. Surg.* 60(6):1661-3.
- De Andrade K., M., Rodrigues C., A., Watanabe P., C., Mazzetto M., O. (2012) Styloid process elongation and calcification in subjects with tmd: clinical and radiographic aspects. *Braz Dent J.* 23(4):443-50.8
- De Paz F., J., Rueda C., Barbosa M., Garcia M., Pastor J., F. (2012) Biometry and statistical analysis of the styloid process. *Anat. Rec.* 295(5): 742-747;
- Deshraj J., Jaideep S. C., Sandhya J., Gaurav G. (2011) Elongated Styloid Process: An Unusual Cause of Neck Pain and Difficulty in Swallowing *J. Orofac. Pain.* 25:269–271
- Eagle W., W. (1937) Elongated styloid processes: report of two cases. *Arch. Otolaryngol.* 25:584–7.
- Eagle W., W. (1948) Elongated styloid process: further observations and a new syndrome. *Arch. Otolaryngol.* 47:630–40.
- Fini G., Gasparin G., Filippini F., Becelli R., Marcotullio D. (2000) The long styloid process syndrome or Eagle's syndrome. *J. Cranio Maxill. Surg.* 28 : 123-127
- Gozil R., Yener N., Calguner E., Arac M., Tunc E., Bahcecioglu M. (2001) Morphological characteristics of styloid process evaluated by computerized axial tomography. *Ann. Anat.* 183:527–535
- Gracco A., De Stefani A., Bruno G., Balasso P., Alessandri-Bonetti G., Stellini E. 2017 Elongated styloid process evaluation on digital panoramic radiograph in a North Italian population *J. Clin. Exp. Dent.* 9(3): 400-4.
- Guarna M., Aglianò M. (2018) An abnormally long styloid process with ossification of the stylohyoid ligament. *Int. J. Anat. Res.* 6(2.1): 5101-5103
- Jagadish Rao P., P., Ritesh G. M., Ramadas N., Anand V., Nagesh K., R., Sampath M., Tanuj K., Astha G., Savita L. (2010) Bilateral calcified stylohyoid ligament: An incidental autopsy finding with medicolegal significance *Leg. Med.* 12: 184–187
- Jung T., Tschernitschek H., Hippen H., Schneider B., Borchers L. (2004) Elongated styloid process: when is it really elongated? *Dentomaxillofac. Radiol.* 33(2):119-24
- Kawai T1, Shimozato K, Ochiai S. (1990) Elongated styloid process as a cause of difficult intubation *J. Oral. Maxillofac. Surg.* 48(11): 1225-28
- Keur J., J., Campbell J., P., McCarthy J., F., Ralph W., J. (1986) The clinical significance of the elongated styloid process. *Oral. Surg. Oral. Med. Oral. Pathol.* 61(4):399-404
- Kubikova E., Varga I. (2009) A case of extremely long styloid process without clinical symptoms and complications. *Clin. Anat.* 22(8):865-7.

- Langlais R.P., Miles D.A., Van Dis M.L. (1986) Elongated and mineralized stylohyoid ligament complex: A proposed classification and report of a case of Eagle's syndrome. *Oral Surg. Oral Med. Oral Pathol.* 61:527-32
- Lins C.C.S.A. Junior A.A.A., Oliveira B.P., Silva E.M.V.M., Torres R.C.M.S (2010) Variation of length of styloid process *Int. J. Morphol.* 28(4): 1277-1280
- Machado A.J. Jr., Crespo A.N. (2012) Cephalometric evaluation of the airway space and hyoid bone in children with normal and atypical deglutition: correlation study. *Sao Paulo Med. J.* 130(4):236-41.
- Magotra R., Radzan S. (2008) Elongated styloid process: anatomical variations. *Horizon* 10: 4
- Natsis K., Repousi E., Noutsios G., Papatheanasiou E., Apostolidis S., Piagkou M. (2015) The styloid process in a Greek population: an anatomical study with clinical implications *Anat. Sci. Int.* 90:67-74
- Paraskevas G., K., Raikos A., Lazos L.M., Kitsoulis P. (2009) Unilateral elongated styloid process: a case report. *Cases. J.* 2:9135
- Patil S., Ghosh S., Vasudeva N. (2014) Morphometric Study of the Styloid Process of Temporal Bone. *J. Clin. Diagn. Res* 8(9): AC04-AC06
- Prabhu L.V., Kumar A., Nayak S.R., Pai M.M., Vadgaonkar R., Krishnamurthy A., Madhan Kumar S.J. (2007) An unusually lengthy styloid process. *Singapore Med. J.* 48(2): 34-36
- Rathva A., Kubavat D.M., Nagar S. K. (2013) Study of styloid process: anatomical variations in length, angulation and distance between the two styloid processes *International Journal of Recent Trends in Science and Technology* 8(2): 109-112
- Shin J.H., Herrera S.R., Eboli P., Aydin S., Eskandar E.H., Slavin KV (2009) Entrapment of the glossopharyngeal nerve in patients with Eagle syndrome: surgical technique and outcomes in a series of 5 patients *J. Neurosurg.* 111:1226-1230,
- Silva, H. J., Moraes S. R. A. & Tashiro T. (2002) Analisis morfometrico de los elementos de la cadena estilohioidea. *Rev. Chil. Anat.* 20:205-10.
- Sokler K., Sandev S. (2019) New classification of the styloid process length--clinical application on the biological base. *Coll. Antropo.* 25(2):627-32.
- Sudhakara Reddy R., Sai Kiran C.H., Sai Madhavi N., Raghavendra M.N., Satish A. (2013) Prevalence of elongation and calcification patterns of elongated styloid process in south India *J. Clin. Exp. Dent.* 5(1): 30-5.
- Thot B., Revel S., Mohandas R., Rao A.V., Kumar A. (2000) Eagle' syndrome. *Anatomy of the styloid process. Indian J. Dent. Res.* 11:65-70.
- Tsai H.H., Ho C.Y., Lee P.L., Tan C.T. (2007) Cephalometric analysis of nonobese snorers either with or without obstructive sleep apnea syndrome. *Angle Orthod.* 77(6):1054-61.
- Tubbs R S, Marios Loukas M., Dixon J., Cohen-Gadol A.A. 2010 Compression of the cervical internal carotid artery by the stylopharyngeus muscle: an anatomical study with potential clinical significance *J. Neurosurg.* 113:881-884,
- Vadgaonkar R., Murlimanju B.V., Prabhu L.V., Rai R., Pai M.M., Tonse M., Jiji P.J. (2015) Morphological study of styloid process of the temporal bone and its clinical implications *Anat. Cell. Biol.* 48(3):195-200
- Vougiouklakis T. (2006) Overview of the ossified stylohyoid ligament based in more than 1200 forensic autopsies. *J. Clin. Forensic Med.* 13: 268-270.
- Yavuz H, Caylakli F, Yildirim T, Ozluoglu L.N. (2008) Angulation of the styloid process in Eagle's syndrome *Eur. Arch. Otorhinolaryngol.* 265(11):1393-6.