

APEXOGENESIS TREATMENT WITH MINERAL TRIOXIDE AGGREGATE: LONG-TERM FOLLOW-UP OF TWO CASES

SADJ March 2018, Vol 73 no 2 p78 - p82

PJ van der Vyver,¹ N Potgieter,² B Selvan.³

ABSTRACT

Apexogenesis is the treatment of choice for traumatized or carious teeth which, at the time of exposure, have a vital pulp and open apex. This article describes two cases of permanent teeth with carious exposures, treated with direct pulp capping procedures using mineral trioxide aggregate (MTA).

METHODS

Radiographic and clinical examination, including testing reaction to cold, showed that both teeth were immature and in a stage of reversible pulpitis. The caries was identified using caries detector dye and removed using a rotary bur. Sodium hypochlorite solution was applied to the exposed pulp to achieve haemostasis. MTA paste was then placed on the pulp exposure and surrounding dentine. In the first case, the MTA was covered with a glass-ionomer restorative material; in the second case, the MTA was covered with a glass-ionomer cement and restored with composite resin.

RESULTS

Radiographic and clinical examinations on the initial and long-term follow-up visits showed that root development continued and apices formed. The teeth remained vital and functional, and no further endodontic intervention was necessary.

CONCLUSION

Under the conditions of this study, MTA proved to be a reliable pulp-capping material on direct carious exposures in immature permanent teeth using a one-visit protocol.

Author affiliation.

1. **Peet J van der Vyver**, BChD, PG Dip Dent (Endo), PG Dip Dent (Aesthet Dent), MSc, PhD (Pret). Division of Endodontics, Department of Odontology, School of Dentistry, Faculty of Health Sciences, University of Pretoria, Gauteng, South Africa; Private Practice, Sandton, South Africa
2. **Nicoline Potgieter**, BChD, PG Dip Dent (Endo)(Pret), PG Dip (Paedo)(UWC), MSc (Pret). Division of Paedodontics, Department of Odontology, School of Dentistry, Faculty of Health Sciences, University of Pretoria, Gauteng, South Africa.
3. **Brad D Selvan**, BDS (Wits), PG Dip Dent (Endo)(Pret). Private Practice, Midrand, South Africa

Corresponding Author

Prof PJ van der Vyver, Division of Endodontics, Department of Odontology, School of Dentistry, Faculty of Health Sciences, University of Pretoria, Gauteng, South Africa. Tel: 011 7821 1020, E-mail: peetv@iafrica.com

ACRONYMS

GMTA : grey mineral trioxide aggregate

MTA : mineral trioxide aggregate

PBRN : practice based research network

WMTA : white mineral trioxide aggregate

INTRODUCTION

Vital pulp therapy (e.g., pulp capping, partial or full pulpotomy) is generally the treatment of choice for traumatized or carious teeth with a vital pulp and open apex at the time of exposure.^{1,2} The treatment is very successful on traumatically exposed teeth^{3,4} because a healthy pulp is capped.^{4,5} Vital pulp therapy on cariously exposed pulp is not as successful,⁶ because the capping of inflamed tissue is less predictable.^{4,7,8}

According to Trope,⁴ the area and depth of inflammation in cariously exposed pulps are very unpredictable, and pulp capping at the superficial exposure site can result in failure. After observing 49 teeth over a period of 9 years, Bogen et al.⁹ found that 97.96% of immature (with open apices) and adult (with closed apices) teeth with carious exposures capped with mineral trioxide aggregate (MTA), had favourable outcomes on the basis of radiographic appearance, no symptoms and normal responses to cold testing. Fifteen of the teeth were immature at the time of treatment, and all these subsequently demonstrated continued normal apexogenesis to complete root formation.

Vital pulp therapy on immature teeth allows for continuation of root formation, which leads to apical closure,¹⁰ preservation and maintenance of pulp vitality,⁹ stronger root structure and greater structural integrity.^{10,11}

The most successful agent for pulp capping procedures is MTA. This material has a long history of use for both pulp capping and other applications.^{9,12-14} As a pulp capping material, MTA can induce hard tissue formation in pulpal tissues,¹⁵⁻¹⁸ produce a thicker dentinal bridge at a faster rate,^{2,19} promote longer-term sealing,² reduce inflammation, reduce hyperaemia and reduce pulpal necrosis compared with calcium hydroxide.^{10,15,20-22}

Despite its biocompatibility as a pulp capping material, it has a delayed setting time,¹⁰ poor handling characteristics^{23,24} and is costly.¹⁰

This article presents two case reports where MTA was used as a direct, single-visit pulp capping material in cariously exposed teeth with immature roots.

CASE REPORT 1

An 8-year-old boy was referred to our private practice by another practitioner who had exposed the pulp during removal of occlusal decay on the recently erupted mandibular right first premolar. The patient was seen at the endodontic practice thirty minutes after the carious exposure. The dentist had placed a moist, sterile cotton pledget over the exposure and covered it with a zinc-oxide eugenol temporary restoration (Kalzinol, Dentsply De Trey, Konstanz, Germany). According to the referring dentist, the patient had suffered no spontaneous pain preoperatively apart from the main complaint of sensitivity to cold liquids. Radiographic examination showed that the root formation was immature (Figure 1a). The patient's medical history was noncontributory. A dose of local anaesthetic was administered. A rubber dam was placed, and a caries indicator dye (Sable Seek, Ultradent, South Jordan, UT, USA) was applied to facilitate final caries excavation, which was done using a slow-speed carbide bur in a contra-angle hand piece under 12X microscope magnification (Figure 1b).

A 6% sodium hypochlorite solution (NaOCl) (Chlor-Xtra, Vista Dental, Racine, WI) was placed on the exposed pulp in order to achieve haemostasis. After three minutes, the NaOCl was rinsed away with water using a two-way syringe, and the area was blot-dried with sterile cotton pledges. Adequate haemostasis was seen to have been achieved. White ProRoot MTA (Dentsply Sirona, Philadelphia, USA) was mixed according to the manufacturer's instructions, and a thick layer of the cement was placed directly over the exposure site and surrounding dentine (Figure 1c). The MTA was then directly covered with a glass-ionomer material (Fuji IX GP, GC Corporation, Tokyo, Japan), which was also used to restore the cavity. Figure 1d shows an immediate postoperative periapical radiograph.

The patient was instructed to call our clinic immediately if any pain or discomfort occurred. At the ten-day recall visit the patient was asymptomatic and had a normal response to cold testing. The patient was rescheduled for follow up after three months, with instructions to return earlier in case of any discomfort. At this recall visit, the tooth was asymptomatic and had a normal response to cold testing.

At the one-year follow-up visit, more root development was observed, with a thickening of root walls and a visible dentine bridge at the exposure site (Figure 2a). At a two-year recall visit, the tooth tested vital, and a periapical radiograph showed additional root formation (Figure 2b). The three-year follow-up visit confirmed complete root formation and apex closure (Figure 2c). Figure 2d depicts the four-year follow-up radiographic image of the asymptomatic tooth. At that stage, the tooth tested vital and a normal periodontal ligament was demonstrated.

CASE REPORT 2

A seven-year-old boy attended our practice for a routine checkup. A bitewing radiograph revealed an occlusal-

mesial cavity on his mandibular left first permanent molar. The patient's medical history was noncontributory. Local anesthetic was administered, a rubber dam was placed, and the cavity prepared with a high-speed diamond bur. Caries indicator was used to ensure complete excavation of caries, which was carried out under 12X microscope magnification using a slow-speed carbide bur in a contra-angle hand piece.

Haemostasis was achieved by the application of a 3.5% NaOCl solution (Jik, Reckitt Benckiser, South Africa) on the exposed pulp for two minutes. The NaOCl was then rinsed away with water using a two-way syringe, and the area was blot-dried with sterile cotton pledges. Grey ProRoot MTA (Dentsply Sirona, Philadelphia, USA) was mixed according to the manufacturer's instructions, and a thick layer of the cement was placed directly over the exposure site and surrounding dentine. Then, the MTA was covered with a light-cured resin-modified glass-ionomer cement (Vitrebond, 3M ESPE, St Paul, Minnesota, USA), and composite resin (TPH Spectrum, Dentsply Sirona, Philadelphia, USA) was used to restore the cavity. An immediate postoperative periapical radiograph showed that the roots of the molar were still immature with large open apices (Figure 3a).

The patient was instructed to call our clinic immediately if any pain or discomfort occurred. At the fifteen-day recall visit the patient reported that the tooth was asymptomatic. Testing with the application of cold resulted in a normal reaction. The patient was rescheduled for follow up at three months and at one, two, four and six years, with instructions to return immediately in case of any discomfort.

Continued root development was evident, and a 0.5-mm dentine bridge was seen to have formed at the exposure site after two years (Figure 3b). At a four-year recall visit, the radiograph revealed closure of the apices of the mesial and distal roots and an increase in the thickness of the dentine bridge formation (Figure 3c). At the six-year follow-up, slight widening of the periodontal ligament around the apical third of the mesial roots was noted.

At a 14-year follow-up visit (Figure 3d), the tooth was still asymptomatic and had a normal response to cold testing. The periodontal ligament around the apical third of the mesial root was still widened. Also visible on the periapical radiographs at these recall visits was a small calcification or pulp stone that had formed in the pulp chamber of the tooth. From the time that root formation was complete and the apices closed (four-year recall, Figure 3c) up to the last follow up at the 14-year recall (Figure 3d), the root canal width and pulpal volume remained approximately the same size.

DISCUSSION

Radiographic assessment of both teeth in the two case reports demonstrated that the roots had progressed to complete root formation and apex closure, and cold testing confirmed the preservation and maintenance of pulp vitality. Dentine bridge formation at the site of pulpal exposure was also noted in both cases.

Studies have shown that properties of a pulp capping material such as sealing ability, alkalinity and biocompatibility could be responsible for dentine bridge formation.¹⁵ MTA has the ability to induce hard tissue formation in pulpal tissues when used as a direct pulp capping material.^{2,16,25,26} The placement of MTA on

exposed pulp tissue stimulates the release of growth factors, which is necessary for pulpal cells to recruit and organize odontoblasts to lay down reparative dentine.^{27,28} Compared with calcium hydroxide ($\text{Ca}(\text{OH})_2$), MTA induces dentine bridge formation at a faster rate,¹⁹ develops more complete dentine bridges and demonstrates an improved ability to maintain pulp tissue integrity.^{2,15,29} Hilton et al.³⁰ conducted a large, randomized clinical trial over a two-year period in a practice-based research network that showed the superior performance of MTA compared with $\text{Ca}(\text{OH})_2$.

Farsi et al.³¹ reported a success rate of 93% over a 24-month recall period in a clinical study in which 30 young, permanent, cariously exposed, asymptomatic teeth were pulp capped with MTA. Clinical and radiographic success was reported as all the teeth were asymptomatic, showed signs of vitality, lacked periapical radiolucencies and showed evidence of continued root growth.

The use of caries detector dye to confirm all caries had been removed, NaOCl for haemostasis and disinfection, MTA as a pulp capping material, glass-ionomer material to cover unset MTA material and enhanced magnification of all clinical procedures were all factors contributing to the success of these two one-visit pulp capping treatments.

Effective operative magnification and careful caries removal have been identified as important prerequisites for success,⁹ with the placement of a bioactive pulp capping material enhancing the innate healing capacity of the human dental pulp.

Haemostasis after pulpal exposure was controlled by applying 3.5–6% NaOCl directly to the exposed pulp tissue for a few

minutes, as suggested by several studies.^{9,32} NaOCl is an excellent haemostatic agent as it can disinfect microbiologically contaminated dentinal chips and micro-debris, inhibit fibrin clot formation, and disinfect the adjacent perforated dentin interface.⁹ NaOCl has potent cytotoxicity, and should therefore be handled with care.³³

The ideal capping material for vital pulp therapy should facilitate bridge formation to re-establish an enclosed, protected pulp, be easy to handle, be non-toxic to pulp, have antibacterial properties, be biocompatible, adhere to dentine sufficiently to create a tight seal, have sufficient mechanical strength including hardness, compressive strength and flexural modulus, and facilitate mineral tissue formation by stimulating the differentiation of pulp cells into odontoblasts/odontoblast-like cells.^{34–39} MTA has gained popularity for this purpose and is indicated for use as a pulp capping material.¹² ProRoot MTA (ProRoot MTA, Dentsply Sirona) is commercially available in both white (WMTA) and grey (GMTA) forms. MTA basically consists of calcium, silica and bismuth oxide,^{40–45} but the two products differ in terms of the presence of aluminum, magnesium and iron (GMTA has higher amounts of each).^{40,41} Previous studies have shown that there are no histological differences in the production of a calcified bridge or the pulp inflammatory response between WMTA and GMTA after pulp capping, which was also demonstrated in the two case studies presented here.^{46,47}

Several studies have highlighted the importance of achieving a coronal seal after pulp capping.^{6,48} Despite the fact that MTA provides some seal to tooth structure,⁴⁹ the glass-ionomer material that was placed over the MTA also provided an excellent bacterial seal when used in close proximity to, but not in direct contact with, the pulp.^{50–52} Placement of glass-

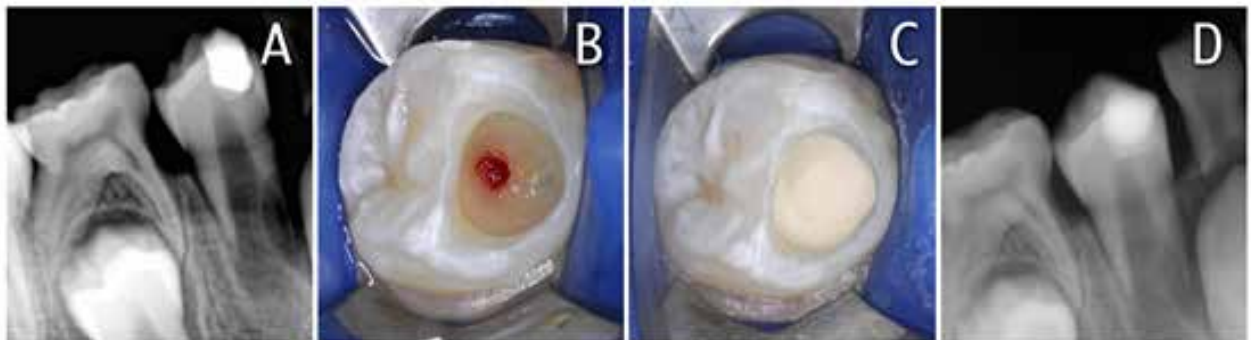


Figure 1: (a) Preoperative radiograph of a mandibular right first premolar with an immature root and recent carious exposure; (b) After removal of the temporary restoration, caries excavation was done under 12X microscope magnification; (c) White ProRoot MTA was placed over the pulp exposure and surrounding dentine; (d) Postoperative periapical radiograph taken after the ProRoot MTA was covered with a glass-ionomer restorative material.

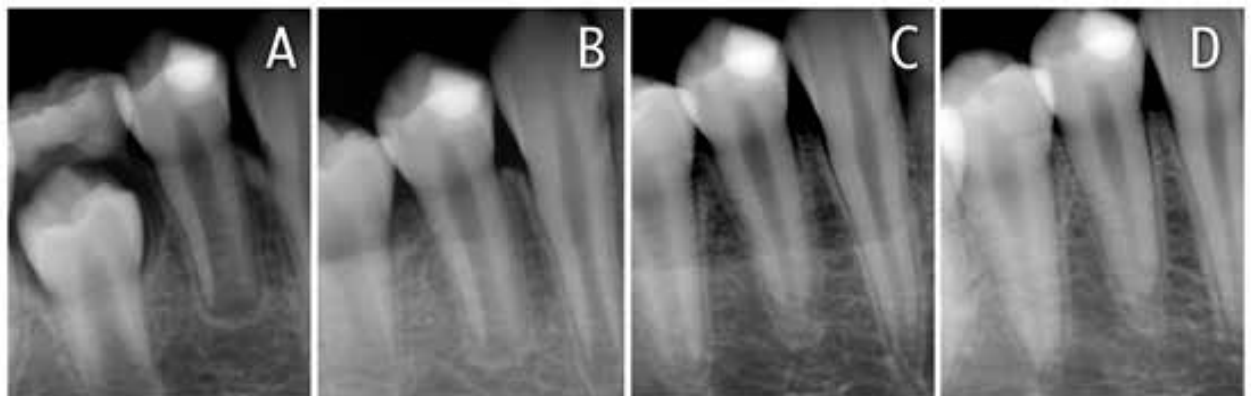

Figure 2: (a) Periapical radiograph taken at the one-year recall visit. Note the continued root development with evidence of a thin dentine bridge at the exposure site; (b) Periapical radiograph taken at the two-year recall visit. Note the continued root development; (c) Periapical radiograph taken at the three-year recall visit clearly showing complete root formation and apex closure; (d) Periapical radiograph taken at the four-year recall visit showing complete root formation with a normal periodontal ligament.

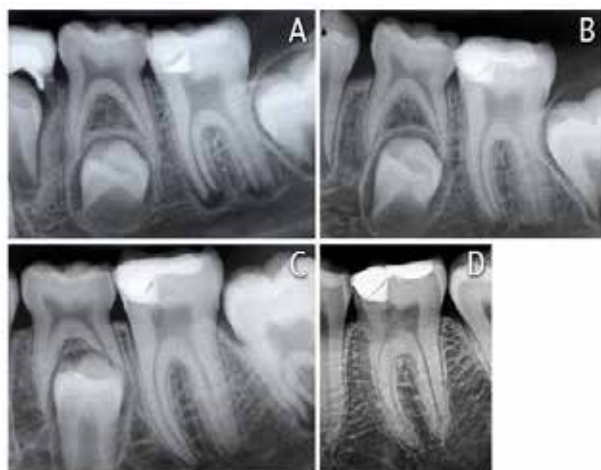

Figure 3: (a) Postoperative periapical radiograph immediately after treatment; (b) Postoperative periapical radiograph taken at the two-year recall visit. Note the continued root development and 0.5 mm dentine bridge that formed at the exposure site; (c) Postoperative periapical radiograph taken at the four-year recall visit. Note the closure of the apices of the mesial and distal roots and an increase in the thickness of the dentine bridge; (d) Postoperative periapical radiograph taken at the 14-year recall visit. The periodontal ligament around the apical third of the mesial root was still widened, and a small calcification or pulp stone formed in the pulp chamber.

ionomer material over MTA is also needed to protect the MTA during restoration placement, thereby allowing for a single-stage pulp capping procedure.⁵² Without this layer of glass-ionomer, it would be necessary to place a water-moistened cotton pellet directly over the unset MTA material, and the patient would need to attend a second appointment for the definitive restoration.⁵²

CONCLUSION

MTA proved to be a reliable pulp capping material on direct carious exposures in immature permanent teeth using a one-visit protocol.

Disclosure

The authors confirm that there are no conflicts of interest related to the case reports depicted in this article.

References

- Rafter M. Apexification: A review. *Dent. Traumatol.* 2005;21:1-8.
- Witherspoon DE. Vital pulp therapy with new materials: New directions and treatment perspectives—permanent teeth. *J. Endod.* 2008;34(7):25-8.
- Cvek M. A clinical report on partial pulpotomy and capping with calcium hydroxide in permanent incisors with complicated crown fracture. *J. Endod.* 1978;4(8):232-7.
- Trope M. Regenerative potential of dental pulp. *J. Endod.* 2008;34(7):S13-S7.
- Cvek M, Cleaton-Jones PE, Austin JC, et al. Pulp reactions to exposure after experimental crown fractures or grinding in adult monkeys. *J. Endod.* 1982;8(9):391-7.
- Barthel CR, Rosenkranz B, Leuenberg A, et al. Pulp capping of carious exposures: Treatment outcome after 5 and 10 years: A retrospective study. *J. Endod.* 2000;26(9):525-8.
- Tronstad L, Mjör IA. Capping of the inflamed pulp. *Oral Surg. Oral Med. Oral Pathol.* 1972;34(3):477-85.
- Mjör IA, Tronstad L. The healing of experimentally induced pulpitis. *Oral Surg. Oral Med. Oral Pathol.* 1974;38(1):115-21.
- Bogen G, Kim JS, Bakland LK. Direct pulp capping with mineral trioxide aggregate: An observational study. *J. Am. Dent. Assoc.* 2008;139(3):305-15.
- Nosrat A, Asgary S. Apexogenesis treatment with a new endodontic cement: A case report. *J. Endod.* 2010;36(5):912-4.
- Katebzadeh N, Dalton BC, Trope M. Strengthening immature teeth during and after apexification. *J. Endod.* 1998;24(4):256-9.
- Torabinejad M, Chivian N. Clinical applications of mineral trioxide aggregate. *J. Endod.* 1999;25(3):197-205.
- Nair MK, Nair UP. Digital and advanced imaging in endodontics: A review. *J. Endod.* 2007;33(1):1-6.
- Haapasalo M, Parhar M, Huang X, et al. Clinical use of bioceramic materials. *Endod. Topics.* 2015;32(1):97-117.
- Ford TRP, Torabinejad M, Abedi HR, et al. Using mineral trioxide aggregate as a pulp-capping material. *J. Am. Dent. Assoc.* 1996;127(10):1491-4.
- Andelin WE, Shabahang S, Wright K, et al. Identification of hard tissue after experimental pulp capping using dentin sialoprotein (dsp) as a marker. *J. Endod.* 2003;29(10):646-50.
- Ford TP, Roberts G. Immediate and delayed direct pulp capping with the use of a new visible light-cured calcium hydroxide preparation. *Oral Surg. Oral Med. Oral Pathol.* 1991;71(3):338-42.
- Dominguez MS, Witherspoon DE, Gutmann JL, et al. Histological and scanning electron microscopy assessment of various vital pulp-therapy materials. *J. Endod.* 2003;29(5):324-33.
- Junn D, McMillan P, Bakland L, et al. Quantitative assessment of dentin bridge formation following pulp capping with mineral trioxide aggregate (mta). *J. Endod.* 1998;24(4):278.
- Asgary S, Eghbal MJ, Parirokh M, et al. A comparative study of histologic response to different pulp capping materials and a novel endodontic cement. *Oral Surg. Oral Med. Oral Pathol. Oral Radiol. Endod.* 2008;106(4):609-14.
- Patel R, Cohenca N. Maturogenesis of a cariously exposed immature permanent tooth using MTA for direct pulp capping: A case report. *Dent. Traumatol.* 2006;22(6):328-33.
- Witherspoon DE, Small JC, Harris GZ. Mineral trioxide aggregate pulp potomies: A case series outcomes assessment. *J. Am. Dent. Assoc.* 2006;137(5):610-8.
- Chng HK, Islam I, Yap AUJ, et al. Properties of a new root-end filling material. *J. Endod.* 2005;31(9):665-8.
- Torabinejad M, Watson T, Ford TP. Sealing ability of a mineral trioxide aggregate when used as a root end filling material. *J. Endod.* 1993;19(12):591-5.
- Parirokh M, Askarifard S, Mansouri S, et al. Effect of phosphate buffer saline on coronal leakage of mineral trioxide aggregate. *J. Oral Sci.* 2009;51(2):187-91.
- Iwamoto CE, Adachi E, Pameijer CH, et al. Clinical and histological evaluation of white proroot MTA in direct pulp capping. *Am. J. Dent.* 2006;19(2):85.
- Goldberg M, Six N, Decup F, et al. Bioactive molecules and the future of pulp therapy. *Am. J. Dent.* 2003;16(1):66-76.
- Güven G, Cehreli ZC, Ural A, et al. Effect of mineral trioxide aggregate cements on transforming growth factor β 1 and bone morphogenetic protein production by human fibroblasts in vitro. *J. Endod.* 2007;33(4):447-50.
- Faraco IM, Holland R. Response of the pulp of dogs to capping with mineral trioxide aggregate or a calcium hydroxide cement. *Dent. Traumatol.* 2001;17(4):163-6.
- Hilton T, Ferracane J, Mancl L. Comparison of CaOH with MTA for direct pulp capping: A pbrn randomized clinical trial. *J. Dent. Res.* 2013;92(7_suppl):S16-S22.
- Farsi N, Alamoudi N, Balto K, et al. Clinical assessment of mineral trioxide aggregate (MTA) as direct pulp capping in young permanent teeth. *J. Clin. Pediatr. Dent.* 2007;31(2):72-6.
- Hafez AA, Cox CF, Tarim B, et al. An in vivo evaluation of hemorrhage control using sodium hypochlorite and direct capping with a one-or two-component adhesive system in exposed nonhuman primate pulps. *Quintessence Int.* 2002;33(4).
- Patel E, Gangadin M. Managing sodium hypochlorite accidents.

- The reality of toxicity. *South African Dental Journal* 2017; 72(6):271-4
34. Bergenholtz G. Advances since the paper by Zander and Glass (1949) on the pursuit of healing methods for pulpal exposures: Historical perspectives. *Oral Surg. Oral Med. Oral Pathol. Oral Radiol. Endod.* 2005;100(2):S102-S8.
 35. Koh E, Torabinejad M, Pitt Ford T, et al. Mineral trioxide aggregate stimulates a biological response in human osteoblasts. *J. Biomed. Mater. Res.* 1997;37(3):432-9.
 36. Zhang S, Yang X, Fan M. Bioaggregate and iroot bp plus optimize the proliferation and mineralization ability of human dental pulp cells. *Int. Endod. J.* 2013;46(10):923-9.
 37. Hashem AAR, Amin SAW. The effect of acidity on dislodgement resistance of mineral trioxide aggregate and bioaggregate in furcation perforations: An in vitro comparative study. *J. Endod.* 2012;38(2):245-9.
 38. Namazikhah M, Nekoofar MH, Sheykhrezae M, et al. The effect of ph on surface hardness and microstructure of mineral trioxide aggregate. *Int. Endod. J.* 2008;41(2):108-16.
 39. Caronna V, Himel V, Yu Q, et al. Comparison of the surface hardness among three materials used in an experimental apexification model under moist and dry environments. *J. Endod.* 2014;40(7):986-9.
 40. Asgary S, Parirokh M, Eghbal MJ, et al. Chemical differences between white and gray mineral trioxide aggregate. *J. Endod.* 2005;31(2):101-3.
 41. Asgary S, Parirokh M, Eghbal MJ, et al. A qualitative x-ray analysis of white and grey mineral trioxide aggregate using compositional imaging. *J. Mater. Sci. Mater. Med.* 2006;17(2):187-91.
 42. Asgary S, Parirokh M, Eghbal M, et al. A comparative study of mineral trioxide aggregate and white portland cements using x-ray analysis. *Aust. Dent. J.* 2004;30:86-9.
 43. Asgary S, Shahabi S, Jafarzadeh T, et al. The properties of a new endodontic material. *J. Endod.* 2008;34(8):990-3.
 44. Asgary S, Eghbal MJ, Parirokh M, et al. Comparison of mineral trioxide aggregate's composition with portland cements and a new endodontic cement. *J. Endod.* 2009;35(2):243-50.
 45. Parirokh M, Torabinejad M. Mineral trioxide aggregate: A comprehensive literature review—part iii: Clinical applications, drawbacks, and mechanism of action. *J. Endod.* 2010;36(3):400-13.
 46. Parirokh M, Asgary S, Eghbal MJ, et al. A comparative study of white and grey mineral trioxide aggregate as pulp capping agents in dog's teeth. *Dent. Traumatol.* 2005;21(3):150-4.
 47. Eskandarizadeh A, Shahpasandzadeh MH, Shahpasandzadeh M, et al. A comparative study on dental pulp response to calcium hydroxide, white and grey mineral trioxide aggregate as pulp capping agents. *J Conserv Dent.* 2011;14(4):351.
 48. Cox CF, Keall CL, Keall HJ, et al. Biocompatibility of surface-sealed dental materials against exposed pulps. *J. Prosthet. Dent.* 1987;57(1):1-8.
 49. Luketić SF, Malčić A, Jukić S, et al. Coronal microleakage of two root-end filling materials using a polymicrobial marker. *J. Endod.* 2008;34(2):201-3.
 50. Heys R, Fitzgerald M. Microleakage of three cement bases. *J. Dent. Res.* 1991;70(1):55-8.
 51. Murray P, Hafez A, Windsor L, et al. Comparison of pulp responses following restoration of exposed and non-exposed cavities. *J. Dent.* 2002;30(5):213-22.
 52. Hilton TJ. Keys to clinical success with pulp capping: A review of the literature. *Oper. Dent.* 2009;34(5):615-25.

register online @ <https://sadacongress.co.za/register.html>

DENTAL ORAL HEALTH
CONGRESS AND EXHIBITION

12-14 OCTOBER 2018 Sun Time Square Arena and Conference Centre, Pretoria SADA

BOOK YOUR SEAT FOR THIS EVENT

You are invited to join an **excellent line up of International and Local speakers** sharing **innovative technology and services** from within a melting pot of the **best in oral health care that the world has to offer**