

Surgical enucleation of unilateral mandibular radicular cysts in an 11-year-old Thoroughbred mare

L. A. Poore^{†*}, T. J. Scase[‡] and J. A. Kidd[§]

[†]The Department of Companion Animal Clinical Studies, Faculty of Veterinary Science, University of Pretoria, Onderstepoort, South Africa;

[‡]Bridge Pathology Ltd, Horfield, Bristol; and

[§]Dr Jessica Kidd Limited, Stanford-in-the-Vale, Oxfordshire, UK.

*Corresponding author email: luke.poore@up.ac.za

Summary

An 11-year-old Thoroughbred broodmare was diagnosed with extensive radicular cysts that affected the left horizontal mandibular ramus. A left mandibular swelling was present clinically, and mandibular lesions appearing cystic in nature were identified with successive radiographic and ultrasonographic examinations. Surgical enucleation of the cysts was performed under a standing sedation protocol and the excised cystic structures submitted for histopathological analysis. Histological examination of the cystic structures confirmed a diagnosis of multiple radicular cysts.

Keywords: horse; radicular; cyst; mandible; mononuclear infiltrate; odontogenic

Introduction

A cyst is an epithelium-lined cavity of pathological origin containing fluid or semisolid material (Kramer 1974; Lovas 1991; Reichart and Philipsen 2000; Ellis 2008). During cyst formation, epithelial cells proliferate and subsequently undergo degeneration and liquefaction (Shear and Seward 1992). The liquefied cyst contents exert pressure on the cyst walls producing a spherical structure (Ellis 2008). As cysts developing within the jaw undergo expansion, adjacent teeth can become displaced and the adjacent cortical bone of the jaw is resorbed becoming deformed and weaker (Ellis 2008; Verstraete *et al.* 2011). Radiographic examinations of cystic structures usually reveal central areas of radiolucency surrounded by a radiopaque periphery of sclerotic bone. The radiolucency may be unilocular or multilocular (Blanas *et al.* 2000; Underbrink and Pou 2002; Ellis 2008).

Cysts located in and around the oral cavity are classified as odontogenic cysts, facial cleft cysts (fissural cysts) and other cysts (nonepitheliated bone cysts, mucous retention cysts and developmental defect cysts) (Ellis 2008). Odontogenic cysts arise from epithelium associated with developing teeth (odontogenic epithelium) during development or as a result of an inflammatory process (Regezi and Sciubba 1993; Blanas *et al.* 2000; Reichart and Philipsen 2000; Ellis 2008). Epithelium from the enamel organ, the cell rests of Malassez or the remnants of the dental lamina are thought to be the sources of odontogenic cysts in animals (Baker *et al.* 1993; Blanas *et al.* 2000).

Reported odontogenic cysts include radicular cysts, dentigerous cysts and keratocysts (Poulet *et al.* 1992; French and Anthony 1996; Reiter 2001; Beckman 2003; Watanabe *et al.* 2004). The classification system for odontogenic cysts in animals is based on the human system and is controversial (Doran *et al.* 2008).

Radicular cysts are the most common type of oral cyst in humans (Koseoglu *et al.* 2004) but are rare findings in animals (Poulet *et al.* 1992; Verstraete *et al.* 2011) and have only been reported in the dog (French and Anthony 1996; Reiter 2001; Beckman 2003; Verstraete *et al.* 2011). Radicular cysts, unlike other odontogenic cysts, are associated with an inflammatory infiltrate (Head *et al.* 2002).

There are no previous reports of radicular cysts in the horse. This paper reports the first confirmed report of a radicular cyst in a horse and describes successful surgical treatment.

Case details

An 11-year-old Thoroughbred broodmare, 7 months in foal, was referred with a 16-week history of focal swelling of the left horizontal mandibular ramus. She had undergone previous examinations by the referring veterinary surgeon. On the first examination, no abnormalities in mentation, mastication or drinking had been evident. An oral examination with a dental mirror and light source was undertaken revealing no evidence of periodontal disease or defects associated with the secondary dentine of the occlusal surfaces of the molars. No abnormalities with the pregnancy were detected, and the mare's clinical parameters were unremarkable. The swelling had appeared acutely and was painful on palpation. A radiographic examination (Fig 1) of the swelling showed a roughly spherical soft tissue opacity adjacent to the left mandible ventral to the apices of the 308 and 309 teeth. Two radiolucent lines thought to be tracts were visible within the swelling. An abscess, possibly involving a tooth root, was considered most likely and the mare was treated with oral trimethoprim sulphonamide (30 mg/kg Norodine¹). A further clinical, radiographic and oral examination with a dental mirror and light source was performed 1 month later. The oral examination was again unremarkable with no periodontal or occlusal surface defects evident and the mare had normal clinical parameters. However, the radiographic examination revealed deformation of the ventral aspect of the left mandibular ramus with thickening of the mandibular cortex adjacent to a radiolucent area and thinning of the mandibular cortex rostral to this area. Multiple radiolucent areas were shown to have developed, but the areas were filled with tissue of a heterogenous density (Fig 2). The abnormal areas were now found to extend caudally to the 310 tooth.

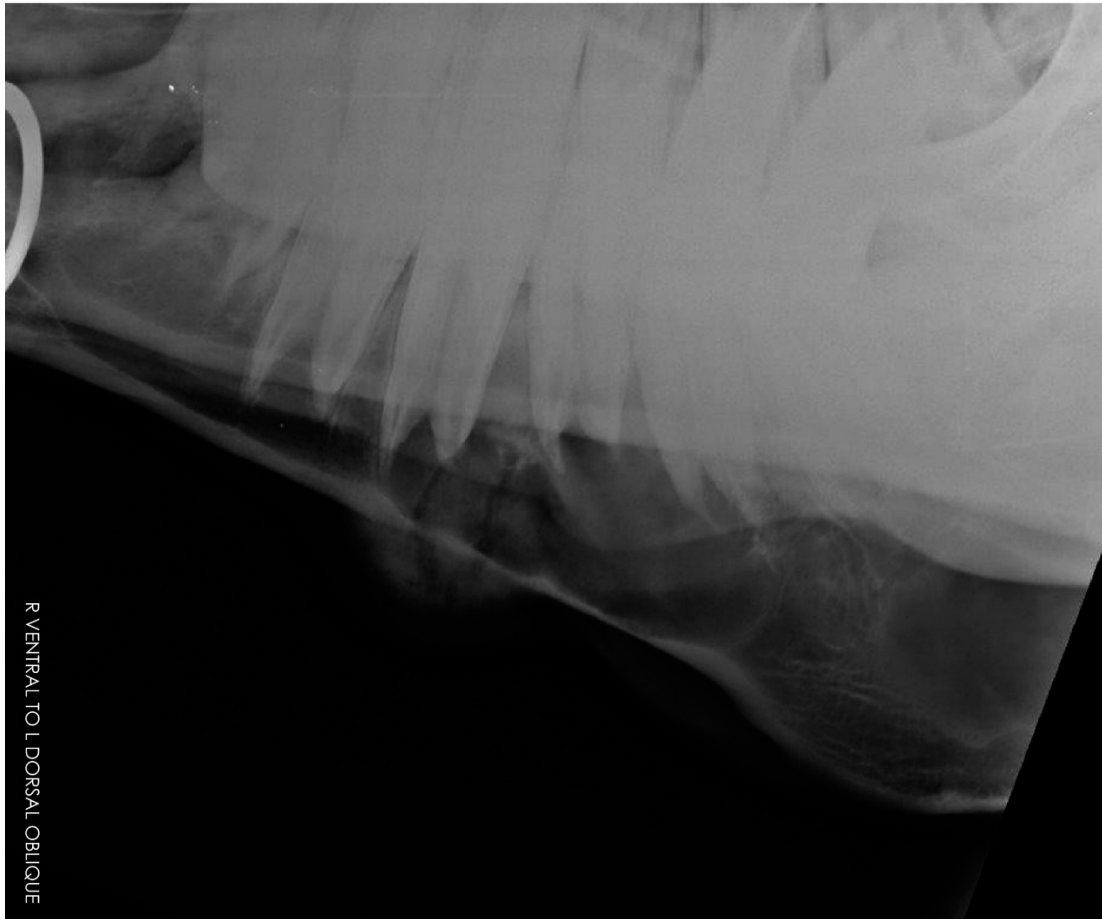


Figure 1. A latero 34–45° ventral-laterodorsal oblique radiograph of the left ramus of the mandible obtained on the day of presentation to the referring veterinary surgeon. There is a roughly spherical soft-tissue opacity and bony remodelling ventral to the roots of 308 and 309 with two vertical radiolucent lines within the swelling. The caudal radiolucent line appears to run towards some sclerosis ventral to the rostral root of 309. The tooth roots appear normal and there is involvement of the bone of the mandible which has some sclerosis, ventral remodelling and lucent lines in it.

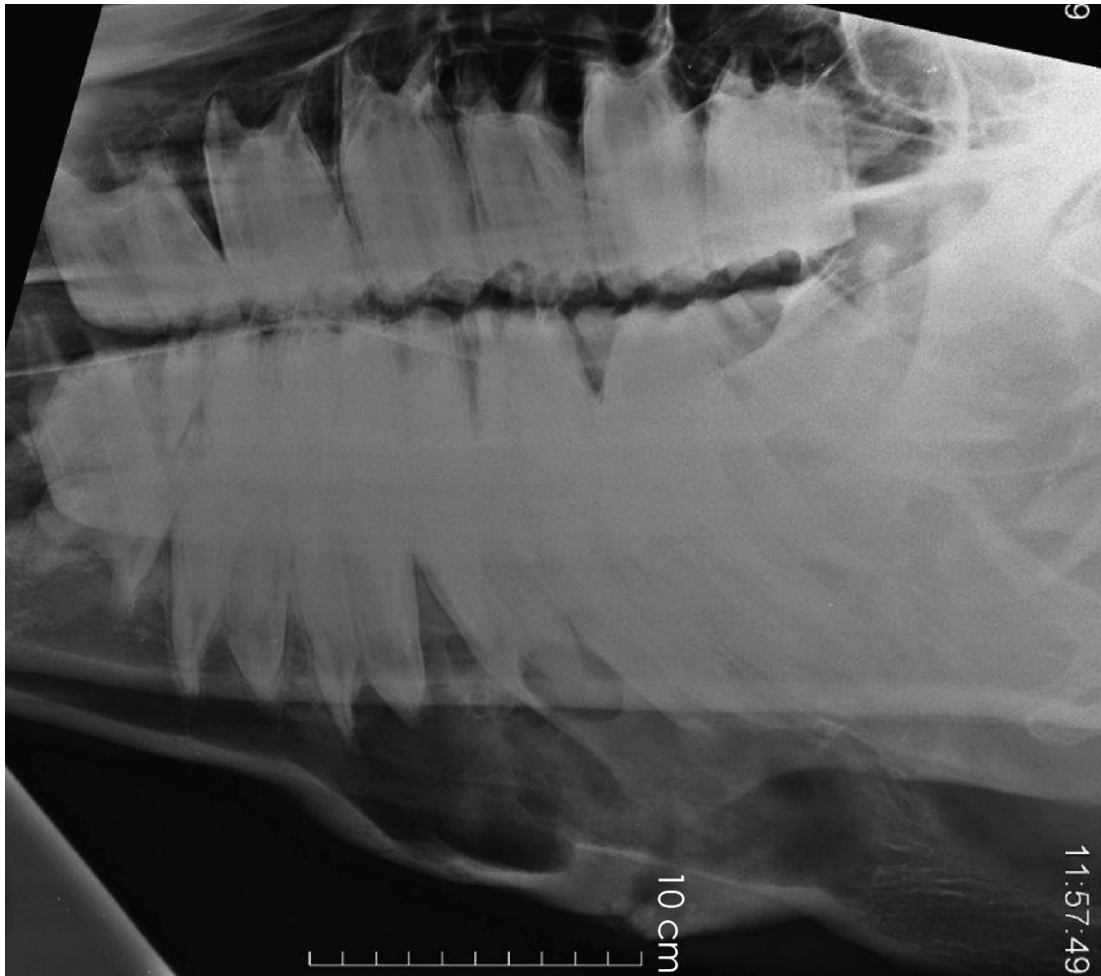


Figure 2. A latero 34–45° ventral-laterodorsal oblique radiograph of the left mandibular arcade taken 5 weeks after the primary presentation to the referring veterinary surgeon. Note the appearance has changed with more radiolucent areas in a caudal position but is not convincingly diagnostic of a cystic structure although the area associated with the caudal aspect of tooth 309 is suspicious. On this examination, the bone of the mandible is involved with a radiolucent line through the bone and exiting the ventral mandible. In the area of this radiolucent line, the bone has thickened while rostral to this area there is thinning of the mandibular cortex.

The mare was maintained in a small paddock, given no further treatment and referred 3 months after the second examination due to a lack of resolution of the swelling. Her clinical parameters at presentation were unremarkable, but there was evidence of a left submandibular lymphadenopathy. Her pregnancy was considered normal for the stage of gestation. An oral examination with a dental mirror, light source and periodontal probe revealed no abnormalities associated with periodontal or periapical disease. The occlusal surfaces of the molars of the third arcade were smooth with no evidence of fissures or defects of the secondary dentine. Palpation of the left horizontal mandibular ramus revealed a large firm nonpainful swelling similar to the adjacent normal mandibular bone with two softer areas palpable at the ventral aspect of the swelling.

A radiographic examination of the left mandible now revealed multiple spherical to ovoid, well-demarcated radiolucent cavities consistent with the appearance of cystic structures (Fig 3a). The cystic cavities were found to be adjacent to the apices of 308–311 teeth, and there were morphological changes in the apices of the 308 and 309 teeth. An ultrasonographic examination of the swelling confirmed the presence of multiple fluid filled structures within the left horizontal mandible.

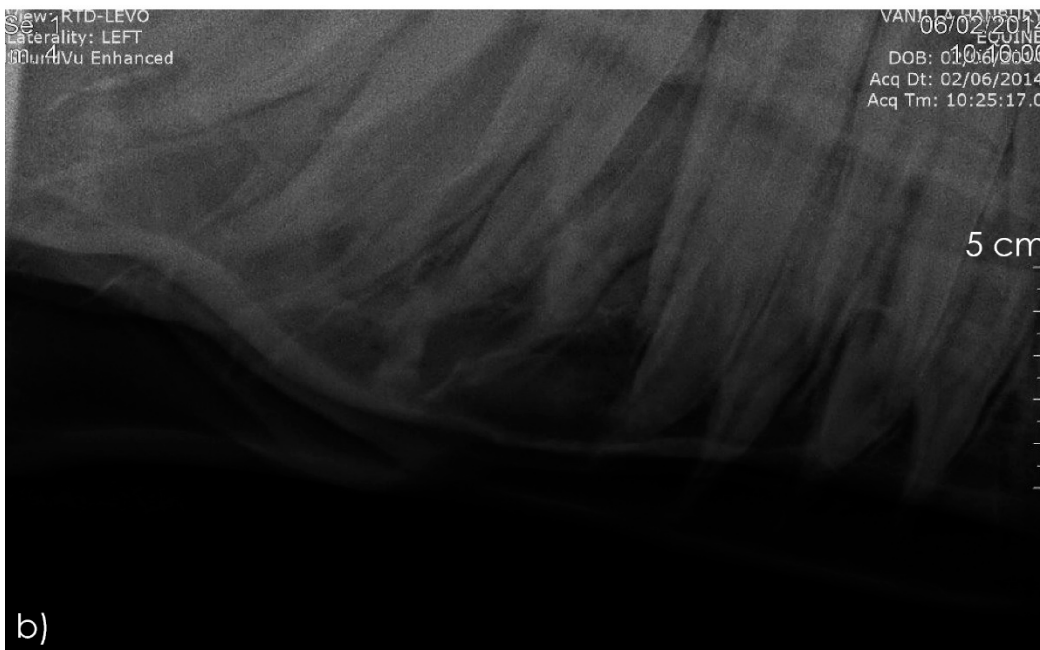
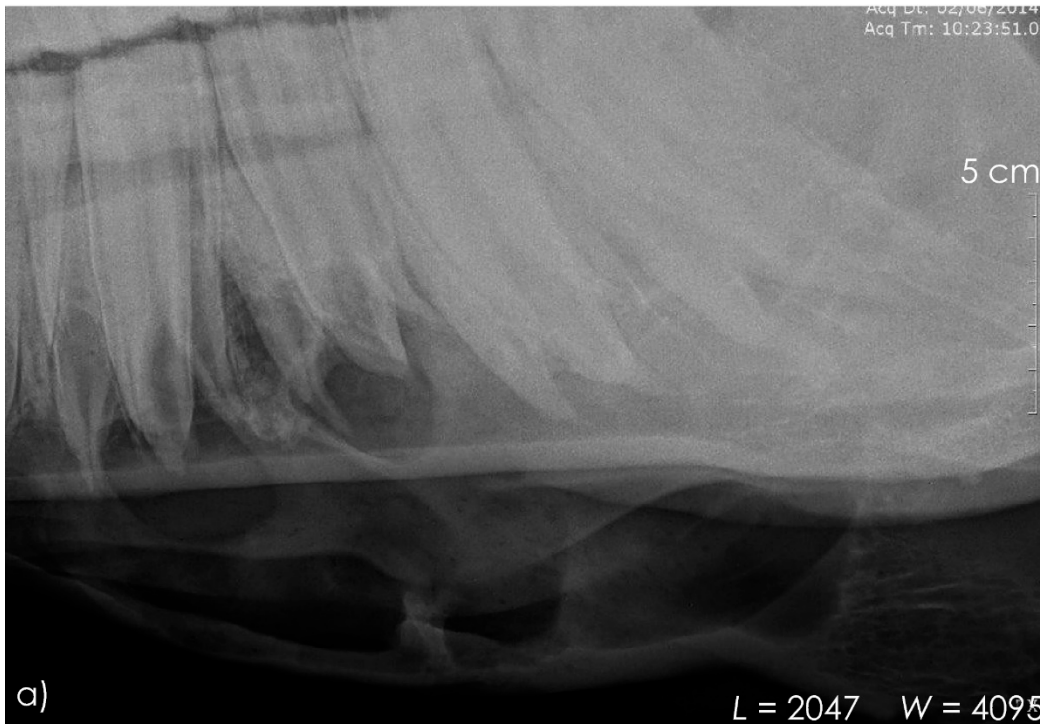

Figure 3. a) A latero 34–45° ventral-laterodorsal oblique radiograph of the left mandibular arcade obtained 4 months after the mandibular swelling was first noted. Multiple spherical to ovoid well demarcated radiolucent cavities consistent with cystic structures are evident. b) A latero 34–45° ventral-laterodorsal oblique radiograph of the right mandibular arcade obtained during the same examination as Fig 3a, showing the normal contralateral side of the mandible.

An intravenous catheter was aseptically placed in the left jugular vein, and a sedation protocol of detomidine (10 µg/kg bwt; Alvegesic²) and butorphanol (0.1 mg/kg bwt; Torbugesic²) was initiated. Perioperative anti-inflammatory treatment with phenylbutazone (8.8 mg/kg bwt: Equipalazone²) and antibiotic therapy with trimethoprim sulphonamide (30 mg/kg bwt: Norodine¹) was administered. Local anaesthesia was achieved using mepivacaine (Intra-Epicaine²) injected as a local subcutaneous infusion at the site of the

ventral swelling, centred over a soft depression. A single linear horizontal incision was made at the site of the ventral swelling, and a large volume of clear yellow fluid was released. The bone lining the cavities was curetted as thoroughly as access would allow and both bone and soft tissue specimens collected. Care was taken not to damage the tooth roots by directing curettage medially and laterally. The incision was closed with stainless steel staples³. Samples of the excised cyst walls, the cyst contents and cortical bone originating from the mandibular ramus were submitted for cytological and histopathological analysis. The mare was discharged the same day with instructions to be maintained on box rest until the staples had been removed 12 days post-operatively. Antibiotic therapy with trimethoprim sulphonamide (30 mg/kg bwt: Norodine¹) was requested for a further 4-day period.

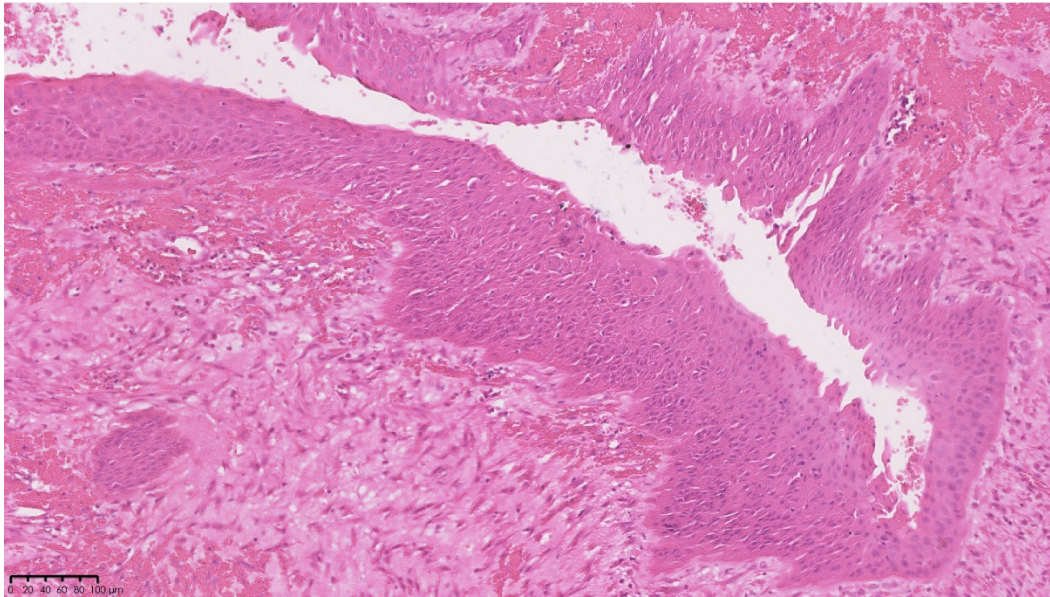


Figure 4. A photomicrograph showing cyst lining, made up of stratified squamous epithelium, partially lining a cystic space. This epithelium is supported by well-organised fibrovascular connective tissue stroma.

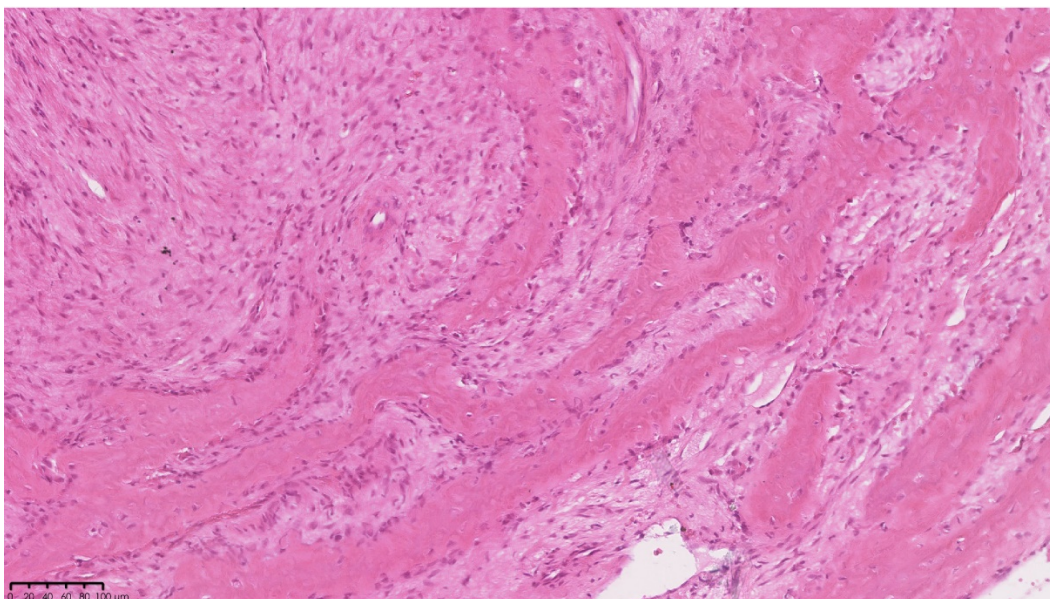


Figure 5. A photomicrograph showing extensive remodelling of the bone underlying the cystic structures with adjacent fibrosis.

The mare was re-examined as an outpatient 5 weeks later when she was clinically unremarkable and was having no difficulty eating or drinking. She was 8 months in foal and in a normal body condition for the stage of pregnancy.

The swelling on the horizontal ramus of the left mandible was much reduced, and the remaining area of swelling was nonpainful on palpation. The palpable osseous cystic cavities had decreased in size, and there was a 3 mm² area of granulation tissue over the previous incision site, which was reported to discharge a small amount of mucopurulent material daily. A fine needle aspirate produced a haemorrhagic fluid sample with greater viscosity compared to the cystic fluid previously recovered. The owners of the mare were instructed to apply a topical emollient daily to protect the skin from any discharge and irritation. She produced a healthy foal 3 months later and the discharge from the mandible stopped shortly after the birth of the foal.

Three years later, the mare was clinically unremarkable with a normal appearance to the mandible, no residual swelling or drainage and no abnormalities evident on an oral examination with a dental mirror and periodontal probe.

Cytological and histopathological analysis

Cytological evaluation of the cyst contents showed no evidence of neoplastic cells and a sparse population of polymorphonuclear cells. Histopathological analysis of the cyst wall and cortical bone confirmed the diagnosis of a radicular cyst with moderate fibrosis, bone resorption and remodelling and confirmed no evidence of a neoplastic component.

Sections of submitted cortical bone were composed of reactive bone, with well-organised osteocytes present throughout the bone trabeculae. There was moderate remodelling of this bone with scattered clusters of multinucleated osteoclasts present adjacent to the scalloped edges of the bony spicules. Extensive accumulations of well-organised, variably dense fibrovascular connective tissue were present supporting and surrounding the bony spicules. Scattered neutrophils, lymphocytes, macrophages and plasma cells were present within the stroma with accumulations of well-organised, stratified squamous epithelium supported by moderate amounts of well-organised fibrovascular connective tissue. An irregular, indistinct basement membrane was present beneath the epithelium with scattered neutrophils and lymphocytes infiltrating the epithelium. Occasional keratinocytes were seen to exhibit dyskeratosis (Figs 4 and 5).

Discussion

Odontogenic cysts of the jaw are rare in domestic animals (Poulet *et al.* 1992; Head *et al.* 2002; Verstraete *et al.* 2011). Radicular cysts are the most common cystic lesion of human jaws and are normally related to teeth with a nonvital pulp cavity (Shear and Seward 1992; Underbrink and Pou 2002; Slootweg 2009). Many radicular cysts in humans are symptomless and are only diagnosed when radiographic examinations of devitalised teeth are performed (Shear and Seward 1992). Multiple radicular cysts in individual humans are often reported (Stoelinga 1973). An association between radicular cysts in dogs and devitalised teeth has also been made (Verstraete *et al.* 2011) with this association proposed as an important criterion for identifying radicular cysts (Regezi and Sciubba 1993). The association with a nonvital tooth has also been used to differentiate a radicular cyst from a dentigerous cyst (Slootweg 2009). The importance of this association has been emphasised as radicular cysts

do not have a specific histological appearance and have no remarkable features, compared with other odontogenic cysts (Slootweg 2009). Treatment of a radicular cyst associated with a nonvital maxillary first incisor tooth in a dog consisted of enucleation, curettage and osteoplasty in addition to extraction of the nonvital tooth (Verstraete *et al.* 2011).

During embryogenesis, mesenchyme-derived fibroblasts penetrate an ectodermal membrane, Hertwig's Sheath, to form the periodontal ligament (Sperber 1993). This sheath located in the apical region of the tooth root subsequently regresses leaving remnants within the newly formed periodontal ligament that are known as the cell rests of Malassez (Moore 2011). Cell rests of Malassez are stimulated to form cystic structures in the presence of inflammation and to occur most commonly as a result of chronic apical periodontitis secondary to microbial invasion into the pulp cavity of a tooth (Shear and Seward 1992; Moore 2011). There was no definitive evidence of endodontic, periapical or periodontal disease of the adjacent teeth; however, there was radiographic evidence of changes in the apical morphology in two of the teeth. A computed tomography (CT) examination may have provided more information. Monitoring of the cheek teeth in the third arcade will be necessary in the future to ensure that no signs of dental disease develop in due course.

Oral examination in this case with a dental mirror and probing of the gingival attachment and occlusal surfaces of the molars failed to identify a periodontal source of infection at the apical regions and revealed regular occlusal surfaces with no evidence of secondary dentinal fissures or defects. Although oral antibiotic therapy was commenced by the referring vet, this has been shown to almost never be effective in treating apical infections of equine teeth (Dixon *et al.* 2000).

Odontogenic cysts in horses are predominately dentigerous cysts with one report of a keratocyst (Delaunois-Vanderperren 2013) and no reports of radicular cysts. Dentigerous cysts in horses have been reported to be congenital defects with incomplete closure of the first branchial cleft during embryogenesis (Carr 2012). The inclusion of dental lamina cell rests in this area may also be implicated in their aetiology (Rashmir-Raven *et al.* 1990). In contrast to radicular cysts, dentigerous cysts and keratocysts are not associated with an inflammatory infiltrate.

Congenital and developmental dental conditions have been related to heritability in cattle (DeBowes and Gaughan 1998) and have been suggested in horses (Baker 1982).

Nutritional factors were suggested as a causative factor in a case of unilateral odontogenic keratocyst in a new-born filly (Delaunois-Vanderperren 2013). Extensive loss of mandibular trabecular bone and the formation of extensive fibrous connective tissue proliferation between the bony trabeculae in this case was consistent with fibrous osteodystrophy. Fibrous osteodystrophy is seen in horses with nutritional secondary hyperparathyroidism due to low calcium/high phosphorous diets (Weisbrode 2007) and is currently a rarely diagnosed condition due to improvements in equine nutrition.

Odontogenic cysts have been diagnosed in animals using a combination of patient case details, anamnesis, clinical examination, radiographic examination, nuclear scintigraphy, computed tomography and histopathological analysis (Cook 1970; Lamb and Schelling 1989; Doran *et al.* 2008; Moore 2011; Delaunois-Vanderperren 2013). Magnetic resonance imaging (MRI) has also been suggested as a useful imaging modality in the diagnosis of odontogenic cysts (Scully *et al.* 2010; Delaunois-Vanderperren 2013) as presumably would computed

tomography. These imaging modalities would also have helped eliminate dental pathology as a cause of the swelling of the cyst, as seen in other species.

The histopathological findings in this case were consistent with the clinical history and the results of the radiographic and ultrasonographic examinations suggestive of mandibular cysts. Areas of bone resorption and bone remodelling, adjacent to accumulations of well-differentiated stratified squamous epithelium, were consistent with the formation of benign epithelium-lined radicular cysts within the mandible. The bony remodelling, the proliferation of fibrous connective tissue and the low-grade inflammation within the surrounding tissue reflect a response to the expanding cystic structures. There was no indication of epithelial atypia to suggest a neoplastic process at the site of the cysts.

In this case, multiple extensive cystic lesions of the left mandible were found to be in close association with the tooth roots but presumed to have no involvement with them and fulfilled the criteria of an odontogenic radicular cyst.

Successful treatment of radicular cysts using surgical curettage of the cyst lining, as in this case, has been reported in dogs (Schrader *et al.* 1983; French and Anthony 1996; Beckman 2003; Doran *et al.* 2008) with recurrence of the cyst uncommon (Poulet *et al.* 1992). Successful surgical reduction of odontogenic cysts in horses has also been described by 'en bloc' resection (DeBowes and Gaughan 1998; Delaunois-Vanderperren 2013).

Filling of a cystic cavity after surgical reduction with decalcified freeze-dried bone or an autogenous cancellous bone graft has been suggested in dogs and horses depending on the cyst location and the need to enhance skeletal support at the site (Schrader *et al.* 1983; DeBowes and Gaughan 1998; Doran *et al.* 2008). These techniques could have been utilised in this case to assist in post-operative healing. Removal of compromised teeth due to displacement by radicular cysts has been recommended (Doran *et al.* 2008) and may still have to be considered in the future if any signs of dental disease are identified on oral examination.

Surgical curettage was used to successfully treat extensive radicular cysts in this case and resulted in a return to normal appearance of the mandible.

The initial radiographs were not consistent with cyst formation, which could lead to the lack of an initial diagnosis in the early stages of similar cases or an unduly pessimistic or incorrect prognosis. With time, the radiographic appearance of the cysts became more obvious facilitating diagnosis. Additional imaging modalities such as nuclear scintigraphy, magnetic resonance imaging and computed tomography may have been of benefit in this case.

Clinical relevance

To our knowledge, there are no previous reports of radicular cysts in the horse. Radicular cysts should be considered in the differential diagnosis of mandibular swellings in horses. Surgical curettage of the radicular cysts in this case report enabled a full resolution of the clinical signs in the follow-up period and is recommended in the treatment of radicular cysts in horses.

Author's declaration of interests

No conflicts of interest have been declared.

Ethical animal research

No ethical review was required as this is a case study. The owners of the mare described in the present case gave their consent for publication.

Source of funding

The authors received no financial support for the research, authorship and publication of this article.

Antimicrobial stewardship policy

The mare in this case report did not receive quinolones, extended spectrum beta-lactam antimicrobials or macrolides.

Acknowledgements

The authors thank Millie Steward-Wood MRCVS for referring this case.

Authorship

Dr Poore and Dr Kidd were responsible for production of the manuscript. Dr Scase was responsible for the cytological and histopathological analysis.

Manufacturers' addresses

¹Norbrook, Corby, Northamptonshire, UK.

²Dechra Veterinary Products, Shrewsbury, Shropshire, UK.

³Covidien, Fareham, Hampshire, UK.

References

Baker, G.J. (1982) Diseases of the teeth and paranasal sinuses. In: Equine Medicine and Surgery, 3rd edn., Eds: R.A. Mansmann, E.S. McAllister and P.W. Pratt, American Veterinary Publishing, Santa Barbara. pp 437- 476.

Baker, I., Van Dreumel, A. and Palmer, N. (1993) Alimentary system. In: Pathology of Domestic Animals, 4th edn., Eds: K. Jubb, P. Kennedy and N. Palmer, Academic Press, San Diego. pp 1- 318.

Beckman, B.W. (2003) Radicular cyst of the premaxilla in a dog. *J. Vet. Dent.* 20, 213- 217.

- Blanas, N., Freund, B., Schwartz, M. and Furst, I.M. (2000) Systematic review of the treatment and prognosis of the odontogenic keratocyst. *Oral Surg. Oral Med. Oral Pathol. Oral Radiol. Endod.* 90, 553- 558.
- Carr, E.A. (2012) Skin conditions amenable to surgery. In: *Equine Surgery*, 4th edn., Eds: J.A. Auer, and J.A. Stick, Elsevier Saunders, Missouri. pp 327- 338.
- Cook, W.R. (1970) Skeletal radiology of the equine head. *J. Am. Vet. Radiol. Soc.* 11, 35- 55.
- DeBowes, R.M. and Gaughan, E.M. (1998) Congenital dental disease of horses. *Vet. Clin. North Am. Equine Pract.* 14, 273- 289.
- Delaunoy-Vanderperren, H. (2013) Congenital odontogenic keratocyst in a filly. *Equine Vet. Educ.* 25, 179- 183.
- Dixon, P.M., Tremaine, W.H., Pickles, K., Kuhns, L., Hawe, C., McCann, J., McGorum, B.C., Railton, D.I. and Brammer, S. (2000) Equine dental disease part 4: a long-term study of 400 cases: apical infections of cheek teeth. *Equine Vet. J.* 32, 182- 194.
- Doran, I., Pearson, G., Barr, F. and Hotson Moore, A. (2008) Extensive bilateral odontogenic cysts in the mandible of a dog. *Vet. Pathol.* 45, 58- 60.
- Ellis, E. (2008) Surgical management of oral pathologic lesions. In: *Contemporary Oral and Maxillofacial Surgery*, 3rd edn., Eds: E. Peterson, J.R. Ellis, M.R. Hupp and M.R. Tucke, Mosby Elsevier, Missouri. pp 449- 468.
- French, S.L. and Anthony, J.M.G. (1996) Surgical removal of a radicular odontogenic cyst in a four year old Dalmatian dog. *J. Vet. Dent.* 13, 149- 151.
- Head, K.W., Else, R.W. and Dubielzig, R.R. (2002) Tumors of the alimentary tract. In: *Tumors in Domestic Animals*, 4th edn., Eds: D.J. Meuten, Iowa State Press, Ames. pp 401- 481.
- Koseoglu, B.G., Atalay, B. and Erdem, M.A. (2004) Odontogenic cysts: a clinical study of 90 cases. *J. Oral Sci.* 46, 253- 257.
- Kramer, I.R. (1974) Changing views on oral disease. *Proc. R. Soc. Med.* 67, 271- 276.
- Lamb, C.R. and Schelling, S.H. (1989) Congenital aneurismal bone cyst in the mandible of a foal. *Equine Vet. J.* 21, 130- 132.
- Lovas, J. (1991) Cysts. In: *Oral and Maxillofacial Radiology: Radiologic/pathologic Correlations*, 2nd edn., Eds: D.A. Miles, G.E. Kaugars and M. Van Dis, W.B. Saunders, Philadelphia. pp 21- 50.
- Moore, U.J. (2011) Treatment of cysts of the jaw. In: *Principles of Oral and Maxillofacial Surgery*, 6th edn., Ed: U.J. Moore. Wiley Blackwell, Iowa. pp 225- 243.
- Poulet, F.M., Valentine, B.A. and Summers, B.A. (1992) A survey of epithelial odontogenic tumours and cysts in dogs and cats. *Vet. Pathol.* 29, 369- 380.

Rashmir-Raven, A., DeBowes, R. and Cash, W. (1990) Dentigerous cysts. *Compend. Contin. Educ. Pract. Vet.* 12, 1120.

Regezi, J.A. and Sciubba, J. (1993) Cysts of the oral region. In: *Oral Pathology, Clinical-Pathologic Correlations*, 2nd edn., Eds: J.A. Regezi and J. Sciubba, W.B. Saunders, Philadelphia, PA. pp 322- 361.

Reichart, P.A. and Philipsen, H.P. (2000) Epithelial cysts of the jaw. In: *Colour Atlas of Dental Medicine. Oral Pathology*, 1st edn., Eds: P.A. Rateitschak, K.H. Herbert and F. Wolf, Georg Thieme Verlag, New York. pp 206- 219.

Reiter, A.M. (2001) Periapical cyst formation of the left maxillary third incisor tooth in an adult Standard Poodle. *Proc. 15th Annual Dent. Forum* 1, 149- 150.

Schrader, S.C., Burk, R.L. and Liu, S.K. (1983) Bone cysts in two dogs and a review of similar cystic bone lesions in the dog. *J. Am. Vet. Med. Assoc.* 182, 490- 495.

Scully, C., Flint, S.R., Bagan, J.V, Porter, S.R. and Moos, K.F. (2010) Jaws. In: *Oral and maxillofacial diseases*, 4th edn., Eds: C. Scully, S.R. Flint, J.V. Bagan, S.R. Porter and K.F. Moos, Informa Healthcare, London. pp 324- 343.

Shear, M. and Seward, G.R. (1992) Radicular cyst, residual cyst, paradental cyst and mandibular infected buccal cyst. In: *Cysts of the Oral Regions*, 3rd edn., Eds: M. Shear and G.R. Seward, Elsevier Health Sciences, London. pp 136- 170.

Slootweg, P.J. (2009) Lesions of the jaws. *Histopathology* 54, 401- 418.

Sperber, G.H. (1993) Development of the dentition (odontogenesis). In: *Craniofacial Embryology*, 4th edn., Ed: G.H. Sperber, Butterworth-Heinemann, London. pp 215- 228.

Stoelinga, P.J. (1973) Recurrences and multiplicity of cysts. *Trans. Int. Conf. Oral Surg.* 4, 77- 80.

Underbrink, M. and Pou, A. (2002) Odontogenic Cysts and Tumours. Grand Rounds Presentation, Dept of Otolaryngology, UTMB.

Verstraete, F.J., Zin, B.P., Kass, P.H., Cox, D.P. and Jordan, R.C. (2011) Clinical signs and histologic findings in dogs with odontogenic cysts: 41 cases (1995–2010). *J. Am. Vet. Med. Assoc.* 239, 1470- 1476.

Watanabe, K., Kadosawa, T., Ishiguro, T., Takagi, S., Ochiai, K., Kimura, T., Okumura, M. and Fujinaga, T. (2004) Odontogenic cysts in three dogs: one odontogenic keratocyst and two dentigerous cysts. *J. Vet. Med. Sci.* 66, 1167- 1170.

Weisbrode, S.E. (2007) Bones and joints. In: *Pathologic Basis Of Veterinary Disease*, 4th edn., Eds: D.M. McGavin and J.F. Zachary, Mosby ELSEVIER, Missouri. pp 1041- 1105.