

COMMENTARY

Mass die-off of African elephants in Botswana: pathogen, poison or a perfect storm?

Shahan Azeem¹ (ID)[§], Roy Bengis², Rudi van Aarde³ & Armanda D.S. Bastos^{3,4*} (ID)

¹Virology Section, Institute of Microbiology, University of Veterinary and Animal Sciences, Lahore, Pakistan

²Retired Chief State Veterinarian, Kruger National Park, South Africa

³Department of Zoology and Entomology, University of Pretoria, Pretoria, South Africa

⁴Centre for Veterinary Wildlife Studies, Faculty of Veterinary Science, University of Pretoria, Onderstepoort, South Africa

Received 17 July 2020. To authors for revision 22 July 2020. Accepted 22 July 2020

Reports of a mass die-off of ~350 elephants (*Loxodonta africana*) in northern Botswana over a period of two months (May–June 2020), has fuelled speculation and concern regarding the cause. Although the area in which these mortalities occurred is not protected and is considered a hotspot for human–elephant conflict and poaching, both malicious poisoning and poaching are unlikely to have played a role as other species were not affected, and elephant carcasses were found with tusks intact. In the absence of a confirmed cause we sought to identify the lines of enquiry that are most likely to lead to a definitive answer. In particular, we consider viral and bacterial agents that could precipitate species-specific mortalities on this scale, potential environmental sources of poisoning and the samples and tests that would assist in excluding/confirming these candidate causes. Whilst it may be argued that these mortalities are unlikely to negatively impact the broader elephant population of ~130 000 individuals in Botswana, the same cannot be said of the many vulnerable population pockets in other parts of Africa. For this reason, it is essential that the cause of the current die-off is identified as it is the only way to prevent similar losses of susceptible elephants elsewhere.

Keywords: Encephalomyocarditis virus, arbovirus, rodent-borne diseases, mosquito vectors, human–elephant conflict, inter-species transmission, cyanobacteria, Okavango.

Introduction

Recent media reports of a mass die-off of African elephants (*Loxodonta africana*), in northern Botswana over a two-month period, have sparked concern and speculation amongst wildlife biologists, conservationists and the public. These reports indicate that ~350 elephants died *en masse* in the months of May and June 2020 ([https://africageographic.com/stories/botswana-elephant-graveyard-mystery-death-toll-rises-to-](https://africageographic.com/stories/botswana-elephant-graveyard-mystery-death-toll-rises-to-400/)

400/) following an initial cluster of deaths (44 animals) in March 2020 (<https://www.iol.co.za/news/africa/botswana-probes-mysterious-death-of-56-elephants-48239310>). The photographic evidence accompanying these reports suggests that the mortalities were indiscriminate with respect to elephant age and sex, and that death for some was sudden as elephants were found collapsed forward onto their chests, tusks in ground, rather than on their sides. Aside from the mention of a single dead horse in a nearby watering hole, this mass mortality event is notable for being highly specific to elephants. What distinguishes it from most past mass mortalities in elephants is that it occurred in an area that is inhabited by elephants, humans and livestock, rather than in a protected area. This species-specificity, together with confirmation that elephant carcasses were found with tusks intact, makes it unlikely that malicious poisoning and poaching were involved, and has led to suggestions that either disease, environmental bio-intoxication or starvation may be to blame (<https://www.nationalgeographic.com/animals/2020/07/botswana-elephant-death-mystery/>). Here, we consider these three possible causes of the mass mortality in the light of locality-specific considerations, historical elephant (and other wildlife species) mortalities reported elsewhere, reports of neurological clinical signs and other anecdotal lines of evidence, and the possibility that a confluence of these factors may have created a perfect storm.

Locality-specific considerations

Most of the elephant carcasses were detected across a 5593 km² area administratively known as NG11 which lies adjacent to the Okavango Panhandle and in which elephant movement is severely constrained to areas NG11 and NG12 by fences and deep water. A northern fence demarcates the border between Botswana and Namibia, a veterinary fence in the east restricts the move-

*To whom correspondence should be addressed.
E-mail: adbastos@zoology.up.ac.za



ment of wildlife, and a relatively deep and wide channel of water forms the western boundary of the Panhandle in the Okavango Delta (Fig. 1). The confinement of elephants within these boundaries has resulted in artificially high elephant densities such that today, ~15 000 of Botswana's ~130 000 elephants live in the NG11-12 (Seronga) area, along with ~16 000 people (Pozo *et al.*, 2017), ~4000 goats and ~25 000 cattle (Chase *et al.*, 2018). Human activities along the Okavango Panhandle restrict the Okavango River Delta as a source of water for elephants in NG11 and the well-worn routes that elephants travel to get to water are invariably accompanied by crop-raiding, particularly for those crops within a 1.2 km distance from these paths (Songhurst & Coulson, 2014), leading to high levels of human–elephant conflict that have long plagued the area (Jackson *et al.*, 2008). In addition to being a hotspot for human–elephant conflict (Pozo *et al.*, 2017), it is considered to be one of five poaching hotspots based on records of tuskless carcasses with damaged skulls (Schlossberg *et al.*, 2019).

The potential causes of a mass die-off are many,

and in the absence of a definitive diagnosis, it is critical to identify the most likely candidate causes and the most appropriate samples that should be collected to rapidly arrive at a definitive diagnosis. We attempt to achieve this objective, under the following two lines of enquiry: pathogens (viral and bacterial) and poisoning/starvation, with emphasis on pathogens.

Diseases: the viral candidates

One of the better known pathogen-induced mass mortality events occurred in a free-ranging African elephant population in the Kruger National Park (KNP), from 1993–4 (Grobler *et al.*, 1995). It was caused by encephalomyocarditis (EMC) virus, a single-stranded RNA virus within the *Cardiovirus* genus that can cause acute death in both captive and free-ranging African and Asian (*Elephas maximus*) elephants. Encephalomyocarditis is often associated with a concomitant increase in sympatric rodent reservoir host populations with elephant mortalities in zoos in the northern hemisphere being linked to *Rattus* (Lamglait *et al.*, 2015) and those in a free-ranging

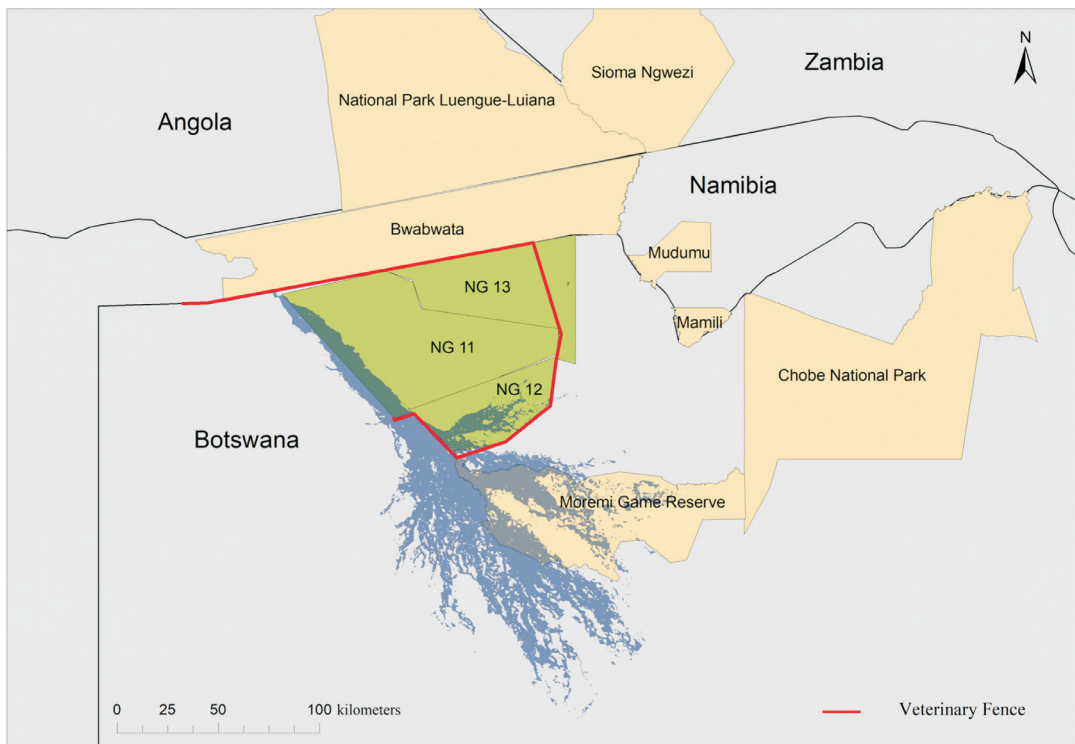


Fig. 1. Map indicating the Okavango Delta Panhandle in which the majority of elephant carcasses were found in the months of March–June 2020 in northern Botswana (green shading). The red line indicate the veterinary fence and the yellow shading denotes fully protected areas in the vicinity of the mass elephant die-off.

elephant population in South Africa, to *Mastomys* species (Grobler *et al.*, 1995). Two distinct EMCV virus (EMCV) serotypes are recognized, *viz.* EMCV-1 and EMCV-2 (Philipps *et al.*, 2012). Both African and Asian elephants are susceptible to EMCV-1 (van Sandwyk *et al.*, 2013), which is excreted in rodent faeces and infects elephants *via* the faecal-oral route. The virus replicates in myocardial cells, leading to severe inflammation and cellular damage and sudden death in acute cases. In less acute cases, lack of appetite, fatigue, and dyspnea and terminal involuntary and uncoordinated movements related to cerebral hypoxia just prior to death, may be interpreted as neurological symptoms. The most notable *post mortem* lesions in elephants include myocarditis and severe pulmonary oedema with froth in the major airways. It is noteworthy that in the KNP outbreak, there was a distinct age and sex bias, with 83% of the deaths occurring in adult males (Grobler *et al.*, 1995). This sex and age bias seems to be contradicted in the current Botswana outbreak as the media reports and accompanying photographs suggest that elephants of all age classes and both sexes were affected.

To establish a definitive EMCV diagnosis, histopathology using immunofluorescent techniques can be used to detect viral antigen in animal tissues. In addition, blood samples from viraemic elephants and rodent reservoir hosts, will allow for the detection of the virus and serum antibodies to the virus, respectively. Fresh heart tissue from elephants that have succumbed to EMCV infection is the ideal tissue type for virus detection and isolation and should be stored at -80°C or in liquid nitrogen. When this is not possible, an appropriate buffer, such as RNAlater, that ensures virus genome integrity and allows for the molecular confirmation of EMCV presence by reverse-transcription polymerase chain reaction (RT-PCR; van Sandwyk *et al.*, 2013) should be used (Table 1). Fresh faecal samples from rodents living in an outbreak area should be collected to identify rodent reservoir species (Lamglait *et al.*, 2015). This is because fresh rodent faecal pellets are not only amenable to virus isolation on Vero cells or cells of murid origin such as baby hamster kidneys (BHK) cells (MacLachlan & Dubovi, 2017), but also to nucleic acid extraction and downstream RT-PCR assays, inclusive of a reverse transcriptase loop-mediated isothermal amplification method that can be deployed in the field (Yuan *et al.*, 2014). When fresh tissue material from elephants is not available, due for example to an extended *post*

mortem and sampling interval, the destruction of ideal tissue type by scavengers or when mortalities suddenly cease, it is critical to sample sympatric rodent populations as soon as possible to assist with confirming/refuting probable EMCV involvement.

Other than the EMCV-1, at least two arboviruses, *viz.* West Nile virus (WNV) and Shuni virus (SHUV) can lead to neurological disease. Horses (also hind gut fermenters) are particularly susceptible to both and considered valuable sentinel species for detecting virus circulation. Both African and Asian elephants are seropositive to WNV (Root & Bosco-Lauth, 2019) with 100% WNV exposure being confirmed for elephants in the Congo basin (Kading *et al.*, 2013). Shuni virus is another RNA arbovirus that has been associated with fatal encephalitis in African equids (van Eeden *et al.*, 2012). Although there is no confirmation of SHUV infection in elephants, exposure has been confirmed in other wildlife species, highlighting the possibility that Shuni virus or another known/unknown arbovirus infection causing neurological symptoms may explain the mass die-off of elephants. The relevance of a dead horse in one of the nearby waterholes may be incidental and unrelated to the elephant mortalities, however, as horses are known to be highly susceptible to WNV; >93% show neurological symptoms and the mortality rate is >34% (Steyn *et al.*, 2019), arbovirus infections should be considered. This can be achieved by sampling brain tissue (Table 1) which, as opposed to heart tissue and other organ tissue types that are rapidly scavenged, is safely encased in the skull. Another reason why arboviruses warrant consideration is because the pans that are filled by rain water during the summer months can be breeding sites of insects that can act as vectors for arboviruses. Mosquitoes, amongst others, should be collected at the waterholes that elephants use.

Diseases: the bacterial candidates

Anthrax is a multi-species bacterial disease caused by *Bacillus anthracis* and can cause peracute death in elephants. Although anthrax has recently been reported in Botswana elephants (<https://www.diseasedaily.org/diseasedaily/article/anthrax-kills-over-100-elephants-botswana-111119>) it is unlikely to be the cause of the current mass elephant die-offs, as clinical signs consistent with anthrax, including haemorrhagic discharge from body orifices, were not reported in these elephants and the carcasses of other species

Table 1. Samples to be collected from an African elephant necropsy in Botswana.

Disease (aetiological agent)	Sample type	Diagnostic test*	Comments/findings	Reference(s)
Encephalomyocarditis (Encephalomyocarditis virus)	Heart	Histopathology, virus isolation and RT-PCR	Myocardial degeneration accompanying necrosis and lymphocytic infiltration. Virus isolation on baby hamster kidney cells (BHK) 5'UTR and 3D PCR assays, inclusive of an endogenous PCR control.	Grobler <i>et al.</i> , 1995; Van Sandwyk <i>et al.</i> , 2013
West Nile (West Nile Virus)	Heart, striated muscle and neural tissue	Histopathology, virus isolation and RT-PCR	Potentially endocarditis, cardiac degeneration, myocardial necrosis, myositis and encephalitis	Fowler, 2006; Kleiboeker <i>et al.</i> , 2004
Encephalitis (Shuni virus)	Neural tissue	Histopathology, virus isolation and RT-PCR	Not known. In a buffalo sample mild white matter cerebro-cerebellar gliosis, especially microglial, associated with considerable glial apoptotic activity and occasional perivascular haemorrhage was noticed.	Steyn <i>et al.</i> , 2020
Anthrax (<i>Bacillus anthracis</i>)	Blood	Blood smears, bacterial isolation and PCR	Biocontainment facilities required for <i>Bacillus anthracis</i> culture. Can be isolated from most organs in fresh carcasses, and from bones from decomposed carcasses, even years after the death of the animal. Similarly, PCR can detect <i>Bacillus</i> in samples that are several years old. Multiplex PCRs are required to discriminate <i>B. anthracis</i> from other genetically related bacilli	Berg <i>et al.</i> , 2006; Ogawa <i>et al.</i> , 2015
Enterotoxaemia, type D (<i>Clostridium perfringens</i> type D)	Gut contents	Mouse or guinea pig inoculation and histopathology	Mouse inoculation can be used for identification of <i>C. perfringens</i> type D	Ali Nasir <i>et al.</i> , 2015
Pasteurellosis (<i>Pasteurella multocida</i>)	Lungs, spleen, liver.	Histopathology, bacterial culture and PCR	Potentially oedema of lungs, kidney, and lymph nodes and to a limited extent in brain; haemorrhages in lungs and intestines.	Narasimham, 1946; Chandranaiik <i>et al.</i> , 2016
Bio-intoxication (<i>Microcystis</i> spp.)	Liver	Histopathology	Severe liver necrosis, and generalized haemorrhaging visible subcutaneously and in most organs, especially the heart	Bengis <i>et al.</i> , 2016; Masango <i>et al.</i> , 2010

RT-PCR: Reverse-transcription polymerase chain reaction:

*While the samples requiring histopathology should be preserved in formalin, fresh tissues maintained in a cold-chain should be submitted, as soon as possible after collection, if virus isolation or molecular testing is intended. If a cold chain cannot be maintained then samples should be placed in a storage buffer such as RNAlater to allow for molecular testing and/or next-generation sequencing.

were not found during the outbreak. During the period of mass replication of anthrax bacilli in the blood and tissues in herbivores, certain exotoxins are produced and these result in severe oedema and haemorrhages throughout the body including the brain. This results in terminal disorientation, ataxia, respiratory distress and apoplectic seizures. With anthrax this period is short-lived and rarely seen, and death occurs peracutely. Another important point is that the body condition of the victims is usually average to good because death occurs acutely. Anthrax is relatively easy to diagnose microscopically on blood smears from fresh carcasses. In older carcasses, the microscopic picture is clouded by the presence of numerous putrefactive organisms including *Clostridia*, but in experienced hands, anthrax 'ghosts' can still be identified. In addition, anthrax can be readily confirmed by culture on appropriate media and phage typing (Bengis, 2011). Molecular techniques using PCR technology are also readily available. Because anthrax is distributed throughout the body (septicaemia), tissue samples from any organ can be used for these molecular techniques.

Enterotoxaemia caused by *Clostridium perfringens* type C can also lead to sudden death, but is frequently characterized by severe diarrhoea, a clinical sign not reported in the current outbreak. In contrast, enterotoxaemia caused by *Clostridium perfringens* type D, leads to peracute death, following sudden involuntary movement of muscles, circling, posterior paralysis, and a little or no diarrhoea and gas production. *Post mortem* lesions consistent with *Clostridium perfringens* type D infection include haemorrhagic intestinal serosa and haemorrhages in epi- and endocardium (Bacciarini *et al.*, 2001). Since some media reports describe neurological signs such as circling and inability to coordinate gait by some of the elephants, *Clostridium perfringens* type D, should be considered a differential diagnosis. We also need to be aware that in recent years there have been several major die-offs of Saiga antelope (*Saiga tatarica*) in eastern Eurasia caused by *Pasteurella multocida*, which have been linked to changing environmental events (Kock *et al.*, 2018). In addition, there have been reports of *Pasteurella*-related deaths in Asian elephants (Chandranai, *et al.*, 2016), indicating that *Pasteurellosis* should also be included in the differential diagnosis.

Whilst genus/species-specific diagnostic assays are available for differential diagnosis of known viral and bacterial pathogens, the possibility that a

novel pathogen caused the mass die-off remains a distinct possibility. Although reports suggest that many of the carcasses were in an advanced stage of decomposition, impeding diagnosis and resulting in the degradation of nucleic acids, next-generation sequencing (NGS) technologies, which generate short stretches of sequence, lend themselves to the identification of novel pathogens from suboptimal samples. Fresh tissue material from multiple individuals would, however, be ideal for NGS-led pathogen discovery and species-specific detection assays.

Environmental bio-intoxication

Sudden death in elephants can involve both pathogens and poisonings. While poisoning in the broad context could cause sudden death in elephants, it is important to distinguish between malicious/deliberate poisoning and non-malicious poisoning caused, for example, by the ingestion of poisonous plants or through exposure to toxigenic cyanobacteria. Although it is known that free-ranging African elephants appear to use secondary metabolites as cues to avoid indigenous toxic plants (Schmitt *et al.*, 2020), the risk lies with alien invasive plants, associated with human habitation. One such example is *Nerium oleander* which has been recorded in northern Botswana (<https://www.inaturalist.org/projects/alien-plants-of-northern-botswana>) and which could result in sudden death if consumed. The possibility of alien, toxic plants as a possible cause of mortalities, therefore, warrants consideration.

Bio-intoxication by ingestion of, and exposure to, toxigenic blue-green algae is another possibility. This has been described in the KNP in 2005, 2007, 2008 and 2009, and mortalities were recorded in zebras (*Equus quagga*), wildebeest (*Connochaetes taurinus*), white rhinoceros (*Ceratotherium simum*) and impala (*Aepyceros melampus*). Cyanobacteria may float as surface scum on the water, or may be attached to sub-surface vegetation. In photo-images of dead elephants close to waterholes and pans in Botswana, a distinct green discoloration of the water is visible. Blue-green algae produce either hepato-toxins (*Microcystis* spp.) as in the KNP or neurotoxins (*Anabaena* spp.) which can be rapidly fatal. *Post mortem* lesions caused by the hepato-toxins include severe liver necrosis, and generalized haemorrhaging visible subcutaneously and in most organs, especially the heart (Bengis *et al.*, 2016). Heart and liver tissue in 10% formaldehyde would be the specimens of choice for histopathological

diagnosis (Table 1). With the neurotoxic form there are generally very few *post mortem* lesions (Beasley *et al.*, 1989). Cutaneous exposure to these neurotoxin-producing cyanobacteria may also result in severe intoxication as has previously been recorded in dogs that were swimming in an affected water body (Edler *et al.* 1985). Elephants are also known to enjoy mud bathing and frolicking in the water. Water samples from these water holes may be collected and kept chilled for identification of the algae and for toxicogenic testing.

Another important potential bio-toxicosis with neurological signs is botulism, especially if contamination of water holes occurred from animal carcasses. In southern Africa, *Clostridium botulinum* types C and D are common saprophytes in decaying organic material (including carcasses), and produce potent neurotoxins during replication that can cause paralysis and death when ingested by mammals or birds. In southern Africa, most cases in mammals occur in areas with phosphate deficient soils and are related to osteophagia (pica) in animals that may need additional phosphate (often lactating or pregnant females). It also commonly occurs where water points have become contaminated by carcasses lying adjacent to or in the water itself. Animals that become intoxicated become progressively paralysed, leading to eventual death due to respiratory failure. This does not fit with the sudden death/collapse reported in elephants in Botswana by some observers. Collection and testing of water samples at the appropriate critical time points may assist with eliminating/confirming these possibilities.

Starvation

Severe resource constraints, during prolonged droughts can result in death due to starvation (Wato *et al.*, 2016). Elephant-induced damage of their own habitat, combined with drought may have caused the mass die-offs of elephants in the Tsavo ecosystem between 1975 and 1980 (Corfield, 1973; Ottichilo, 1987). Unlike the 2020 year, which experienced late, heavy rains, 2019 was a dry year in Botswana, yet no mass mortality event similar to the present one occurred in 2019. Starvation is therefore unlikely to be the cause of the current mass mortality of elephants in northern Botswana.

A perfect storm (and why EMCV should not be discounted)



The Seronga area is characterized by steadily increasing numbers of people, livestock and

wildlife, creating a nexus for increased disease transmission opportunities across these three interfaces. Whilst the current mass mortality of elephants in this area does not bear the hallmarks of rodent irruptions and sex-biased elephant mortalities that typified the mass die-off in the KNP in the mid-1990s, it is important to note that the systems are vastly different and that an explosion in rodent numbers may not necessarily be required. This is because (i) in 1993/4 KNP had ~8000 elephants in an area of ~22 000 km² whereas the affected area of the Okavango panhandle has ~15 000 elephants in an area of ~5500 km², (ii) KNP is a protected wildlife area which would require high levels of environmental contamination to achieve spillover from rodents to elephants, whereas in the Seronga area there are numerous crops that not only attract elephants, but also rodents. As such, crops effectively concentrate the two major role-players and may facilitate inter-species transmission through environmental contamination, without the requirement of significant increases in rodent density. Thus, although an overt increase in rodent numbers has not been noted in northern Botswana, it is likely that rodent numbers are higher in Seronga this year as the late rains of 2020 have resulted in bumper crops, and follow successive dry years. The timing of the mortalities is also of relevance as extensive studies in the Seronga area have identified the months of February to May as peak crop-raiding months (Songhurst, 2017). Crop raiding is not only carried out by males, but by family units predominantly comprising females and young elephants, which would explain the lack of sex and age bias. Based on this, EMC virus should be given due consideration as a possible cause of the current mass die-off, even in the absence of obvious signs of increased rodent numbers.

If we consider that Botswana's elephant population of ~130 000 has been stable for the last 25 years, and that yearly mortalities of between 3000 and 4000 individuals should be associated with this stable population size (van Aarde *et al.* 2008), then it could be argued that the loss of ~400 elephants is unlikely to negatively impact the broader elephant population; elephants regularly die of natural causes, including diseases. The concern is that the current wave of elephant mortalities will continue, and spread to other areas or that a similar mass mortality event will affect other small and isolated elephant populations, which will not be able to withstand the loss of so many individuals. Thorough and speedy epidemi-

ological studies exploring disease transmission dynamics, supported by detailed laboratory investigation are an important basis for limiting mortalities and for devising strategies to prevent future mass mortality events. Since wildlife-livestock-human interface could serve as a hotspot for emergence of new pathogens, observations made by local tribal communities could educate, inform, and pre-warn us of an imminent disease outbreak in wildlife, including elephants (Hassell *et al.*, 2017). In keeping with this, government and non-governmental organizations should assist, where possible, in mortality investigation by working with local communities to locate fresh carcasses for sampling and to assist with sampling of possible reservoirs on infection, such as rodents and mosquitoes. Only once the aetiological causality for the mass die-off of Botswana's elephants has been established, will it become clear as to whether we are dealing with a self-limiting, non-contagious/contagious agent, or a propagating epidemic. This will determine whether mitigation strategies are called for or not.

ORCID iDs

S. Azeem:  orcid.org/0000-0002-1261-2034
 A.D.S. Bastos:  orcid.org/0000-0002-9223-4204

REFERENCES

- Ali Nasir, A., Younus, M., Rashid, A., Abdul Khaliq, S., Khan, E., Shah, S.H., Aslam, A., Ghumman, M.A. & Joiya, M.H. (2015). Clinico-pathological findings of *Clostridium perfringens* type D enterotoxaemia in goats and its hemolytic activity in different erythrocytes. *Iranian Journal of Veterinary Research*, 16(1), 94–99.
- Bacciarini, L.N., Pagan, O., Frey, J. & Gröne, A. (2001). *Clostridium perfringens* β 2-toxin in an African elephant (*Loxodonta africana*) with ulcerative enteritis. *Veterinary Record*, 149(20), 618–620. <https://doi.org/10.1136/vr.149.20.618>
- Beasley, V.R., Dahlem, A.M., Cook, W. O., Valentine, W.M., Lovell, R.A., Hooser, S.B., ... Carmichael, W. W. (1989). Diagnostic and clinically important aspects of cyanobacterial (blue-green algae) toxicoses. *Journal of Veterinary Diagnostic Investigation*, 1(4), 359–365. <https://doi.org/10.1177/104063878900100417>
- Bengis, R.G. (2011). Anthrax in free-ranging wildlife. In R.E. Miller & M.E. Fowler (Eds), *Zoo and wild animal medicine – Current therapy*, Vol. 7, (pp. 98–107). St Louis, Missouri, U.S.A.: Elsevier Saunders.
- Bengis, R.G., Govender, D., Myburgh, J.G., Oberholster, P., Keet, D.F., Buss, P.E., Prozesky, L. & Lane, E.P. (2016). Eco-epidemiological and pathological features of wildlife mortality events related to cyanobacterial bio-intoxication in the Kruger National Park. *Journal of the South African Veterinary Association*, 87(1), 132. <https://doi.org/10.4102/jsava.v87i1.1391>
- Berg, T., Suddes, H., Morrice, G. & Hornitzky, M. (2006). Comparison of PCR, culture and microscopy of blood smears for the diagnosis of anthrax in sheep and cattle. *Letters in Applied Microbiology*, 43, 181–186. <https://doi.org/10.1111/j.1472-765X.2006.01931.x>
- Chase, M., Schlossberg, S., Sutcliffe, R. & Seonyatseng, E. (2018). Dry season aerial survey of elephants and wildlife in northern Botswana, July–October 2018. Gabarone, Botswana: Department of Wildlife and National Parks.
- Chandranaiik, B.M., Shivashankar, B.P., Giridhar, P. & Nagaraju, D.N. (2016). Molecular characterisation and serotyping of *Pasteurella multocida* isolates from Asiatic elephants (*Elephas maximus*). *European Journal of Wildlife Research*, 62(6), 681–685. <https://doi.org/10.1007/s10344-016-1043-8>
- Corfield, T.F. (1973). Elephant mortality in Tsavo National Park, Kenya. *African Journal of Ecology*, 11, 339–368. <https://doi.org/10.1111/j.1365-2028.1973.tb00098.x>
- Edler, L., Fernö, S., Lind, M.G., Lundberg, R. & Nilsson, P.O. (1985). Mortality of dogs associated with a bloom of the cyanobacterium *Nodularia spumigena* in the Baltic Sea. *Ophelia*, 24(2), 103–109. <https://doi.org/10.1080/00785236.1985.10426623>
- Garlt, C., Kiupel, H. & Ehrentraut, W. (1979). Ein Beitrag zum botulismus bei elefanten [Botulism in elephants]. *Erkr Zootiere*, 13, 207–211.
- Grobler, D.G., Raath, J.P., Braack, L.E., Keet, D.F., Gerdes, G.H., Barnard, B.J., Kriek, N.P., Jardine, J. & Swanepoel, R. (1995). An outbreak of encephalomyocarditis-virus infection in free-ranging African elephants in the Kruger National Park. *The Onderstepoort Journal of Veterinary Research*, 62(2), 97–108.
- Hassell, J.M., Begon, M., Ward, M.J. & Fèvre, E.M. (2017). Urbanization and disease emergence: dynamics at the wildlife–livestock–human interface. *Trends in Ecology and Evolution*, 32(1), 55–67. <https://doi.org/10.1016/j.tree.2016.09.012>
- Jackson, T.P., Mosojone, S., Ferreira, S. & van Aarde, R.J. (2008). Solutions for elephant *Loxodonta africana* crop raiding in northern Botswana: moving away from symptomatic approaches. *Oryx*, 42(1), 83–91. <https://doi.org/10.1017/S0030605308001117>
- Kading, R.C., Borland, E.M., Cranfield, M. & Powers, A.M. (2013). Prevalence of antibodies to alphaviruses and flaviviruses in free-ranging game animals and nonhuman primates in the greater Congo basin. *Journal of Wildlife Diseases*, 49(3), 587–599. <https://doi.org/10.7589/2012-08-212>
- Kleiboeker, S.B., Loiacono, C.M., Rottinghaus, A., Pue, H.L. & Johnson, G.C. 2004. Diagnosis of West Nile virus infection in horses. *Journal of Veterinary Diagnostic Investigation*, 16, 2–10. <https://doi.org/10.1177/104063870401600102>
- Kock, R.A., Orynbayev, M., Robinson, S., Zuther, S., Singh, N.J., Beauvais, W., ... Milner-Gulland, E.J. (2018). Saigas on the brink: multidisciplinary analysis of the factors influencing mass mortality events. *Science Advances*, 4(1), 1–11. <https://doi.org/10.1126/sciadv.aao2314>

- Lamglait, B., Joris, A., Romey, A., Bakkali-Kassimi, L. & Lemberger, K. (2015). Fatal encephalomyocarditis virus infection in an African savanna elephant (*Loxodonta africana*) in a French zoo. *Journal of Zoo and Wildlife Medicine*, 46(2), 393–396.
<https://doi.org/10.1016/b978-0-12-800946-8.00026-x>
- MacLachlan, N.J. & Dubovi, E.J. (Eds) (2017). Picornaviridae. In *Fenner's veterinary virology* (pp. 477–495). London, U.K.: Academic Press.
<https://doi.org/10.1016/b978-0-12-800946-8.00026-x>
- Masango, M.G., Muylburgh J.G., Labuscagne, L., et al. (2010). Assessment of microcystis bloom toxicity associated with wildlife mortality in the Kruger National Park, South Africa. *Journal of Wildlife Diseases* 46, 95–102.
- Narasimham, C.V. (1946). A case of haemorrhagic septicaemia in an elephant. *Indian Veterinary Journal* 22, 294.
- Ottichilo, W.K. (1987). The causes of the recent heavy elephant mortality in the Tsavo ecosystem, Kenya, 1975–1980. *Biological Conservation*, 41(4), 279–289.
[https://doi.org/10.1016/0006-3207\(87\)90091-7](https://doi.org/10.1016/0006-3207(87)90091-7)
- Ogawa, H., Fujikura, D., Ohnuma, M., Ohnishi, N., Hang'ombe, B.M., Mimuro, H., Ezaki, T., Mweene, A.S. & Higashi, H. (2015). A novel multiplex PCR discriminates *Bacillus anthracis* and its genetically related strains from other *Bacillus cereus* group species. *PLOS ONE*, 10(3), e0122004.
<https://doi.org/10.1371/journal.pone.0122004>
- Philipps, A., Dauber, M., Groth, M., Schirmeier, H., Platzer, M., Krumbholz, A., ... Zell, R. (2012). Isolation and molracterization of a second serotype of the encephalomyocarditis virus. *Veterinary Microbiology*, 161(1–2), 49–57.
<https://doi.org/10.1016/j.vetmic.2012.07.006>
- Root, J.J. & Bosco-Lauth, A.M. (2019). West Nile virus associations in wild mammals: an update. *Viruses*, 11(5), 1–11.
<https://doi.org/10.3390/v11050459>
- Spinage, C.A. (1994). *Elephants*. London, U.K.: T E A D Poyser Ltd.
- Schmitt, M.H., Shuttleworth, A., Shrader, A. & Ward, D. (2020). The role of volatile plant secondary metabolites as pre-ingestive cues and potential toxins dictating diet selection by African elephants, *Oikos*, 129, 24–34.
<https://doi.org/10.1111/oik.06665>
- Songhurst, A. (2017). Measuring human-wildlife conflicts: comparing insights from different monitoring approaches. *Wildlife Society Bulletin* 41(2), 351–361.
<https://doi.org/10.1002/wsb.773>
- Songhurst, A. & Coulson, T. 2014. Exploring the effects of spatial autocorrelation when identifying key drivers of wildlife crop-raiding. *Ecology and Evolution*, 4, 582–593
- Steyn, J., Botha, E., Stivaktas, V. I., Buss, P., Beechler, B.R., Myburgh, J. G., ... Venter, M. (2019). West Nile virus in wildlife and nonequine domestic animals, South Africa, 2010–2018. *Emerging Infectious Diseases*, 25(12), 2290–2294.
<https://doi.org/10.3201/eid2512.190572>
- Steyn, J., Motlou, P., van Eeden, C., Pretorius, M., Stivaktas, V.I., Williams, J. ... Venter, M. (2020). Shuni virus in wildlife and nonequine domestic animals, South Africa. *Emerging Infectious Diseases*, 26(7), 1521–1525.
<https://dx.doi.org/10.3201/eid2607.190770>
- van Eeden, C., Williams, J.H., Gerdes, T.G.H., van Wilpe, E., Viljoen, A., Swanepoel, R. & Venter, M. (2012). Shuni virus as cause of neurologic disease in horses. *Emerging Infectious Diseases*, 18(2), 318–321.
<https://doi.org/10.3201/eid1802.111403>
- van Sandwyk, J., Bennett, N.C., Swanepoel, R. & Bastos, A.D.S. (2013). Retrospective genetic characterisation of encephalomyocarditis viruses from African elephant and swine outbreaks reveals two distinct lineages in South Africa. *Veterinary Microbiology*, 162, 23–31.
<https://doi.org/10.1016/j.vetmic.2012.08.008>
- van Aarde, R.J., Ferreira, S., Jackson, T., Page, B., de Beer, Y., Gough, K., Guldemond, R., Junker, J., Olivier, P. & Ott, T. (2008). Elephant population biology and ecology. In R.J. Scholes & K.G. Mennell (Eds), *Elephant management: a scientific assessment for South Africa* (Chapter 8). Johannesburg, South Africa: Wits University Press.
<https://doi.org/10.18772/22008034792.13>
- Wato, Y.A., Heitkönig, I.M.A., van Wieren, S.E., Wahungu, G., Prins, H.H.T. & van Langevelde, F. (2016). Prolonged drought results in starvation of African elephant (*Loxodonta africana*). *Biological Conservation*, 203, 89–96.
<https://doi.org/10.1016/j.biocon.2016.09.007>
- Yuan, W., Wang, J., Sun, M., Zheng, Y., Li, L., Zhang, X. & Sun, J. (2014). Rapid detection of encephalomyocarditis virus by one-step reverse transcription loop-mediated isothermal amplification method. *Virus Research*, 189, 75–78.
<https://doi.org/10.1016/j.virusres.2014.04.015>