



# A case report of COVID-19-associated acute hand ischaemia in a young professional volleyball player

Alexandru Achim <sup>1,2\*</sup>, Kornél Kákonyi<sup>1</sup>, Zoltán Jambrik<sup>1</sup>, and Zoltán Ruzsa <sup>1</sup>

<sup>1</sup>Invasive Cardiology Division, Internal Medicine Department, Faculty of Medicine, University of Szeged, Semmelweis Str 6, 6726, Szeged, Hungary; and <sup>2</sup>Nicolae Stancioiu Heart Institute, University of Medicine and Pharmacy "Iuliu Hatieganu", Cluj-Napoca, Romania

Received 11 November 2021; first decision 6 December 2021; accepted 21 February 2022; online publish-ahead-of-print 23 February 2022

## Background

Several coronavirus disease-19 (COVID-19)-associated complications are being increasingly reported, including arterial and venous thrombo-embolic events that may lead to amputation of the affected limbs. So far, acute upper limb ischaemia (ULI) has been reported only in critically ill patients.

## Case summary

Herein, we aimed to present a case of a 29-year-old, otherwise healthy male volleyball player, with acute ischaemic signs in the upper extremity who was diagnosed with COVID-19 1 month before the ischaemic event. It has been shown that volleyball players experience repetitive stress that involves their hands and, in particular, their fingers. Repetitive trauma can lead to local vascular abnormalities, such as reduced capillarization and lower resting blood flow that can lead to pain and cold digits, but never acute ULI.

## Discussion

To our knowledge, this is the first case of such a hypercoagulable synergistic mechanism that leads to a high thrombus burden. Intra-arterial local thrombolysis and percutaneous transluminal angioplasty failed to succeed, and percutaneous large-bore embolectomy with the Indigo Aspiration System (Penumbra Inc., CA, USA) was deemed necessary.

## Keywords

Case report • COVID-19 • Upper limb ischaemia • Thrombosis • Penumbra • Thrombolysis

## ESC Curriculum

8.1 Sports Cardiology • 9.3 Peripheral artery disease

## Learning points

- Dedicated continuous-aspiration devices are safe and feasible in complex cases of upper limb ischaemia with a high thrombus burden.
- Coronavirus disease-19 might aggravate vascular injuries in young professional athletes who use their hands.

## Specialties other than cardiology involved

Vascular Surgery, Angiology, Hematology, Pathology

## Introduction

Coronavirus disease-19 (COVID-19) first emerged in December 2019 in China and has rapidly spread worldwide. Although various studies have reported that COVID-19 is associated with a hypercoagulable

\* Corresponding author. Tel: +40753803716, Email: [dr.alex.achim@gmail.com](mailto:dr.alex.achim@gmail.com)

Handling Editor: Antonios Karanasos

Peer-reviewers: Ali Nazmi Calik; Roman Komorovsky

Compliance Editor: Polyvios Demetriades

Supplementary Material Editor: Ameenathul Mazaya Fawzy

© The Author(s) 2022. Published by Oxford University Press on behalf of the European Society of Cardiology.

This is an Open Access article distributed under the terms of the Creative Commons Attribution-NonCommercial License (<https://creativecommons.org/licenses/by-nc/4.0/>), which permits non-commercial re-use, distribution, and reproduction in any medium, provided the original work is properly cited. For commercial re-use, please contact [journals.permissions@oup.com](mailto:journals.permissions@oup.com)

state and thrombotic complications in critically ill patients, there are few case reports on thrombotic events as one of the presenting symptoms<sup>1</sup> and none of the acute upper limb ischaemia (ULI) at 1-month after COVID-19 diagnosis. The pathophysiology behind thrombus formation in COVID-19 is still unclear, and the risk of thrombosis extends up to 4–6 weeks after resolution of infection.<sup>2,3</sup>

Acute ULI is an infrequent clinical condition when the perfusion of the upper limb suddenly decreases and the onset of the symptoms is less than 2 weeks. Pulmonary embolism, atrial fibrillation, valvular heart disease, and left ventricular apical aneurysm are frequent aetiologies. Another mechanism is the blunt injury to the upper extremity that causes local thrombosis.<sup>4</sup> Acute ULI is usually treated by open surgery, but endovascular approaches including catheter-based thrombolysis and balloon angioplasty are important options to manage this entity.<sup>4,5</sup> Limited data are available on treating ULI with mechanical thrombus aspiration by the Indigo Aspiration System (Penumbra Inc., CA, USA).

Herein, we aimed to present a case of an acute ulnar and radial arterial occlusion associated with COVID-19 and volleyball practice-induced endothelial injury as a rare and challenging case, and we report the safety and feasibility of such dedicated aspiration device as a revascularization option in acute ULI.

## Timeline

1-month before	Coronavirus disease-19 infection: mild form, home isolation
<b>Day 0</b>	On-set of symptoms: cold right IV–V fingers, right mild forearm and palm pain, intermittent paraesthesia
<b>Day 5</b>	Aggravation of the symptoms, continuous pain
<b>Day 7</b>	(1) Presentation at the hospital (2) Computed tomography and hand angiography, diagnosis
<b>Day 7</b>	First percutaneous transluminal angioplasty (PTA) attempt (failed), start local thrombolysis with alteplase 0.1 mg/kg/h.
<b>Day 8</b>	(1) Partial lysis after 24 h of continuous thrombolysis (2) Second PTA attempt (failed), start with continuous thrombaspiration (6-Fr catheter), reperfusion success. (3) Palmar arch reconstruction with simultaneous radial-ulnar long-balloon PTA.
<b>Day 10</b>	Disappearance of symptoms, home discharge
<b>Follow-up 6 months</b>	Asymptomatic, playing volleyball, negative thrombophilia tests.

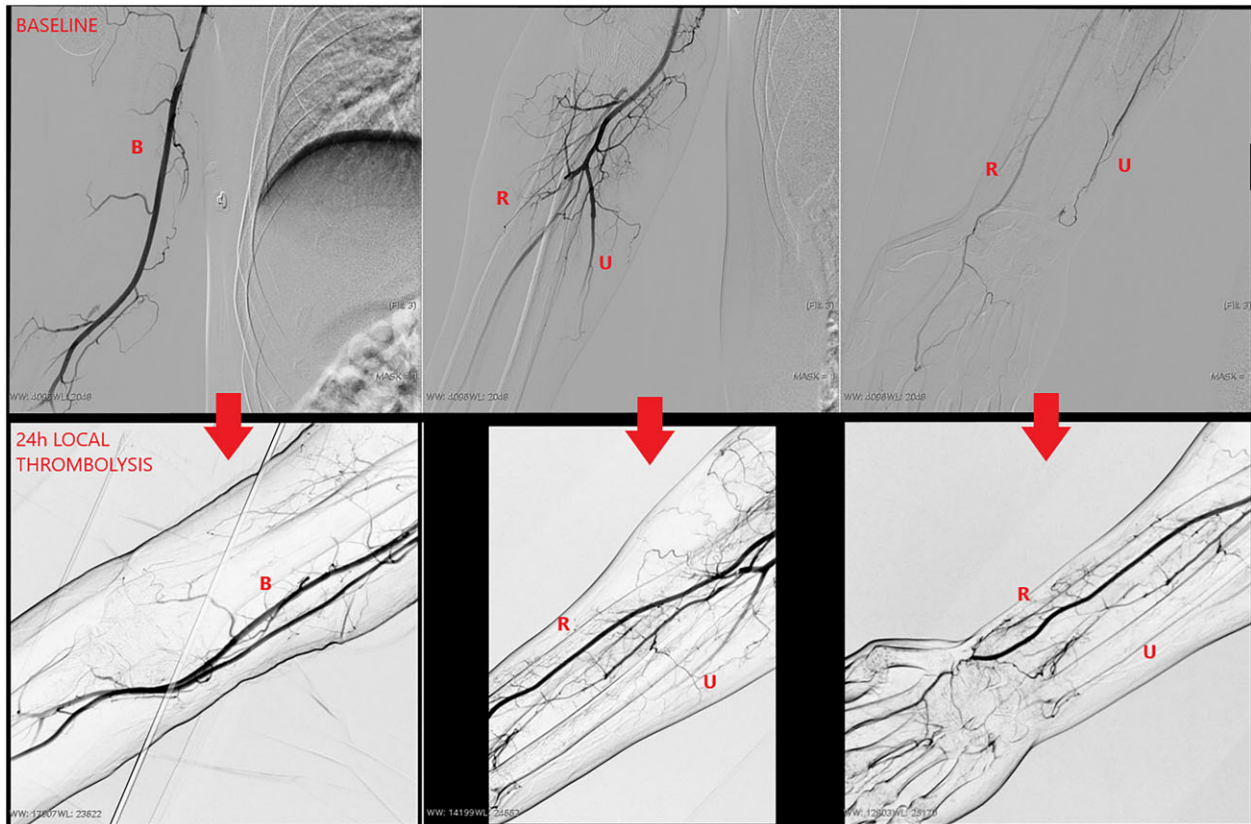
## Case presentation

A 29-year-old volleyball player male with no significant medical history presented to the emergency room with a chief complaint of

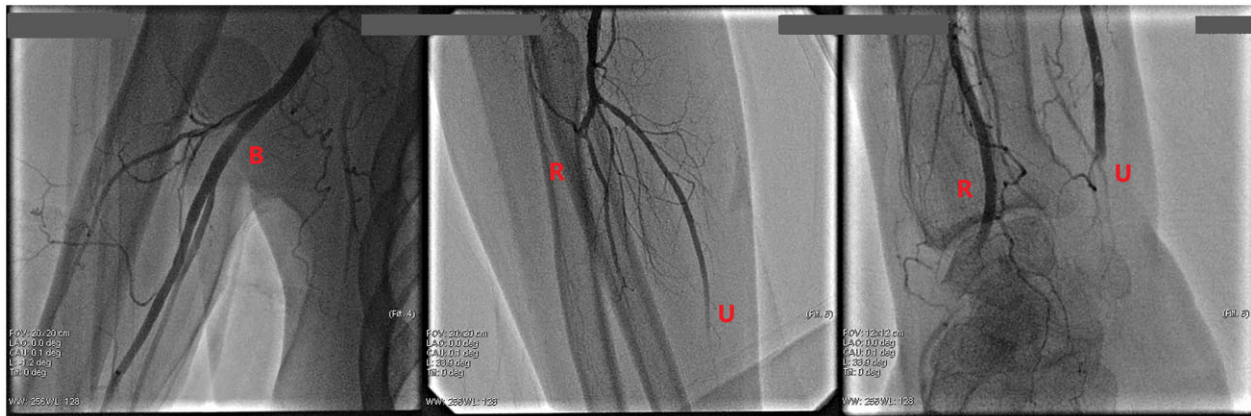
worsening right hand and forearm pain and cold IV–V fingers, 1 month after COVID-19 infection. Symptoms started 1 week ago and aggravated in the last 2 days. The patient reported that he was often affected by blunt trauma to his hands during the volleyball training. On clinical examination, the temperature of the right hand was lower than the left, the hand was tensed and swollen. Pulse in the right upper extremity was not palpable at the ulnar artery. Doppler ultrasound revealed 8 cm long right ulnar artery occlusion, the right radial, and brachial artery flow were maintained. A right hand computed tomography angiogram (CTA) demonstrated long thrombotic occlusion of the ulnar artery. Evaluation of the digital arterial supply by CTA was non-conclusive. The electrocardiogram showed a normal sinus rhythm. The D-Dimer level was 3252 ng/mL on admission (normal range < 250 ng/mL). Because of the severe ischaemic signs, invasive angiography of the arm was proposed by a multidisciplinary team consisting of angiologists and vascular and orthopaedic surgeons. Upper extremity catheter angiography via right femoral access revealed high take-off occlusion of both radial and ulnar arteries, with the poor collateral flow. The distal part of the ulnar artery and interosseous artery were without any flow. Local thrombolysis with alteplase (0.1 mg/kg/h) was initiated.

Twenty-four hours later, the radial artery was open but the ulnar artery and the superficial palmar arch of the hand were still occluded (Figure 1). In an effort to prevent tissue necrosis and to relieve symptoms, the aspiration procedure was performed via the same femoral access through a 6F Flexor Check-Flo introducer (Cook Medical LLC, Bloomington, USA). After the administration of 5000 I.U. of intra-arterial heparin-sodium, the occlusion of the ulnar artery was passed with a hydrophilic 0.014"–300 cm Progress 40 guidewire (Abbott Vascular, Santa Clara, CA, USA) on a CXI Support catheter (Cook Medical LLC, Bloomington, USA) (the Penumbra catheter needs rail support, especially in this case, with long distance between femoral access and palmar extremity). Initial percutaneous transluminal angioplasty (PTA) was tried in both arteries with a 2.0 mm × 120 mm Armada balloon (Abbott Vascular, Santa Clara, CA, USA), with no improvement (Figure 2). As a last resort, mechanical thrombaspiration was attempted. Thrombus was not retractable with the Penumbra CAT3 (3.4-Fr) aspiration catheter (Penumbra Inc., CA, USA) due to its small calibre but then, upgrading to Penumbra CAT6 (6.0-Fr) aspiration catheter, a large amount of thrombus could be retrieved (Figure 3). The wire was crossed retrogradely into the radial artery and the superficial palmar arch was reconstructed using a long 2/2.5 mm × 210 mm Amphirion peripheral balloon (Invatec, Roncadelle, Italy). Final angiography revealed good antegrade flow (Figure 4, Video 1). The hand regained normal colour and temperature, with a Doppler signal in both forearm arteries. Medication at discharge was clopidogrel 75 mg PO qDay and rivaroxaban 20 mg PO qDay.<sup>6</sup>

The patient was seen in the outpatient clinic 6 months later, being asymptomatic, with patent forearm arteries and continuing to play volleyball (against medical advice). Because the thrombophilia screening came back negative (antithrombin, protein C, protein S, antiphospholipid antibodies, lupus anticoagulant, factor V Leiden prothrombin gene mutation, anti-β-2-glycoprotein-1 antibodies), his antithrombotic scheme was stopped. Histopathological analysis of the thrombus revealed local thrombosis.



**Figure 1** Prior and after local thrombolysis with alteplase infusion placed at the level of the brachial artery (B). Both radial (R) and ulnar (U) arteries are occluded at initial angiography, partial improvement after the lytic agent, with radial artery reperfusion.

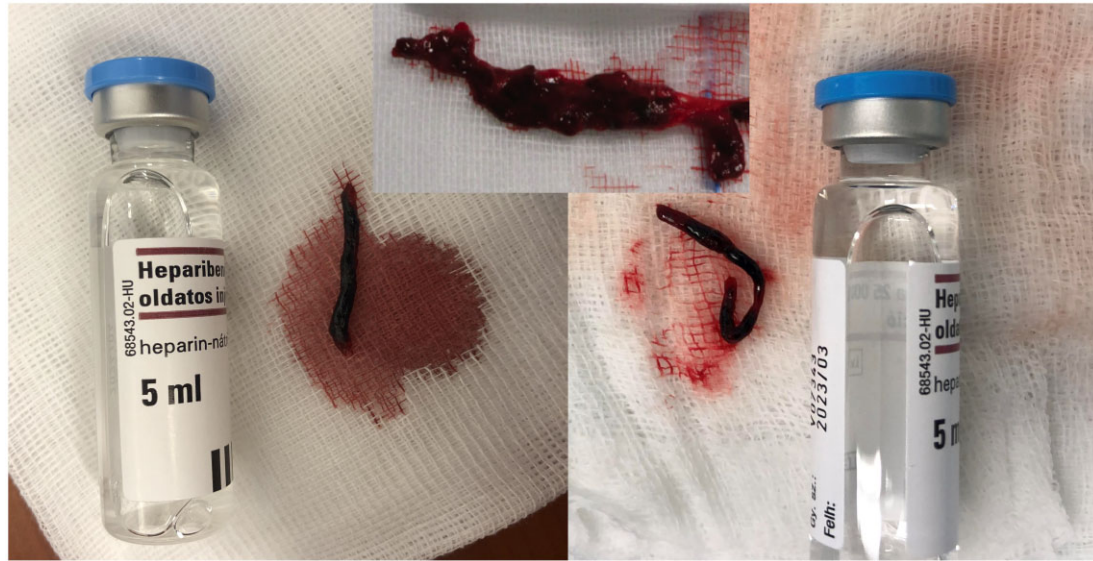

**Figure 2** Control angiography after failed percutaneous transluminal angioplasty, minimal improvement with residual thrombotic occlusion in both radial (R) and ulnar (U) arteries.

## Discussion

Vascular compromise of the hand has long been recognized in the patient population exposed to repetitive blunt trauma.<sup>7</sup> Ischaemia,

digital artery occlusions, and aneurysms of the ulnar artery occur in athletes participating in baseball, handball, hockey, volleyball, or karate.<sup>8</sup> Symptoms in these individuals range from severe hand pain or numbness to cold hypersensitivity and palmar pulsatile masses.



**Figure 3** Organized, snake-like thrombi extracted with the CAT6 aspiration catheter.

Unless an obvious vascular compromise is present, the pain is frequently attributed to a musculoskeletal aetiology.

Pathophysiologically, blunt trauma-induced arterial injuries frequently result in tunica intima tearing and subsequent obstruction of the lumen by fresh thrombus. A study conducted on volleyball players with ischaemic digits of their dominant hand highlighted the correlation between the digital trauma caused by the collision with the ball and the formation of micro-emboli in digital arteries.<sup>9</sup> The embolic complications of the affected extremity, in combination with pain and ischaemia, can lead to microvascular damage, but no clinical acute ULI was ever reported through such a mechanism. Out of 100 young Dutch volleyball players studied by van de Pol *et al.*,<sup>10</sup> the prevalence of symptoms associated with digital ischaemia in the dominant hand was 27% of cold digits, 18% of blue digits, and 20% of pale digits. Suker *et al.*<sup>11</sup> reported two athletes that required hospitalization because of their severe hand ischaemia, but they were managed non-operatively with intravenous heparin and dextran, and they were professional baseball catchers.

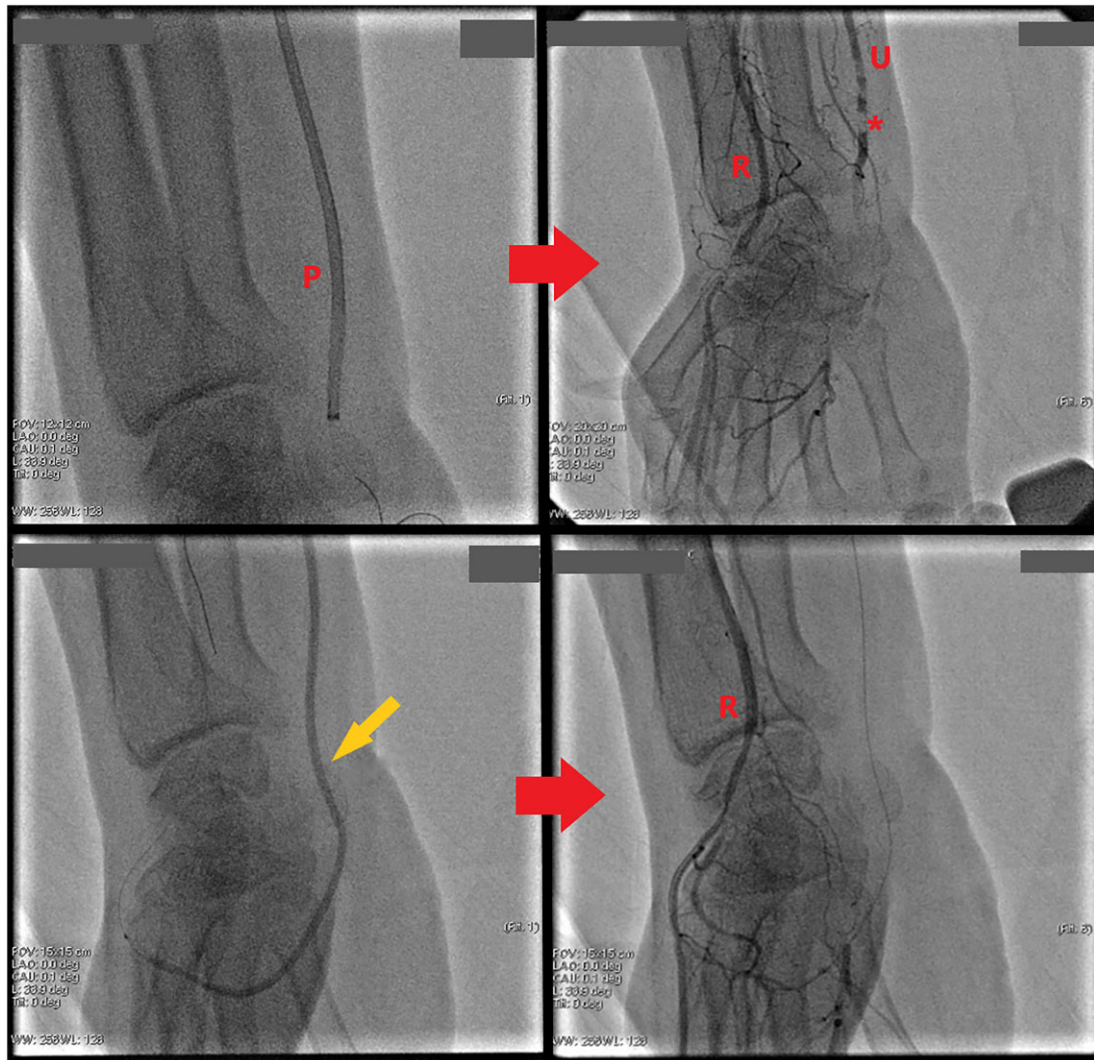
On the other hand, the mechanism behind the COVID-19 coagulopathy remains to be explored. The systemic inflammatory response, platelet activation, and endothelial dysfunction all go hand in hand to disturb the tune balance between the pro- and anticoagulant pathways.<sup>2</sup> Immune responses, including cytokine release, complement activation, NETosis, and monocyte-platelet aggregation have been recognized.<sup>3</sup> Case series of critically ill COVID-19 patients have shown persistent severe elevations in von Willebrand factor, fibrinogen, and factor VII, all of which are suggestive of endothelial injury.<sup>12,13</sup> Resultant venous and arterial thrombosis both in macro- and microvasculature leads to significant morbidity and mortality. Clinical manifestations of disrupted coagulation in COVID-19 patients include deep venous thrombosis, pulmonary embolism,

acute ischaemic stroke, and peripheral arterial thrombosis. It is worth mentioning that, although antiphospholipid antibodies positivity may be a feature of COVID-19, they are of low titre and transient (this would explain the negative result in our patient) and cannot be incriminated for COVID-19-related arterial clots anyway.<sup>14,15</sup>

Because approximately 20% of hands have incomplete arches,<sup>4</sup> compromise of one of the feeding arteries—ulnar, radial, or median—may compromise vascular supply to the digits, as in the case of our patient. Therefore, on the unfavourable ground of a hand with mechanically induced endothelial injury and with this anatomical variant, COVID-19-infection as another procoagulant factor might have finally potentiated and activated the coagulation cascade that led to the large amount of thrombus found in our patient's hand. Of course, the authors acknowledge the speculative nature of this theory, a direct association between trauma-induced vascular injury and COVID-19 infection cannot be formulated, and the definitive cause of arterial occlusion in our patient remains obscure.

Peripheral artery thrombotic occlusion is usually surgically treated with a Fogarty catheter, but endovascular approaches have been increased in the last decade.<sup>5</sup> Because patients with upper extremity artery occlusion develop a compensatory collateral circulation through the interosseous arteries, their presentation at the hospital is usually late and thrombolysis is less likely to be resolute.<sup>5</sup> Choosing the best revascularization option depends on the complexity of the case and the expertise of the centre. A multidisciplinary team of vascular surgeons, angiologists, and cardiologists should be promptly formed after imaging diagnosis. The inclusion of other specialists such as haematologists or pathologists facilitates the understanding of the aetiology. We found the percutaneous option attractive because the thrombus seemed small in size and situated distal to the bifurcation of the brachial artery, a convenient location for a catheter approach.

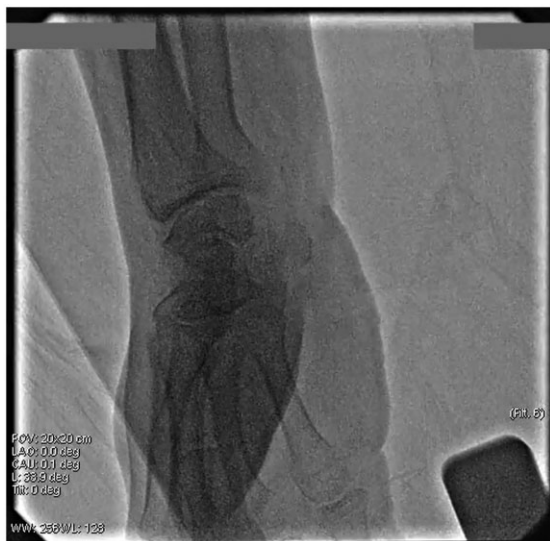



**Figure 4** Ulnar artery (U) mechanical thrombectomy with Penumbra Indigo System (P), partial improvement, with residual intraluminal thrombus (asterisk), palmar arch percutaneous transluminal angioplasty using a long 2.0 mm × 210 mm peripheral balloon (yellow arrow) with good final angiographic result.

Various dedicated catheters for manual thrombectomy have been reported, including PriorityOne AC (Terumo Interventional Systems), the Aspire (Control Medical Technology), Xpress-Way (Getinge), Export (Medtronic), ASAP aspiration catheter (Merit Medical Systems), Pronto (Teleflex), and QuickCat (Spectranetics).<sup>16</sup> The small inner diameter of the aspiration catheter is an important limitation of thrombectomy. Aspiration with bigger inner-diameter catheters is a common and effective method, but advancing the device is challenging. The Indigo System (Penumbra Inc., CA, USA) is a dedicated aspirator system for mechanical thrombectomy to remove thrombus from arteries or veins, and it has been well established in the treatment of

pulmonary embolism<sup>17</sup> and lower limb ischaemia.<sup>18</sup> The device is comprised of a mechanical thrombectomy catheter, separator, aspiration tubing, aspiration source, and a canister. The trackability of Indigo catheters is better than normal catheters in stiff, calcified vessels. Because of the softer tip, the risk of vessel injury is lower. Buddy-wire, distal anchor, balloon-assisted tracking, and inchworm technique facilitate the tracking, but the high-pushing force increases the risk of vessel injury, and changing with a smaller catheter size can be useful. Also, the guidewire should be removed to not reduce the lumen of the aspiration catheter. Waiting 1 or 2 min after starting the vacuum system is recommended in order to fix the thrombus at the tip of the catheter. Before removing



**Video 1** Final angiographic result with good flow throughout the palmar arch and no residual thrombus.

the aspiration catheter, the guide should be in the upper extremity artery to avoid systemic embolization. The engine maintains the vacuum during the aspiration, in contrast to conventional syringe aspiration, so it reduces the risk of embolization. After aspiration, catheter back-bleeding and arterial pressure waveform should be visualized to ensure that there is no thrombus left inside the gear.

## Conclusion

Coronavirus disease-19 might aggravate vascular injuries in young professional athletes who use their hands. The Indigo Aspiration System for treatment of acute ULL is a feasible percutaneous option in selected cases with a high thrombus burden, and it is safer and more effective than thrombectomy with smaller inner-diameter catheters.

## Lead author biography



Interventional Cardiology fellow and enthusiast, former EAPCI-PCR IC Training (Graz, Austria, 2020), research and PhD student at the Medical University of Szeged, Hungary (2020) and present complex PCI and CTO fellow in Basel, Switzerland (2021).

## Supplementary material

Supplementary material is available at *European Heart Journal - Case Reports* online.

**Slide sets:** A fully edited slide set detailing this case and suitable for local presentation is available online as [Supplementary data](#).

**Consent:** The authors confirm that written consent for submission and publication of this case report including images and associated text has been obtained from the patient in line with COPE guidance.

**Funding:** None declared.

**Conflict of interest:** None declared.

## References

- Jongkind V, Earnshaw JJ, Bastos GF, Cochenec F, Debus ES, Hinchliffe R et al. Update of the European Society for Vascular Surgery (ESVS) 2020 clinical practice guidelines on the management of acute limb ischaemia in light of the COVID-19 pandemic, based on a scoping review of the literature. *Eur J Vasc Endovasc Surg* 2021;**S1078**:00688–00682.
- Kohansal Vajari M, Shirin M, Pourbagheri-Sigaroodi A, Akbari ME, Abolghasemi H, Bashash D. COVID-19-related coagulopathy: a review of pathophysiology and pharmaceutical management. *Cell Biol Int* 2021;**45**:1832–1850.
- Goswami J, MacArthur TA, Sridharan M, Pruthi RK, McBane RD, Witzig TE et al. A Review of pathophysiology, clinical features, and management options of COVID-19 associated coagulopathy. *Shock* 2021;**55**:700–716.
- Dieter RS, Dieter RA, Jr, Dieter RA, III, Nanjundappa A, editors. *Critical Limb Ischemia: Acute and Chronic*. Switzerland: Springer International Publishing; 2017.
- Ruzsa Z, Berta B, Tóth J, Nemes B, Katona A, Hüttl A et al. Short- and long-term results with a percutaneous treatment in critical hand ischaemia. *Catheter Cardiovasc Interv* 2019;**93**:1301–1310.
- D'Oria M, Mills JL Sr, Cohnert T, Oderich GS, Hultgren R, Lepidi S. The "Vascular Surgery COVID-19 Collaborative" (VASCC). *Eur J Vasc Endovasc Surg* 2020;**60**:489.
- McCarthy WJ, Yao JS, Schafer MF, Nuber G, Flinn WR et al. Upper extremity arterial injury in athletes. *J Vasc Surg* 1989;**9**:317–327.
- Yao JS. Upper extremity ischemia in athletes. *Semin Vasc Surg* 1998;**11**:96–105.
- Bouwmeester OVA, van de Pol D, Kuijter PPFM, Planken RN, Terpstra A, Pannekoek-Hekman M et al. Diagnostic properties of the SPIQuestionnaire to detect posterior circumflex humeral artery disease in elite volleyball players: a cross-sectional study. *Eur J Radiol* 2018;**98**:20–24.
- van de Pol D, Kuijter PP, Langenhorst T, Maas M. High prevalence of self-reported symptoms of digital ischemia in elite male volleyball players in the Netherlands: a cross-sectional national survey. *Am J Sports Med* 2012;**40**:2296–2302.
- Nuber GW, McCarthy WJ, Yao JS, Schafer MF, Suker JR. Arterial abnormalities of the hand in athletes. *Am J Sports Med* 1990;**18**:520–523.
- Goshua G, Pine AB, Meizlish ML, Chang CH, Zhang H, Bahel P et al. Endotheliopathy in COVID-19-associated coagulopathy: evidence from a single-centre, cross-sectional study. *Lancet Haematol* 2020;**7**:575–582.
- Escher R, Breakey N, Lammle B. Severe COVID-19 infection associated with endothelial activation. *Thromb Res* 2020;**190**:62.
- Favaloro EJ, Henry BM, Lippi G. COVID-19 and antiphospholipid antibodies: time for a reality check? *Semin Thromb Hemost* 2021;**48**:72–92. doi: 10.1055/s-0041-1728832.
- Borghi MO, Beltagy A, Garrafa E, Curreli D, Cecchini G, Bodio C et al. Anti-phospholipid antibodies in COVID-19 are different from those detectable in the anti-phospholipid syndrome. *Front Immunol* 2020;**11**:584241.
- Lind B, Morcos O, Ferral H, Chen A, Aquisto T, Lee S et al. Endovascular strategies in the management of acute limb ischemia. *Vasc Specialist Int* 2019;**35**:4–9.
- Sista AK, Horowitz JM, Tapson VF, Rosenberg M, Elder MD, Schiro BJ et al. Indigo aspiration system for treatment of pulmonary embolism: results of the EXTRACT-PE trial. *JACC Cardiovasc Interv* 2021;**14**:319–329.
- de Donato G, Pasqui E, Sponza M, Intrieri F, Spinazzola A, Silingardi R et al. Safety and efficacy of vacuum assisted thrombo-aspiration in patients with acute lower limb ischaemia: the INDIAN Trial. *Eur J Vasc Endovasc Surg* 2021;**61**:820–828.