



## Letter to the Editor

## Intracoronary thrombus on optical coherence tomography in a patient with variant angina: Treatment and follow-up



Péter Hausinger<sup>a</sup>, Imre Ungi<sup>a</sup>, Gyula Szántó<sup>a</sup>, László Hajtman<sup>a</sup>, Tamás Forster<sup>a</sup>, Evelyn Regar<sup>b</sup>, Attila Thury<sup>a,\*</sup>

<sup>a</sup> Invasive Cardiology Unit, Cardiology Center, University of Szeged, Szókefalvi-Nagy Béla u. 6, H-6720 Szeged, Hungary

<sup>b</sup> Department of Cardiology, Thoraxcenter, BA-585, Erasmus University Medical Center, Rotterdam, The Netherlands

## ARTICLE INFO

## Article history:

Received 18 May 2014

Accepted 5 July 2014

Available online 22 July 2014

## Keywords:

Variant angina

Coronary artery disease

Intracoronary thrombus

Optical coherence tomography

Stent

Neoatherosclerosis

Variant angina is caused by transient and recurrent coronary spasm leading to episodes of transmural myocardial ischemia with ST segment elevation. Neurological, humoral, local factors and endothelial dysfunction are important predisposing factors [1]. However, intravascular ultrasound studies have shown that atherosclerosis is invariably present at the site of focal vasospasm [2]. Intravascular optical coherence tomography (OCT) is a high-resolution imaging method for plaque characterization and detection of intracoronary thrombus [3]. We present a case of variant angina with evidence of coronary spasm related to non-occlusive intraluminal thrombus detected by OCT.

An 81 year-old patient presented with NSTEMI with history of hypertension, smoking and peptic ulcer (also had occult gastrointestinal bleeding 2–3 weeks prior to admission). Coronary angiography revealed a 50% stenosis on mid-LAD (Fig. 1), with minimal haziness at the lesion, suspicious of intraluminal thrombus but flow was not impaired. Fractional flow reserve test (PressureWire Certus, 240 µg ic. bolus adenosine) measurement excluded the presence of a hemodynamic relevant stenosis (FFR = 0.97).

Consequently, the patient was discharged to step-down unit with complete medication consisting of dual antiplatelet-, beta-blocker-, ACE inhibitor- and statin therapy. However, the patient experienced repetitive episodes of intensive chest pain with increasing severity at rest which was accompanied by 10–15 mm ST elevation in the precor-

dial leads (Fig. 2). Medication was complemented with parenteral nitroglycerin and increasing dose of Ca-antagonist but symptoms were maintained in the following 2 weeks. Thus, a control coronary angiography was performed which demonstrated no relevant change of the vessel or the lesion. An OCT examination was performed (Dragonfly™ catheter, St. Jude C7-XR console) which detected a flattened intraluminal white thrombus on a 9-mm segment at the site of the borderline LAD lesion just proximal to the diagonal branch (Figs. 3 and 4). OCT also revealed a loss of the endothelial lining with lacerations of the superficial intimal layers without “trans-cap” rupture just distal to the thrombus (Fig. 5).

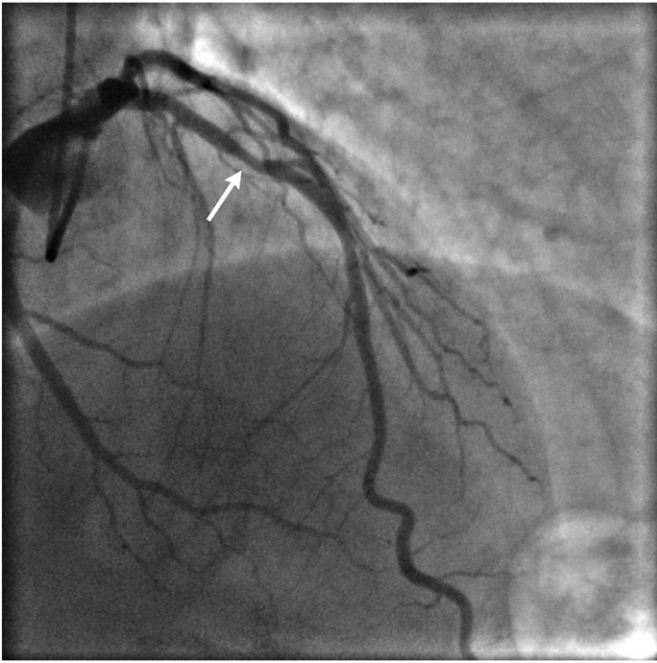
Since the patient had severe persistent symptoms and relative contraindication to receive GP2b3a-blocker therapy, on the basis of the OCT images we consented him to receive a stent to stabilize the lesion (3.5 × 18 mm zotarolimus-eluting stent was implanted with 16 atm, post-dilated with 3.5 × 15 mm NC balloon, 24 atm) without complication. Post-procedure OCT examination showed well expanded and apposed stent (Fig. 6). At nine-month follow-up the patient was free of angina. Angiography showed no in-stent restenosis, however OCT demonstrated small degree of concentric layered lipid-laden intima which could be an atypical appearance of neoatherosclerosis within the proximal part of the stent at the site of remote thrombus (Fig. 7).

We report a case of a patient presenting troponin-positive unstable (variant) angina with intraluminal thrombus where clinical decision-making was assisted by intracoronary OCT. This thrombus was superposed on a large eccentric plaque which appeared to be fibroatheroma. Also, on the surface of the plaque we suspect some laceration distal to the site of thrombus. On the basis of these findings we hypothesize that plaque erosion took place at the culprit lesion site with consequent thrombus formation. Our case is similar to the patient of Takano et al. [4].

Vasoconstrictor substances are well-known [5] to get liberated from rather fresh thrombi ultimately leading to obstructive transient repetitive spasm in our case. Recently, coronary endothelial laceration is reported to play a major role in cardiac allograft vasculopathy [6] and also in plaque progression [7]. This trigger might have caused plaque erosion in our patient which is a frequent cause of myocardial infarction [8]. However in our case, we cannot exclude that minor disruption might be covered by the attenuation of the large thrombus. In 2007 OCT was already demonstrated [3] to be superior to IVUS in detecting fibrous cap erosion which was characterized by loss of the endothelial lining with lacerations of the superficial intimal layers and without “trans-cap” ruptures.

\* Corresponding author.

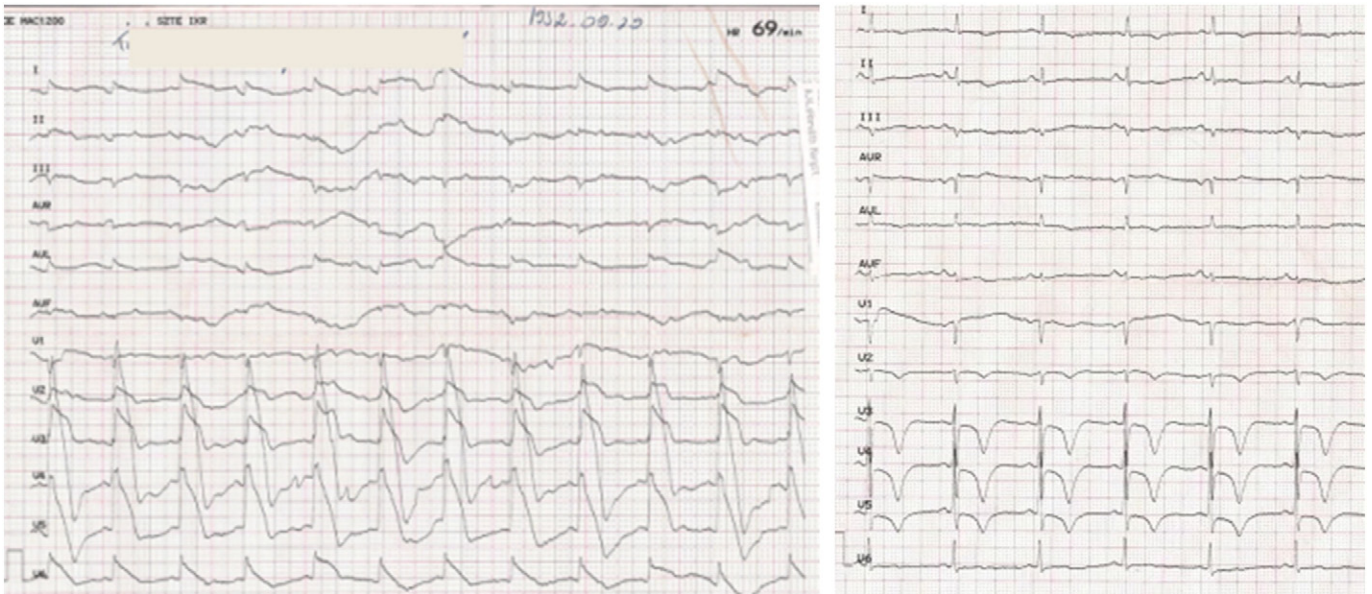
E-mail address: [thury.attila@med.u-szeged.hu](mailto:thury.attila@med.u-szeged.hu) (A. Thury).



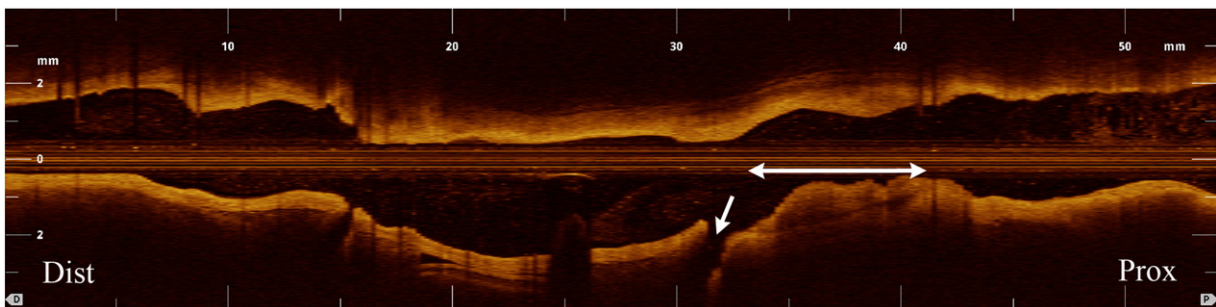
**Fig. 1.** Right cranial view of the left coronary shows a 50% stenosis (white arrow) in mid-LAD. The LAD supplies a large area of the left ventricle and had normal flow dynamics.

We treated our patient with local stabilization (stenting) of this culprit lesion, immediate result was satisfactory on angiography and OCT (Fig. 6). Also, more importantly chest pain and vasospastic attacks of the patient ceased completely. This invasive treatment is a matter of current debate in the literature [9]. Recent retrospective analysis [10] demonstrated successful OCT-based management of these patients without stenting. However, we believe that in our patient this was indeed substantiated by the relative contraindication to GP2b3a-blocker therapy. Moreover, it might be hypothesized that we could halt the progression of non-flow limiting coronary plaque as it had been found to present more intimal laceration and also thrombi at index examination than those not progressing [7].

Late (9-month) clinical outcome was uneventful. Angiographic and OCT follow-up showed non-significant restenosis at proximal edge of the stent (30% diameter stenosis) with almost circular neointimal tissue proliferation. However, at the proximal part of the stent this neointima shows layered, signal-poor appearance which resembles some form of neoatherosclerosis. This phenomenon has recently gained much attention and described in details [11]. It develops earlier in drug-eluting stents and histology clarified its various OCT appearances [12]. It is more frequent in current smokers [13]; our patient was also a heavy smoker at both hospital admissions. It also seems logical that initial thrombus-burden could play a role in the development of neoatherosclerosis, in line with restenosis in drug-eluting stents had been correlated with thrombus formation [14]. We don't know what clinical importance this finding holds for our patient, but we



**Fig. 2.** ECG during chest pain (left panel) and after it resolved (right panel).



**Fig. 3.** Longitudinal view of the original OCT pullback (20 mm/s, 54 mm). A large white intraluminal thrombus can be seen on a 9-mm long segment (arrow) at the site of the borderline lesion just proximal to the diagonal branch (small arrow).

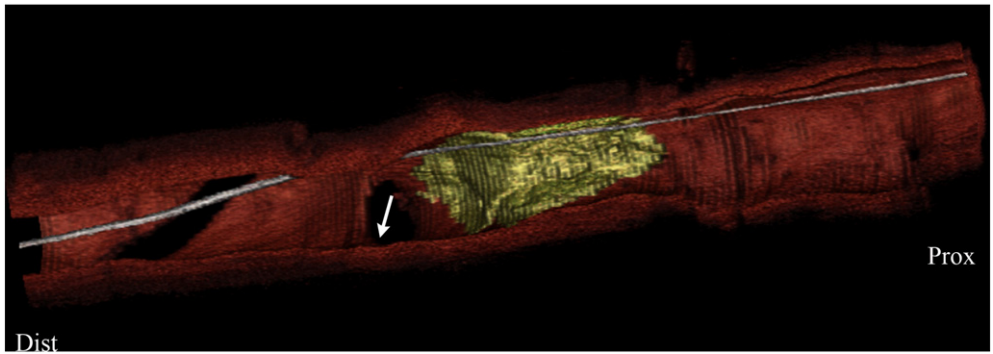


Fig. 4. 3D reconstruction of the segment. The overlying surface of the thrombus is illustrated with a yellow color (diagonal branch is denoted with small arrow).

strongly advised him to quit smoking, adhere to secondary preventive medication.

Plaque erosion and subsequent platelet activation with thrombus formation detected by OCT may increase the risk of coronary spasm and variant angina. OCT may be a feasible method to study the

underlying pathology of culprit lesions in patients suffering from variant angina. In select cases, stenting of lesions may become necessary even if functionally not significant. However, at late follow-up we found neoatherosclerotic changes in the proximal (originally thrombotic) part of the stent, which deserves further attention.

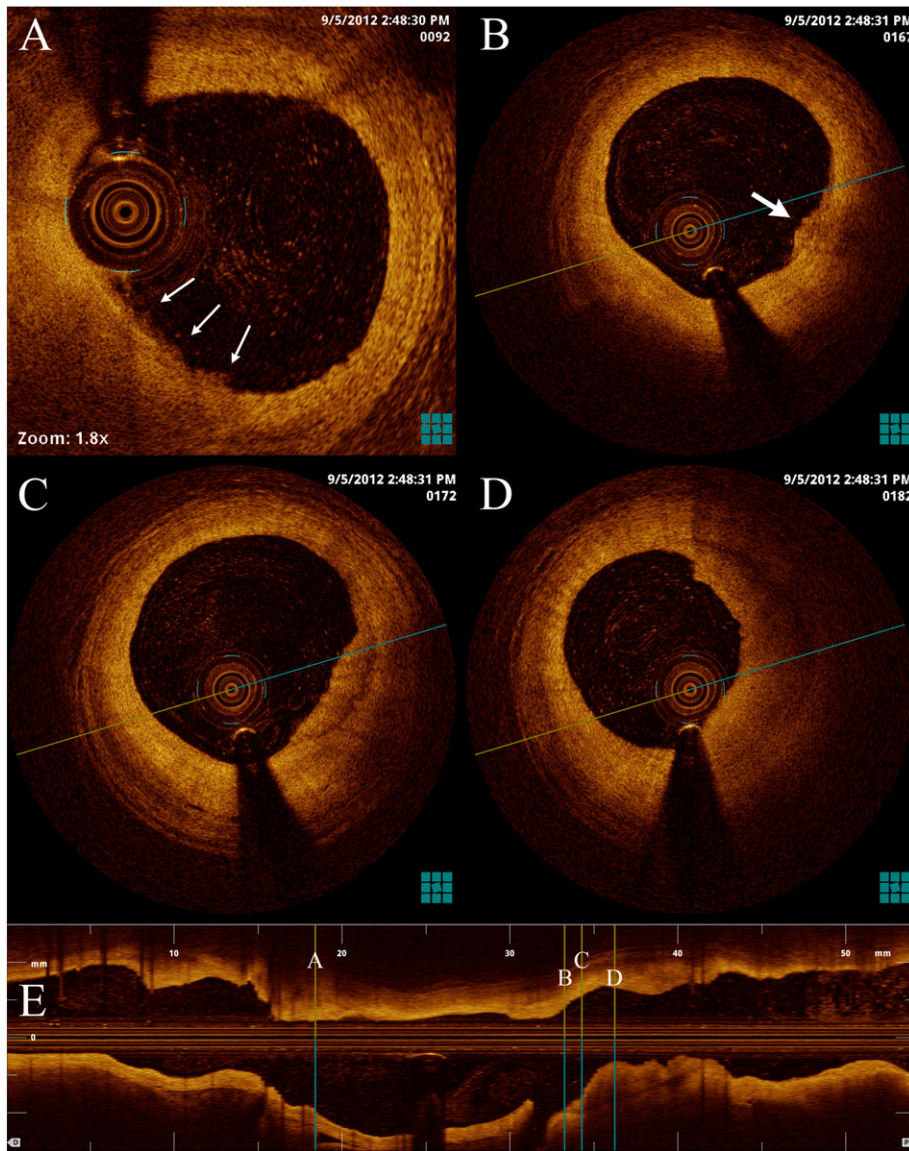
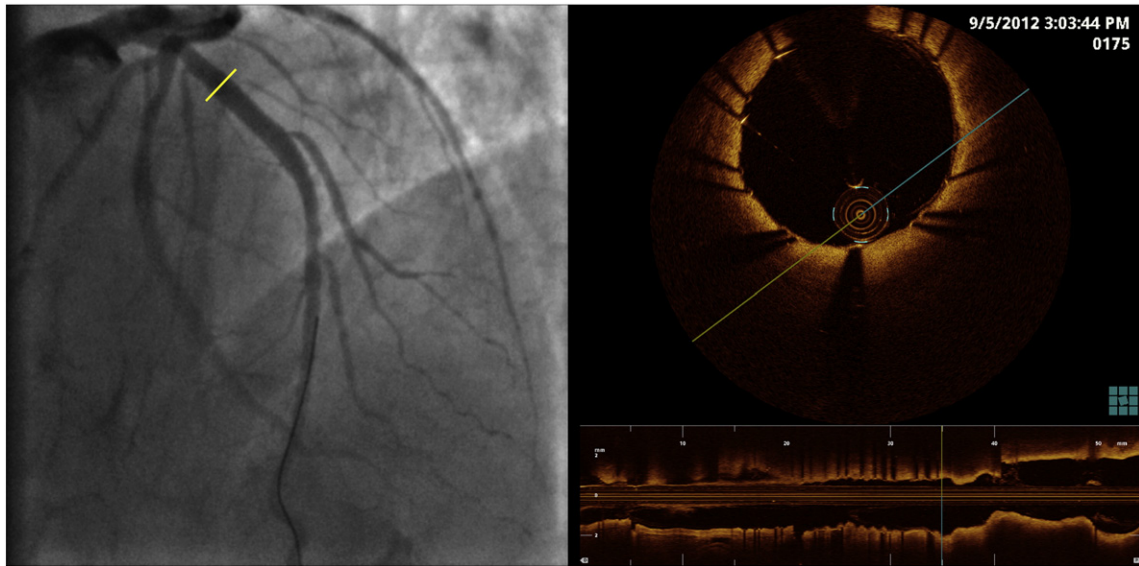
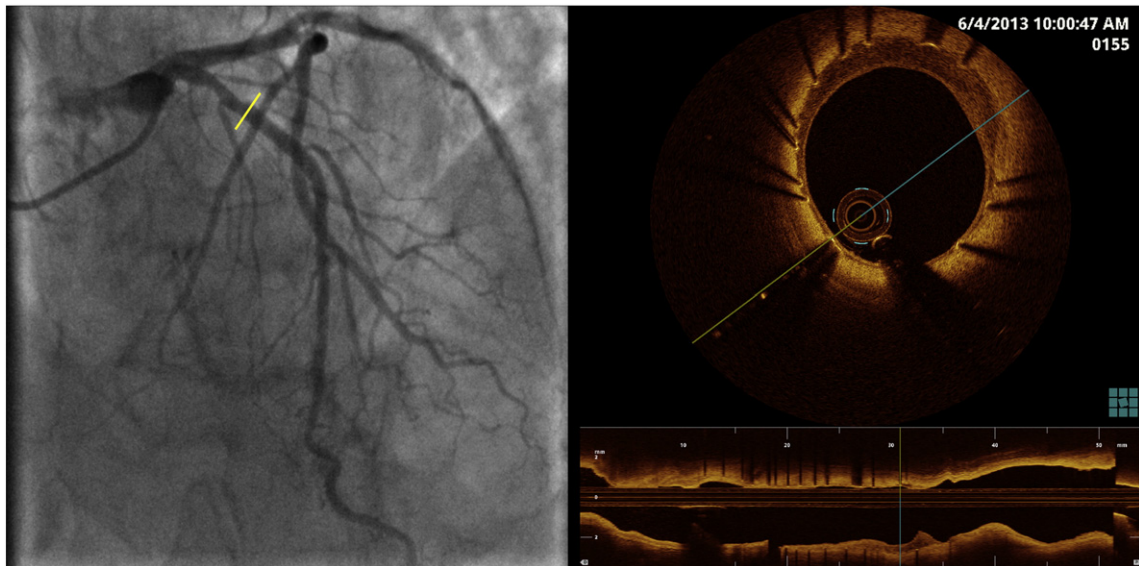


Fig. 5. Cross-sections of mid-LAD with diffuse concentric fibroatheroma. Panel A shows enlarged image with possible lacerations (small arrows). Panel B shows a small thrombus (arrow) of a possibly denuded (eroded) intimal layer. Panels C and D clearly show the large intraluminal thrombus lying on thick fibroatheroma (panel D is the cross-section at the minimal lumen area).



**Fig. 6.** Angiography and OCT cross-section at the site of pre-procedure proximal cross-section of the lesion (yellow line) immediately after stent-implantation and optimization with NC balloon post-dilatation. OCT shows good apposition; no residual thrombus.



**Fig. 7.** At 9-month, on angiographic follow-up, there was no apparent angiographic restenosis. However, at the corresponding section of the index procedure (yellow line) some signal poor and low-attenuation layer on the luminal surface of the struts is clearly visible.

## References

- [1] Stern S, Bayes de Luna A. Coronary artery spasm: a 2009 update. *Circulation* 2009; 119:2531–4.
- [2] Saito S, Yamagishi M, Takayama T, et al. Plaque morphology at coronary sites with focal spasm in variant angina: study using intravascular ultrasound. *Circ J* 2003;67:1041–5.
- [3] Kubo T, Imanishi T, Takarada S, et al. Assessment of culprit lesion morphology in acute myocardial infarction: ability of optical coherence tomography compared with intravascular ultrasound and coronary angiography. *J Am Coll Cardiol* 2007;50:933–9.
- [4] Takano M, Kitamura M, Inami T, Seino Y, Mizuno K. Acute coronary syndrome without optical coherence tomography identification of plaque disruption: is this plaque erosion? *Int J Cardiol* 2013;163:e14–5.
- [5] Herrmann KS, Kreuzer H. Local measurements of thrombus induced vasoconstriction in vivo. *Thromb Res* 1988;50:827–35.
- [6] Cassar A, Matsuo Y, Herrmann J, et al. Coronary atherosclerosis with vulnerable plaque and complicated lesions in transplant recipients: new insight into cardiac allograft vasculopathy by optical coherence tomography. *Eur Heart J* 2013;34:2610–7.
- [7] Uemura S, Ishigami K, Soeda T, et al. Thin-cap fibroatheroma and microchannel findings in optical coherence tomography correlate with subsequent progression of coronary atheromatous plaques. *Eur Heart J* 2012;33:78–85.
- [8] Farb A, Burke AP, Tang AL, et al. Coronary plaque erosion without rupture into a lipid core. A frequent cause of coronary thrombosis in sudden coronary death. *Circulation* 1996;93:1354–63.
- [9] Holmes Jr DR, Lerman A, Moreno PR, King III SB, Sharma SK. Diagnosis and management of STEMI arising from plaque erosion. *JACC Cardiovasc Imaging* 2013;6:290–6.
- [10] Prati F, Uemura S, Souteyrand G, et al. OCT-based diagnosis and management of STEMI associated with intact fibrous cap. *JACC Cardiovasc Imaging* 2013;6:283–7.
- [11] Park SJ, Kang SJ, Virmani R, Nakano M, Ueda Y. In-stent neoatherosclerosis: a final common pathway of late stent failure. *J Am Coll Cardiol* 2012;59:2051–7.
- [12] Kim JS, Afari ME, Ha J, et al. Neointimal patterns obtained by optical coherence tomography correlate with specific histological components and neointimal proliferation in a swine model of restenosis. *Eur Heart J Cardiovasc Imaging* 2014;15:292–8.
- [13] Yonetsu T, Kato K, Kim SJ, et al. Predictors for neoatherosclerosis: a retrospective observational study from the optical coherence tomography registry. *Circ Cardiovasc Imaging* 2012;5:660–6.
- [14] Oikawa Y, Yajima J, Costa MA, et al. Intravascular ultrasound, angiographic and histopathological characterisation of heterogeneous patterns of restenosis after sirolimus-eluting stent implantation: insights into potential “thromborestenosis” phenomenon. *EuroIntervention* 2010;6:380–7.