

# Journal Pre-proof

The biomechanical effect of root amputation and degree of furcation involvement on intracoronally splinted upper molar teeth – An *in vitro* study

Veronika T. Szabó, Balázs Szabó, Balázs Paczona, Csongor Mészáros, Gábor Braunitzer, P. Balázs Szabó, Sufyan Garoushi, Márk Fráter



PII: S1751-6161(22)00066-2

DOI: <https://doi.org/10.1016/j.jmbbm.2022.105143>

Reference: JMBBM 105143

To appear in: *Journal of the Mechanical Behavior of Biomedical Materials*

Received Date: 12 January 2022

Revised Date: 18 February 2022

Accepted Date: 23 February 2022

Please cite this article as: Szabó, V.T., Szabó, Balá., Paczona, Balá., Mészáros, C., Braunitzer, Gá., Balázs Szabó, P., Garoushi, S., Fráter, Má., The biomechanical effect of root amputation and degree of furcation involvement on intracoronally splinted upper molar teeth – An *in vitro* study, *Journal of the Mechanical Behavior of Biomedical Materials* (2022), doi: <https://doi.org/10.1016/j.jmbbm.2022.105143>.

This is a PDF file of an article that has undergone enhancements after acceptance, such as the addition of a cover page and metadata, and formatting for readability, but it is not yet the definitive version of record. This version will undergo additional copyediting, typesetting and review before it is published in its final form, but we are providing this version to give early visibility of the article. Please note that, during the production process, errors may be discovered which could affect the content, and all legal disclaimers that apply to the journal pertain.

© 2022 Published by Elsevier Ltd.

Short Communication

The biomechanical effect of root amputation and degree of furcation involvement on intracoronally splinted upper molar teeth – an *in vitro* study

Veronika T. Szabó<sup>1</sup>, Balázs Szabó<sup>2</sup>, Balázs Paczona<sup>1</sup>, Csongor Mészáros<sup>1</sup>, Gábor Braunitzer<sup>3</sup>, Balázs Szabó P.<sup>4</sup>, Sufyan Garoushi<sup>5</sup> and Márk Fráter<sup>1\*</sup>

<sup>1</sup>Department of Operative and Esthetic Dentistry, Faculty of Dentistry, University of Szeged, Szeged, Hungary

<sup>2</sup>Department of Periodontology, Faculty of Dentistry, University of Szeged, Szeged, Hungary

<sup>3</sup>dicomLAB Dental Ltd., Szeged, Hungary

<sup>4</sup>Department of Food Engineering, Faculty of Engineering, University of Szeged, Szeged, Hungary

<sup>5</sup>Department of Biomaterials Science and Turku Clinical Biomaterials Centre - TCBC  
Institute of Dentistry, University of Turku, Turku, Finland

Veronika T. Szabó and Balázs Szabó contributed equally to this work.  
Sufyan Garoushi and Márk Fráter contributed equally to this work.

\*Corresponding author:

Dr. Márk Fráter, DMD, PhD, M.Sc., assistant professor  
Department of Operative and Esthetic Dentistry  
Faculty of Dentistry  
University of Szeged  
Tisza Lajos Krt. 64  
H-6720  
Szeged, HUNGARY  
+36303192937  
E-mail address: meddentitst.fm@gmail.com

## Abstract

**Objectives.** The aim of this study was to evaluate the effect of the amount of periodontal support and the presence or absence of root amputation on the fracture resistance of intracoronally splinted maxillary molar teeth.

**Materials and Methods.** 48 extracted human upper first molars and 48 second premolars were included in the study. All teeth underwent standard mesio-occluso-distal (MOD) (molars) and standard occluso-distal (OD) (premolars) cavity preparation. After the preparation, all molars were root canal treated, and 48 molar-premolar units were created by intracoronally splinting. The units were randomly divided into 4 groups (Groups A-D, 12 units per group): in Groups C and D, the disto-buccal (DB) roots of the molars were amputated, while in Groups A and B, no root amputation was performed. All units were embedded in methacrylate resin at different levels: in Groups A and C, at 4 mm apically from the cemento-enamel junction (CEJ), while in Groups B and D, at 6 mm apically from the CEJ, mimicking the different stages of furcation involvement. All units were submitted first to dynamic and then to static, load-to-fracture mechanical testing. Fracture resistance values were recorded and fracture mode was analysed.

**Results.** During the load-to-fracture test, Groups A and B (without root amputation) were characterized by significantly higher fracture resistance values compared to Groups C and D (with root amputation) ( $p < 0.05$ ). Regarding fracture mode, irreparable fracture was more frequent in Group D (with root amputation and advanced furcation involvement) than in any other group ( $n=8$ ).

**Conclusions.** Root amputation has a negative effect on the fracture resistance of intracoronally splinted upper first molar-second premolar units with modeled furcation involvement.

**Keywords:** furcation involvement, root amputation, intracoronally splinting, fracture resistance, biomechanical behavior

## Highlights:

- Root amputation negatively affects furcation-involved, splinted upper posterior units
- The level of furcation involvement is not a major influencing factor in these cases

## Introduction

Periodontitis is one of the most common oral health conditions among adults [1]. According to epidemiological surveys, the incidence of periodontitis shows a quite uniform picture worldwide [2]. Those types of periodontal disease that affect the supporting tissues usually result in irreversible destruction of the alveolar bone. Simultaneously with bone degradation, the periodontal ligaments are also damaged, which leads to attachment loss that –if left untreated– can result in tooth loss [3,4]. Deterioration of the attachment apparatus is usually a slow process and it shows individual differences in its extent and clinical appearance over time [5]. In the case of multi-rooted teeth, a special situation known as furcation involvement may occur [6,7]. The treatment of this is one of the greatest challenges in periodontal therapy [5,8,9]. Periodontal disease is treated either in a conservative manner or surgically. According to Hermann et al., by the time the furcation has been exposed, more than 30% of the available attachment surface has been lost [10]. Also, due to the poor accessibility of the exposed furcal area, molar teeth respond less favorably to non-surgical periodontal treatment than single-rooted teeth [11], which may necessitate more invasive interventions (e.g. root amputation, etc.). Root amputation is the surgical procedure by which one or more roots of a multi-rooted tooth are removed at the level of the furcation whilst the crown and remaining roots are left in function [6,12]. Restoration and maintenance therapy of teeth that have undergone root amputation poses a serious challenge to dentist and patient alike. Both furcation involvement and root amputation can increase tooth mobility, which can lead to further loss of attachment [13], and intracoronally splinting of the affected posterior tooth with fiber-reinforced material may become necessary.

From a clinical perspective, degradation of the periodontal tissues most commonly affects multi-rooted, upper posterior teeth, which are difficult to clean and have complex anatomy [14,15]. As a result, the second and third molars are often extracted earlier than the other teeth, and so the upper first molars may become the most distal teeth in the arch, exposed to excessive loading during chewing. It is characteristic of this unfortunate, yet common situation that the pre-existing periodontal bone destruction on the distal surface is further aggravated by the degeneration of the alveolar bone following extraction.

The question arises as to whether the presence or absence of root amputation and the remaining bone level may play a role in the fracture behavior of intracoronally splinted upper maxillary first molar teeth. In this study, our null hypothesis was that neither of the mentioned factors

would have a significant effect on the maximal fracture resistance and fracture mode in intracoronally splinted upper maxillary first molars.

Journal Pre-proof

## **Materials and methods**

### **Sample selection**

All procedures of the study were approved by the Ethics Committee of the University of Szeged, and the study was designed in accordance with the Declaration of Helsinki.

In this study 48 maxillary molars and 48 maxillary premolars extracted for periodontal or orthodontic reasons were selected for this study. The freshly extracted teeth were immediately placed in 5.25% NaOCl for 5 minutes and then stored in 0.9% saline solution at room temperature until the soft tissues from the root surface were removed with hand scalers. All teeth were used within 6 months after extraction. Inclusion and exclusion criteria, and standardization regarding coronal and root dimensions were the same as in our previous studies [16,17]. The inclusion criteria were visual absence of caries or root cracks, absence of previous endodontic treatment, posts or crown, or resorptions. Regarding the coronal dimensions of the molar teeth, approximately 80% of the specimens ranged 10 to 10.9 mm in the bucco-palatal dimension, and the rest were between 11 to 12 mm. The mesio-distal dimension of the specimens was also measured; a mean was calculated and specimens that fell within the  $\pm 10\%$  range of the mean were included. The height of the specimens was between 8 and 9 mm measured from the cemento-enamel-junction (CEJ). Also, root length was also standardized as follows: mesio-buccal: 12–14 mm, distobuccal: 11–13 mm, palatal 12–15 mm. Regarding the coronal dimensions of the premolars, 90% of the teeth ranged between 9 and 10 mm bucco-palately. The average mesio-distal dimension was between 7 and 7.5 for 90% of the samples. Ten percent maximum deviation was allowed in the remaining 10% of the samples.

### **Cavity preparation and coronal restoration**

Standardized occluso-distal (OD) (premolars) and mesio-occluso-distal (MOD) (molars) cavities were prepared in all teeth according to Cara et al., [18] as follows: the bucco-palatal width (BPW) of the approximal box was prepared to two-thirds of the BPW of the tooth, and the occlusal isthmus was prepared to half the BPW. In addition, the cavity depth at the occlusal isthmus was also standardized to 3.5 mm from the tip of the lingual cusp and 1 mm above the CEJ at the cervical aspect of the approximal boxes. After cavity preparation, the molar teeth underwent root canal treatment according to the protocol described by Szabó et al., [17]. The root canals were instrumented with Pathfiles (1–2–3) and ProTaper (S1-S2-F1-F2-F3) (Dentsply Maillefer, Ballaigues, Switzerland) to the working length. The specimens were irrigated with 5% NaOCl alternated with 10% EDTA (ethylenediaminetetraacetic acid) with a

2-mL syringe and 25-gauge needle. Root canal filling was performed by matched-single-cone obturation with a master cone (F3 gutta-percha, Dentsply-Maillefer) matching the final instrument used for preparation and sealer (AH plus, Dentsply-Maillefer). Following root canal obturation, a base was applied to the pulp chamber in the form of an approx. 2 mm thick glass-ionomer barrier (Equia Forte, GC Europe, Leuven, Belgium).

After the root canal obturation, all cavity preparations were finalized. The cavosurface margins were prepared perpendicular to the tooth surface at the end of the preparation. The cavity was rinsed with water and air-dried with an air/water syringe. All premolar and molar specimens received the same adhesive treatment. The enamel was acid-etched selectively with 37% phosphoric acid for 15 seconds, rinsed with water and air-dried. The cavity was adhesive-treated with G-Premio Bond (GC Europe) according to the manufacturer's instructions. The adhesive layer was light-cured for 40 seconds with an Optilux 501 halogen light in standard mode at a light intensity of  $740 \pm 36 \text{ mWcm}^2$ . The gingival boxes were levelled till the position of the occlusal cavity with packable composite resin (G-aenial Posterior A3, GC Europe) to aid the positioning of the splinting fibers. Premolar and molar tooth pairs were randomly selected and embedded in silicon material (Elite HD Putty, Zhermack SpA, Badia Polesine, Italy) to stabilize the teeth during the intracoronal splinting procedure (Figure 1).

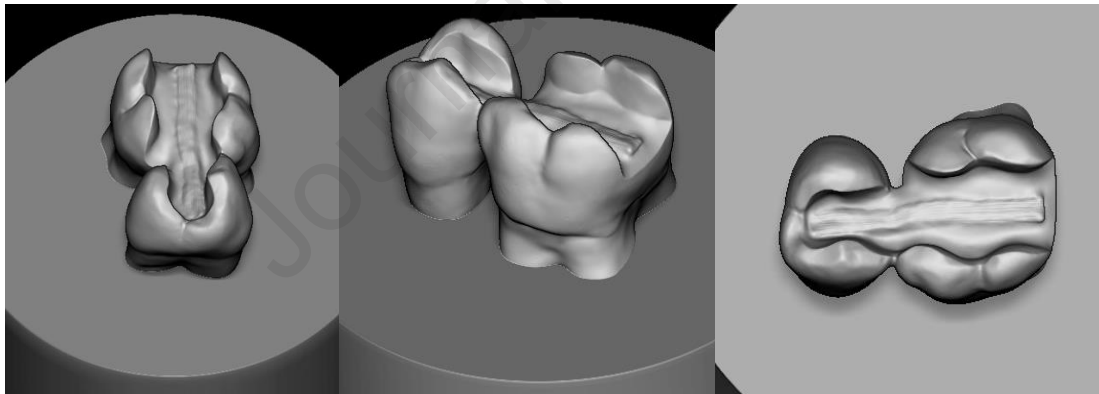


Figure 1. The images show the positioning of the teeth and the splint during the restorative procedures.

Splinting was carried out with long E-glass fibers (everStick Perio, GC Europe). The size of the cavities was measured with a periodontal probe and fiber bundles were cut to the adequate length. After adhesive treatment of the fiber bundle splint according to manufacturer's instructions, the fibers were positioned into a layer of highly filled flowable composite resin (G-aenial Universal Flo A3, GC Europe) and light cured for 1 minute. The remaining part of the cavities were restored with packable composite resin (G-aenial Posterior A3, GC Europe) in an oblique layering manner. Each layer was light cured for 40 seconds.

The splinted models were randomly divided into 4 groups (n=12, Group A, B, C and D). In Group C and D each disto-buccal (DB) root was sectioned horizontally at the level of the furcation with a fissure diamond bur (881.31.014 FG – Brasseler USA Dental, Savannah, GA). The sectioned surfaces were smoothed to eliminate any remnants below the sectioning level to have a cleansable non-retentive surface. In Group A and B no root amputation was performed.

The restored specimens were kept wet (Isotonic Saline Solution 0.9%; B. Braun, Melsungen, Germany) in an incubator (37°C). The root surface of each specimen was coated with two layers of liquid latex separating material (Rubber-Sep, Kerr, Orange, CA, USA) prior to embedding for mimicking the periodontal ligament. To simulate the bone level, the restored teeth were embedded in methacrylate resin (Technovit 4004, Heraeus-Kulzer, Germany). The artificial bone level was set at 4 mm from the cemento-enamel junction (CEJ) in Group A and C, simulating mild furcation involvement (Figure 2 A and C), while in Group B and D 6 mm from the CEJ, simulating more advanced/moderate furcation involvement (Figure 2 B and D).

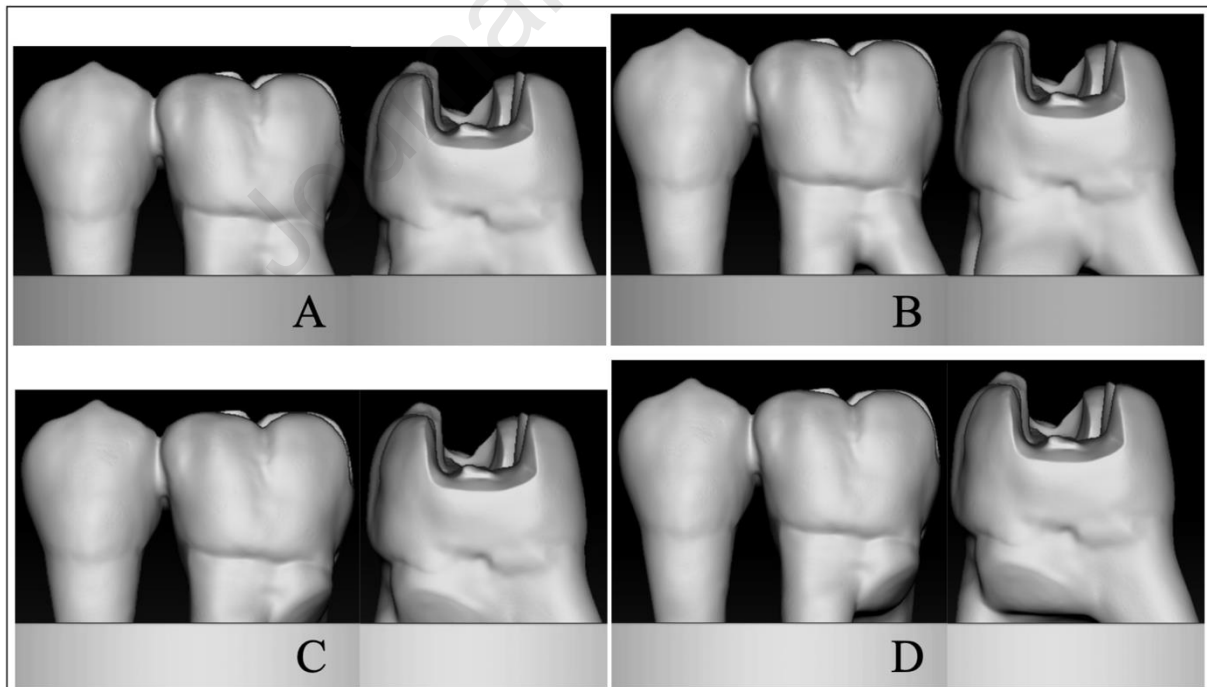


Figure 2: Three-dimensional virtual reconstructions to illustrate the four study groups: A: Group A, no root amputation and mild furcation involvement (4 mm) , B: no root amputation and advanced/moderate furcation involvement (6 mm) , C: root amputation and mild furcation



involvement (4 mm) , D: root amputation and advanced/moderate furcation involvement (6 mm).

Mechanical testing was carried out in two phases. In the first phase (pretesting), the restoration-tooth units were firstly submitted to an accelerated fatigue-testing protocol [19,20], performed with a hydrodynamic testing machine (Instron ElektroPlus E3000, Norwood, MA, USA). Cyclic isometric loading was applied on the connector part of the splinted teeth units with a 5 mm wide, round ended metallic tip. Cyclic load was applied at 5 Hz, starting with gradually increasing static loading till 100 N in 5 seconds, followed by cyclic loading in 100 N steps up to 500 N, with 5000 cycles per step. The specimens were loaded until fracture occurred or up to 25,000 cycles. This phase served the purpose of simulating biting forces occurring during normal mastication. In the second phase, the survived specimens underwent static load-to-fracture testing (Lloyd R1000, Lloyd Instruments Ltd., Fareham, UK) at a crosshead speed of 2 mm/min. This phase simulated the occurrence of traumatic forces. A force vs. extension curve was dynamically plotted for each specimen. Fracture threshold, defined as the load at which the tooth-restoration complex exhibited the first fracture (detectable as peak formation on the extension curve), was recorded in Newtons (N).

After completing the loading test, the fracture mode of all specimens was examined both visually and under stereomicroscope (Heerbrugg M3Z, Heerbrugg, Switzerland) at different magnifications (6.5 and 15x) and illumination angles. Fracture mode was classified into two categories according to the extension of the fracture line. A reparable fracture was defined as a fracture of the restoration with or without the fracture of the tooth structure that did not extend below the simulated bone level, while an irreparable fracture was defined as one that extended below the simulated bone level.

Representative fractured specimens were selected and examined by scanning electron microscopy (SEM) (JSM 5500, Jeol Ltd., Tokyo, Japan). Prior to observation, all the specimens were cleaned with alcohol and then coated with a gold layer using a sputter coater in vacuum evaporator (BAL-TEC SCD 050 Sputter Coater, Balzers, Liechtenstein). The analysis started at the upper, load-bearing part and progressed toward the inner surfaces.

Statistical analysis was performed in SPSS 26.0 (IBM, USA). Beside the descriptive analyses, ANOVA and factorial ANOVA were used. For the factorial ANOVA, bone level and

amputation were used as factors. The level of significance was  $p=0.01$  (corrected for multiple comparisons according to Bonferroni).

## Results

Figure 3 displays the boxplots of the fracture thresholds by study group. The results of the post-hoc pairwise comparisons (Tukey's HSD) are given in Table 1.

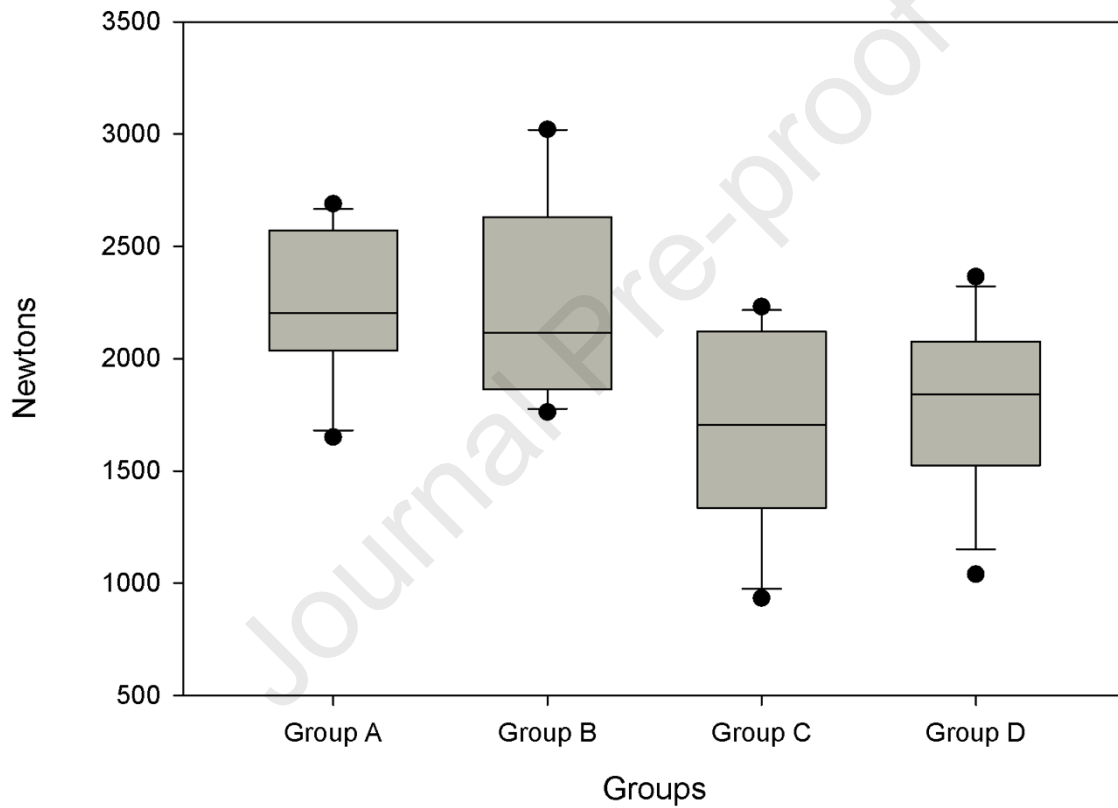


Figure 3. Boxplots of the fracture thresholds by study group.

Table 1. Results of the post-hoc pairwise comparisons (Tukey's HSD). Significant values are highlighted with red.


(I) Group	(J) Group	Mean Difference (I-J)	Std. Error	Sig.	95% Confidence Interval	
					Lower Bound	Upper Bound
Group A	Group B	.750	164.085	1.000	-437.36	438.86
	Group C	552.333*	164.085	.008	114.23	990.44
	Group D	459.667*	164.085	.036	21.56	897.77
Group B	Group A	-.750	164.085	1.000	-438.86	437.36
	Group C	551.583*	164.085	.008	113.48	989.69
	Group D	458.917*	164.085	.037	20.81	897.02
Group C	Group A	-552.333*	164.085	.008	-990.44	-114.23
	Group B	-551.583*	164.085	.008	-989.69	-113.48
	Group D	-92.667	164.085	.942	-530.77	345.44
Group D	Group A	-459.667*	164.085	.036	-897.77	-21.56
	Group B	-458.917*	164.085	.037	-897.02	-20.81
	Group C	92.667	164.085	.942	-345.44	530.77

\*. The mean difference is significant at the 0.05 level.

Groups without root amputation (Groups A and B) exhibited significantly higher fracture resistance than groups with root amputation (Groups C and D). Groups without root amputation (Groups A and B) did not show significant difference regarding fracture resistance from each other, irrespective of the degree of furcation involvement. The same applies for groups with root amputation (Groups C and D) when compared to each other. Therefore, the null hypothesis regarding fracture resistance was rejected. Factorial ANOVA was conducted with bone level and amputation as variable factors. The analysis indicated a significant effect for amputation ( $F= 18.99$ ,  $df=1$ ,  $p<0.001$ ), but neither the effect of bone level ( $p= 0.694$ ) nor the interaction of amputation and bone level was significant ( $p= 0.689$ ).

In terms of the fracture mode, groups with mild furcation involvement (Groups A and C) exhibited a reparable fracture mode more frequently ( $n=8$  &  $9$ , respectively) than groups (Groups B and D) with advanced/moderate furcation involvement ( $n=6$  &  $4$ , respectively). Therefore, the null hypothesis regarding fracture modes was also rejected.

Optical microscope and SEM images of the tested specimens showed that the crack path propagated from the loading surface (occlusally at connector area) to the inner part of composite restoration (Figure 4). Figure 4 A,B & C illustrate fracture propagation through the occlusal composite resin towards the fiber bundle splint and Figure 4D shows how fracture crack is stopped or redirected by fibers.



**Figure 4.** Stereomicroscopic (A) and SEM (B,C & D) images of a fractured specimen at different magnifications. Arrows (A,B & C) show fracture crack propagation from the load application area (connector) through composite resin towards the fiber bundle splint. Panel D clearly shows the fibers' ability to stop/redirect a crack.

## Discussion

The present study focused on the possible effect of root amputation and remaining bone level on the fracture resistance of splinted upper molar teeth. The goal of root amputation is to remove a root or roots of a multi-rooted molar tooth if the root cannot be treated due to endodontic and/or periodontal reasons. DeSanctis et al., summarized the periodontal indications of root

amputation as follows: moderate to advanced furcation involvement, severe bone loss affecting one or more root(s), severe recession or dehiscence of a root or unfavorable root proximity between adjacent teeth [21]. In our study, we modeled two situations with different degrees of furcation involvement and bone loss. It is well documented in the literature that, due to specific anatomical features, furcation involvement affects the upper molars three times more often than the lower ones [22]. Of the upper molars, the first molars [23] and their distal furcations are the most frequently affected [14,24,25]. Partly because of this, it has been previously shown that of all periodontally compromised teeth, maxillary molars are the most likely to be lost [26,27]. Therefore we chose to test maxillary molars.

In the present study, amputation of the DB root (Groups C and D) significantly reduced the fracture resistance of intracoronally splinted upper premolar-molar tooth pair units compared to non-amputated ones (Groups A and B). To our knowledge, this is the first study to show the effect of root amputation alone on the fracture resistance of periodontally involved, intracoronally splinted maxillary molar teeth under *in vitro* conditions. Furthermore, our results indicate that the amount of bony support does not play a major role in the fracture resistance of such teeth as the groups did not differ significantly when only the degree of furcation involvement was different (comparing Group A to Group B, and Group C to Group D). This was further confirmed by the factorial variance analysis, which revealed a significant effect for root amputation, but not for furcation involvement or the interaction of the two.

In a previous *in vitro* study [17], we examined how the level of periodontal support (modeling physiological conditions and furcation involvement) may impact the fracture resistance of root-amputated upper first molars that were restored by either a direct filling or an overlay.

To our knowledge, so far only we have dealt with the fracture resistance of root-amputated and/or furcation-involved teeth, so a direct comparison is possible only with our own studies. Regarding the amount of supporting bone, our current results contradict our previous findings where furcation involvement appeared as a significant factor in weakening root-amputated maxillary molars [17]. It is important to note that in the present study, splinted tooth pairs were tested, whereas previously we tested single upper molars, and this might well be the reason for the seemingly opposing results. Our current results also contradict the findings of Soares et al., as in their study the amount of bony support influenced the strain that developed in the splinted teeth [28]. However, it should be emphasized that Soares et al., examined lower front teeth, which could easily account for the difference in their results.

Regarding the fracture modes, mainly repairable fractures occurred in all groups, except for teeth with root amputation and advanced furcation involvement (Group D). This partly supports our previous results, according to which root-amputated furcation-involved teeth develop predominantly irreparable fractures [16,17]. Figure 4 shows clearly that the splinting fiber bundle has a reinforcing effect because it acts as a crack stopper. Many cracks started from the loading area and stopped at the fiber-composite interface. This could explain why all restorations survived fatigue loading. However, during static loading, a few cracks did pass the fibers and lead to failure. In terms of reinforcement, it is important to highlight the effect of the adhesion between the fiber bundle and the composite resin, and the position of the splinting fibers on the distribution of the occlusal forces. It has been shown that when the fiber bundle is applied to the occlusal third of the crown, it has all the benefits of occlusal splinting. That is, it works as an early stress-redirecting layer and its application results in a shorter working arm under loading [29].

In our study, premolar-molar tooth pairs were splinted with fiber-reinforced composite splinting. It is important to emphasize that root amputation alone does not necessarily indicate splinting [4]. Tooth mobility should also be considered when assessing the need for splinting in everyday practice. Klavan et al., found no difference in the survival rates of splinted and non-splinted, root-amputated upper first molar teeth, unless included in the anchorage of partial removable prosthesis [30]. Kumbuloglu et al., found good survival rates for periodontally involved teeth splinted with the same fiber-reinforced composite splint (everStick Perio) as we used in our study, however, they splinted lower front teeth [31]. Periodontal disease with bone loss and secondary furcation involvement is one of the most difficult-to-manage conditions in periodontology [11], reducing the 10- to 15-year survival rates by about 50% compared to non-furcation-affected teeth [32]. Root amputation has both advantages and disadvantages in such a situation. On the one hand, it provides better cleanability, but on the other hand, it has a significant impact on tooth stability and statics. The lifespan of teeth that have undergone root amputation has long been in the focus of research, but the results are diverse: some authors report survival rates above 90% [7,12,33-35], while others report significantly less favorable results of only 40-60% [36,37].

In the present *in vitro* study, we modeled a clinically relevant, common periodontal situation, when the upper first molar becomes the most distally located tooth in the upper quadrant, and the bone loss on the distal surface necessitates the amputation of the DB root. In this specific clinical situation, the molar tooth is always furcation-involved to a certain extent. Furcation-

involved molars are at a greater risk of further attachment loss than teeth without furcation involvement [5]. Furthermore, furcation involvement has been shown to be among the most serious deteriorating factors regarding the long-term prognosis of multi-rooted teeth [7]. In these clinical cases, it is important that the teeth that have become mobile (above a certain extent) should be stabilized in some way. Intracoronar splinting with FRC is one of the least invasive procedures that can be applied in the posterior zone in this clinical situation.

In this study, all specimens were pretested in an accelerated fatigue testing protocol under dynamic loading conditions. It is known that cyclic fatigue loading is a better model of the clinical situation than static loading, since cyclically applied forces act in a manner that is closer to what happens during normal mastication [38]. The accelerated fatigue protocol was introduced as a middle ground between the classic load-to-fracture test and the more sophisticated, but also time-consuming, fatigue tests [39-41]. As all specimens survived the pretesting phase, load-to-fracture testing was also carried out on all specimens. Static load-to-fracture testing simulates a sudden traumatic event, with greater forces or loading compared to normal chewing (e.g.: biting on a foreign object, stone, seed, etc.), which is usually a limitation compared to dynamic loading [42]. Therefore, combining the dynamic and static loading conditions in the same setup makes *in vitro* mechanical testing more reliable and more clinically realistic compared to static loading alone [43]. We would like to point out that, in our opinion, the static load-to-fracture test is almost mandatory in this specific situation as clinically mobile teeth are more prone to sudden fracture compared to their sound, periodontally intact counterparts [17,42]. Thus, we consider the application of both dynamic and static load-to-fracture tests a major strength of our study.

On the other hand, cyclic loading was not performed in a fluid chamber, and this weakens the comparability of our results to those of *in vivo* studies where saliva is always present during the loading cycles. This is a limitation should be addressed in future studies. Furthermore, the extracted teeth used in this study were not standardized according to their age but only according to their dimensions. Aging can alter the mechanical features of dentine, especially in the root canal. This is a known limitation of all current *in vitro* mechanical testing studies, which should be addressed in future. Finally, we would like to point out that the fact that our results are not comparable to independent studies (as studies in the simulation and mechanical testing of periodontally compromised teeth are absolutely lacking) is a clear limitation to the generalizability of our findings.

## Conclusions

Within the limitations of this study, it can be concluded that root amputation has a negative effect on the fracture resistance of furcation-involved, intracoronally splinted upper first molar and second premolar units. The degree of furcation involvement, as modeled in this study, does not seem to influence the fracture resistance of such units.

### **Compliance with Ethical Standards**

Conflict of Interest: Author Veronika T. Szabó, Balázs Szabó, Balázs Szabó P., Balázs Paczona, Csongor Mészáros, Gábor Braunitzer, Sufyan Garoushi and Márk Fráter declares that they have no conflict of interest.

Funding: This study was supported by the Bolyai János Research Scholarship (BO/701/20/5) and by and by the ÚNKP-21-5-SZTE New National Excellence Program of The Ministry for Innovation and Technology from the Source of National Research, Development and Innovation Fund, Hungary, and by the University of Szeged Open Access Fund (5623).

Ethical approval: This article does not contain any studies with human participants or animals performed by any of the authors.

Informed consent: For this type of study, formal consent is not required.



## References

1. Eke PI, Wei L, Borgnakke WS, Thornton-Evans G, Zhang X, Lu H, McGuire LC, Genco RJ. Periodontitis prevalence in adults  $\geq 65$  years of age, in the USA. *Periodontol* 2000. 2016 Oct;72(1):76-95. doi: 10.1111/prd.12145.
2. Eke PI, Dye BA, Wei L, Slade GD, Thornton-Evans GO, Borgnakke WS, Taylor GW, Page RC, Beck JD, Genco RJ. Update on Prevalence of Periodontitis in Adults in the United States: NHANES 2009 to 2012. *J Periodontol*. 2015 May;86(5):611-22. doi: 10.1902/jop.2015.140520.
3. Kurgan S, Terzioglu H, Yılmaz B. Stress distribution in reduced periodontal supporting tissues surrounding splinted teeth. *Int J Periodontics Restorative Dent*. 2014 Sep-Oct;34(5):e93-e101. doi: 10.11607/prd.1899.
4. Graetz C, Ostermann F, Woeste S, Sälzer S, Dörfer CE, Schwendicke F. Long-term survival and maintenance efforts of splinted teeth in periodontitis patients. *J Dent*. 2019 Jan;80:49-54. doi: 10.1016/j.jdent.2018.10.009
5. Dommisch H, Walter C, Dannewitz B, Eickholz P. Resective surgery for the treatment of furcation involvement: A systematic review. *J Clin Periodontol*. 2020 Jul;47 Suppl 22:375-391. doi: 10.1111/jcpe.13241.
6. American Academy of Periodontology. Glossary of Periodontal Terms. 4th ed. American Academy of Periodontology; Chicago, LA, USA: 2001. [(accessed on 2 November 2017)].
7. Derks H, Westheide D, Pfefferle T, Eickholz P, Dannewitz B. Retention of molars after root-resective therapy: a retrospective evaluation of up to 30 years. *Clin Oral Investig*. 2018 Apr;22(3):1327-1335. doi:10.1007/s00784-017-2220-1.

8. Salvi GE, Mischler DC, Schmidlin K, Matuliene G, Pjetursson BE, Brägger U, Lang NP. Risk factors associated with the longevity of multi-rooted teeth. Long-term outcomes after active and supportive periodontal therapy. *J Clin Periodontol*. 2014 Jul;41(7):701-7. doi: 10.1111/jcpe.12266.
9. Jepsen K, Dommisch E, Jepsen S, Dommisch H. Vital root resection in severely furcation-involved maxillary molars: Outcomes after up to 7 years. *J Clin Periodontol*. 2020 Aug;47(8):970-979. doi: 10.1111/jcpe.13306.
10. Hermann DW, Gher ME Jr, Dunlap RM, Pelleu GB Jr. The potential attachment area of the maxillary first molar. *J Periodontol*. 1983 Jul;54(7):431-4. doi:10.1902/jop.1983.54.7.431.
11. Walter C, Weiger R, Zitzmann NU. Periodontal surgery in furcation-involved maxillary molars revisited-an introduction of guidelines for comprehensive treatment. *Clin Oral Investig*. 2011 Feb;15(1):9-20. doi:10.1007/s00784-010-0431-9.
12. Schmitz JH, Granata S, Magheri P, Noè G. Single crowns on tooth root-resected molars: A retrospective multicentric study. *J Prosthet Dent*. 2020 Nov;124(5):547-553. doi: 10.1016/j.prosdent.2019.07.020.
13. Wang HL, Burgett FG, Shyr Y, Ramfjord S. The influence of molar furcation involvement and mobility on future clinical periodontal attachment loss. *J Periodontol*. 1994 Jan;65(1):25-9. doi: 10.1902/jop.1994.65.1.25.
14. Svärdström G, Wennström JL. Prevalence of furcation involvements in patients referred for periodontal treatment. *J Clin Periodontol*. 1996 Dec;23(12):1093-9. doi: 10.1111/j.1600-051x.1996.tb01809.x.
15. Gonçalves BC, Costa ALF, Correa R, Andere NMRB, Ogawa CM, Santamaria MP, de Castro Lopes SLP. Analysis of geometrical tomographic parameters of furcation lesions in periodontitis patients. *Heliyon*. 2021 Jan 30;7(1):e06119. doi:10.1016/j.heliyon.2021.e06119.

16. Szabó B, Eördegh G, Szabó P B, Fráter M. *in vitro* fracture resistance of root amputated molar teeth restored with overlay: a pilot study. *Fogorv Szle* 2017;111(4): 111-116. <https://doi.org/10.33891/FSZ.110.4.111-116>
17. Szabó B, Garoushi S, Braunitzer G, Szabó P B, Baráth Z, Fráter M. Fracture behavior of root-amputated teeth at different amount of periodontal support – a preliminary *in vitro* study. *BMC Oral Health*. 2019 Nov 27;19(1):261. doi:10.1186/s12903-019-0958-3.
18. Cara RR, Fleming GJ, Palin WM, Walmsley AD, Burke FJ. Cuspal deflection and microleakage in premolar teeth restored with resin-based composites with and without an intermediary flowable layer. *J Dent*. 2007 Jun;35(6):482-9. doi:10.1016/j.jdent.2007.01.005.
19. Fráter M, Sály T, Braunitzer G, Balázs Szabó P, Lassila L, Vallittu PK, Garoushi S. Fatigue failure of anterior teeth without ferrule restored with individualized fiber-reinforced post-core foundations. *J Mech Behav Biomed Mater*. 2021 Jun;118:104440. doi:10.1016/j.jmbbm.2021.104440.
20. Fráter M, Sály T, Vincze-Bandi E, Volom A, Braunitzer G, Szabó P B, Garoushi S, Forster A. Fracture Behavior of Short Fiber-Reinforced Direct Restorations in Large MOD Cavities. *Polymers (Basel)*. 2021 Jun 23;13(13):2040. doi:10.3390/polym13132040.
21. DeSanctis M, Murphy KG. The role of resective periodontal surgery in the treatment of furcation defects. *Periodontol* 2000. 2000 Feb;22:154-68. doi:10.1034/j.1600-0757.2000.2220110.x.
22. Ross IF, Thompson RH Jr. Furcation involvement in maxillary and mandibular molars. *J Periodontol*. 1980 Aug;51(8):450-4. doi: 10.1902/jop.1980.51.8.450.
23. Megarbane JM, Kassir AR, Mokbel N, Naaman N. Root Resection and Hemisection Revisited. Part II: A Retrospective Analysis of 195 Treated Patients with Up to 40 Years of Follow-up. *Int J Periodontics Restorative Dent*. 2018 Nov/Dec;38(6):783-789.

24. Al-Shammari KF, Kazor CE, Wang HL. Molar root anatomy and management of furcation defects. *J Clin Periodontol*. 2001 Aug;28(8):730-40. English, French, German. doi: 10.1034/j.1600-051x.2001.280803.x.
25. Majzoub Z, Kon S. Tooth morphology following root resection procedures in maxillary first molars. *J Periodontol*. 1992 Apr;63(4):290-6. doi:10.1902/jop.1992.63.4.290.
26. Hirschfeld L, Wasserman B. A long-term survey of tooth loss in 600 treated periodontal patients. *J Periodontol*. 1978 May;49(5):225-37. doi:10.1902/jop.1978.49.5.225.
27. McFall WT Jr. Tooth loss in 100 treated patients with periodontal disease. A long-term study. *J Periodontol*. 1982 Sep;53(9):539-49. doi:10.1902/jop.1982.53.9.539.
28. Soares PB, Fernandes Neto AJ, Magalhães D, Versluis A, Soares CJ. Effect of bone loss simulation and periodontal splinting on bone strain: Periodontal splints and bone strain. *Arch Oral Biol*. 2011 Nov;56(11):1373-81. doi:10.1016/j.archoralbio.2011.04.002.
29. Sáry T, Garoushi S, Braunitzer G, Alleman D, Volom A, Fráter M. Fracture behaviour of MOD restorations reinforced by various fibre-reinforced techniques - An in vitro study. *J Mech Behav Biomed Mater*. 2019 Oct;98:348-356. doi:10.1016/j.jmbbm.2019.07.006. Epub 2019 Jul 9. Erratum in: *J Mech Behav Biomed Mater*. 2020 Feb;102:103505.
30. Klavan B. Clinical observations following root amputation in maxillary molar teeth. *J Periodontol*. 1975 Jan;46(1):1-5. doi: 10.1902/jop.1975.46.1.1.
31. Kumbuloglu O, Saracoglu A, Ozcan M. Pilot study of unidirectional E-glass fibre-reinforced composite resin splints: up to 4.5-year clinical follow-up. *J Dent*. 2011 Dec;39(12):871-7. doi: 10.1016/j.jdent.2011.09.012.
32. Nibali L, Zavattini A, Nagata K, Di Iorio A, Lin GH, Needleman I, Donos N. Tooth loss in molars with and without furcation involvement - a systematic review and meta-analysis. *J Clin Periodontol*. 2016 Feb;43(2):156-66. doi:10.1111/jcpe.12497.

33. Carnevale G, Pontoriero R, di Febo G. Long-term effects of root-resective therapy in furcation-involved molars. A 10-year longitudinal study. *J Clin Periodontol.* 1998 Mar;25(3):209-14. doi: 10.1111/j.1600-051x.1998.tb02430.x.
34. Fugazzotto PA. A comparison of the success of root resected molars and molar position implants in function in a private practice: results of up to 15-plus years. *J Periodontol.* 2001 Aug;72(8):1113-23. doi: 10.1902/jop.2001.72.8.1113.
35. El Sayed N, Cosgarea R, Rahim S, Giess N, Krisam J, Kim TS. Patient-, tooth-, and dentist-related factors influencing long-term tooth retention after resective therapy in an academic setting-a retrospective study. *Clin Oral Investig.* 2020 Jul;24(7):2341-2349. doi: 10.1007/s00784-019-03091-9.
36. Langer B, Stein SD, Wagenberg B. An evaluation of root resections. A ten-year study. *J Periodontol.* 1981 Dec;52(12):719-22. doi: 10.1902/jop.1981.52.12.719.
37. Alassadi M, Qazi M, Ravidà A, Siqueira R, Garaicoa-Pazmiño C, Wang HL. Outcomes of root resection therapy up to 16.8 years: A retrospective study in an academic setting. *J Periodontol.* 2020 Apr;91(4):493-500. doi:10.1002/JPER.19-0033.
38. Battancs E, Fráter M, Sály T, Gál E, Braunitzer G, Szabó P B, Garoushi S. Fracture Behavior and Integrity of Different Direct Restorative Materials to Restore Noncarious Cervical Lesions. *Polymers (Basel).* 2021 Nov 29;13(23):4170. doi: 10.3390/polym13234170.
39. Magne P, Lazari PC, Carvalho MA, Johnson T, Del Bel Cury AA. Ferrule-Effect Dominates Over Use of a Fiber Post When Restoring Endodontically Treated Incisors: An In Vitro Study. *Oper Dent.* 2017 Jul/Aug;42(4):396-406. doi:10.2341/16-243-L.
40. Lazari PC, de Carvalho MA, Del Bel Cury AA, Magne P. Survival of extensively damaged endodontically treated incisors restored with different types of posts-and-core foundation restoration material. *J Prosthet Dent.* 2018 May;119(5):769-776. doi: 10.1016/j.prosdent.2017.05.012.

41. Magne P, Carvalho AO, Bruzi G, Anderson RE, Maia HP, Giannini M. Influence of no-ferrule and no-post buildup design on the fatigue resistance of endodontically treated molars restored with resin nanoceramic CAD/CAM crowns. *Oper Dent*. 2014 Nov-Dec;39(6):595-602. doi: 10.2341/13-004-L.

42. Szabó P B, Sály T, Szabó B. The key elements of conducting load to fracture mechanical testing on restoration-tooth units in restorative dentistry. *Analecta Technica Szegedinensia* 2019; 13: 2. doi: 10.14232/analecta.2019.2.59-64

43. T Szabó V, Szabó B, Tarjányi T, Trenyik Sz E, Szabó P B, Fráter M. Analog and digital modelling of sound and impaired periodontal supporting tissues during mechanical testing. *Analecta Technica Szegedinensia* 2021; 15: 2. doi: 10.14232/analecta.2021.2.84-97

### Declaration of interests

The authors declare that they have no known competing financial interests or personal relationships that could have appeared to influence the work reported in this paper.

Author Veronika T. Szabó declares that they have no conflict of interest.

Author Balázs Szabó declares that they have no conflict of interest.

Author Balázs Szabó P declares that they have no conflict of interest.

Author Balázs Paczona declares that they have no conflict of interest

Author Csongor Mészáros declares that they have no conflict of interest.

Author Gábor Braunitzer declares that they have no conflict of interest.

Author Sufyan Garoushi declares that they have no conflict of interest.

Author Márk Fráter declares that they have no conflict of interest.