




Contents lists available at ScienceDirect

Journal of Cranio-Maxillo-Facial Surgery

journal homepage: www.jcmfs.com

Vertical mandibular bone augmentation by the osteodistraction of the transplanted fibula free flap: A case series with long-term follow-up

Tamás Sass ^{a, b, *}, József Piffkó ^c, Ferenc Oberna ^d

^a Bács-Kiskun County Hospital, Teaching Hospital of the University of Szeged, Department of Oral and Maxillofacial Surgery and Otolaryngology, Nyíri út 38, Kecskemét, Hungary

^b Doctoral School of Clinical Medicine, University of Szeged, Kálvária Sugárút 57, Szeged, Hungary

^c Department of Oral and Maxillofacial Surgery, Faculty of Medicine, University of Szeged, Kálvária Sugárút 57, Szeged, Hungary

^d Multidisciplinary Head and Neck Cancer Center, National Institute of Oncology, Ráth György Utca 7-9, Budapest, Hungary



ARTICLE INFO

Article history:

Paper received 5 February 2021

Received in revised form

6 June 2021

Accepted 20 June 2021

Available online 23 June 2021

Keywords:

Free fibula flap

Osteodistraction

Large mandible defect

Vertical bone augmentation

Implant-retained prosthetic rehabilitation

ABSTRACT

Vertical augmentation of the mandible to prepare dental implant therapy is still a challenge, especially with large mandible defects. Reconstruction with fibula free flap is a regularly applied approach in such cases, but it does not always yield optimal results: the resulting crestal height might differ significantly from the crestal height of the patient's intact bone, which makes esthetic and functional rehabilitation difficult. Osteodistraction of the integrated flap is a known but rarely discussed approach where the already integrated flap undergoes additional distraction. Through the four cases reported here, we would like to demonstrate that the osteodistraction of the transplanted fibula free flap is a useful and efficient method of secondary augmentation for cases where the flap itself fails to produce the desired crestal height, and no other method is applicable. The cases show that the method allows outcomes that are highly satisfactory, both in the functional and esthetic sense.

© 2021 The Authors. Published by Elsevier Ltd on behalf of European Association for Cranio-Maxillo-Facial Surgery. This is an open access article under the CC BY license (<http://creativecommons.org/licenses/by/4.0/>).

1. Introduction

Surgical rehabilitation of the atrophic alveolar ridge is often necessary prior to dental implant placement. GTR (guided tissue regeneration) procedures used for lateral bone ridge augmentation provide excellent results with minimal risks. The same is not true for the vertical dimension. This is so because it is challenging to achieve tension-free suturing and the stability of the graft material is unpredictable over time (Jensen et al., 1995; Simon et al., 2000; Sheikh et al., 2015). Osteodistraction is an approach to vertical augmentation without these difficulties (Natu et al., 2014). As the osteotomized bone segments are slowly pulled apart, the intact soft tissue provides an ideal environment for the formation of new bone. As the circulation of the osteotomized segments is partially maintained via the periosteum, less bone volume is lost than with GTR. A further advantage is that the expansion of the surrounding

soft tissues is proportional to bone growth (Ilizarov, 1989b, a; Suhr et al., 2004). A major disadvantage of osteodistraction, however, is that it is time-consuming and may be uncomfortable to the patient.

In our clinical practice, fibula free flaps are used to reconstruct extensive mandibular hard- and soft tissue composite defects, as they allow the reconstruction of even an entire mandible if necessary (Flemming et al., 1990; Hidalgo and Rekow, 1995; Bahr et al., 1998; Wei et al., 1999). Major advantages of fibula free flap include that it provides a long vascular pedicle, and that the diameter of the artery and veins surrounding the fibula correspond with the diameter of the arteries and veins in the neck region. The main disadvantage is that the vertical height of the harvested bone (1.3–2.3 cm) and that of the patient's mandible may differ considerably, especially in younger patients (Disa et al., 1997; Ferri et al., 1997). Such cases necessitate secondary vertical augmentation.

Annually, an average of 15 mandible reconstruction surgeries are performed in our practice with the fibula free flap approach. Approximately every other patient receives full mouth rehabilitation with implant-retained restorations following mandibular reconstruction. In this case series, four cases are presented. In all 4 cases, there was a large difference in the vertical height between

* Corresponding author. Bács-Kiskun County Hospital, Teaching Hospital of the University of Szeged, Department of Oral and Maxillofacial Surgery and Otolaryngology, Nyíri út 38, Kecskemét, Hungary.

E-mail address: t.sass@yahoo.com (T. Sass).

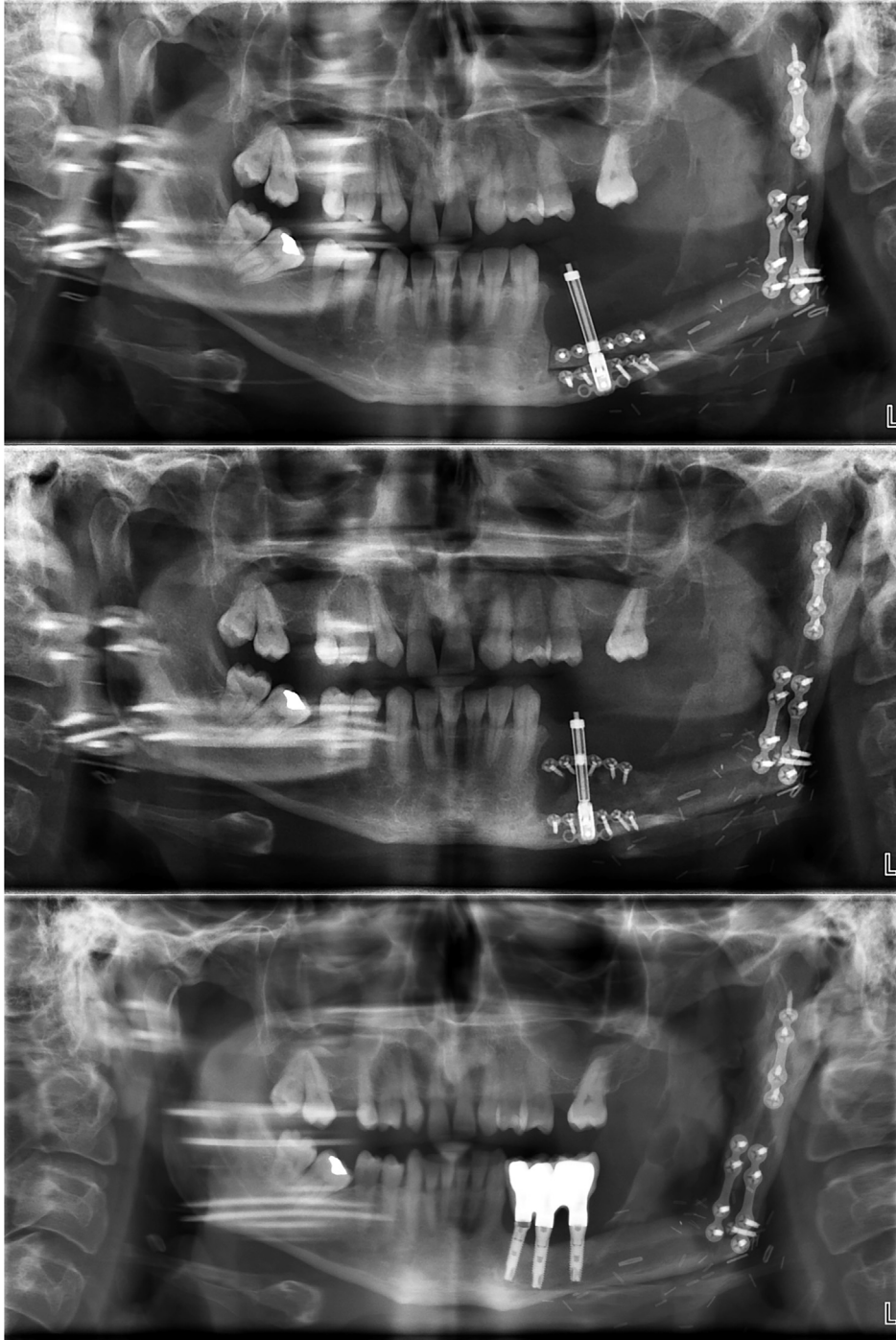


Fig. 1. Case 1. Panoramic x-ray images. Top: at the beginning of osteodistraction; Middle: at the end of osteodistraction; Bottom: at the 8-year follow-up.

the patient's healthy mandible and the bony segment of the vascularized fibula flap, which necessitated vertical augmentation prior to implant placement to achieve satisfactory prosthetic results. In all the presented cases, the reconstructed mandibular segment was longer than 11 cm. Therefore, the duplication of the

fibula free flap, the “double barrel technique” was not possible at the time of the primary surgery (Bahr et al., 1998), and another approach had to be found to restore the vertical dimension. To reach that end, distraction of the fibula flap was performed.

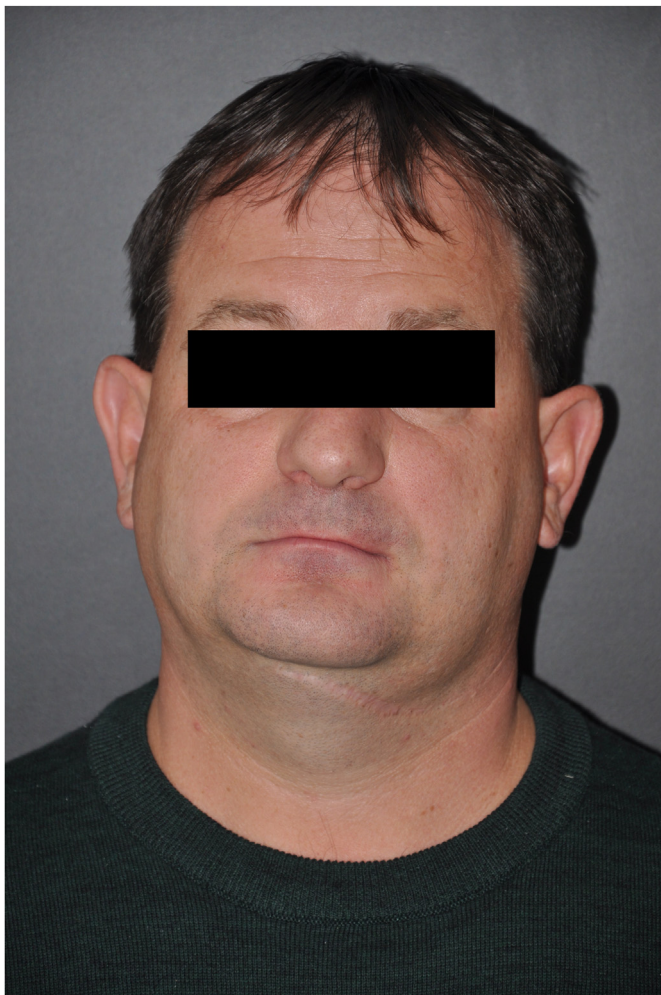

Fig. 2. Case 1. Clinical presentation at the 8-year follow-up.

The various methods of vertical augmentation of the alveolar ridge for the purpose of dental rehabilitation, including osteodistraction of the fibula free flap, are well documented in the literature (Nocini et al., 2000; Klesper et al., 2002; Saulacic et al., 2008; Wang et al., 2015; Saito et al., 2018). Long-term reports with both hard- and soft tissue outcomes, however, are scarce in the literature. Sometimes the cases are not followed up (Nocini et al., 2000; Xingzhou et al., 2020), or if they are, the usual follow-up period is typically 2–3 years, but no longer than 5 years (Klesper et al., 2002; Ortakoglu et al., 2006; Cheung et al., 2011; Wang et al., 2015). It is also often a problem that the management of the soft tissues is not documented to a satisfactory degree and/or the condition of the soft tissues is not followed up. The retrospective study of Wang and colleagues is a welcome exception, but again, with a relatively short follow-up period (Wang et al., 2015). This case series includes cases with 7 and 8 years of follow-up. Our aim was to analyze these cases in terms of long-term function and esthetics, considering the condition of both the hard and soft tissues.

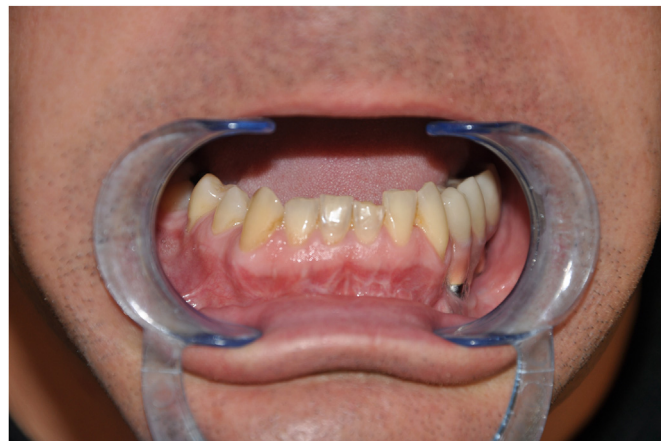

Fig. 3. Case 1. The dental work and its surroundings at the 8-year follow-up.

2. Case report

2.1. Ethical approval

Ethical approval to report these cases was obtained from the Institutional Research Ethics Committee of the Bács-Kiskun County Hospital (No. 2/20.09.02.). Written informed consent was obtained from all four patients for their anonymized information and images to be published in this article.

2.2. Treatment

Osteodistraction of the fibula flap was always performed as the first step of rehabilitation, one year after the reconstructive surgery or the last radiation therapy session (where radiotherapy was applied). An intraoral incision was made at the junction of the alveolar ridge and the buccal vestibule taking extreme care to keep the lingual and ridge periosteum intact. The osteotomies were carried out using a piezoelectric system, and following the placement of the distraction device its correct function and movement were monitored until removal. The patients then received a course of antibiotics for 7 days (amoxicillin and clavulanic acid, 1000 mg, per os). 10 days after the surgery, the activation of the distraction device was initiated, and the patients were instructed to activate the device twice a day, resulting in vertical expansion at the rate of 1 mm/day. The activation period was followed by a 3-month consolidation period without the distraction device. Prosthetic rehabilitation was the last stage of treatment. All patients received implant-retained fixed prosthetics.

2.3. Case 1

The mandible defect of this 34-year-old male patient arose as the result of multiple surgeries to treat a large keratocyst on the left side of his mandible. Segmental mandible resection with fibula free flap reconstruction was performed. The reconstruction was successful, but there was a marked difference in the vertical height between the reconstructed and the intact sides, which could have interfered with the success of the prosthetic treatment. To increase the vertical height of the reconstructed segment, osteodistraction

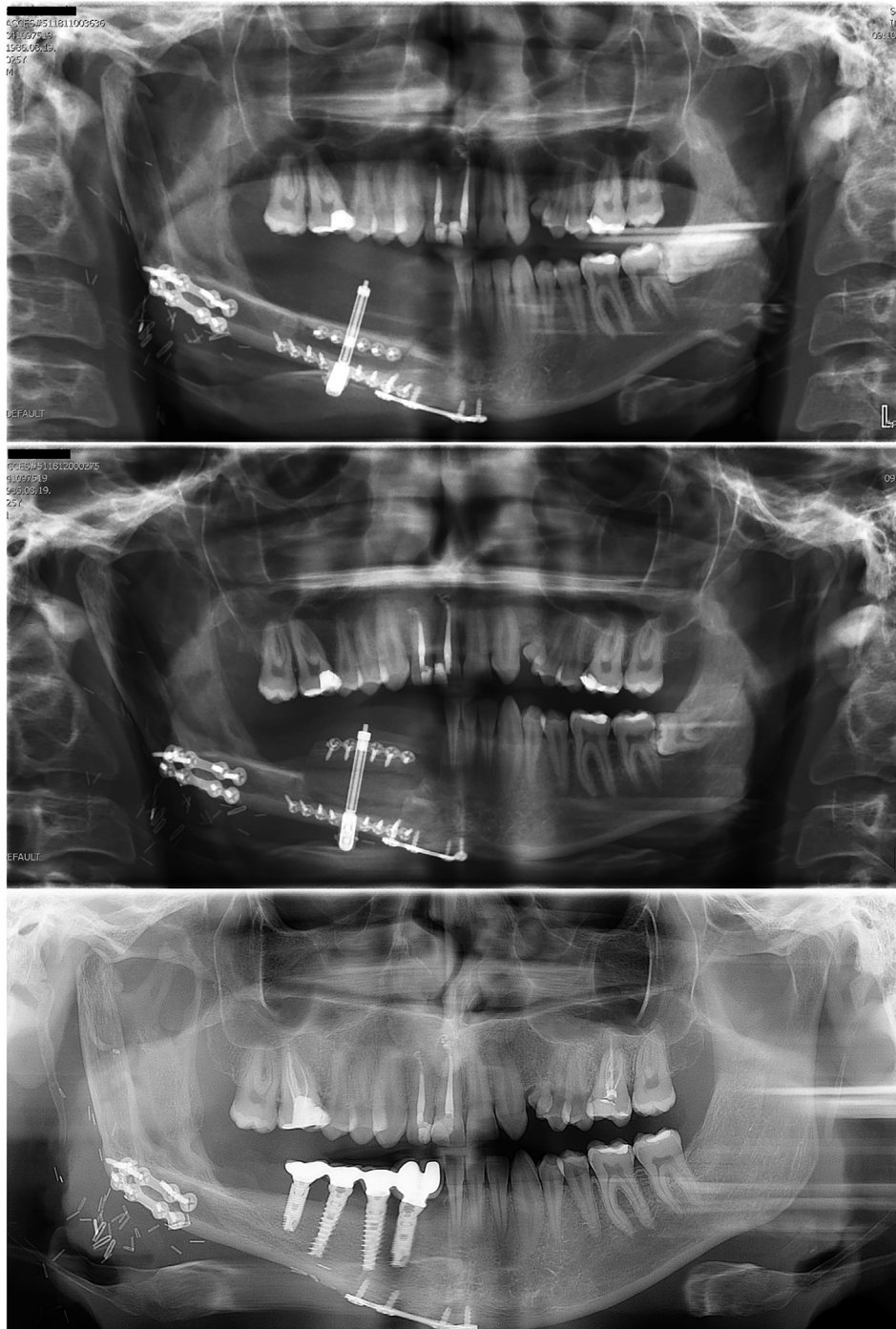


Fig. 4. Case 2. Panoramic x-ray images. Top: at the beginning of osteodistraction; Middle: at the end of osteodistraction; Bottom: at the 1-year follow-up.



Fig. 5. Case 2. Clinical presentation at the 1-year follow-up.

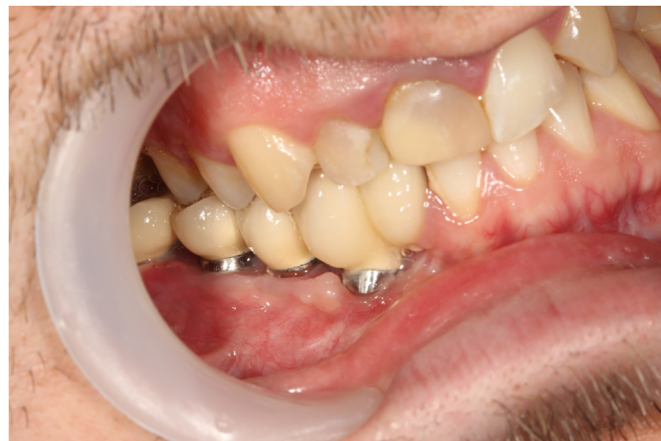

Fig. 6. Case 2. The dental work and its surroundings at the 1-year follow-up.

of the fibula flap was performed in the premolar-molar region. This way, 10 mm vertical augmentation was achieved (Fig. 1 top and middle). Following the removal of the distraction device, it was found that the width of the anterior part of the augmented bone tissue was insufficient for implant therapy, therefore lateral augmentation was necessary. For that purpose, guided tissue regeneration was performed, using resorbable collagen membrane and a mixture of autogenic (intraoral) and xenogenic grafting material. When the osseointegration of the lateral augmentation was confirmed, 3 dental implants were placed, which successfully integrated 3 months after their placement. At the time of the exposure of the implants, free palatal autograft was used for augmentation around the implants to improve aesthetics. The patient received fixed dental restoration a month later. The patient has been followed up for 8 years (Fig. 1 bottom, Figs. 2 and 3).

2.4. Case 2

Similar to Case 1, this 23-year-old male patient underwent multiple surgeries to remove a keratocyst located on the right side of the mandible. The course of his therapy was also quite similar. The definitive treatment was segmental resection of the right side of the mandible, followed by microsurgical reconstruction with fibula free flap. The outcome was fine in the surgical sense, but again, there was a marked difference in the vertical dimension between the reconstructed and the intact sides. To correct this, osteodistraction of the fibula flap from the canine to the molar region was performed, and 12 mm vertical augmentation was achieved (Fig. 4 top and middle). When the distracting device was removed, the same problem was seen as in Case 1: the horizontal bone volume in the anterior region of the reconstructed segment was insufficient for implantation, so the treatment continued with lateral augmentation of this region. The procedure was the same as in Case 1. When integration was verified, 4 dental implants were placed, which successfully integrated by the 3rd month after placement. At the time of the exposure of the implants, free palatal autograft was used for augmentation around the implants to improve aesthetics. The patient received fixed dental restoration on the implants one month later. The patient has been followed up for 1 year now (Fig. 4 bottom, Figs. 5 and 6).

2.5. Case 3

The 27-year-old female patient underwent partial mandible resection as definitive surgical treatment for ameloblastoma infiltrating the intraoral soft tissues. Reconstruction was carried out using fibula free flap with skin pedicle on the left side of the mandible, in the premolar-molar region. Height difference between the reconstructed segment and the patient's own remaining bone necessitated vertical augmentation of the fibula flap with an alveolar distractor. 10 mm vertical augmentation was achieved (Fig. 7 top and middle). After bone healing, the device was removed, and the patient received 3 implants in the treated area immediately. When osseointegration was verified, the implants were exposed, and the patient received a fixed dental restoration. Peri-implant soft tissue management was done by thinning the subcutaneous fat of the skin pedicle of the flap, so no additional grafting was necessary. The patient has been followed up for 4 years (Fig. 7 bottom, Figs. 8 and 9).

2.6. Case 4

The 42-year-old male patient was diagnosed with malignant fibrous histiocytoma of the mandible, and he underwent hemimandibulectomy followed by fibula free flap reconstruction. He received radiotherapy after the reconstructive surgery. It was obvious that the height difference between the reconstructed part and the patient's own bone would need to be corrected, but it could not happen earlier than one year after the last exposure to radiation. The alveolar distraction device was placed 12 months after the last radiotherapy session. Five days after activation, though, the surrounding soft tissues swelled up and the patient complained of pain, which raised the possibility of infection. The distraction process was halted immediately (with the device in place) and antibiotic therapy was initiated (Amoxicillin + clavulanic acid, 1000 mg, twice a day for 7 days). As expected, the symptoms resolved, and it was possible to continue the distraction 14 days later. 10mm vertical augmentation was achieved (Fig. 10 top and middle). 6 months after the removal of the device, the patient received 3 implants in the treatment area. Peri-implant soft tissue management was done with keratinized tissue harvested from the patient's

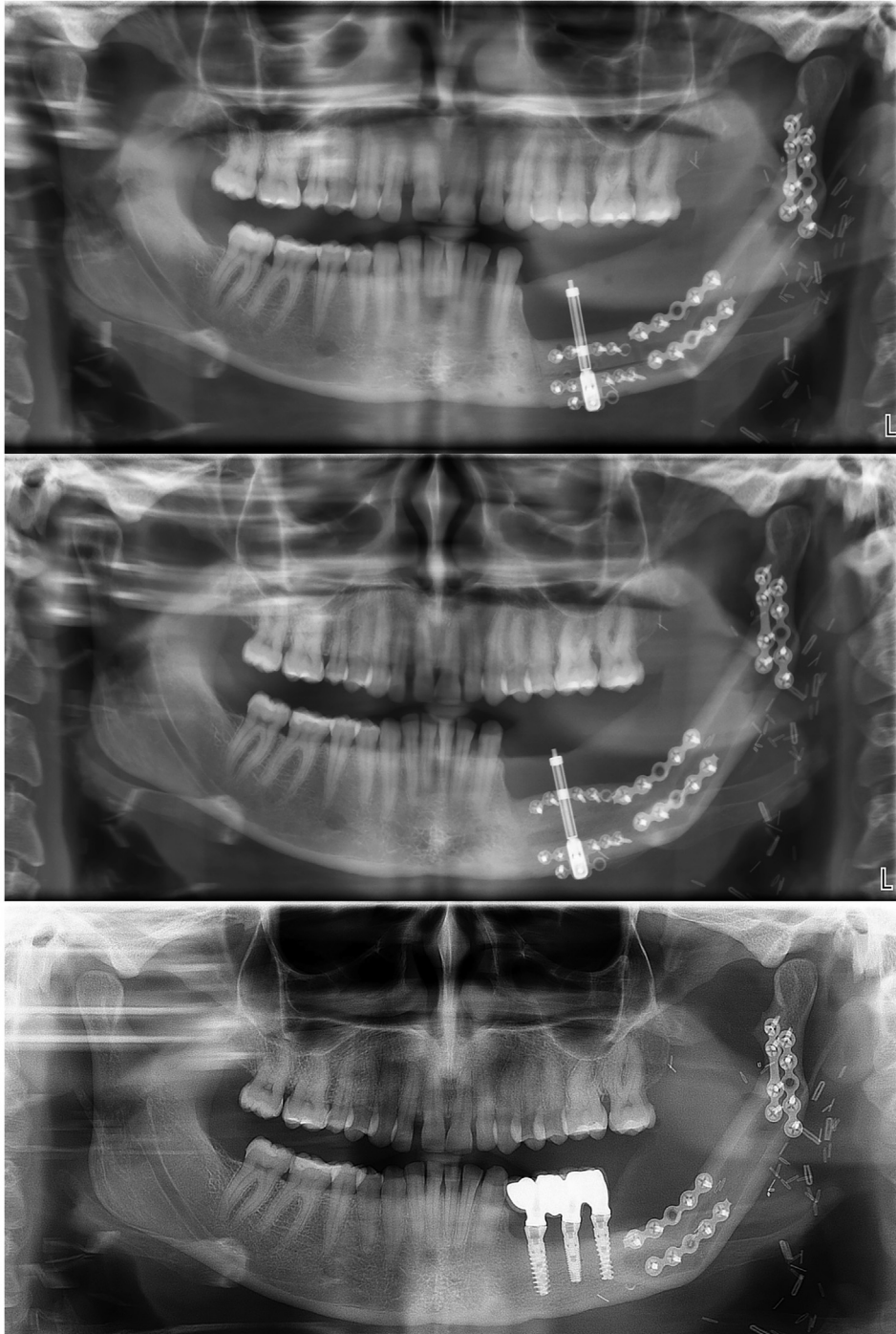


Fig. 7. Case 3. Panoramic x-ray images. Top: at the beginning of osteodistraction; Middle: at the end of osteodistraction; Bottom: at the 4-year follow-up.

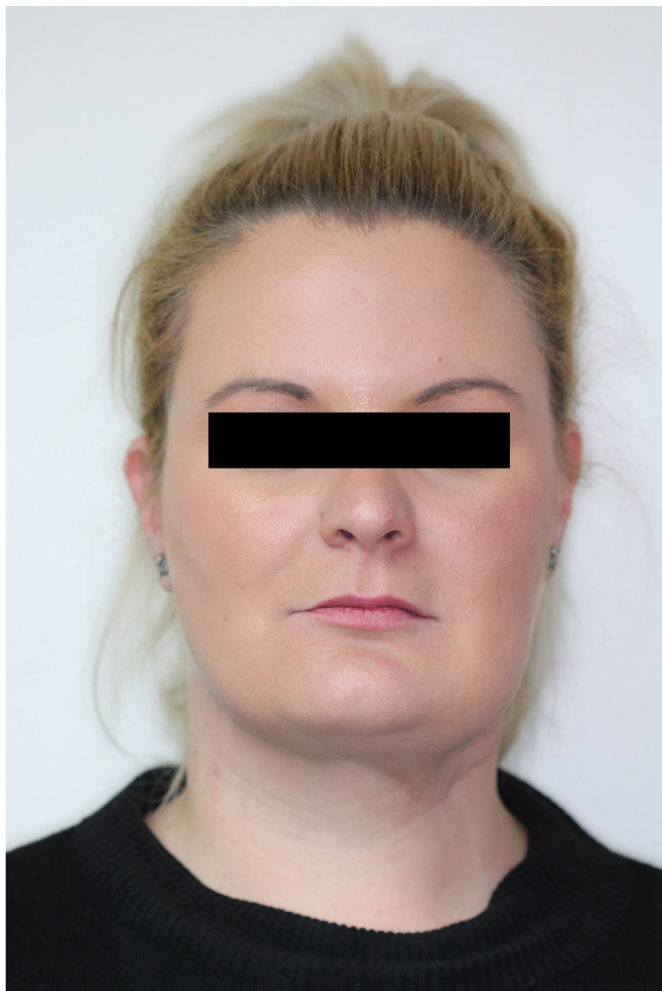

Fig. 8. Case 3. Clinical presentation at the 4-year follow-up.

own palate. As the last step of the prosthetic treatment, the patient received a fixed dental restoration. The patient has been followed up for 7 years now (Fig. 10 bottom, Figs. 11 and 12).

3. Discussion

In this case series, we reported on the short-, medium- and long-term follow-up of patients having undergone osteodistraction of the fibula flap as a secondary intervention to restore crestal height and allow implant therapy. To our knowledge, we are the first to report such cases with a follow-up period longer than 5 years. In all four cases, osteodistraction of the fibula flap combined with implant therapy was successfully applied to correct the mandible defect and rehabilitate the patients both functionally and esthetically. No bone loss (as evidenced by OPT scans) or peri-implant soft tissue inflammation was observed in any of the patients during the follow-up. The esthetic aspect is especially important in these cases, as for these relatively young patients (all under 50, with a mean age of 31.5 years) good esthetics can be a major determinant of psychosocial well-being.

There are multiple surgical options available for the reconstruction of composite oral and maxillofacial defects (Torrioni et al., 2015; Yao et al., 2020). The most commonly used donor sites include the iliac crest, the radial forearm, the scapula and the fibula

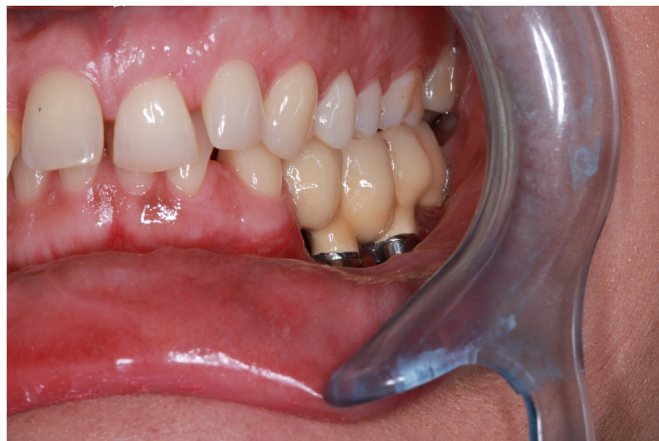

Fig. 9. Case 3. The dental work and its surroundings at the 4-year follow-up.

(Disa et al., 2000; Valentini et al., 2009; Myeroff et al., 2011; Lodders et al., 2021). The radial free flap has the advantage of a long vascular pedicle, but its clinical vertical bone gain is expected to be only 4–6mm. A further disadvantage is the risk of radial fracture, because of which it is strongly advised to perform titanium plate osteosynthesis as a preventive measure (Militsakh et al., 2005; Loeffelbein et al., 2012). The iliac donor site is especially popular because of the amount of transplantable bone it offers (Myeroff et al., 2011). Popular as it may be, it does not come without drawbacks: the vascular pedicle is normally much shorter than optimal, the complications may be severe as compared to the fibular donor site (Huemer et al., 2004), and the bone volume is characterized by a higher reduction rate (Ritschl et al., 2020). The scapular free flap carries fewer risks, but the vascular pedicle is usually short and sometimes requires venous interpositional grafting. Furthermore, the harvestable bone is only monocortical, and bone quantity is poor compared to the fibula (Lanzer et al., 2015).

The fibula free flap has numerous advantages. Most importantly, the bone gain may be as much as 1–2 cm, which may be amplified up to 4 cm with the double barrel technique (Bahr et al., 1998). However, the technique is of limited use for long defects (approximately >10 cm in the antero-posterior dimension), as the length of the vascular pedicle allows no more. Weighing the disadvantages against the advantages, the fibula free flap may still be considered the best approach to large mandible defects, because it allows the harvesting of bicortical bone, the restorable length and achievable shape is still excellent as compared to the other techniques, and the complication profile of this technique is the most acceptable when compared against that of other microvascular composite flaps (Attia et al., 2019; Awad et al., 2019; Modabber et al., 2019; Dean et al., 2020). There are some cases where the height of the reconstructed bone tissue and the vertical dimension of the mandible differ significantly and therefore secondary vertical augmentation is necessary to reduce the height difference. If the difference is > 6 mm, GTR is not safe, due to the increased risk of wound opening and resorption.

In such cases, osteodistraction of the flap is still an option. It is free of the risks of GTR, and it allows considerable bone gain (Cope et al., 2000; Ow et al., 2008; Andrade et al., 2011), therefore a closer to optimal implant-to-crown ratio may be achieved - a key factor of proper function over a long period of time. Peri-implant soft tissues can also be managed a lot easier with this approach, which reduces the risk of periimplantitis (Lodders et al., 2021). On the negative side, it is time-consuming and may be uncomfortable for the

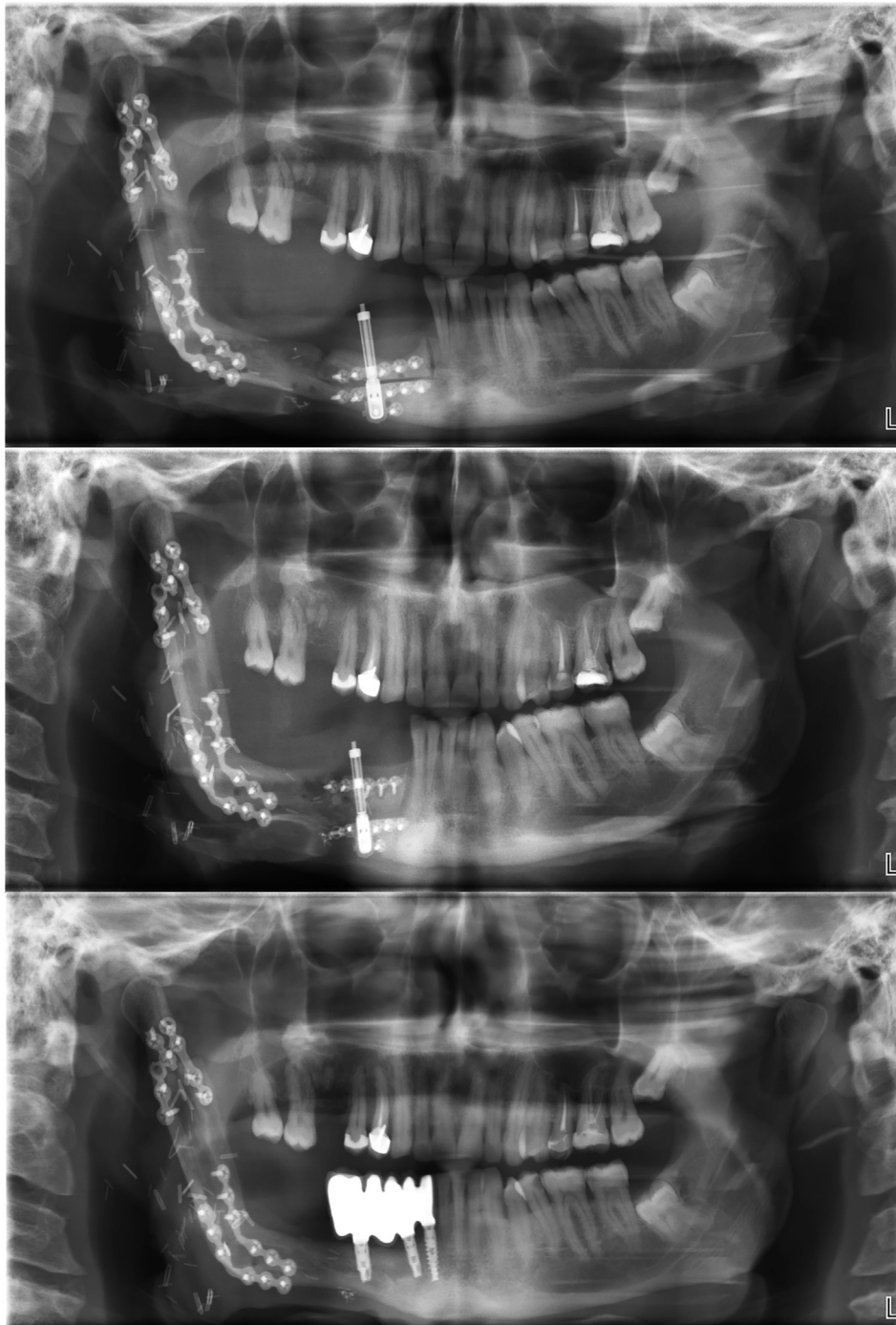


Fig. 10. Case 4. Panoramic x-ray images. Top: at the beginning of osteodistraction; Middle: at the end of osteodistraction; Bottom: at the 7-year follow-up.



Fig. 11. Case 4. Clinical presentation at the 7-year follow-up.

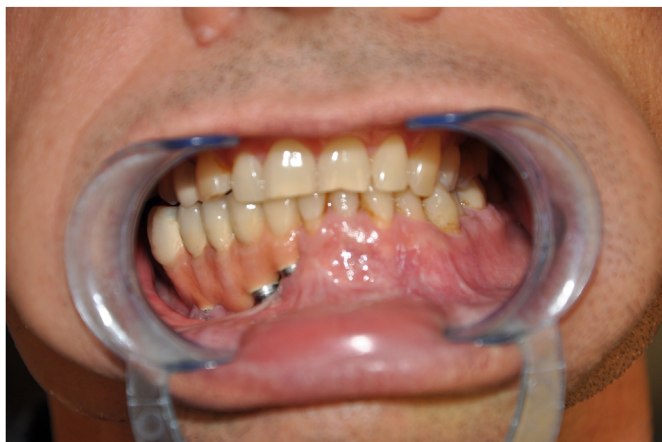

Fig. 12. Case 4. The dental work and its surroundings at the 7-year follow-up.

patient. Still, it is a very predictable and efficient procedure, as evidenced by the presented cases. Even patients having undergone radiotherapy are eligible for this procedure (as seen in Case 4), but such patients must be assessed and monitored with extreme care.

4. Conclusions

The outcomes suggest that in the case of large mandible defects, fibula free flap with secondary distraction of the flap is a safe and reliable approach to the surgical rehabilitation of the atrophic alveolar ridge prior to dental implant therapy. In all cases, the method yielded lastingly favorable outcomes, both functionally and esthetically.

Funding statement

This research did not receive any specific grant from funding agencies in the public, commercial, or not-for-profit sectors.

Declaration of competing interest

The authors declare no conflict of interest.

References

- Andrade, N., Gandhewar, T., Kalra, R., 2011. Development and evolution of distraction devices: use of indigenous appliances for Distraction Osteogenesis-An overview. *Ann Maxillofac Surg* 1, 58–65.
- Attia, S., Wiltfang, J., Streckbein, P., Wilbrand, J.F., El Khassawna, T., Mausbach, K., Howaldt, H.P., Schaaf, H., 2019. Functional and aesthetic treatment outcomes after immediate jaw reconstruction using a fibula flap and dental implants. *J. Cranio-Maxillo-Fac. Surg.* 47, 786–791.
- Awad, M.E., Altman, A., Elrefai, R., Shipman, P., Looney, S., Elsalanty, M., 2019. The use of vascularized fibula flap in mandibular reconstruction; A comprehensive systematic review and meta-analysis of the observational studies. *J. Cranio-Maxillo-Fac. Surg.* 47, 629–641.
- Bahr, W., Stoll, P., Wachter, R., 1998. Use of the "double barrel" free vascularized fibula in mandibular reconstruction. *J. Oral Maxillofac. Surg.* 56, 38–44.
- Cheung, L.K., Hariri, F., Chua, H.D., 2011. Alveolar distraction osteogenesis for oral rehabilitation in reconstructed jaws. *Curr. Opin. Otolaryngol. Head Neck Surg.* 19, 312–316.
- Cope, J.B., Samchukov, M.L., 2000. Regenerate bone formation and remodeling during mandibular osteodistraction. *Angle Orthod.* 70, 99–111.
- Dean, A., Alamillos, F., Heredero, S., Redondo-Camacho, A., Guler, I., Sanjuan, A., 2020. Fibula free flap in maxillomandibular reconstruction. Factors related to osteosynthesis plates' complications. *J. Cranio-Maxillo-Fac. Surg.* 48, 994–1003.
- Disa, J.J., Cordeiro, P.G., 2000. Mandible reconstruction with microvascular surgery. *Semin. Surg. Oncol.* 19, 226–234.
- Disa, J.J., Winters, R.M., Hidalgo, D.A., 1997. Long-term evaluation of bone mass in free fibula flap mandible reconstruction. *Am. J. Surg.* 174, 503–506.
- Ferri, J., Piot, B., Ruhin, B., Mercier, J., 1997. Advantages and limitations of the fibula free flap in mandibular reconstruction. *J. Oral Maxillofac. Surg.* 55, 440–448 discussion 448–449.
- Flemming, A.F., Brough, M.D., Evans, N.D., Grant, H.R., Harris, M., James, D.R., Lawlor, M., Laws, I.M., 1990. Mandibular reconstruction using vascularised fibula. *Br. J. Plast. Surg.* 43, 403–409.
- Hidalgo, D.A., Rekow, A., 1995. A review of 60 consecutive fibula free flap mandible reconstructions. *Plast. Reconstr. Surg.* 96, 585–596 discussion 597–602.
- Huemer, G.M., Puelacher, W., Schoeller, T., 2004. Improving the iliac crest donor site by plate insertion after harvesting vascularized bone. *J. Cranio-Maxillo-Fac. Surg.* 32, 387–390.
- Ilizarov, G.A., 1989a. The tension-stress effect on the genesis and growth of tissues. Part I. The influence of stability of fixation and soft-tissue preservation. *Clin. Orthop. Relat. Res.* 249–281.
- Ilizarov, G.A., 1989b. The tension-stress effect on the genesis and growth of tissues: Part II. The influence of the rate and frequency of distraction. *Clin. Orthop. Relat. Res.* 263–285.
- Jensen, O.T., Greer Jr., R.O., Johnson, L., Kassebaum, D., 1995. Vertical guided bone-graft augmentation in a new canine mandibular model. *Int. J. Oral Maxillofac. Implants* 10, 335–344.
- Klesper, B., Lazar, F., Siessegger, M., Hidding, J., Zoller, J.E., 2002. Vertical distraction osteogenesis of fibula transplants for mandibular reconstruction—a preliminary study. *J. Cranio-Maxillo-Fac. Surg.* 30, 280–285.
- Lanzer, M., Gander, T., Gratz, K., Rostetter, C., Zweifel, D., Bredell, M., 2015. Scapular free vascularised bone flaps for mandibular reconstruction: are dental implants possible? *J. Oral Maxillofac. Res.* 6 (e4).
- Lodders, J.N., Leusink, F.K.J., Ridwan-Pramana, A., Winters, H.A.H., Karagozoglu, K.H., Dekker, H., Forouzanfar, T., Schulten, E., 2021. Long-term outcomes of implant-based dental rehabilitation in head and neck cancer patients after reconstruction with the free vascularized fibula flap. *J. Cranio-Maxillo-Fac. Surg.* <https://doi.org/10.1016/j.jcms.2021.03.002>. S1010-5182(21)00101-3, Online ahead of print.

- Loeffelbein, D.J., Al-Benna, S., Steinstrasser, L., Satanovskij, R.M., Rohleder, N.H., Mucke, T., Wolff, K.D., Kesting, M.R., 2012. Reduction of donor site morbidity of free radial forearm flaps: what level of evidence is available? *Eplasty* 12 e9.
- Militsakh, O.N., Werle, A., Mohyuddin, N., Toby, E.B., Kriet, J.D., Wallace, D.I., Girod, D.A., Tsue, T.T., 2005. Comparison of radial forearm with fibula and scapula osteocutaneous free flaps for oromandibular reconstruction. *Arch. Otolaryngol. Head Neck Surg.* 131, 571–575.
- Modabber, A., Rauen, A., Ayoub, N., Möhlhenrich, S.C., Peters, F., Kniha, K., Hölzle, F., Raith, S., 2019. Evaluation of a novel algorithm for automating virtual surgical planning in mandibular reconstruction using fibula flaps. *J. Cranio-Maxillo-Fac. Surg.* 47, 1378–1386.
- Myeroff, C., Archdeacon, M., 2011. Autogenous bone graft: donor sites and techniques. *J. Bone Joint Surg. Am* 93, 2227–2236.
- Natu, S.S., Ali, I., Alam, S., Giri, K.Y., Agarwal, A., Kulkarni, V.A., 2014. The biology of distraction osteogenesis for correction of mandibular and craniomaxillofacial defects: a review. *Dent. Res. J.* 11, 16–26.
- Nocini, P.F., Wangerin, K., Albanese, M., Kretschmer, W., Cortelazzi, R., 2000. Vertical distraction of a free vascularized fibula flap in a reconstructed hemimandible: case report. *J. Cranio-Maxillo-Fac. Surg.* 28, 20–24.
- Ortakoglu, K., Suer, B.T., Ozyigit, A., Ozen, T., Sencimen, M., 2006. Vertical distraction osteogenesis of fibula transplant for mandibular reconstruction: a case report. *Oral Surg. Oral Med. Oral Pathol. Oral Radiol. Endod.* 102, e8–11.
- Ow, A.T., Cheung, L.K., 2008. Meta-analysis of mandibular distraction osteogenesis: clinical applications and functional outcomes. *Plast. Reconstr. Surg.* 121, 54e–69e.
- Ritschl, L.M., Fichter, A.M., Grill, F.D., Hart, D., Hapfelmeier, A., Deppe, H., Hedderich, D.M., Wolff, K.D., Mucke, T., 2020. Bone volume change following vascularized free bone flap reconstruction of the mandible. *J. Cranio-Maxillo-Fac. Surg.* 48, 859–867.
- Saito, N., Funayama, A., Arai, Y., Suda, D., Takata, Y., Kobayashi, T., 2018. Vertical distraction osteogenesis of a reconstructed mandible with a free vascularized fibula flap: a report of two cases. *Maxillofac. Plast. Reconstr. Surg.* 40, 32.
- Saulacic, N., Iizuka, T., Martin, M.S., Garcia, A.G., 2008. Alveolar distraction osteogenesis: a systematic review. *Int. J. Oral Maxillofac. Surg.* 37, 1–7.
- Sheikh, Z., Sima, C., Glogauer, M., 2015. Bone replacement materials and techniques used for achieving vertical alveolar bone augmentation. *Materials* 8, 2953–2993.
- Simon, B.I., Von Hagen, S., Deasy, M.J., Faldu, M., Resnansky, D., 2000. Changes in alveolar bone height and width following ridge augmentation using bone graft and membranes. *J. Periodontol.* 71, 1774–1791.
- Suhr, M.A., Kreuzsch, T., 2004. Technical considerations in distraction osteogenesis. *Int. J. Oral Maxillofac. Surg.* 33, 89–94.
- Torroni, A., Marianetti, T.M., Romandini, M., Gasparini, G., Cervelli, D., Pelo, S., 2015. Mandibular reconstruction with different techniques. *J. Craniofac. Surg.* 26, 885–890.
- Valentini, V., Gennaro, P., Torroni, A., Longo, G., Aboh, I.V., Cassoni, A., Battisti, A., Anelli, A., 2009. Scapula free flap for complex maxillofacial reconstruction. *J. Craniofac. Surg.* 20, 1125–1131.
- Wang, F., Huang, W., Zhang, C., Sun, J., Kaigler, D., Wu, Y., 2015. Comparative analysis of dental implant treatment outcomes following mandibular reconstruction with double-barrel fibula bone grafting or vertical distraction osteogenesis fibula: a retrospective study. *Clin. Oral Implants Res.* 26, 157–165.
- Wei, F.C., Demirkan, F., Chen, H.C., Chen, I.H., 1999. Double free flaps in reconstruction of extensive composite mandibular defects in head and neck cancer. *Plast. Reconstr. Surg.* 103, 39–47.
- Xingzhou, Q., Wang, Z., Ong, H.S., Chenping, Z., Abdelrehem, A., 2020. Accuracy of computer-aided design/computer-aided manufacturing surgical template for guidance of dental implant distraction in mandibular reconstruction with free fibula flaps. *J. Craniofac. Surg.* 31, 355–359.
- Yao, X.Y., Liu, H., Liu, W.W., 2020. Reconstruction of composite oral and maxillofacial defects by free flaps based on a new classification. *Sci. Rep.* 10, 4300.