



LUND UNIVERSITY

Perfusion Monitoring in Oculoplastic Reconstructive Surgery

Berggren, Johanna

2022

Document Version:

Publisher's PDF, also known as Version of record

[Link to publication](#)

Citation for published version (APA):

Berggren, J. (2022). *Perfusion Monitoring in Oculoplastic Reconstructive Surgery*. Lund University, Faculty of Medicine.

Total number of authors:

1

Creative Commons License:

CC BY

General rights

Unless other specific re-use rights are stated the following general rights apply:

Copyright and moral rights for the publications made accessible in the public portal are retained by the authors and/or other copyright owners and it is a condition of accessing publications that users recognise and abide by the legal requirements associated with these rights.

- Users may download and print one copy of any publication from the public portal for the purpose of private study or research.
- You may not further distribute the material or use it for any profit-making activity or commercial gain
- You may freely distribute the URL identifying the publication in the public portal

Read more about Creative commons licenses: <https://creativecommons.org/licenses/>

Take down policy

If you believe that this document breaches copyright please contact us providing details, and we will remove access to the work immediately and investigate your claim.

LUND UNIVERSITY

PO Box 117
221 00 Lund
+46 46-222 00 00

Perfusion Monitoring in Oculoplastic Reconstructive Surgery

Perfusion Monitoring in Oculoplastic Reconstructive Surgery

Johanna V. Berggren, M.D.



LUND
UNIVERSITY

DOCTORAL DISSERTATION

by due permission of the Faculty of Medicine, Lund University, Sweden.
To be defended at 1 pm on April 29th 2022, in Belfragesalen,
Klinikgatan 32, Lund University, Lund, Sweden.

Faculty Opponent

Clinical Assistant Professor Dan Georgescu, M.D., Ph.D.
Nova Southeastern University,
Fort Lauderdale, Florida, USA

Organization LUND UNIVERSITY Faculty of Medicine Department of Clinical Sciences Lund, Ophthalmology, Lund, Sweden		Document name DOCTORAL DISSERTATION	
Author: Johanna V. Berggren		Date of issue April 29 th 2022	
		Sponsoring organization	
Title and subtitle Perfusion Monitoring in Oculoplastic Reconstructive Surgery			
Abstract Understanding the vascular supply and the process of reperfusion is crucial for the successful design of flaps and the use of free full-thickness skin grafts in periocular reconstructive surgery. Many of the existing procedures are based on observation and experience, and were developed before objective perfusion monitoring was available. Modern imaging techniques have allowed detailed and reliable perfusion monitoring. In the work presented in this dissertation, laser speckle contrast imaging (LSCI) was used to monitor the blood perfusion in different kinds of flaps in humans (Studies I-IV), and in full-thickness skin grafts (Study V) frequently used in reconstructive surgery in the periocular area. Studies I, II, and IV were carried out to investigate the change in perfusion over the flap length. Studies I and II were performed on random flaps, meaning that they did not have a specific blood vessel. In Study I, upper eyelid flaps were raised in patients undergoing blepharoplasty. LSCI showed a gradual decrease in perfusion, from the base to the tip of the flaps. Perfusion was significantly higher in the myocutaneous flaps (including skin and orbicularis muscle), than in the cutaneous flap, in which the orbicularis muscle had been removed. Similar results were found in Study II, in which glabellar flaps were raised for tumor reconstruction. The perfusion in the flaps in both Studies I and II was very low beyond 15 mm, indicating that this part of the flap resembles a free skin graft, and could, if necessary, be replaced with a free graft. Study IV was performed on axial flaps, which are perfused by a specific blood vessel. Full-thickness lower eyelid flaps were raised as part of a modified Quickert procedure to treat entropion. The decrease in perfusion was found to be less pronounced than in the random flaps investigated in Studies I and II. This can be explained by the fact that axial flaps include an anatomically named blood vessel. The results of this study indicate that axial flaps can be longer than random flaps, while still ensuring adequate perfusion. In Studies II, III and V, the reperfusion of flaps and grafts was monitored over time postoperatively. The proximal parts of glabellar flaps (Study II) were rapidly reperfused within 1 week. Similar results were found in the reperfusion of random advancement flaps that were raised in an H-plasty procedure for tumor reconstruction (Study III). This rapid reperfusion is probably explained by the fact that the flaps maintain a vascular connection to the body via the base. In Study V, free full-thickness skin grafts were used for tumor or cicatricial ectropion reconstruction. Reperfusion took longer (7 weeks), probably due to the fact that free full-thickness skin grafts lack a vascular connection and depend on de novo angiogenesis, in contrast to the flaps in Studies II and III. In conclusion, modern imaging techniques, such as LSCI, enable detailed perfusion monitoring in different kinds of flaps and free skin grafts. This will provide opportunities to optimize surgical procedures, and thus outcome, and to gain a deeper understanding of the healing process.			
Key words perfusion, flap, free full-thickness skin graft, eyelid, oculoplastic, laser speckle contrast imaging			
Classification system and/or index terms (if any)			
Supplementary bibliographical information		Language: English	
ISSN and key title	1652-8220	ISBN	978-91-8021-203-8
Recipient's notes	Number of pages 49		Price
	Security classification		

I, the undersigned, being the copyright owner of the abstract of the above-mentioned dissertation, hereby grant to all reference sources permission to publish and disseminate the abstract of the above-mentioned dissertation.

Signature



Date 2022-03-08

Perfusion Monitoring in Oculoplastic Reconstructive Surgery

Johanna V. Berggren, M.D.



LUND
UNIVERSITY

Cover photo by Mika Liffner

Copyright pp. 1-49 Johanna V. Berggren

Paper 1 © 2021 Author

Paper 2 © 2021 Author

Paper 3 © 2020 Author

Paper 4 © 2020 Author

Paper 5 © 2020 Author

Review © 2021 Author

Lund University, Faculty of Medicine Doctoral
Dissertation Series 2022:42


ISSN 1652-8220

ISBN 978-91-8021-203-8

Printed in Sweden by Media-Tryck, Lund University, Lund 2022



Media-Tryck is a Nordic Swan Ecolabel
certified provider of printed material.
Read more about our environmental
work at www.mediatryck.lu.se

MADE IN SWEDEN 

To my supportive and loving family

*The more I learn,
the less I realize I know.*
– Socrates

Contents

Papers included in this dissertation	1
Original publications	1
Review.....	2
Abstract	3
Introduction	5
Vascular anatomy of the periocular region	6
Cutaneous microcirculation.....	7
Eyelid anatomy.....	9
Reconstructive techniques.....	10
Wound healing by secondary intention	11
Direct closure.....	11
Skin graft	11
Types of flaps	12
Perfusion monitoring in reconstructive surgery	14
Laser speckle contrast imaging	14
Dissertation at a glance	18
Aims	19
General aim	19
Specific aims	19
Methods	21
Ethical considerations	21
Perfusion monitoring and statistics	21
Reconstructive surgical procedures.....	22
Upper eyelid myocutaneous and cutaneous flaps.....	22
Glabellar flaps	22
H-plasty	23
Full-thickness lower eyelid flaps.....	24
Free full-thickness skin grafts	25
Results and discussion.....	27

Upper eyelid myocutaneous and cutaneous flaps.....	27
Glabellar flaps	28
H-plasty.....	29
Full-thickness lower eyelid flaps.....	31
Free full-thickness skin grafts	32
Conclusions and future perspectives.....	35
The surgical procedures	35
Perfusion monitoring.....	36
Populärvetenskaplig sammanfattning	39
Acknowledgements	41
References	45

Papers included in this dissertation

Original publications

This dissertation is based on the papers below, which will be referred to in the text as Study I-V.

- I. **Berggren JV**, Tenland K, Bunke J, Albinsson J, Hult J, Merdasa A, Sheikh R, Lindstedt S, Malmsjö M. Blood Perfusion of Human Upper Eyelid Skin Flaps Is Better in Myocutaneous than in Cutaneous Flaps. *Ophthalmic Plast Reconstr Surg*. 2021 Jul 21. doi: 10.1097/IOP.0000000000002015. Epub ahead of print. PMID: 34293787.
- II. **Berggren JV**, Tenland K, Sheikh R, Hult J, Engelsberg K, Lindstedt S, Malmsjö M. Laser Speckle Contrast Imaging of the Blood Perfusion in Glabellar Flaps Used to Repair Medial Canthal Defects. *Ophthalmic Plast Reconstr Surg*. 2021 Nov 8. doi: 10.1097/IOP.0000000000002082. Epub ahead of print. PMID: 34750313.
- III. **Berggren J**, Castelo N, Tenland K, Engelsberg K, Dahlstrand U, Albinsson J, Sheikh R, Lindstedt S, Malmsjö M. Revascularization after H-plasty Reconstructive Surgery in the Periorbital Region Monitored with Laser Speckle Contrast Imaging. *Ophthalmic Plast Reconstr Surg*. 2021 May-Jun 01;37(3):269-273. doi: 10.1097/IOP.0000000000001799. PMID: 32852371.
- IV. Tenland K, **Berggren JV**, Dybelius Ansson C, Hult J, Dahlstrand U, Lindstedt S, Sheikh R, Malmsjö M. Blood Perfusion in Rotational Full-Thickness Lower Eyelid Flaps Measured by Laser Speckle Contrast Imaging. *Ophthalmic Plast Reconstr Surg*. 2020 Mar/Apr;36(2):148-151. doi: 10.1097/IOP.0000000000001496. PMID: 31876674.
- V. **Berggren J**, Castelo N, Tenland K, Dahlstrand U, Engelsberg K, Lindstedt S, Sheikh R, Malmsjö M. Reperfusion of Free Full-Thickness Skin Grafts in Periocular Reconstructive Surgery Monitored Using Laser Speckle Contrast Imaging. *Ophthalmic Plast Reconstr Surg*. 2021 Jul-Aug 01;37(4):324-328. doi: 10.1097/IOP.0000000000001851. PMID: 32991497.

Review

This review was performed to summarize the research field in the perspective of my scientific contributions, with the aim of facilitating for the reader, but is not part of this dissertation.

Berggren JV, Stridh M, Malmsjö M. Perfusion Monitoring during Oculoplastic Reconstructive Surgery: A Comprehensive Review. *Ophthalmic Plast Reconstr Surg.* 2021, Dec. 16. doi: 10.1097/IOP.0000000000002114. Epub ahead of print. PMID: 34919068.

Abstract

Understanding the vascular supply and the process of reperfusion is crucial for the successful design of flaps and the use of free full-thickness skin grafts in periocular reconstructive surgery. Many of the existing procedures are based on observation and experience, and were developed before objective perfusion monitoring was available. Modern imaging techniques have allowed detailed and reliable perfusion monitoring. In the work presented in this dissertation, laser speckle contrast imaging (LSCI) was used to monitor the blood perfusion in different kinds of flaps in humans (Studies I-IV), and in full-thickness skin grafts (Study V) frequently used in reconstructive surgery in the periocular area.

Studies I, II, and IV were carried out to investigate the change in perfusion over the flap length. Studies I and II were performed on random flaps, meaning that they did not have a specific blood vessel. In Study I, upper eyelid flaps were raised in patients undergoing blepharoplasty. LSCI showed a gradual decrease in perfusion, from the base to the tip of the flaps. Perfusion was significantly higher in the myocutaneous flaps (including skin and orbicularis muscle), than in the cutaneous flap, in which the orbicularis muscle had been removed. Similar results were found in Study II, in which glabellar flaps were raised for tumor reconstruction. The perfusion in the flaps in both Studies I and II was very low beyond 15 mm, indicating that this part of the flap resembles a free skin graft, and could, if necessary, be replaced with a free graft.

Study IV was performed on axial flaps, which are perfused by a specific blood vessel. Full-thickness lower eyelid flaps were raised as part of a modified Quickert procedure to treat entropion. The decrease in perfusion was found to be less pronounced than in the random flaps investigated in Studies I and II. This can be explained by the fact that axial flaps include an anatomically named blood vessel. The results of this study indicate that axial flaps can be longer than random flaps, while still ensuring adequate perfusion.

In Studies II, III and V, the reperfusion of flaps and grafts was monitored over time postoperatively. The proximal parts of glabellar flaps (Study II) were rapidly reperfused within 1 week. Similar results were found in the reperfusion of random advancement flaps that were raised in an H-plasty procedure for tumor reconstruction (Study III). This rapid reperfusion is probably explained by the fact that the flaps maintain a vascular connection to the body via the base. In Study V,

free full-thickness skin grafts were used for tumor or cicatricial ectropion reconstruction. Reperfusion took longer (7 weeks), probably due to the fact that free full-thickness skin grafts lack a vascular connection and depend on *de novo* angiogenesis, in contrast to the flaps in Studies II and III.

In conclusion, modern imaging techniques, such as LSCI, enable detailed perfusion monitoring in different kinds of flaps and free skin grafts. This will provide opportunities to optimize surgical procedures, and thus outcome, and to gain a deeper understanding of the healing process.

Introduction

The goal of oculoplastic reconstructive surgery is to achieve functional and esthetically pleasing results. Reconstructive procedures are often used to repair tissue defects after tumor excision. Non-melanoma skin cancer is the most common malignant condition in the Caucasian population, with basal cell carcinoma (BCC) accounting for 75%, and squamous cell carcinoma for 20% of all cases of skin cancer. (1, 2) Skin tumors such as basal cell carcinoma are common in areas exposed to the sun, such as the face. The unique anatomy of the periocular area presents a reconstructive challenge, and surgery must be carefully planned in order to avoid distortion of the surrounding tissues. The eyelids protect the eye, and scarring may cause malposition of the eyelid, leading to asymmetry of the eyelids and damage to the eye. The tissue in the periocular area is often limited following tumor excision, which may pose a challenge for the surgeon. (3) If direct closure is not possible, flaps or free full-thickness skin grafts are often considered. Correct design of the flaps and skin grafts is vital for the survival of the tissue and the surgical outcome. A good understanding of the vascular supply and the process of revascularization is thus essential. The main aim of the research described here was to deepen our knowledge on microvascular blood perfusion in the periocular region, the way in which it is affected by surgery, and its restoration postoperatively.

Reconstructive surgical procedures are described in ancient Egyptian documents dated around 1500 BC. (4) In the 6th century BC, the Indian physician Sushruta described reconstructive procedures such as the pedicle cheek flap for reconstruction of the nose. (5, 6) The two World Wars resulted in the need for reconstructive surgery following the horrific traumas inflicted by heavy artillery, machine guns and poison gas. Sir Harold Gilles (1882-1960) was responsible for important advances in plastic surgery, and is often referred to as the father of modern plastic surgery. (7) It was not possible to monitor perfusion when many reconstructive surgical techniques were developed, and they are thus based on empirical observations and clinical outcome. Today, laser-based techniques can be used to monitor the perfusion of skin flaps during surgery, enabling detailed perfusion monitoring in flaps and free skin grafts. This provides opportunities to both optimize surgical procedures, and to understand the healing process in greater detail. Improved knowledge on perfusion and revascularization will help oculoplastic surgeons in their choice of reconstructive technique in individual cases.

Details concerning the various methods that can be used to evaluate blood perfusion, and the current literature on blood perfusion monitoring in the periocular area are presented in a review appended to this dissertation.

Vascular anatomy of the periocular region

Knowledge of the blood supply to the periocular area is essential when predicting the effect of reconstructive surgery. The periocular vascular system is complex, with inter-individual variations. The internal carotid artery branches off into the lacrimal, supraorbital, supratrochlear, and dorsal nasal arteries (Figure 1). The two medial palpebral arteries may branch off from the ophthalmic artery. The lacrimal artery passes laterally of the eye and supplies the lacrimal gland. It pierces the septum and then branches off into the two lateral palpebral arteries. The supraorbital artery passes superiorly into the brow fat pad and pierces the frontalis muscle, supplying part of the upper eyelid, forehead and scalp. The dorsal nasal artery runs superior to the medial canthal tendon and supplies the skin of the root of the nose and the lacrimal sac. In cases where the medial palpebral arteries do not arise from the ophthalmic artery, they branch off from the dorsal nasal artery. The medial and lateral palpebral arteries anastomose in the upper and lower eyelids. They form tarsal arcades on the surface of the tarsal plates 2-4 mm from the lid margins, and supply the area of the fornices and the bulbar conjunctiva. In the upper eyelid, they form another tarsal arcade on top of the tarsal plate (the superior peripheral arcade). The supratrochlear artery pierces the septum with the supratrochlear nerve and continues superiorly into the mid forehead and supplies it. It anastomoses with the supraorbital artery. The external carotid system supplies parts of the eyelids through the infraorbital artery, the angular artery and the superficial temporal artery. The infraorbital artery branches off from the internal maxillary artery and runs along the orbital floor. It has several small branches anterior to the lacrimal sack. The angular artery forms the termination of the facial arteries and extends about 8 mm medially of the inner canthus. It anastomoses with the dorsal nasal branch of the ophthalmic artery and supplies the orbicularis muscle and the lacrimal sac. The superficial temporal artery progresses from the preauricular area with three branches that supply the lateral portion of the eyelids: the frontal, the zygomatico-orbital and the transverse facial branches. (8-10)

The anatomy of the periocular vascular system has initially mostly been mapped by dissecting human cadavers. (11) Modern perfusion and oxygenation monitoring techniques now provide the opportunity to learn more about the importance of the vascular supply in reconstructive surgery in this area.

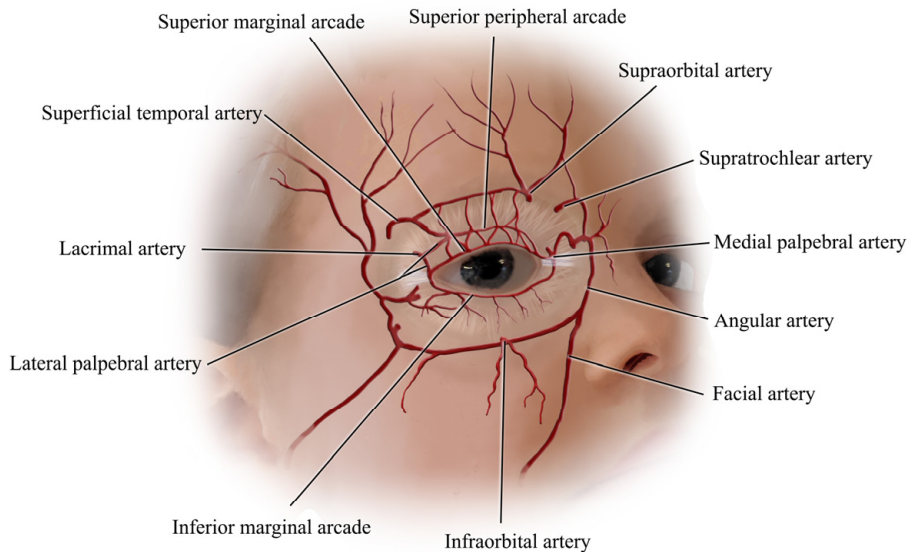


Figure 1. Illustration of the vascular anatomy in the periorcular area. Note the arterial arcades of the upper and lower eyelids. (Illustration by Jenny Hult)

Cutaneous microcirculation

The smallest blood vessels in the body with a diameter of $<150\ \mu\text{m}$, i.e. the arterioles, capillaries and venules, are referred to as the microcirculation (Figure 2A). These vessels are very narrow, so the erythrocytes are as close as possible to the vessel wall and the cells in the target organ, in order to achieve an effective exchange of oxygen and nutrients. The diameter of a typical capillary is only $4\text{-}10\ \mu\text{m}$. The architecture of the capillary network differs in different tissues, such as skin and muscles. In the skin, which has low metabolic activity, the capillary density is low ($16\text{-}55/\text{mm}^2$), while it is much higher in muscles ($1000\text{-}2000/\text{mm}^2$) which have high metabolic needs. (12-14)

The circulation can be adjusted to the current needs of a particular organ. For example, blood flow to the stomach and intestines is increased following a meal, providing oxygen and transporting the products of digestion. During strenuous exercise, the circulation in the skin is increased to dissipate heat in order to achieve thermal homeostasis. (12, 15, 16) Spontaneous contraction and vasodilation in the microvascular bed (vasomotion) leads to an increase and decrease in the blood flow in the capillaries approximately 4 times per minute. (13)

The skin is the largest organ of the human body. The outermost layer of the skin, the epidermis, acts as a waterproof barrier. Its thickness varies between 0.05 mm and 1 mm, depending on the location on the body. The underlying dermis contains tough connective tissue, sensory receptors, hair follicles, and sweat glands. The thickness of this varies between 1 and 10 mm. (17) The deeper subcutaneous tissue, also known as the subcutis, consists of fat and connective tissue.

The microcirculation in the skin consists of two plexuses, the superficial and deep plexuses (Figure 2B), which include capillaries, arterioles and venules. (12, 14) The deep vascular plexus is located between dermis and the subcutaneous fat. Arterioles and venules connect the superficial and deep plexuses. Arterial capillaries in the superficial plexus form the dermal capillary loops. Microcirculation is vital for skin homeostasis, nourishment, blood pressure regulation and inflammatory response. Smooth muscle cells and pericytes enable changes in perfusion. Normal blood flow is about 0.25 L/min. During for example, strenuous exercise it can reach 8 L/min to reduce body temperature,. (15) Nerve signals, local chemical mediators such as histamine and nitric oxide, and local oxygen tension will affect the vascular resistance and thus the blood flow. (18, 19)

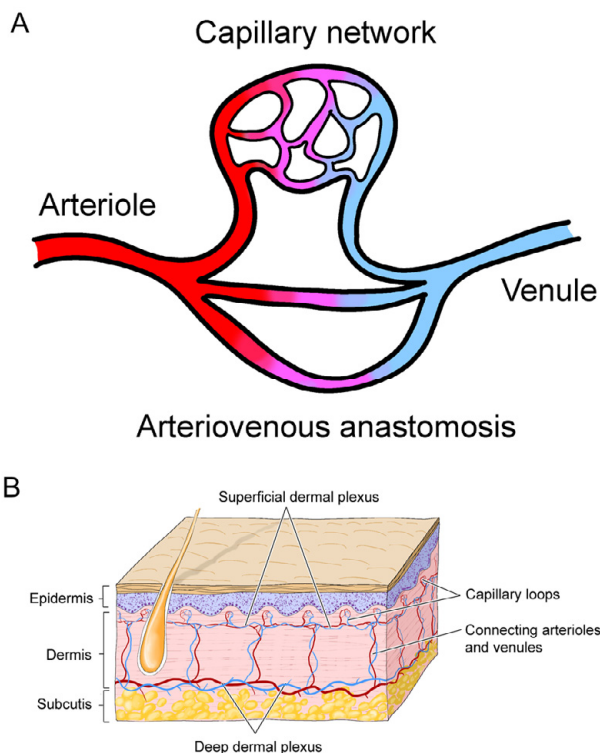


Figure 2. (A) The microcirculation consists of arterioles, capillaries and venules. (B) Microcirculation in the skin, showing the different layers in the skin: the epidermis, dermis and subcutis. (Illustration by Jenny Hult)

Eyelid anatomy

The eyelids are essential in spreading the tear film, lubricating the cornea, and protecting the eye bulb. The eyelids are divided into the anterior and posterior lamellae, as shown in Figure 3. The skin and the orbicularis muscle form the anterior lamella, while the tarsal plate and the conjunctiva build the posterior lamella. (20) When reconstructing full-thickness defects of the eyelids, both lamellae need to be repaired to achieve good results, both functionally and esthetically. Disruption of the eyelid anatomy can be a potential threat to the cornea and the ocular surface, and thus a potential threat to the integrity of the whole eye.

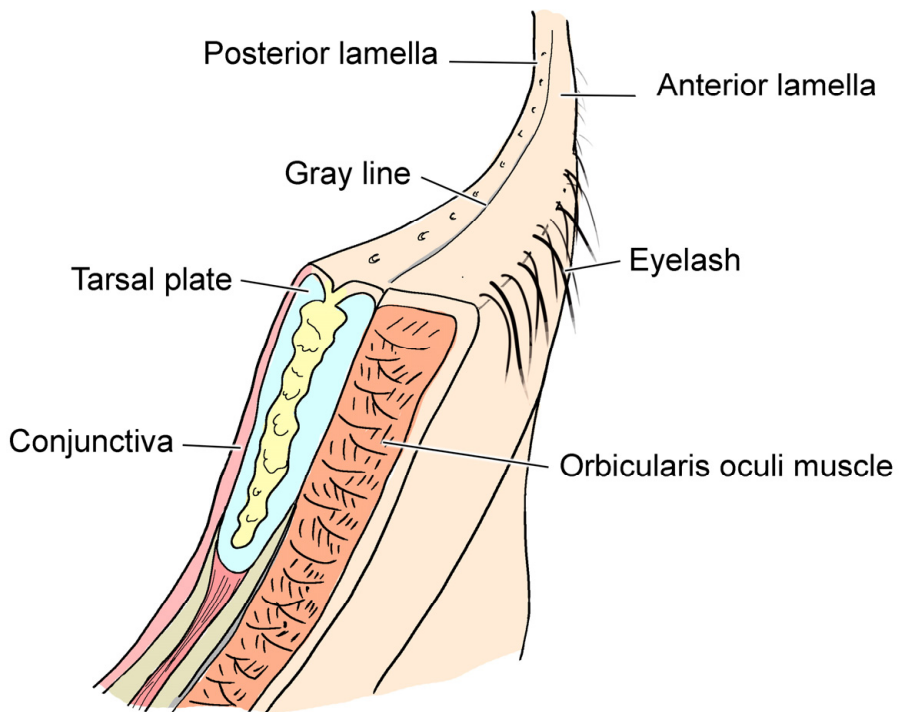


Figure 3. Anatomy of the human eyelid, showing the division into the anterior and posterior lamellae. The gray line is the most superficial aspect of the orbicularis muscle (the muscle of Riolan) and it is often used as an anatomic landmark by surgeons. (Illustration by Jenny Hult)

Reconstructive techniques

Choosing the most suitable reconstructive procedure poses a challenge to the surgeon. The “reconstructive ladder” is a familiar concept to all plastic surgeons, and can be used as a guide when choosing the method of wound closure (Figure 4). According to the reconstructive ladder, the simplest reconstruction of the defect should be chosen. The more complex the wound, the more complex the technique. (16, 21) The reconstructive ladder has been criticized for oversimplification, and a newer concept, the “reconstructive elevator”, was presented by Gottlieb in 1994. This makes it possible to choose a more complex method of reconstruction in specialized cases of function and aesthetic outcome. (22)

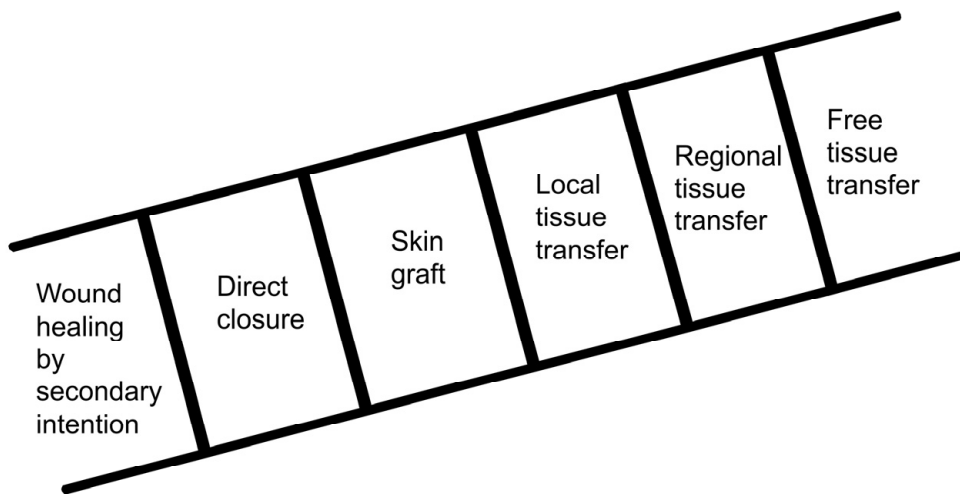


Figure 4. The reconstructive ladder illustrates the possible options for wound closure. Different wounds will require different closure techniques depending on their complexity. Closure should be achieved by the simplest effective technique. However, more sophisticated techniques are needed in some cases, to ensure a better outcome. Wound healing by secondary intention means that the wound is left to heal by itself. Direct closure can be used if the laxity of the tissue allows the layers of the tissue to be directly opposed. Skin graft is a technique in which free tissue is harvested from a remote donor site and transferred to the wound. Unlike skin flaps, grafts lack a connection to the vascular network. In local tissue transfer adjacent tissue is transferred to repair the defect. In regional tissue transfer, tissue is obtained from an area further away from the defect. Both local and regional tissue transfer are connected to the vascular network. During free tissue transfer, tissue with its blood supply (artery and vein) is surgically removed from one part of the body and transferred to the wound, and the blood vessels are reconnected to the circulation using microsurgery. (Illustration by Jenny Hult)

Wound healing by secondary intention

Wound healing by secondary intention, also known as *laissez-faire*, was first described in the periorbital region in 1957. (23) The wound edges are not opposed and therefore healing must occur from the bottom of the wound upwards. More recent studies have shown that this technique can be used for relatively large periorbital defects with good results, especially in the medial canthal region and in full-thickness lower lid defects. However, it is associated with a risk of cicatrization in large defects, particularly with extension into the cheek. (24)

Direct closure

In direct closure, the wound is closed by directly opposing the tissue layers, which minimizes new tissue formation within the wound. (24) Late post-operative outcome has been reported to be excellent following direct closure of eyelid defects, even under high tension (25, 26). Although some expansion of the eyelid is possible, larger defects cannot be repaired in this way.

Full-thickness eyelid defects in the upper eyelid of up to approximately 20% can be closed directly in young patients, and those up to 30% in older patients due to increased age-related laxity. Direct closure can be considered for central eyelid defects of the lower lid that involve less than 20% of the lid margin. (8)

Skin graft

Skin grafting involves the transplantation of skin from another part of the body. Skin grafts from the inside of the arm, the pre- and postauricular area, the supraclavicular fossa, or the contralateral upper eyelid above the skin crease, are often preferred in reconstructive surgery in the periocular area. (9)

Split-thickness skin grafts consist of the epidermis and the superficial part of the dermis. This type of graft is usually only used for large wounds or areas with a poor blood supply. The split-thickness technique is seldom used on the face, due mainly to poor cosmetic outcome. However, it is a reconstructive option after orbital exenteration. (27)

A full-thickness skin graft consists of the entire epidermis and dermis. The graft is harvested from an area with spare skin, and the donor wound is closed directly. Attempts are usually made to match the skin color, texture and thickness in periocular reconstructive surgery, and spare skin from the upper eyelids is therefore often used. (9) The aim of study V was to monitor the reperfusion of free skin grafts in the periocular area.

Types of flaps

A flap is a construct of tissue with a partially intact vascular supply that is relocated or repositioned from the donor site to repair a defect. Successful reconstruction using flaps requires good understanding of cutaneous vascular anatomy, skin biomechanics, and tissue geometry. Pre-operative errors in flap choice and design can reduce the probability of successful reconstruction. Pre-operative analysis of a skin defect, precise planning, and atraumatic surgical technique are needed for a favorable outcome. (19) Flaps can be categorized according to their origin, blood supply and the primary movement of the flap.

Local flaps

Local flaps, belonging to the local tissue transfer rung of the reconstructive ladder, are raised from tissue next to the defect, and are often preferred after removal of a facial skin lesion. Local skin flaps have the advantage of coverage with skin that matches in color, thickness, and texture. The risk of donor site morbidity is also avoided. (28) Studies I-IV involved different types of local flaps.

Regional flaps

Regional flaps, the next rung on the reconstructive ladder, are created using tissue from the same general area as the defect. For example, a contra- or an ipsilateral paramedian forehead flap may be an alternative for repairing large defects resulting from the excision of a skin tumor in the canthal area. (29-31)

Distant flaps

Distant flaps originate far away from the defect, and are usually divided into pedicled or free flaps. Pedicled flaps are raised from another region and are still attached to the donor site to ensure a vascular supply. A well-known flap in plastic surgery is the Tagliacozzi flap, i.e. an upper-arm skin flap, which can be used for total nasal reconstruction in children.

Free tissue transfer, the highest rung on the reconstructive ladder, involves microsurgery, in which the blood vessels in the flap are attached to the blood vessels in the defect. For example, a free flap can be harvested from the scapular-parascapular region for the reconstruction of defects on the face. (32) However, free flaps are seldom used in the periocular area.

Random flaps

A random skin flap is not based on a specific vessel for perfusion. Instead its blood perfusion originates from the dermal plexus of the base of the flap (Figure 5A). (19, 33) Random flaps are often used in the richly vascularized periocular area. The perfusion in different kinds of random flaps was monitored in Studies I-III.

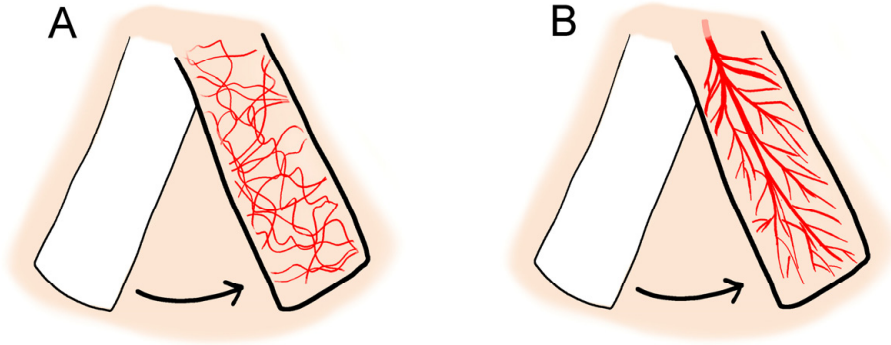


Figure 5. (A) A random flap showing the vascular network. (B) An axial flap supplied by a specific artery. (Illustration by Jenny Hult)

Axial flaps

Unlike random flaps, axial pattern skin flaps are based on a specific, anatomically named vascular vessel, and have a large cutaneous arteriovenous system parallel to the skin surface (Figure 5B). (19, 33) In periocular reconstructive surgery, the superficial temporal artery can be used. (34)

In Study IV, a model of an axial flap perfused by the inferior arcade was created, and the way in which perfusion was affected by rotation and stretching was investigated. This kind of flap can be useful in the case of very large full-thickness defects (>75%) in the upper eyelid, i.e. when both the anterior and posterior lamellae are affected. When using the Mustardé lower lid switch flap, a full-thickness flap from the lower eyelid is rotated based on the marginal vessels, and used to repair the defect in the upper eyelid. The pedicle is typically divided after up to 6 weeks. A significant portion of the lower eyelid will need to be repaired using cheek advancement and posterior lamella grafts. (35)

Advancement flaps

When using advancement flaps, adjacent tissue is stretched and mobilized linearly to cover a defect. Rectangular advancement flaps are often used in the periocular area. When pretarsal eyelid skin defects are repaired, the flap is advanced horizontally. These can be unipedicle or bipedicle. (34) The use of bipedicle advancement flaps is often referred to as H-plasty, and is the subject of Study III. Unipedicle upper eyelid advancement flaps were studied in Study I.

Rotational flaps

In some cases, adjacent tissue is raised as a flap and rotated into a defect to repair it. This kind of flap is referred to as a rotational flap. Rotational flaps, such as the Mustardé cheek flap and the Tenzel flap, are frequently used in the periocular region for defects in the eyelids. (34)

Transposition flaps

Tissue nearby can be lifted over intervening skin and used to cover a defect. The glabellar flaps in Study II were considered to be such transposition flaps. This type of flap is often considered for the repair of medial canthal defects, where a flap shaped like an inverted V is raised from the glabellar region between the eyebrows and rotated into the defect. (34)

Perfusion monitoring in reconstructive surgery

Various techniques have been used to monitor blood perfusion. Traditionally, surgeons have assessed the blood perfusion using subjective signs, such as skin temperature, turgor, color, smell and capillary refill time. (36) Different techniques based on the use of pharmacological agents or fluorescent dyes, pH monitoring, radioactive isotopes, hydrogen gas clearance, microdialysis, spectroscopic methods and temperature monitoring have been used in attempts to evaluate perfusion in a more objective manner. (19) However, many of these techniques are associated with limitations, for example, they are invasive, not reliable or too cumbersome. Thanks to the invention of the laser in 1960, (37) techniques such as laser Doppler flowmetry, laser Doppler perfusion imaging and laser speckle contrast imaging (LSCI), are now used to assess perfusion. LSCI was used in Study I-V. Other promising techniques are also being developed, such as photoacoustic imaging, for the monitoring of tissue oxygenation during reconstructive surgery. These techniques are further described and discussed in the review at the end of this dissertation.

Laser speckle contrast imaging

Modern imaging techniques have made it easier to monitor microvascular blood flow. LSCI allows for the continuous recording of blood flow over large areas of the skin, and was used in all the studies presented here (Figure 6). LSCI was first introduced in the 1980s as a powerful blood flow imaging tool, and has been used to monitor perfusion, for example, in the brain, skin, retina and kidneys. (38) Accurate measurements of microvascular blood perfusion are of interest in plastic reconstructive procedures, (39-41) and in monitoring burns (42) and wound healing, (43) and can also provide insight into vascular diseases and their mechanisms. The measurement of peripheral skin perfusion is relatively easy, and has thus been suggested as a means of detecting systemic microvascular dysfunction in several vascular pathologies, including hypertension, renal disease, diabetes, peripheral vascular disease, atherosclerotic coronary artery disease, heart failure and systemic sclerosis. (44, 45)

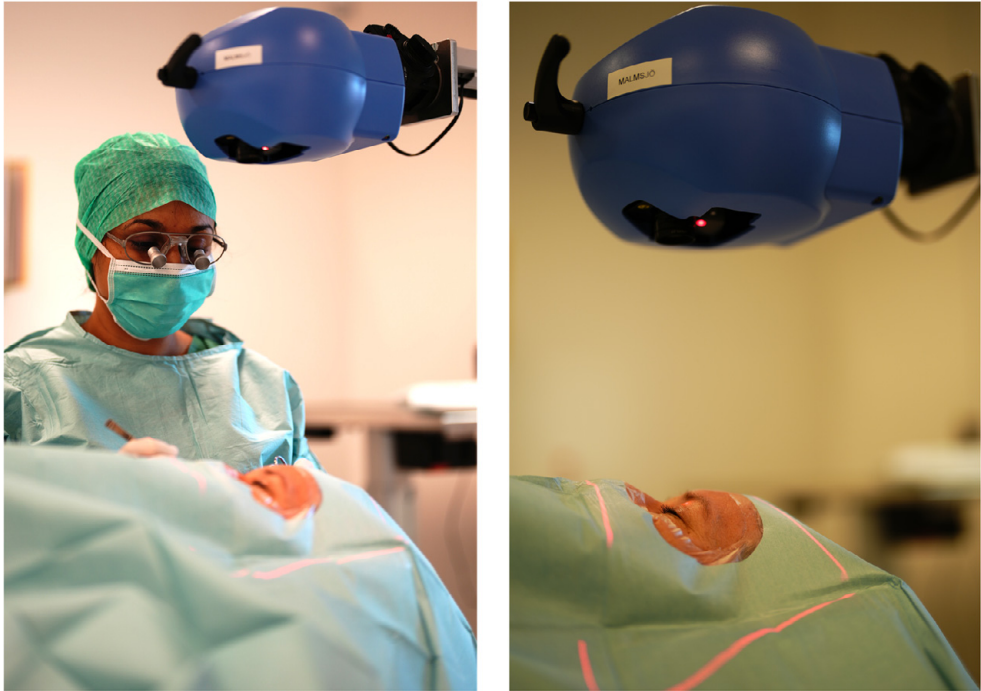

Figure 6. Photograph showing the PeriCam equipment for perfusion monitoring during surgery. The visible red laser light (650 nm) seen in the photograph is used for positioning. (Photograph by Rafi Sheikh)

The LSCI system employs a near-infrared 785 nm laser beam to create speckle patterns. The measurement depth is related to the wavelength of the laser; longer wavelengths penetrating deeper. Other factors, such as the concentration of red blood cells and the vascular anatomy are also known to affect the penetration depth. The penetration depth in tissue is approximately 300 μm . According to a study by Davis et al., 95% of the detected LSCI signal derives from the upper 700 μm of superficial tissue. (46)

When a seemingly smooth surface is illuminated by a coherent light source, such as a laser, there will be differences between the surface and the image plane (the camera or the observer's eye) due to minor irregularities in the surface. When light is reflected from two positions at different distances from the detector, the waves will interfere, either constructively or destructively, as illustrated in Figure 7.

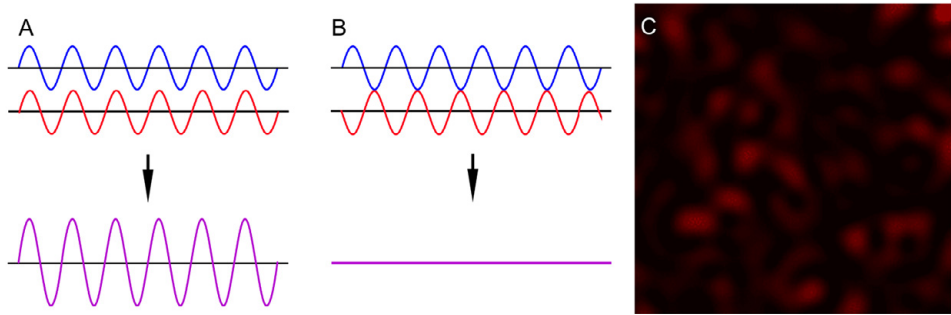


Figure 7. (A) Constructive interference where the amplitudes add. (B) Destructive interference where the light waves cancel each other out. (Illustration by Jenny Hult) (C) The speckle pattern produced by interference. (Photograph courtesy of Perimed).

Random interference of coherent light reflected from different scatterers will produce a speckle pattern, which is recorded in a photodetector. If the particles in the scattering medium are moving, such as moving red blood cells, the speckle pattern will fluctuate (moving speckle pattern), and the intensity at the photodetector will vary. If there is no movement the speckle pattern will be static. (47) When the blood flow is high, the intensity fluctuations of the speckle pattern are more rapid, and when integrated over the exposure time of the charged-coupled device (CCD) camera, the speckle pattern will be blurred. A measure of the relative blood flow is then obtained by quantifying the blurring of the speckles in the image by measuring the spatial contrast of the intensity variations (Figure 7C). The recording rate is up to 100 images per second, and the spatial resolution up to 100 $\mu\text{m}/\text{pixel}$. The variations in the speckle pattern are analyzed and the blood perfusion calculated automatically by the software in the system. To quantify the blurring of the speckles, the local speckle contrast (C) is calculated as the ratio of the standard deviation of the intensity (σ) and the mean intensity ($\langle I \rangle$) calculated over a window in space or time. (48)

$$C = \frac{\sigma}{\langle I \rangle}$$

LSCI is thus highly sensitive to movement artifacts, and it can be difficult to separate the signals from these from the signal generated by the microcirculation. (49) Any movement of the patient (e.g., breathing, trembling, coughing, shivering, and flinching), even of very small amplitude, will result in large artifacts in the recorded signal. Although an occasional movement artifact can be easily identified and manually removed, repetitive or prolonged movements produce very “noisy” data making their interpretation difficult.

Another difficulty in interpreting LSCI data is caused by the so-called “biological zero”, i.e. when blood flow is assumed to be zero during vascular occlusion, there is still a residual value. Biological zero is defined as the signal obtained from a tissue

in the absence of vascular flow. This has been the subject of many studies. Although its origin is still not completely understood, it is thought to be generated by Brownian motion of the macromolecules within the interstitium, the vascular compartment and lymphatic system, or other phenomena related to the function of the autonomic nervous system. (49-51)

LSCI gives the blood flow in arbitrary units, called perfusion units (PU), rather than the flow in terms of ml/kg body weight or ml/min. This makes it difficult to compare measurements from different studies. Figure 8 shows the results of a perfusion measurement using LSCI on a patient.

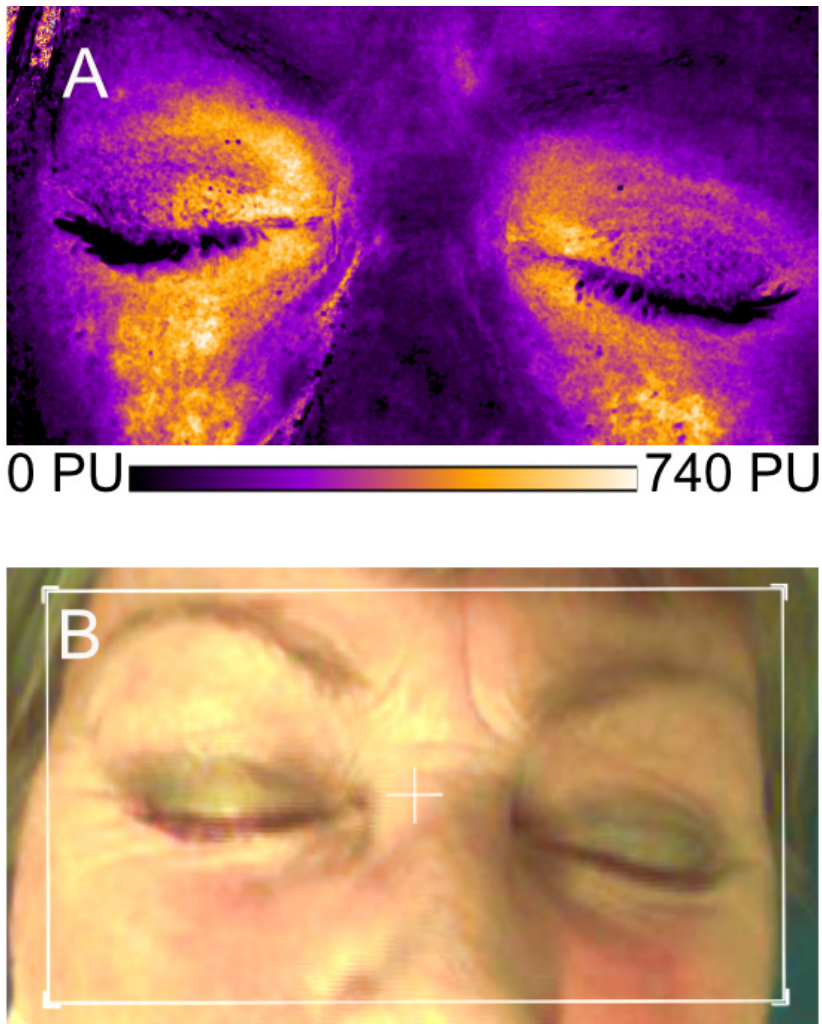


Figure 8. (A) LSCI image of the periocular area of a patient. The paler white and yellow areas are regions with high blood perfusion, and dark areas are regions with low perfusion. (B) A photograph of the patient for comparison.

Dissertation at a glance

This dissertation presents blood perfusion measurements with laser speckle contrast imaging in patients undergoing different oculoplastic surgical procedures. The aim of each study, flap/graft type and surgical procedure are outlined below.

Study	Aim	Flap/graft type	Surgical procedure
I	To study the perfusion of myocutaneous and cutaneous upper eyelid flaps.	Random flap	Upper eyelid blepharoplasty to correct dermatochalasis
II	To study the perfusion and the reperfusion of glabellar flaps used to repair medial defects.	Random flap	Reconstruction after tumor excision
III	To study reperfusion following H-plasty.	Bipedicle, random advancement flap	Reconstruction after tumor excision
IV	To study the perfusion of lower eyelid flaps and how it is impacted by flap length, rotation, and stretching.	Axial flap	Quickert procedure for treatment of entropion
V	To study the reperfusion of free full-thickness skin grafts.	Free full-thickness skin graft	Reconstruction after tumor excision or correction of cicatricial ectropion

Aims

General aim

The main aim of this work was to deepen our knowledge on the effects of oculoplastic reconstructive surgery on perfusion in patients.

Specific aims

The specific aims were as follows.

- To monitor perfusion using laser speckle contrast imaging during oculoplastic surgery procedures.
- To examine the change in perfusion over the flap length in:
 - random flaps, in patients undergoing blepharoplasty,
 - random glabellar flaps, and
 - axial flaps, raised as part of a modified Quickert procedure.
- To examine the reperfusion of flaps and grafts over time during the process of healing in:
 - glabellar flaps,
 - advancement flaps in the H-plasty procedure, and
 - free full-thickness skin grafts.

Methods

Ethical considerations

The studies were carried out in patients referred to the Department of Ophthalmology, Skåne University Hospital (Studies I-V) and to the Central Hospital Växjö, Sweden (Study I). The experimental protocols for these studies were approved by the Ethics Committee at Lund University, Sweden. The research adhered to the tenets of the Declaration of Helsinki as amended in 2008 (52). Participation was voluntary, and all patients included in the studies gave their fully informed consent. Patients who were incapable of providing consent or who were physical or mentally unable to cooperate during the surgical procedure under local anesthesia, were not included in the studies.

The health of the patients was our primary consideration. Research was preceded by careful assessment of predictable risks and burdens to the individual. Laser light may be harmful, and could damage the retina. The LSCI laser used is considered a class 1 laser. This means that it has low energy output and only superficial tissue penetration. It has therefore been approved for use in the region around the eye and is known to be safe to use without eye protection. (53) However, as a precaution, a corneal shield (Ellman International Inc., Oceanside, NY, USA) was used to protect the patient's eye when LSCI was used close to the eye.

Perfusion monitoring and statistics

In study II-V blood perfusion was monitored using a PeriCam PSI NR system (Perimed AB, Stockholm, Sweden) (Figure 6) calibrated in accordance with the instructions of the manufacturer. A corresponding system, moorFLP-2 (Moor Instruments, Devon, United Kingdom), was used in study I.

Perfusion measured with LSCI is expressed in arbitrary units (perfusion units, PU). The perfusion was calculated as a percentage of the perfusion at a reference point (baseline). GraphPad Prism (GraphPad Software, San Diego California USA, www.graphpad.com) was used for statistical calculations. Details of the perfusion measurements and statistical analysis can be found in the papers.

For description of the protocols for perfusion monitoring and statistical analysis, see respective Study I-V.

Reconstructive surgical procedures

Upper eyelid myocutaneous and cutaneous flaps

In Study I, a total of 20 random upper eyelids flaps were dissected in 10 patients with excess skin as part of the blepharoplasty procedure. These flaps are considered random skin flaps since they lack a specific vessel at the flap base. The flaps consisted of skin and the underlying orbicularis oculi muscle, and the medial end remained intact in order to mimic a flap (Figure 9). The perfusion was monitored in the random myocutaneous flaps. The orbicularis oculi muscle was then removed in order to create a cutaneous flap, and the perfusion measurements repeated. The median horizontal length of the flaps was 44.5 mm, and the median vertical width at the base was 6.5 mm. (See Paper I for a detailed description of the method.) Six flaps were excluded from the analysis due to very pronounced motion artifacts.

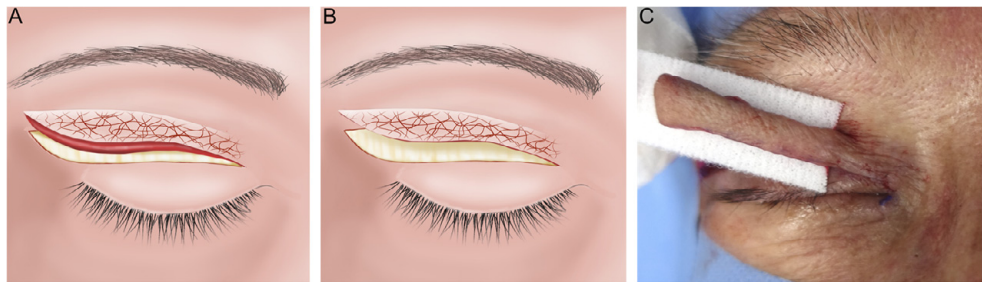


Figure 9. (A) Schematic illustration of a dissected random upper eyelid myocutaneous flap including the orbicularis oculi muscle. (B) Schematic illustration of a dissected random upper eyelid cutaneous flap. (Illustrations by Jenny Hult) (C) Photograph showing a dissected random upper eyelid myocutaneous flap in a patient.

Glabellar flaps

Seven patients requiring reconstructive surgery after tumor excision from the medial canthal area were included in Study II. There are a number of options for repairing medial canthal defects, for example, laissez-faire and full-thickness skin grafting. In these patients, the random glabellar flap was chosen, where adjacent tissue on a vascular base was transposed into the defect. After incising an inverted V-shaped flap in the midline of the brow extending down to the defect, the flap was subcutaneously undermined (Figure 10). The blood supply for these flaps was not derived from a specific artery but, from the microvasculature, making it a random flap. The median width of the flap base was 17 mm. The flap was then rotated and sutured into the defect in the medial canthus. The defect between the eyebrows was

sutured. The flap is therefore based on a V-Y flap design. (54) Perfusion monitoring was performed during surgery and at several follow-up visits at approximately 1, 3 and 6 weeks. (For details, see Paper II.)

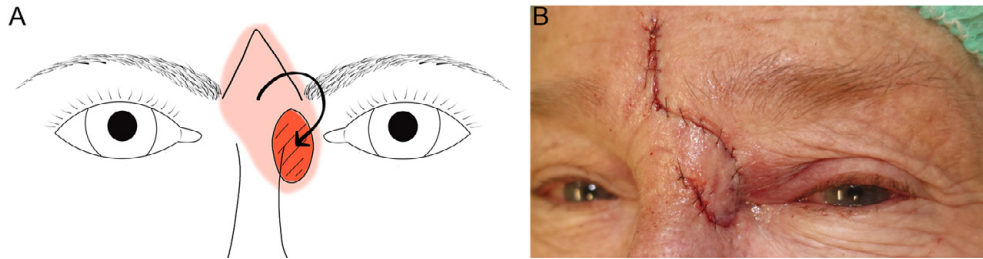


Figure 10. (A) Schematic illustration showing the use of a glabellar flap to cover a defect in the canthal area. (Illustration by Jenny Hult) (B) Photograph showing the glabellar flap sutured into place immediately after surgery.

H-plasty

In Study III, defects resulting from tumor excision in the periocular area were repaired in seven patients using bipedicle random advancement flaps (H-plasty). In the H-plasty procedure the skin on both sides of the defect is incised with two parallel lines creating two flaps. The flaps are not based on a specific vessel, and are therefore considered random. The skin is undermined and the flaps advanced until the leading edges meet, as illustrated in Figure 11. (9, 55) Flaps included skin and underlying orbicular muscle or skin only. As the flaps are stretched and advanced in a linear direction to cover the defect they are considered advancement flaps. In the present study, the median horizontal length of the flaps was 13 mm, and the median vertical width was 10 mm. Perfusion was monitored immediately postoperatively and at three follow-up visits, after approximately 1, 3 and 6 weeks. (Details can be found in Paper III.)

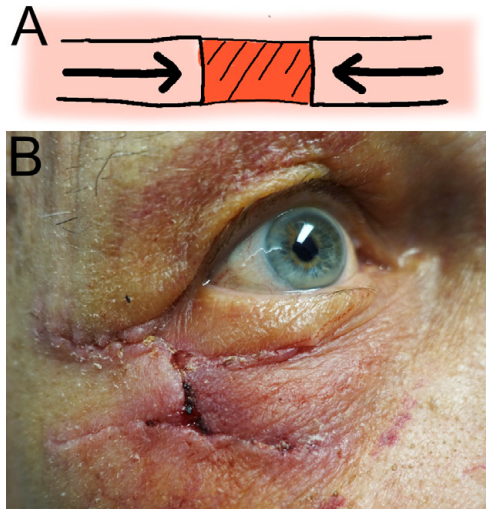


Figure 11. (A) Schematic illustration of the H-plasty procedure. The central defect, shaded red, is covered using two random advancement flaps. (Illustration by Jenny Hult) (B) Photograph of a patient at the 3-week follow-up after the H-plasty procedure.

Full-thickness lower eyelid flaps

Study IV included nine eyelids in eight patients with involitional entropion. All were scheduled for a modified Quickert procedure, a procedure often used for the correction of entropion. (9) The kind of flap used in this procedure has an anatomically recognized arteriovenous system running along its long axis, i.e. the marginal arcade, and could therefore be regarded as an axial flap. This procedure includes a full-thickness transverse lid split just below the tarsal plate, and a vertical incision through the lid 5 mm from the lateral canthus. In this way, a long medially based full-thickness flap is created, as illustrated in Figure 12. This medial flap was used as a model for a lower eyelid flap that can be used, for example, to reconstruct large defects of the upper eyelid (the Mustardé lower lid switch flap). (3, 8, 35, 56) This type of flap can also be stretched in the horizontal direction to repair laterally located full-thickness lower eyelid defects. (8) The median horizontal length of the flaps was 21 mm, the median vertical width was 5 mm, and the median thickness 3 mm. Perfusion was monitored before and after rotating (90° and 120°) and/or stretching (using forces of 0.5, 1 and 2 Newton) the flap. (For a detailed description, see Paper IV.)

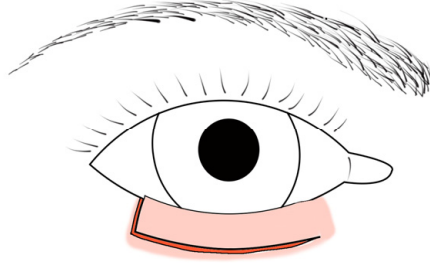


Figure 12. Illustration of the axial lower medial eyelid flap that was rotated and stretched. (Illustration by Jenny Hult)

Free full-thickness skin grafts

Seven patients scheduled for free full-thickness skin grafts due to tumor excision or cicatricial ectropion were included in Study V. Full-thickness skin grafts from the upper eyelid or the upper arm were used (Figure 13). As mentioned above, full-thickness skin grafts include the entire epidermis and dermis, and are entirely detached from the vascular network. Grafts were trimmed and tailored to fit the defects. The grafts measured 10-30 mm horizontally and 9-30 mm vertically, and were used to repair defects on the lower eyelid, the upper eyelid, the median canthal area or the upper cheek. Perfusion was monitored immediately postoperatively, and on three follow-up visits, after approximately 1, 3 and 7 weeks. (For details see Paper V.)

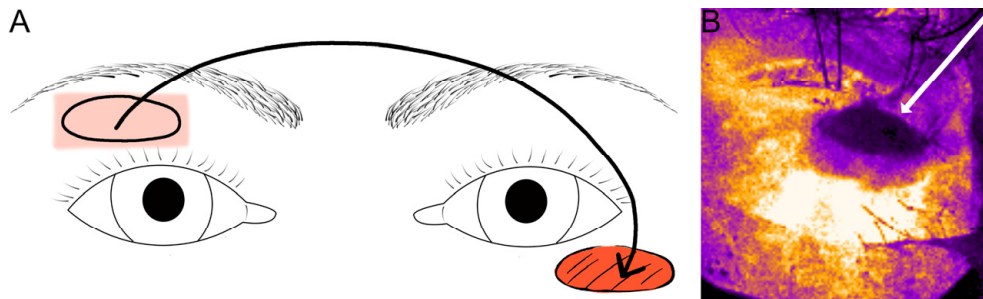


Figure 13. (A) Illustration of the use of full-thickness skin grafts from the upper right eyelid to repair a skin defect close to the left eye. (Illustration by Jenny Hult) (B) LCSl image of a patient receiving a free full-thickness skin graft in the lower eyelid (indicated by the white arrow), imaged immediately postoperatively. It can be seen that the graft has no perfusion immediately after surgery, and appears as a black area.

Results and discussion

Upper eyelid myocutaneous and cutaneous flaps

Study I was performed on patients undergoing blepharoplasty using random flaps on the upper eyelids. In order to create a random myocutaneous flap a flap including underlying orbicularis muscle was dissected. The orbicularis muscle was after that trimmed off in order to obtain a random cutaneous flap. LSCI showed a gradual decrease in perfusion from the base to the tip of the flap, in both the random myocutaneous flaps and the random cutaneous upper eyelid flap (Figure 14A). Perfusion was significantly higher in the random myocutaneous flaps than in the random cutaneous flap. Furthermore, perfusion appeared to be preserved further from the base in the random myocutaneous flaps, than in the random cutaneous flap. This indicates that random myocutaneous flaps could be longer than random cutaneous flaps. Longer flaps compensate for flap contraction during healing, and reduce the need for free full-thickness skin grafts.

The results of Study I are in accordance with previous studies on random porcine flaps, in which higher perfusion and oxygenation were observed in thicker flaps than in thinner flaps (57). The dermal and subdermal vascular plexuses are less affected in random myocutaneous flaps than in random cutaneous flaps, which probably explains the higher perfusion in the former.

Perfusion along the random myocutaneous flaps in Study I decreased in a similar way to that in the random glabellar flaps in Study II (Figure 14B). Both of these kinds of flap are random flaps supplied by the microvascular vascular plexuses. In contrast, perfusion was preserved to a greater extent in the axial full-thickness lower eyelid flaps in Study IV (Figure 14C). This is probably explained by the fact that the full-thickness flap in Study IV was an axial flap perfused by a specific vessel, in this case the marginal arcade, unlike the flaps in Studies I and II which were random patterned.

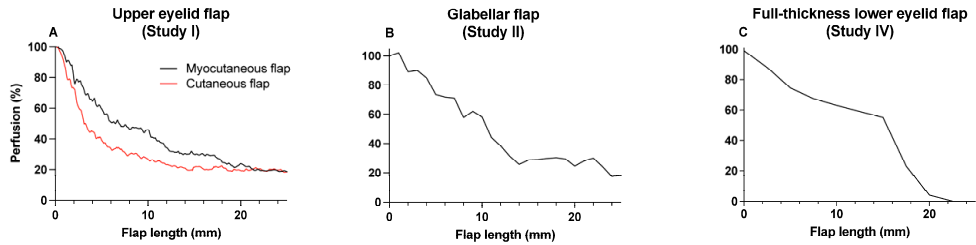


Figure 14. The results of perfusion monitoring with LSCI, showing the gradual decrease in perfusion with flap length, in (A), random upper eyelid myocutaneous and cutaneous flaps (n=14) (Study I), (B) the upper part of random glabellar flaps (n=7) (Study II), and (C) axial full-thickness lower eyelid flaps (n=9) (Study IV). Data are expressed as the median value of the percentage of the perfusion at a reference point in undissected tissue close to the flap base. Note that the perfusion was preserved to a greater extent in the axial flap in Study IV, than in the random pattern flaps in Studies I and II, probably due to blood perfusion from the marginal arcade in the axial flap.

For detailed results and discussion, see Paper I.

Glabellar flaps

Study II was performed on glabellar flaps, which are random flaps, in patients requiring reconstructive surgery after tumor removal in the canthal region. Tissue was mobilized from the area between the eyebrows and rotated into the defect. LSCI was used to analyze perfusion along the length of the glabellar flaps before rotating the flap into position, and was found to decrease in a similar gradual fashion in the upper (Figure 15A blue arrow) and lower (Figure 15A green dashed arrow) parts of the flap. When the flap was rotated and sutured in place a further decrease in perfusion was seen in the upper part of the flap at 14 mm, however, this was not significant. No further decrease was observed in the lower part. The minimum perfusion was recorded 14 and 15 mm from the base in the upper and lower part of the sutured flaps, respectively.

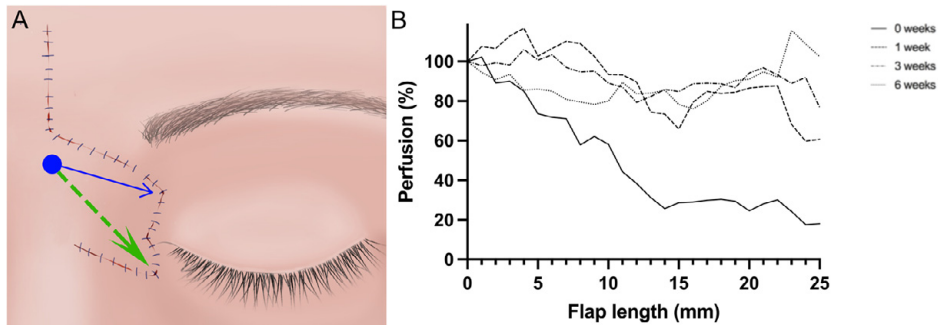


Figure 15. (A) Illustration of a glabellar flap sutured in place. Perfusion was measured along the upper (blue arrow) and lower part of the flap (green dashed arrow). (Illustration by Jenny Hult) (B) Graph showing the gradual change in median perfusion over the length of the upper part of the flap immediately after surgery, and the reperfusion in the flap over time postoperatively. LSCI measurements were performed in 7 flaps. Data are expressed as the median value of the percentage of the perfusion at a reference point in the flap base.

Rapid reperfusion was seen postoperatively and complete restoration of the perfusion was seen in the proximal 20 mm of the upper part of the flap after 1 week (Figure 15B). The distal part of the flap was gradually reperfused, the median value being 91% at 25 mm after 6 weeks. The lower part of the flap showed a similar process of reperfusion.

The random advancement flaps in the H-plasty procedure (Study III) were also found to be fully reperfused within one week of surgery, as in the case of the proximal 20 mm of the upper part of the random glabellar flaps. The random advancement flaps in Study III and the random glabellar flaps in Study II both retained their connection to the circulation via the flap base, explaining the rapid reperfusion. The fast reperfusion seen in Studies II and III is in line with previous studies on reperfusion of other types of reconstructive flaps. (58-60)

In the random glabellar flap procedure, the skin is rotated and stretched in order to cover the medial canthal defect, and the perfusion decreased only slightly after suturing the flap in place. However, it is known from previous studies that manipulation of a flap can impair perfusion. Our group has previously shown that stretching a non-rotated, random upper eyelid flap only affected the perfusion slightly, whereas simply rotating it by 90° had no significant effect on perfusion. However, the combination of rotating (90°) and stretching (2 N) random upper eyelid flaps led to a significant reduction in perfusion 5 mm from the base. (39) This is in accordance with a study on eyelid flaps in a porcine model. (61) The degree of stretching of glabellar flaps was not measured in Study II, but was limited. Greater forces might be needed when using a random glabellar flap to reconstruct defects of the middle and distal parts of the nose, and blood perfusion could be significantly affected. This should be investigated in the future.

For detailed results and discussion, see Paper II.

H-plasty

In Study III, random advancement flaps in a bipedicle, H-plasty procedure were studied in patients with tissue defects after tumor excision. Adjacent tissue was advanced from both sides to cover the defect. LSCI showed relatively well-preserved perfusion in the distal end of random advancement flaps in a bipedicle, H-plasty procedure (54%) per-operatively, which can probably be explained by the fact that the flaps in this study were fairly short (median horizontal length 13 mm). Perfusion was monitored at follow-up visits, and was found to be rapid, being 104% already after one week. Full perfusion was maintained after 3 and 6 weeks (Figure 16A).

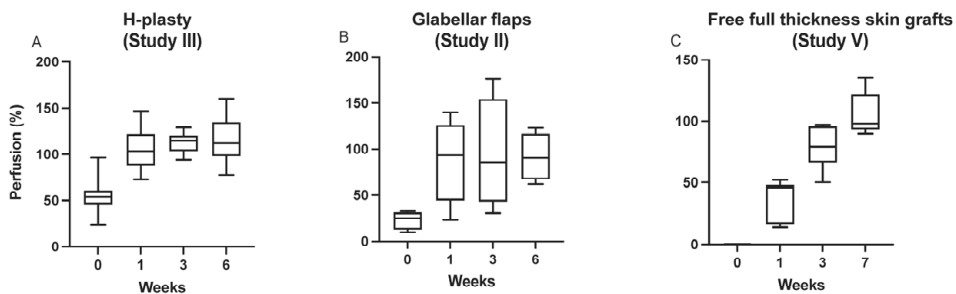


Figure 16. Plots showing the rapid reperfusion of (A) random flaps in the H-plasty procedure and (B) random glabellar flaps. Blood perfusion was monitored using LSCI immediately postoperatively (0 weeks), and at follow-up after 1, 3, and 6 weeks. Data are expressed as the percentage (median values and quartiles) of the perfusion in a reference area near the base of the flap. The median length of the flaps in H-plasty was 13 mm (range 8-20 mm) and reperfusion was measured in the distal end of these flaps. The reperfusion in the glabellar flaps was measured in the upper part of the flap, 20 mm from the base. (C) Plot showing the slower reperfusion in the central part of the free skin grafts, immediately postoperatively (0 weeks), and at follow-up after 1, 3, and 7 weeks. Data are expressed as the percentage (median values and quartiles) after normalization to the perfusion at a reference point just outside the grafts (100%).

The results of Study III are in line with the fast reperfusion of the random glabellar flaps observed in Study II, in which reperfusion occurred mainly within the first week in the proximal part of the flap (Figure 16B). The rapid reperfusion observed in in Studies II and III can probably be explained by the pedicle of the flap being connected to the circulation. The process of reperfusion in free full-thickness skin grafts (Study V) was found to be slower than in the flaps in Studies II and III, being fully reperfused after 7 weeks (Figure 16C).

The process of revascularization of flaps has been studied by others, mainly in animal models. Young et al. reported rapid revascularization of pedicle skin flaps in pigs by injecting disulphine blue. (60) New vascular connections were observed between the distal part of flap and the surrounding tissue 3-4 days postoperatively. After 7-10 days, a collateral vascular supply had been formed in the whole flap. This is in line with the findings of Cumming et al., who used laser Doppler flowmetry (LDF) and dermofluorometry to study perfusion in panniculus carnosus myocutaneous flaps in a porcine model. (58) They concluded that the perfusion of the flap was sufficient for survival without the pedicle 7-10 days postoperatively. Tsur et al. found the revascularization to be sufficient for axial flap survival after 6-7 days in a rat model, and after 4-5 days in a porcine model. (59) The results of Study III show that random advancement flaps in H-plasty procedures are reperfused quickly in the periocular area, making it a reliable reconstructive procedure.

For detailed results and discussion, see Paper III.

Full-thickness lower eyelid flaps

Study IV was performed on axial flaps. Full-thickness flaps were dissected in the lower eyelid as part of a modified Quickert procedure to correct entropion. The perfusion in these axial medial-anchored lower eyelid flaps was also monitored when the flap was stretched and/or rotated. This kind of flap can be considered an axial flap since it is perfused by an anatomically recognized arteriovenous system, in this case the marginal arcade. LSCI showed that blood perfusion decreased from the base to the tip of the axial full-thickness lower eyelid flaps, being almost half of the reference value 15 mm from the base (55%) (Study IV). Further than 15 mm from the flap base, the perfusion was minimal (Figure 14C), indicating that 15 mm is probably the maximum length of an axial full-thickness lower eyelid flap, to retain perfusion, especially as it was found that stretching reduced perfusion even further (Figure 17A). Survival of such flaps beyond this point might be due to the passive diffusion of oxygen and nutrients. Free full-thickness eyelid grafts have been used successfully to repair both upper and lower eyelid defects. (62)

Rotation of the axial full-thickness flaps by 90° and 120° had little effect on perfusion (Figure 17B). This is in agreement with the observation of no significant effect on perfusion when random glabellar flaps were rotated (Study II). Perfusion 10 mm from the flap base in unrotated flaps subjected to a limited force (0.5-1 N) caused a non-significant decrease in perfusion. However, when subjected to a higher force (2 N), the perfusion decreased significantly (Figure 17B).

Stretching an already rotated axial full-thickness flap with a limited force (0.5-1 N) did not influence the perfusion significantly when measured 10 mm from the flap base. When applying a force of 2 N, the perfusion was significantly decreased in both unrotated and rotated axial flaps (Figure 17B).

For detailed results and discussion, see Paper IV.

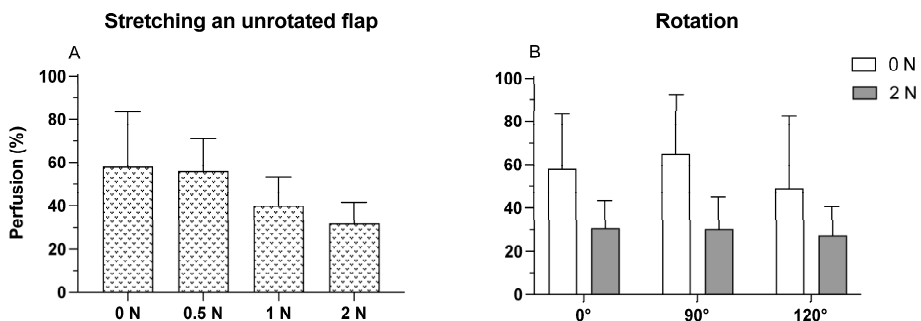


Figure 17. Plots showing the effect on the blood perfusion 10 mm from the base in axial full-thickness eyelid flaps when (A) unrotated flaps were stretched by 0.5, 1 and 2 N and (B) rotated flaps (90° and 120°) were stretched by 2 N. Data are given as medians. Error bars represent 75% percentiles. Stretching the flaps significantly reduced the perfusion, while simply rotating the flaps had little effect on the perfusion.

Perfusion in these axial full-thickness eyelid flaps was found to be better preserved in the proximal 15 mm than in random myocutaneous flaps (Study I) (Figure 14). The fact that an axial flap is based on a specific vessel can explain this.

It has previously been found that perfusion in random skin flaps in a porcine model decreased significantly when the flap was manipulated by stretching and/or rotating it 90° (61). This could probably be explained by differences in the structure of porcine and human skin.

Free full-thickness skin grafts

LSCI was used to monitor the reperfusion of free full-thickness skin grafts in patients (Study V). In contrast to the flaps investigated in the previous studies (I-IV) skin grafts have no connection to the vascular network. LSCI showed that the free skin grafts were rapidly reperfused, and after one week, the perfusion measured in the central part of the graft was 46% of that in the surrounding tissue (Figure 16C). Complete reperfusion was seen in all grafts after seven weeks. However, in two cases, the grafts were fully reperfused after three weeks. The reperfusion rate of the center and the periphery of the graft did not differ significantly. This could indicate that the entire graft is revascularized from the underlying wound bed, but the grafts in this study were fairly small, and different results might have been obtained if the grafts had been larger.

Free full-thickness skin grafts lack a connection to the circulation, and reperfusion will depend on angiogenesis throughout the graft. With this in mind, it is hardly surprising that the reperfusion of full-thickness skin grafts is slower than that in the flaps investigated in Studies II and III, where the flaps were connected to the circulation (Figure 16). The distal part of random glabellar flaps, i.e. beyond 20 mm, was reperfused after 6 weeks (Study II). Reperfusion of a free skin graft thus follows the same pattern as reperfusion of the glabellar flap tip, presumably through angiogenesis.

In a previous study, where the reperfusion of free skin grafts overlying a tarsoconjunctival flap in the modified Hughes procedure was monitored, our group found that it took eight weeks for the grafts to become fully reperfused. (41) Previous perfusion monitoring has shown that the perfusion in the tarsoconjunctival flap is virtually nonexistent. (63) It was speculated that the lack of perfusion is compensated for by the rich vascularization of the periocular area, and the fact that the grafts are soaked in tear fluid, which has a similar spectrum of nutrients to the blood. (64) This might explain why a graft applied to a nonvascularized tissue elsewhere in the body, such as bone without periosteum, does not survive. (65-67)

Rapid reperfusion of free full-thickness skin grafts has been reported previously. In 1956, Converse and Rapaport observed sluggish flow in the vessels of full-thickness

grafts placed on the radial aspect of the volar surface of the forearm in humans three days after surgery. (68) In 1960, Ohmori and Kurata demonstrated the uptake of intravenous injections of radioisotopes in free skin grafts in a rabbit model 4 days postoperatively. (69) Clemmens and Ronhovde noted vessels connected to the original vessels in biopsies three days after skin grafting in humans in 1968. (70) In a histological study from 2006, Capla et al. observed vessels growing in the periphery of full-thickness grafts in a mouse model after three days. (71) In a more recent study in a mouse model Lindenblatt et al. used intravital microscopy and found capillary buds and sprouts after two days, and graft capillaries containing blood after three days. (72) However, differences between the vascular systems in animal models and humans complicate comparisons with humans.

For detailed results and discussion, see Paper V.

Conclusions and future perspectives

The surgical procedures

This dissertation presents the findings of studies on the perfusion and reperfusion of flaps with different designs with different anatomical architectures, and free skin grafts.

Study I showed that blood perfusion was better preserved in random myocutaneous flaps, including both skin and the orbicularis oculi muscle, than in random cutaneous flaps. This may be of clinical interest in patients with poor microcirculation in which a long flap is required for reconstructive surgery.

In Study II, the rapid reperfusion of the proximal part of random glabellar flaps may be explained by their connection to the vascular network via the flap pedicle. In flaps longer than 20 mm, the distal part can be considered a free skin graft, and a combination of a random glabellar flap and a free skin graft could then be considered. In this study, the random glabellar flaps included only skin, as in the case of the random cutaneous flaps in Study I. In both types of flaps (Studies I and II) perfusion decreased gradually with increasing distance from the flap base, but the decrease was less rapid in glabellar flaps (Study II) than in the other kind of flap (Study I). This could be due to the greater thickness of skin in the random glabellar flaps, stabilizing and protecting the vascular anatomy to a greater extent.

Study III showed that reperfusion following the use of random advancement flaps in the H-plasty procedure took place quickly, within a week postoperatively, presumably due to the vascular network in the flap pedicle. This perfusion study confirms the general opinion that H-plasty is a good reconstructive technique, especially in the periorbital region with its rich vascular supply. The random advancement flaps in Study III resemble the random advancement flaps in Study I, but unlike Study I, which was a model for reconstruction, an established surgical procedure was used. Perfusion along the flaps was not investigated in this study since these are often short and well perfused, instead reperfusion was the main focus.

The findings of Study IV indicated that blood perfusion in lower eyelid axial full-thickness flaps seemed to be more sensitive to stretching than to rotation. Provided the flap is no longer than 10 mm, the perfusion will be greater than 20%, even when rotated and stretched, which should be sufficient for adequate survival and healing

in the periocular region. Furthermore, in Study II the perfusion of the glabellar flaps only decreased slightly after rotating and suturing the flap into place.

The perfusion was better preserved in the proximal 15 mm of the axial full-thickness flaps (Study IV) than in the flaps studied in Studies I and II. This can be explained by the full-thickness design, with preserved blood vessels, including part of the marginal arcade. With this in mind, this thicker type of flap could be made longer, as concluded from Study I, where it was shown that the perfusion was less effected in thick random myocutaneous flaps than in thin random cutaneous flaps. As in the case of Study I, this was a model for a frequently used reconstruction technique studied during a Quickert procedure to correct eyelid malposition.

A full-thickness lower eyelid flap, like the ones studied in Study IV, can be used to repair large defects in the upper eyelid. The pedicle is typically divided after up to 6 weeks. (35) Monitoring the reperfusion of this type of flap using LSCI would be of great interest in order to evaluate the optimal time for division of the pedicle.

Study V showed that free full-thickness skin grafts in the periocular area were fully reperfused after seven weeks. The reperfusion of these skin grafts is slower than that in the flaps in Studies II and III, probably because there are no intact vessels in the transplanted tissue. The periocular area is known to be well-vascularized and thus forgiving to reconstructive surgery. It would be interesting to study the reperfusion of full-thickness skin grafts on other parts of the body that are less well perfused.

The main limitation of the studies presented in this dissertation is the limited number of participants, which did not allow subgroup analyses. Therefore, factors known to affect blood perfusion and compromise the oxygenation of tissue, such as smoking, diabetes, previous surgery, or radiation therapy, could not be taken into account. Another limitation of Studies II, III and V is that perfusion measurements could not be made on a daily basis, as this was impractical. The studies were conducted at an outpatient clinic, and many of the patients had to travel far to attend follow-up visits.

Perfusion monitoring

LSCI could easily be implemented in clinical routine in reconstructive surgery, since it is non-invasive, and the measurements are not very time-consuming. However, problems associated with motion artifacts must first be overcome. Methods of, at least partially, overcoming these, such as shorter sampling times (73) or simultaneously recording the signal backscattered from an adjacent opaque surface, have been suggested. (74) LSCI monitoring would be particularly important in flaps or grafts at risk of failure, i.e. when the geometry or size of the flap indicates a risk of poor perfusion, or when the patient has poor microcirculation, as in the case of diabetics or smokers. If graft failure could be identified early, timely revision could be carried out to optimize the healing process. LSCI could be used to assess

flap perfusion, maybe allowing the pedicle to be cut earlier in procedures such as the Tagliacozzi flap and the paramedical flap procedures, where the pedicle is usually cut after 3 weeks, when revascularization of the mobilized tissue is deemed to be adequate.

Our group has recently started to investigate hyperspectral imaging (HSI) in the periocular region. This is a non-invasive technique providing spatial maps of oxygen saturation of the skin using a white incandescent light source (broad spectrum). The reflected light is processed to extract a map of spatially resolved reflectance spectra (Figure 18). Hyperspectral imaging has been used to map oxygen saturation in skin flaps, arms, and legs (75, 76), but our recently accepted study is, to the best of our knowledge, the first in which the technique was applied to the periocular area (77). The simultaneous use of LSCI and HSI might be an advantage, since it allows direct comparison of perfusion and oxygenation in the same patient.

Measurements of tissue perfusion using LSCI could also be useful in the diagnosis of other conditions, and as a prognostic tool, both per- and postoperatively. Further studies will hopefully improve our understanding of physiological processes. Further perfusion monitoring will hopefully lead to improved surgical outcome following different procedures, and perhaps even the development of new ones. It may also aid the surgeon in choosing the best procedure, bearing in mind specific patient's characteristics, allowing a tailor-made surgical strategy.

A detailed survey of the relevant scientific literature, and a discussion of blood perfusion monitoring in the periocular area, can be found in the review appended to this dissertation.

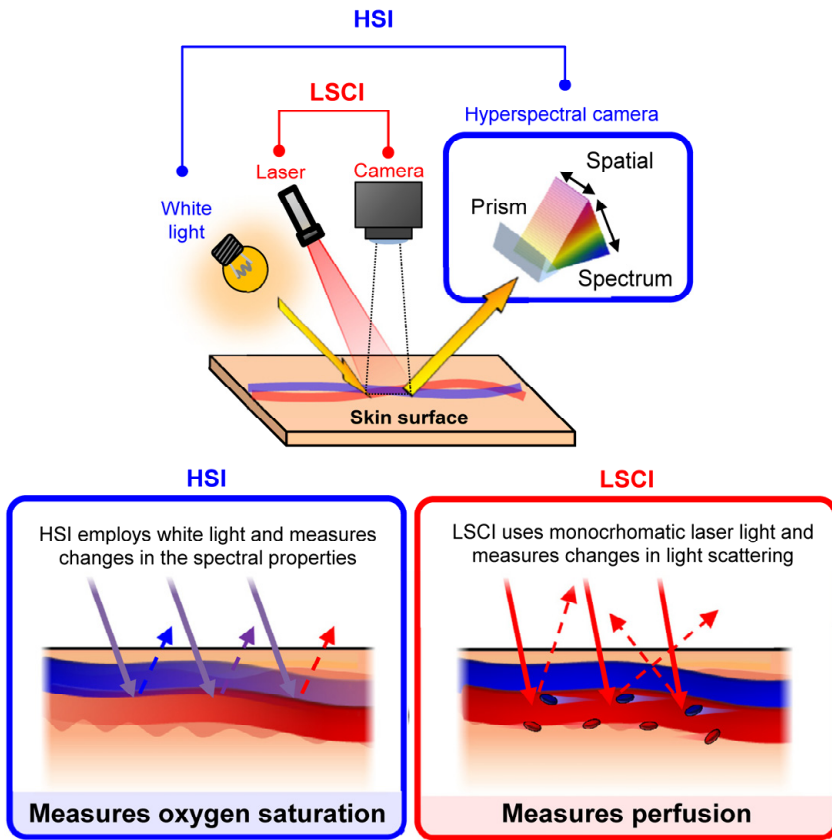


Figure 18. Illustration showing how hyperspectral imaging (HSI) and laser speckle contrast imaging (LSCI) complement each other, the former by monitoring saturation and the latter perfusion during reconstructive surgery. (Illustration by Aboma Merdasa)

Populärvetenskaplig sammanfattning

Vi blir allt äldre i Sverige och hudcancer som exempelvis basalcellscancer, som är den vanligaste formen av hudcancer, blir allt vanligare. Den vanligaste behandlingen är skära bort tumören, men vävnaden runt ögonen är begränsad på ett helt annat sätt än på andra ställen på kroppen. Att kirurgisk avlägsna en tumör på ögonlocket ställer helt andra krav på kirurgen än att avlägsna samma tumör där det finns mer överskottsvävnad och kraven på funktion och estetik inte är lika höga.

För att ”laga” de ”hål” som uppkommer då tumörerna tas bort använder kirurger olika mer eller mindre avancerade knep. Framför allt om hålet är stort kan det vara en utmaning för kirurgen, som kan behöva låna hud från andra kroppsdelar eller angränsande områden. För att denna lånade vävnad ska överleva är blodcirkulationen särskilt viktig. Baserat på kirurgisk erfarenhet och tradition har det genom årens lopp formulerats olika regler för kirurgen att följa för att operationen ska lyckas. För att den lånade vävnaden ska överleva på det nya stället måste blodcirkulationen vara tillräcklig, något som tidigare varit omöjligt att mäta. Nya avbildningstekniker har nu gjort det möjligt att studera detta och många av de gamla, icke-vetenskapliga antaganden och myterna inom kirurgin har börjat att ifrågasättas.

I denna avhandling studeras blodflödet med hjälp av laserbaserad avbildningsteknik (Laser speckle contrast imaging, LSCI). Syftet är att kartlägga hur blodflödet ändras vid och efter kirurgin. Till exempel, hur påverkas blodflödet i den ”lånade” huden när den roteras eller sträcks för att laga ”hålet” efter tumören.

Laser speckle contrast imaging mäter rörelse i vävnaden med infrarött laserljus som reflekteras tillbaka. Den reflekterade signalen ändras när de cirkulerande röda blodkropparna rör sig i hudens blodkärl och på så sätt kan blodflödet mätas. En utmaning med metoden är att den är känslig för all rörelse, och det kan vara svårt att avgöra hur mycket av signalen som orsakas av blodkropparnas rörelse eller av till exempel vibrationer och muskulära rörelser.

Blodcirkulationen har studerats vid fem olika kirurgiska ingrepp som kan bli aktuella efter att tumörer avlägsnats i ögonnära hud: övre ögonlockslambåer (Studie I), glabellalambåer (Studie II), H-plastiker (Studie III), rotationslambåer (Studie IV) och fria fullhudstransplantat (Studie V). Studie I-IV undersöker således blodcirkulationen i hudbryggor (lambåer) och Studie V undersöker cirkulationen i fria hudbitar (transplantat).

I samtliga Studier har patienter på ögonkliniken på Skånes Universitetssjukhus och i Studie I även på Centrallasaretet i Växjö inkluderats efter att de lämnat sitt muntliga och skriftliga samtycke. Mätningar har gjorts direkt vid operation (Studie I-V) och sedan vid återbesöken på mottagningen (Studie II, III och V) för att följa hur blodcirkulationen återhämtar sig.

I Studie I studerades cirkulationen i tunna (enbart hud) och tjocka (hud och muskel) hudbryggor (lambåer) i övre ögonlocket. Cirkulationen var betydligt högre i de tjocka bryggorna jämfört med de tunna och cirkulationen kvarstod längre ut i bryggan i de tjocka bryggorna.

I Studie II studerades så kallade glabellalambåer, dvs hudbryggor som lossats från området mellan ögonbrynen och sedan roteras ned för att laga "hål" vid ögonvrån. Vid mätning under operation noterades att cirkulationen sjönk gradvis från bryggans bas. Cirkulationen i de första 20 mm av bryggan var helt återställd efter en vecka, medan det tog 6 veckor innan den återställdes i resten av bryggan.

I Studie III studerades så kallad H-plastik, vilket innebär att två hudbryggor dras in från motsatta sidorna om "hålet" som ska täckas. Direkt efter operationen minskade cirkulationen till 54% av referensvärdet. Blodcirkulationen ökade sedan snabbt och redan efter en vecka var den helt återställd.

I Studie IV studerades cirkulationen i genomgripande hudbryggor i nedre ögonlocket. När dessa bryggor används inom rekonstruktiv kirurgi sträcks och/eller roteras de ofta för att laga "hål". Även här sjönk cirkulationen från början av bryggan till spetsen. Rotation av hudbryggan med 90° och 120° hade begränsad effekt på cirkulationen. Att däremot sträcka hudbryggan hade betydligt större effekt på cirkulationen som då minskade betydligt.

I Studie V lossades hud (transplantat) helt från en annan region (från ögonlocket eller armen) och flyttades till "hålet" som skulle repareras. Direkt efter operationen var det således ingen blodcirkulation i hudtransplantaten. Cirkulationen återkom sedan successivt och var helt återställd efter 7 veckor.

Den kunskap som framkommit i Studie I-V bidrar till att vi lärt oss mer om hur blodförsörjningen påverkas av kirurgi och hur blodförsörjningen utvecklas under läkningsförloppet i området runt ögonen. Förhoppningen är att detta ska leda till utveckling av nya kirurgiska metoder och att befintliga metoder optimeras.

Acknowledgements

There are so many people I want to thank, and too little space to mention them all here. This work would not have been possible without any of you. I have had the privilege to be part of a wonderful and very supportive research group, and would especially like to thank the following people.

Malin Malmsjö – I could not have wished for a more positive, inspiring and energetic main supervisor. She is always available to give help and advice. She is an inspiration to all researchers.

Karl Engelsberg – My co-supervisor and mentor, always ready to help. A great surgeon always available for support and good advice. The world would be a much better place with more people like him in it.

Sandra Lindstedt Ingemansson – My other co-supervisor, who was a great inspiration to me.

Rafi Sheikh – a.k.a. Mr. Speckle, the master of LSCI. I have so much to thank you for.

Jonas Blohmé – A legend within the field of oculoplastic and strabismus surgery. Super power: “Flytta små muskler. Lite.”

Kajsa Tenland – Thank you for making this research process so much fun, and for all our interesting discussions. I’m looking forward to our future collaboration.

Ulf Dahlstand – a fast-rising star in oculoplastic and strabismus surgery, who knows just about everything except the Oromo language. I’m looking forward to working with you in the future.

Jenny Hult – for her fantastic illustrations, and for always offering to help. She never ceases to impress me, and is always a pleasure to work with. I’m sure she will make important contributions to the field of corneal surgery.

Cu Dybelius Anson – for all our interesting collaborations and discussions and his help.

Björn Hammar – for always being ready to help, whether it was to identify a tricky vessel, to figure out the nature of a swelling of the optic nerve, or to prepare a public defense of doctoral dissertation.

John Albinsson – engineer in the research group, thank you for all your assistance and patience, and for always being ready to help with a friendly smile.

Aboma Merdasa, engineer in the research group, thank you for helping me understand light and different imaging techniques on a deeper level, and for your parables that even I could relate to.

Bodil Gesslein – Thank you for all your help with the financial side of my research, and for our friendly chats.

Josefine Bunke – oculo-plastic colleague and researcher from Växjö. Thank you for all our interesting talks and lunch meetings. A special thanks to Pernilla Rosenquist and all the surgical staff involved at the Department of Ophthalmology at the Central Hospital Växjö.

Khashayar Memarzadeh – great corneal surgeon and former member of the research group. Thank you for all your advice and help.

Nazia Castelo – for always offering to help and being so positive.

Magne Tordengren – one of the newest members of the research group with great enthusiasm; I'm looking forward to future collaborations.

Magdalena Naumovska – for always being there to help and offering a friendly chat.

The staff on Ward 40 and at the Departments of Eye Surgery in Lund and Malmö, and the heads of department, Birgit Drott and Annika Creutz – for all their help and patience during these studies. This work would not have been possible without you. A special thanks to Maria Schalén.

Lena Rung, Kristina Johansson, Sten Kjellström, Anette Lindström, Anders Bergström and Vesna Ponjavic – for making it possible for me to pursue my PhD studies alongside my clinical work and specialization, and for creating such a great research environment and for facilitating my research during surgery.

Anna Dahlgren – for introducing me to the world of oculo-plastic surgery, for all her support, and for making me believe in my own capacity. She is such a great teacher.

Helen Sheppard – for her invaluable help with the language. She has taught me so much.

Christina Rosdahl – surgery coordinator, for being flexible when scheduling surgery, and for always being willing to assist in planning research projects.

All my amazing colleagues and the staff at the Department – who made it all worthwhile.

Pia Weibull – for babysitting Frank and Olof and for being a truly supportive friend; we miss having you as a neighbor.

Britt-Marie and Lars – my parents-in-law, for helping out with Olof and Liv, and for traveling to Stockholm in 2018 so that I could attend a cataract course and finish my residency when Olof was only three months old.

Helena and Johan – my sister and brother, some of the brightest and kindest persons I know.

Birgitta och Anders – my mother and father, for always believing in me. You are my greatest inspiration in life.

Olof and Liv – my amazing children, for being you.

Jonny – for all your love and support and, but above all, your patience.

References

1. Bernstein SC, Lim KK, Brodland DG, Heidelberg KA. The many faces of squamous cell carcinoma. *Dermatol Surg.* 1996;22(3):243-54.
2. Gloster HMJr, Brodland DG. The epidemiology of skin cancer. *Dermatol Surg.* 1996;22(3):217-26.
3. Ferguson NM, Mathijssen IM, Hofer SO, Mureau MA. Decision making in reconstruction of defects of the eyelid. *J Plast Surg Hand Surg.* 2011;45(1):45-50.
4. Barr J. Vascular medicine and surgery in ancient Egypt. *J Vasc Surg.* 2014;60(1):260-3.
5. Ellis H, Abdalla S. *A History of Surgery.* . Third edit. ed: CRC Press.
6. Mazzola IC, Mazzola RF. History of reconstructive rhinoplasty. *Facial Plast Surg.* 2014;30(3):227-36.
7. Gilies H. *Plastic surgery of the face:* Hodder and Stoughton; 1920.
8. Codner MA, McCord CD, Mejia JD, Lalonde D. Upper and lower eyelid reconstruction. *Plast Reconstr Surg.* 2010;126(5):231e-45e.
9. Collin J. *A Manual of Systematic Eyelid Surgery.* 3 ed. Philadelphia, PA: Elsevier Inc.; 2006.
10. Erdogmus S, Govsa F. The arterial anatomy of the eyelid: importance for reconstructive and aesthetic surgery. *J Plast Reconstr Aesthet Surg.* 2007;60(3):241-5.
11. Ghosh SK. Human cadaveric dissection: a historical account from ancient Greece to the modern era. *Anat Cell Biol.* 2015;48(3):153-69.
12. Braverman IM. The cutaneous microcirculation. *J Investig Dermatol Symp Proc.* 2000;5(1):3-9.
13. Levick JR. *An introduction to cardiovascular physiology.* London: Hodder Arnold; 2010.
14. Reid L, Meyrick B. Microcirculation: definition and organization at tissue level. *Ann N Y Acad Sci.* 1982;384:3-20.
15. Charkoudian N. Skin blood flow in adult human thermoregulation: how it works, when it does not, and why. *Mayo Clin Proc.* 2003;78(5):603-12.
16. Patel KG, Sykes J. Concepts in local flap design and classification. *Operative Techniques in Otolaryngology-head and Neck Surgery.* 2011;22:13-23.
17. Rorsman H, Björnberg A, Vahlquist A. *Dermatologi Venerologi: Studentlitteratur;* 2007.
18. Heistad DD, Abboud FM. Factors that influence blood flow in skeletal muscle and skin. *Anesthesiology.* 1974;41(2):139-56.

19. Sloan GM, Reinisch JF. Flap physiology and the prediction of flap viability. *Hand Clin.* 1985;1(4):609-19.
20. McCord CD, Codner MA. Classical surgical eyelid anatomy. In: McCord CD, Codner MA, eds. *Eyelid and Periorbital Surgery*. St. Louis: Quality Medical; 2008.
21. Simman R. Wound closure and the reconstructive ladder in plastic surgery. *J Am Col Certif Wound Spec.* 2009;1(1):6-11.
22. Gottlieb LJ, Krieger LM. From the reconstructive ladder to the reconstructive elevator. *Plast Reconstr Surg.* 1994;93(7):1503-4.
23. Brown JB, Fryer MP. Carcinoma of eyelids and canthal region. *Geriatrics.* 1957;12(3):181-4.
24. DaCosta J, Oworu O, Jones CA. Laissez-faire: how far can you go? *Orbit.* 2009;28(1):12-5.
25. Thaller VT, Madge SN, Chan W, Vujic I, Jazayeri F. Direct eyelid defect closure: a prospective study of functional and aesthetic outcomes. *Eye (Lond).* 2019;33(9):1393-401.
26. Thaller VT, Vahdani K. The magic suture in periocular reconstruction. *Eye (Lond).* 2020.
27. Yesensky J, Lebo N. Reconstructive options following orbital exenteration. *Curr Opin Otolaryngol Head Neck Surg.* 2020;28(5):352-4.
28. Becker FF. Local tissue flaps in reconstructive facial plastic surgery. *South Med J.* 1977;70(6):677-80.
29. Onishi K, Maruyama Y, Okada E, Ogino A. Medial canthal reconstruction with glabellar combined Rintala flaps. *Plast Reconstr Surg.* 2007;119(2):537-41.
30. Mustardé JC. Surgery of the medial canthus. In: Mustardé JC, editor. *Repair and reconstruction in the orbital region.* . 3 ed. Edinburgh: Churchill Livingstone; 1991.
31. Baker SR. Regional flaps in facial reconstruction. *Otolaryngol Clin North Am.* 1990;23(5):925-46.
32. Angrigiani C, Grilli D. Total face reconstruction with one free flap. *Plast Reconstr Surg.* 1997;99(6):1566-75.
33. McGregor IA, Morgan G. Axial and random pattern flaps. *Br J Plast Surg.* 1973;26(3):202-13.
34. Patrinely JR, Marines HM, Anderson RL. Skin flaps in periorbital reconstruction. *Surv Ophthalmol.* 1987;31(4):249-61.
35. Mustardé JC. Eyelid reconstruction,. *Orbit.* 1982;1(1):33-43.
36. Pickard A, Karlen W, Ansermino JM. Capillary refill time: is it still a useful clinical sign? *Anesth Analg.* 2011;113(1):120-3.
37. Maiman TH. Stimulated Optical Radiation in Ruby. *Nature.* 1960;187(4736):493-4.
38. Heeman W, Steenbergen W, van Dam G, Boerma EC. Clinical applications of laser speckle contrast imaging: a review. *J Biomed Opt.* 2019;24(8):1-11.
39. Ansson CD, Berggren JV, Tenland K, Sheikh R, Hult J, Dahlstrand U, et al. Perfusion in Upper Eyelid Flaps: Effects of Rotation and Stretching Measured With Laser Speckle Contrast Imaging in Patients. *Ophthalmic Plast Reconstr Surg.* 2020.

40. Ansson CD, Sheikh R, Dahlstrand U, Hult J, Lindstedt S, Malmsjo M. Blood perfusion in Hewes tarsoconjunctival flaps in pigs measured by laser speckle contrast imaging. *JPRAS Open*. 2018;18:98-103.
41. Berggren J, Tenland K, Ansson CD, Dahlstrand U, Sheikh R, Hult J, et al. Revascularization of Free Skin Grafts Overlying Modified Hughes Tarsoconjunctival Flaps Monitored Using Laser-Based Techniques. *Ophthalmic Plast Reconstr Surg*. 2019;35(4):378-82.
42. Mirdell R, Farnebo S, Sjoberg F, Tesselaar E. Accuracy of laser speckle contrast imaging in the assessment of pediatric scald wounds. *Burns*. 2018;44(1):90-8.
43. Basak K, Dey G, Mahadevappa M, Mandal M, Sheet D, Dutta PK. Learning of speckle statistics for in vivo and noninvasive characterization of cutaneous wound regions using laser speckle contrast imaging. *Microvasc Res*. 2016;107:6-16.
44. Holowatz LA, Thompson-Torgerson CS, Kenney WL. The human cutaneous circulation as a model of generalized microvascular function. *J Appl Physiol* (1985). 2008;105(1):370-2.
45. Mahe G, Humeau-Heurtier A, Durand S, Leftheriotis G, Abraham P. Assessment of skin microvascular function and dysfunction with laser speckle contrast imaging. *Circ Cardiovasc Imaging*. 2012;5(1):155-63.
46. Davis MA, Kazmi SM, Dunn AK. Imaging depth and multiple scattering in laser speckle contrast imaging. *J Biomed Opt*. 2014;19(8):086001.
47. Boas DA, Dunn AK. Laser speckle contrast imaging in biomedical optics. *J Biomed Opt*. 2010;15(1):011109.
48. Briers JD, Webster S. Laser speckle contrast analysis (LASCA): a non-scanning, full-field technique for monitoring capillary blood flow. *J Biomed Opt*. 1996;1(2):174-9.
49. Humeau-Heurtier A, Abraham P, Mahe G. Linguistic Analysis of Laser Speckle Contrast Images Recorded at Rest and During Biological Zero: Comparison With Laser Doppler Flowmetry Data. *IEEE Trans Med Imaging*. 2013;32(12):2311-21.
50. Binzoni T, Tchernin D, Richiardi J, Van De Ville D, Hyacinthe JN. Haemodynamic responses to temperature changes of human skeletal muscle studied by laser-Doppler flowmetry. *Physiol Meas*. 2012;33(7):1181-97.
51. Kernick DP, Tooke JE, Shore AC. The biological zero signal in laser Doppler fluximetry - origins and practical implications. *Pflugers Arch*. 1999;437(4):624-31.
52. WMA. Declaration of Helsinki - Ethical Principles for Medical Research Involving Human Subjects [Available from: <https://www.wma.net/policies-post/wma-declaration-of-helsinki-ethical-principles-for-medical-research-involving-human-subjects/>].
53. Bargman H. Laser classification systems. *J Clin Aesthet Dermatol*. 2010;3(10):19-20.
54. Maloof AJ, Leatherbarrow B. The glabellar flap dissected. *Eye (Lond)*. 2000;14 (Pt 4):597-605.
55. Petres J, Rompel R, Robins P. *Dermatologic surgery*: Springer Science & Business Media; 2012.
56. O'Donnell BA, Mannor GE. Oculoplastic surgery for upper eyelid reconstruction after cutaneous carcinoma. *Int Ophthalmol Clin*. 2009;49(4):157-72.

57. Memarzadeh K, Sheikh R, Blohme J, Torbrand C, Malmsjo M. Perfusion and Oxygenation of Random Advancement Skin Flaps Depend More on the Length and Thickness of the Flap Than on the Width to Length Ratio. *Eplasty*. 2016;16:e12.
58. Cummings CW, Trachy RE. Measurement of alternative blood flow in the porcine panniculus carnosus myocutaneous flap. *Arch Otolaryngol*. 1985;111(9):598-600.
59. Tsur H, Daniller A, Strauch B. Neovascularization of skin flaps: route and timing. *Plast Reconstr Surg*. 1980;66(1):85-90.
60. Young CM. The revascularization of pedicle skin flaps in pigs: a functional and morphologic study. *Plast Reconstr Surg*. 1982;70(4):455-64.
61. Nguyen CD, Sheikh R, Dahlstrand U, Lindstedt S, Malmsjo M. Investigation of blood perfusion by laser speckle contrast imaging in stretched and rotated skin flaps in a porcine model. *J Plast Reconstr Aesthet Surg*. 2018;71(4):611-3.
62. Tenland K, Berggren J, Engelsberg K, Bohman E, Dahlstrand U, Castelo N, et al. Successful Free Bilamellar Eyelid Grafts for the Repair of Upper and Lower Eyelid Defects in Patients and Laser Speckle Contrast Imaging of Revascularization. *Ophthalmic Plast Reconstr Surg*. 2021;37(2):168-72.
63. Tenland K, Memarzadeh K, Berggren J, Nguyen CD, Dahlstrand U, Hult J, et al. Perfusion Monitoring Shows Minimal Blood Flow From the Flap Pedicle to the Tarsconjunctival Flap. *Ophthalmic Plast Reconstr Surg*. 2019;35(4):346-9.
64. Jalbert I. Diet, nutraceuticals and the tear film. *Exp Eye Res*. 2013;117:138-46.
65. Flowers RS. Unexpected postoperative problems in skin grafting. *Surg Clin North Am*. 1970;50(439-456).
66. Peer LA. *Transplantation of Tissues*. Baltimore: Williams & Wilkins; 1955.
67. Thornton JF, Gosman AA. Skin grafts and skin substitutes and principles of flaps. *Sel Read Plast Surg*. 2004;10:15-60.
68. Converse JM, Rapaport FT. The vascularization of skin autografts and homografts; an experimental study in man. *Ann Surg*. 1956;143(3):306-15.
69. Ohmori S, Kurata K. Experimental studies on the blood supply to various types of skin grafts in rabbits using isotope P32. *Plast Reconstr Surg Transplant Bull*. 1960;25:547-55.
70. Clemmesen T, Ronhovde DA. Restoration of the blood-supply to human skin autografts. *Scand J Plast Reconstr Surg*. 1968;2(1):44-6.
71. Capla JM, Ceradini DJ, Tepper OM, Callaghan MJ, Bhatt KA, Galiano RD, et al. Skin graft vascularization involves precisely regulated regression and replacement of endothelial cells through both angiogenesis and vasculogenesis. *Plast Reconstr Surg*. 2006;117(3):836-44.
72. Lindenblatt N, Calcagni M, Contaldo C, Menger MD, Giovanoli P, Vollmar B. A new model for studying the revascularization of skin grafts in vivo: the role of angiogenesis. *Plast Reconstr Surg*. 2008;122(6):1669-80.
73. Zötterman J, Mirdell R, Horsten S, Farnebo S, Tesselar E. Methodological concerns with laser speckle contrast imaging in clinical evaluation of microcirculation. *PLoS One*. 2017;12(3):e0174703.

74. Mahe G, Rousseau P, Durand S, Bricq S, Leftheriotis G, Abraham P. Laser speckle contrast imaging accurately measures blood flow over moving skin surfaces. *Microvasc Res.* 2011;81(2):183-8.
75. Calina MA, Boianuiu IC, Parascac SV, Miclosa S, Savastru D, Manea D. Blood oxygenation monitoring using hyperspectral imaging after flap surgery. *Spectroscopy Letters.* 2017;50(3):150-5.
76. Chiang N, Jain JK, Sleight J, Vasudevan T. Evaluation of hyperspectral imaging technology in patients with peripheral vascular disease. *J Vasc Surg.* 2017;66(4):1192-201.
77. Bunke J, Merdasa A, Stridh M, Rosenquist P, Berggren J, Hernandez J, et al. Hyperspectral and laser speckle contrast imaging for monitoring the effect of epinephrine in local anesthetics in oculoplastic surgery. *Ophthalmic Plast Reconstr Surg.* In Print.

Paper I



Blood Perfusion of Human Upper Eyelid Skin Flaps Is Better in Myocutaneous than in Cutaneous Flaps

Johanna V. Berggren, M.D.*, Kajsa Tenland, M.D.*, Josefine Bunke, M.D.*,
John Albinsson, M.Sc., Ph.D.*, Jenny Hult, M.D.*, Aboma Merdasa, M.Sc., Ph.D.*,
Rafi Sheikh, M.D., Ph.D.*, Sandra Lindstedt, M.D., Ph.D.†, and Malin Malmjö, M.D., Ph.D.*

*Department of Clinical Sciences Lund, Ophthalmology, Skåne University Hospital, Lund University, Lund, Sweden; and †Department of Cardiothoracic Surgery, Skåne University Hospital, Lund University, Lund, Sweden.

Background: The aim of this study was to monitor blood perfusion in human upper eyelid skin flaps and examine how the perfusion is affected by the thickness of the flap.

Methods: Twenty upper eyelids were dissected as part of a blepharoplasty procedure in patients. The medial end of the blepharoplasty flap remained attached to mimic a flap design often used in reconstruction in the periorcular area, a myocutaneous flap in which the blood supply follows the fibers of the orbicularis muscle and is thus parallel to the long axis of the flap. The muscle was thereafter dissected from the flap to create a cutaneous flap. Blood perfusion in the 2 types of flaps was compared using laser speckle contrast imaging.

Results: Blood perfusion decreased gradually from the base to the tip of all the flaps. Perfusion was significantly higher in the myocutaneous flaps than in the cutaneous flaps ($p < 0.0004$): 69% in the myocutaneous flaps and 43% in the cutaneous flaps, measured 5 mm from the base. Blood perfusion was preserved to a greater extent distally in the myocutaneous flaps (minimum value seen at 25 mm) than in the cutaneous flaps (minimum seen at 11 mm).

Conclusions: Blood perfusion was better preserved in myocutaneous flaps, including both skin and the orbicularis oculi muscle, than in cutaneous flaps. This may be of clinical interest in patients with poor microcirculation in which a long flap is required for reconstructive surgery.

(*Ophthalmic Plast Reconstr Surg* 2021;XX:00-00)

Reconstruction of tissue defects following, for example, trauma, the removal of tumors, or the repair of malformations, may require the use of a cutaneous or myocutaneous flap or a free skin graft. Adequate blood perfusion is crucial for the survival of flaps and free grafts. Flaps retain some blood supply, as the pedicle remains attached to the tissue and vascular

network. Other advantages of flaps are that they have similar color, thickness, and texture to the surrounding tissue, and they undergo less contraction on healing.¹

It is well known that the design of a flap is crucial to ensure optimal healing and clinical outcome. Clinical Praxis based on empirical knowledge usually determines the design of the flap, that is, its thickness, width, and length. However, our ability to study the effects of flap design on blood perfusion has previously been limited.² Modern laser-based imaging techniques have recently been developed, enabling accurate non-invasive measurements of blood perfusion in flaps in patients. Laser speckle contrast imaging (LSCI) provides high-resolution images of the microvascular blood perfusion and has been shown to have high reproducibility.²⁻⁴ To the best of our knowledge, no study has been conducted on the relationship between the blood perfusion in periorbital flaps and their thickness.

The aim of the present study was to investigate perfusion in cutaneous and myocutaneous upper eyelid flaps, dissected as part of a blepharoplasty procedure in patients using LSCI.

METHODS

Ethics. The experimental protocol was approved by the Ethics Committee at Lund University, Sweden. The research was conducted in accordance with the ethical principles of the Declaration of Helsinki as amended in 2008. Fully informed consent was obtained on the day of surgery from all the patients participating in the study. The patients were given information and asked for their consent by one of the authors of the study. If a patient declined to participate in the study, the blepharoplasty surgery took place as planned.

Subjects. Ten patients (20 upper eyelids) undergoing blepharoplasty due to excess skin in the upper eyelid were included in the study. Exclusion criteria were the inability to provide informed consent and physical or mental inability to cooperate during the local anesthetic procedure. No patient was excluded from the study. The characteristics of the patients are presented in the table.

Patient characteristics

No. of patients/eyelids (datasets)	10/20
Gender women/men	5/5
Median age (range), years	75 (45–86)
No. of patients using antihypertensive medication	9
No. of patients with diabetes	3
No. of patients with other cardiovascular disease	6
No. of patients using anticoagulant medication	4
Smokers	0

Accepted for publication May 14, 2021.

This study was supported by the Swedish Government Grant for Clinical Research (ALF), Skåne University Hospital (SUS) Research Grants, Skåne County Council Research Grants, the Lund University Grant for Research Infrastructure, Crown Princess Margaret's Foundation (KMA), the Foundation for the Visually Impaired in the County of Malmöhus, the Swedish Eye Foundation and the Department of Research and Development Region Kronoberg.

The authors have no conflicts of interest to disclose.

Address correspondence and reprint requests to Malin Malmjö, M.D., Ph.D., Department of Ophthalmology, Skåne University Hospital, Ögonklinik A, Admin, 2nd floor, Kioskgatan 1, SE-221 85 Lund, Sweden. E-mail malin.malmj@med.lu.se.

DOI: 10.1097/IOP.0000000000002015

Surgical Procedure. Surgery was carried out under local infiltration anesthesia with 20mg/mL lidocaine (Xylocaine, AstraZeneca, Södertälje, Sweden) and tetracaine eye drops (Tetracaine, Bausch & Lomb, Rochester, NY). Adrenalin was avoided so as not to cause vasoconstriction and subsequent hypoperfusion that would have interfered with the perfusion measurements. One surgeon (JVB) carried out the operations. The skin was incised with a scalpel and then dissected, using a pair of scissors, together with the underlying orbicularis oculi muscle down to the orbicular septum. Bipolar diathermy (25 W, KLS Martin ME102, KLS Martin, Tuttlingen, Germany) was used with caution in the wound bed. Diathermy on the flap and at the base of the flap in the wound bed was carefully avoided since we have found in a previous study that repeated diathermy at the base of the flap significantly reduces the blood perfusion.⁵ The medial end of the blepharoplasty flap remained intact to mimic a flap design often used in reconstruction in the periorcular area, a myocutaneous flap in which the blood supply follows the orbicularis fibers and hence is parallel to the long axis of the flap. Blood perfusion was monitored in the flap using LSCI (see below). The orbicularis oculi muscle was thereafter dissected from the flap, to create a cutaneous flap, including epidermis and dermis, as illustrated in Figure 1, and the perfusion monitoring was repeated. The median horizontal length of the flaps was 44.5 mm (range 30.0–70.0 mm), and the median vertical width at the base of the flap was 6.5 mm (range 5.0–10.0 mm). The length and width of the flaps and the thickness of the myocutaneous flaps were measured perioperatively by the surgeon using a measuring stick. The thickness of the flap was not measured in this way as the method described was deemed not sufficiently accurate for measurements of the thickness of these thin flaps. Instead, the thickness was defined by the anatomical structures, that is, the myocutaneous flap, being dissected

in the plane of the orbital septum, containing both skin and orbicularis oculi muscle and the cutaneous flaps being dissected in the subcutaneous plane, containing only skin. After completing the perfusion measurements with LSCI, the flap was detached, and the blepharoplasty procedure was proceeded according to established clinical practice. There were no adverse events. The surgical results were good.

Laser Speckle Contrast Imaging. LSCI is a noninvasive perfusion monitoring technique employing an infrared laser beam that is diffusely reflected from the surface of the skin. Dark and bright areas are formed by random interference of the light backscattered from the illuminated area, creating a speckled pattern, which is recorded in real time by a camera. Blood perfusion was monitored using LSCI with a moorFLP-2 blood flow imager (Moor Instruments, Devon, United Kingdom). The wavelength of the laser light was 785 nm, and the recording rate was up to 100 images per second at full field. The highest spatial resolution is 3.9 μm per pixel (6.6 megapixels/cm²).

During perfusion monitoring, the flap was placed on a piece of sterile paper to block signals from the underlying tissue.

Calculations and Statistical Analysis. The speckle patterns are automatically analyzed, and the blood perfusion is calculated by the software in the system and presented in arbitrary perfusion units (PU).

Blood perfusion is then calculated as the percentage of the perfusion at a reference point medial to the base of the flap, in undissected tissue where the perfusion is presumed not to be affected by the surgical procedure. The LSCI instrument gives the value of perfusion in each pixel and these were then converted to metric measurements using MATLAB R2018b (MathWorks Inc., Natick, MA).

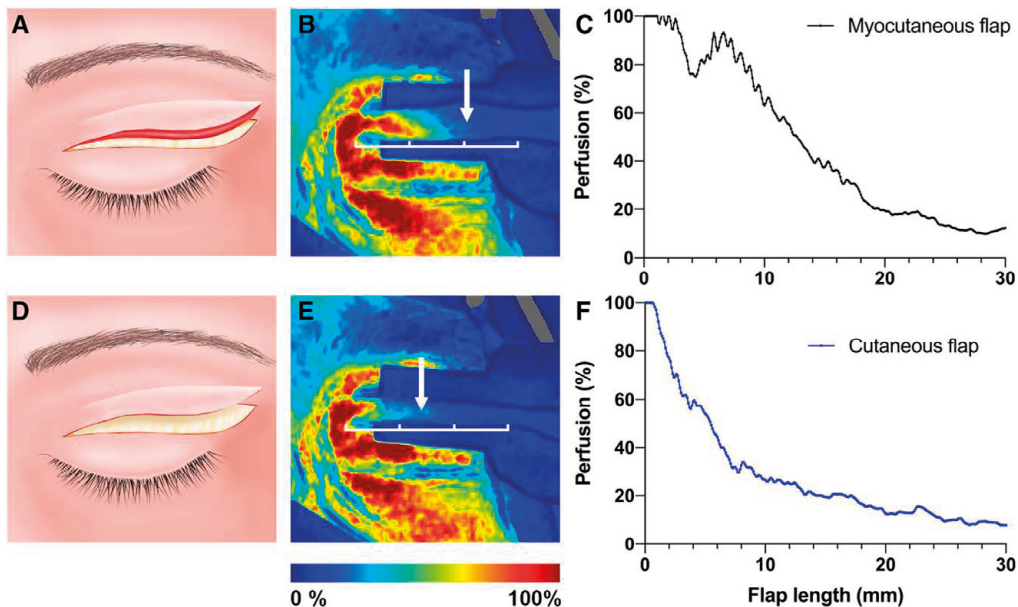


FIG. 1. To the left, illustration of the blepharoplasty procedure in which the skin and muscle were first dissected as a myocutaneous flap (A) and then thinned to achieve a cutaneous flap (D). In the middle column, LSCI images showing perfusion in the myocutaneous flap (B) and in the cutaneous flap (E). The scale bar is 30 mm, and the base of the flap, which remained attached, is on the left side of the scale bar. The white arrows indicate the position at which minimum perfusion was first observed. The graphs on the right show the perfusion, calculated as percentage of a reference point medial to the flap base. In this patient, it can clearly be seen that blood perfusion is preserved to a greater extent in the myocutaneous flap (C) than in the cutaneous flap (F). LSCI indicates laser speckle contrast imaging.

It is well known that LSCI is highly sensitive to movement artifacts.⁶ Attempts were made to reduce motion artifacts as follows. When the perfusion curve for the first time reached the lowest recorded value, this value was considered to represent the minimal perfusion and any increase over 150 PU distal to this point was considered to be due to motion artifacts. This was done in 4 datasets, 1 dataset containing all the data from 1 eyelid. The plateau value of the curve was set to 100% and spikes greater than the plateau value were considered to be motion artifacts and therefore ignored. This was done in 2 datasets. Curves showing large variations, with high frequency and an amplitude >150 PU, were interpreted as motion artifacts and were excluded. Six datasets were excluded, leaving a total of 14 datasets to be analyzed.

Calculations and statistical analysis were performed using GraphPad Prism 9.0 (GraphPad Software Inc., San Diego, CA). The results are expressed as mean values and 95% confidence intervals. Statistical analysis was performed using 2-way repeated measures ANOVA and Šidák's multiple comparisons test. The decrease in perfusion along the flap length was calculated using nonlinear regression with 1-phase decay.

RESULTS

Perfusion was higher in the myocutaneous flap than in the cutaneous flap ($p < 0.001$). Representative examples of 2 LSCI recordings and are shown in Figure 1. The mean perfusion in the myocutaneous and the cutaneous flaps and are shown in Figure 2. The difference in perfusion was significant between 1 and 15 mm from the flap base. The greatest difference between the 2 different flaps was observed at 5 mm, being 69% of the reference value in the myocutaneous flaps and 43% in the cutaneous flaps ($p < 0.0001$).

Blood perfusion decreased gradually from the base to the tip of both the myocutaneous and cutaneous upper eyelid flaps. The distance from the base at which minimum perfusion was first observed was calculated using nonlinear regression. This gave good fits, with p values < 0.0001 , for both myocutaneous and cutaneous flaps. The results show that blood perfusion is preserved to a greater extent and further along myocutaneous flaps than in cutaneous flaps. Minimum perfusion was observed 25.0 mm (23.3–25.9 mm) from the flap base in the myocutaneous flaps and at 11.0 mm (10.5–11.3 mm) in the cutaneous flaps. At these

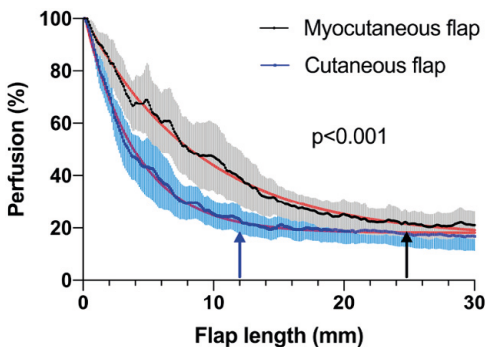


FIG. 2. Mean blood perfusion (and 95% CIs) in myocutaneous and cutaneous flaps in 14 upper eyelids, expressed as the percentage of the perfusion at a reference point medial to the flap base. The red curves show the nonlinear regression analysis with 1-phase decay and were used to calculate the flap length at which minimum perfusion was reached, which was 25 mm from the flap base for the myocutaneous flaps (black arrow), and at 11 mm for the cutaneous flaps (blue arrow). CIs, confidence intervals.

positions, LSCI recordings were 16% and 18%, respectively, which was assumed to reflect movement artifacts and not blood perfusion.

DISCUSSION

The results of this study show that blood perfusion was better preserved in myocutaneous flaps than in cutaneous flaps. These results are in line with those of our previous studies on porcine flaps, in which better perfusion and oxygenation were measured in a thicker flap that was dissected down to the muscle fascia through the subcutaneous tissue, than in a thinner flap, dissected only through half the subcutaneous tissue.⁷ The better perfusion in a myocutaneous flap can probably be explained by the vascular anatomy of the upper eyelid, with the dermal and subdermal vascular plexuses being less affected in myocutaneous flaps, thus allowing greater perfusion.

Minimum perfusion was observed 25 mm from the flap base in the myocutaneous flaps and 11 mm in the cutaneous flaps. Perfusion thus appears to be preserved at a greater distance from the base in a myocutaneous flap, suggesting that such a flap could be made longer than a cutaneous flap. Longer local flaps, with matching skin color and texture, could facilitate reconstructive surgery, compared with a free full-thickness skin graft.

Considering that perfusion decreased rapidly along the length of the flap and then leveled off at a minimum value of about 17% of the reference value in the distal end, we assumed that the flap was not perfused after the point at which the perfusion leveled off. In a previous study on detached upper eyelid skin from blepharoplasty procedures resting on the eyelid, the median value of perfusion was found to be 16 PU (range 2–37 PU).⁸ This residual value is due to a combination of motion artifacts and is referred to as the “biological zero.”^{9,10} The biological zero is believed to be due to Brownian motion of the macromolecules within the interstitium, the vascular compartment, and the lymphatic system,¹¹ or other phenomena related to the function of the autonomic nervous system.^{12,13}

In the present study, minimal perfusion values in the myocutaneous and cutaneous flaps were measured at 25 mm and 11 mm from the flap base, respectively. This is in line with a previous study by our group, in which it was shown that the perfusion in a human cutaneous upper eyelid flap was primarily maintained in the first 15 mm from the flap base but very limited beyond this distance.^{5,8} Rotating and stretching the flap was found to reduce blood perfusion.⁸ Administering diathermy to the base of the flap has also been shown to significantly reduced blood perfusion.⁵ Since the distal part of the flap does not seem to be perfused, a free full-thickness skin graft could be considered as well. Free skin grafts are known to survive well in the well-perfused periocular area, as shown in our previous studies on free full-thickness skin grafts used on their own to repair defects¹⁴ or in combination with tarsoconjunctival flaps.¹⁵

A flap is often thinned to achieve better reconstructive results, especially in the face.¹⁶ However, flap thinning can compromise the vascular supply of the flap. This has been discussed by Park et al., who addressed the need of a better understanding of the vascular network in flaps.¹⁶ This has not been studied to any great extent in the past. Modern imaging techniques, such as LSCI, offer a noninvasive means of obtaining a more detailed picture of perfusion.

Skin graft contraction has been reported to occur in 10%–40% of flaps¹⁷ and is thought to be due to passive recoil of elastin fibers in the dermis.¹⁸ It is well known that free full-thickness skin grafts contract more during healing than free split-thickness skin grafts.^{19,20} Other factors such as the

position of the flap relative to the tension lines and the size also influence the degree of contraction.¹⁷ The amount of available tissue in the periorbital area is often limited, and flaps and grafts must therefore be designed with the optimal size and thickness to avoid wasting tissue, difficulties in donor site closure, or failure of healing. However, the present study shows that myocutaneous flaps can be made longer than cutaneous flaps with retained perfusion, indicating that surgeons could consider increasing the size of these flaps to compensate for flap contraction during healing, as is seen with cutaneous skin flaps. Making the flaps longer also results in a reduced need for free skin grafts. Using a local skin flap has advantages over a free skin graft; in addition to having its own blood supply, the color and texture of local flaps better match the surrounding skin, and it exhibits less contraction upon healing than skin grafts.²¹

LSCI is hampered by technical limitations, mainly motion artifacts. In the present study, the perfusion never reached zero. This is probably due to motion artifacts, and the so-called biological zero believed to be caused by Brownian motion of the macromolecules within the interstitium, the vascular compartment and lymphatic system,¹¹ or other phenomena related to the autonomic nervous system.¹²

One limitation of this study is the great variability in the results, which may be caused by individual differences in the vascular network, the extent of the orbicularis oculi muscle, peripheral vasoconstriction due to temperature or cardiovascular regulation due to the stress in the tissue caused by surgery, microvascular disease, motion artifacts, or the individual microvascular status. A subgroup analysis of the effects of conditions that are known to affect the microvasculature, such as diabetes or smoking, on perfusion would be of great interest, but this would require a larger group of subjects.

Another limitation of the present study is that flap survival of myocutaneous and cutaneous flaps could not be compared with the current experimental setup. However, the periorbital area is well perfused and known to be forgiving to reconstructive surgery, and flap viability is seldom a problem in this area. It would be of interest to monitor the effects of flap thickness on perfusion and tissue survival postoperatively in different kinds of flaps in other areas of the body.

In conclusion, the results presented here suggest that blood perfusion is preserved to a greater extent and further distally in myocutaneous eyelid flaps than in cutaneous flaps. This may be of clinical interest in patients with poor microcirculation in which a long flap is required for reconstructive surgery.

ACKNOWLEDGMENTS

We would particularly like to thank Pernilla Rosenquist and all the surgical staff involved at the Department of Ophthalmology at Skåne University Hospital in Lund and the Central Hospital Växjö, Sweden.

REFERENCES

1. Patrinely JR, Marines HM, Anderson RL. Skin flaps in periorbital reconstruction. *Surv Ophthalmol* 1987;31:249–261.
2. Myers B, Donovan W. An evaluation of eight methods of using fluorescein to predict the viability of skin flaps in the pig. *Plast Reconstr Surg* 1985;75:245–250.
3. Zötterman J, Bergkvist M, Iredahl F, et al. Monitoring of partial and full venous outflow obstruction in a porcine flap model using laser speckle contrast imaging. *J Plast Reconstr Aesthet Surg* 2016;69:936–943.
4. Karakawa R, Yano T, Yoshimatsu H, et al. Use of laser speckle contrast imaging for successful fingertip replantation. *Plast Reconstr Surg Glob Open* 2018;6:e1924.
5. Nguyen CD, Hult J, Sheikh R, et al. Blood perfusion in human eyelid skin flaps examined by laser speckle contrast imaging—importance of flap length and the use of diathermy. *Ophthalmic Plast Reconstr Surg* 2018;34:361–365.
6. Heeman W, Steenbergen W, van Dam G, et al. Clinical applications of laser speckle contrast imaging: a review. *J Biomed Opt* 2019;24:1–11.
7. Memarzadeh K, Sheikh R, Blohmé J, et al. Perfusion and oxygenation of random advancement skin flaps depend more on the length and thickness of the flap than on the width to length ratio. *Eplasty* 2016;16:e12.
8. Ansson CD, Berggren JV, Tenland K, et al. Perfusion in upper eyelid flaps: effects of rotation and stretching measured with laser speckle contrast imaging in patients. *Ophthalmic Plast Reconstr Surg* 2020;36:481–484.
9. Zhong J, Seifalian AM, Salerud GE, et al. A mathematical analysis on the biological zero problem in laser Doppler flowmetry. *IEEE Trans Biomed Eng* 1998;45:354–364.
10. Abbot NC, Beck JS. Biological zero in laser Doppler measurements in normal, ischaemic and inflamed human skin. *Int J Microcirc Clin Exp* 1993;12:89–98.
11. Kernick DP, Tooke JE, Shore AC. The biological zero signal in laser Doppler fluximetry—origins and practical implications. *Pflugers Arch* 1999;437:624–631.
12. Humeau-Heurtier A, Abraham P, Mahe G. Linguistic analysis of laser speckle contrast images recorded at rest and during biological zero: comparison with laser Doppler flowmetry data. *IEEE Trans Med Imaging* 2013;32:2311–2321.
13. Binzoni T, Tehernin D, Richiardi J, et al. Haemodynamic responses to temperature changes of human skeletal muscle studied by laser-Doppler flowmetry. *Physiol Meas* 2012;33:1181–1197.
14. Berggren J, Castelo N, Tenland K, et al. Reperfusion of free full-thickness skin grafts in periorbital reconstructive surgery monitored using laser speckle contrast imaging [published online ahead of print September 25, 2020]. *Ophthalmic Plast Reconstr Surg*. doi: 10.1097/IOP.0000000000001851.
15. Berggren J, Tenland K, Ansson CD, et al. Revascularization of free skin grafts overlying modified Hughes tarsalconjunctival flaps monitored using laser-based techniques. *Ophthalmic Plast Reconstr Surg* 2019;35:378–382.
16. Park SO, Chang H, Imanishi N. Anatomic basis for flap thinning. *Arch Plast Surg* 2018;45:298–303.
17. Rudolph R, Ballantyne D. *Plastic Surgery*. Philadelphia: Saunders, 1990:221–274.
18. Agarwal PMP, Sharma D. Contraction of skin flaps: re-examining the scientific basis. *Eur J Plast Surg* 2020;43:453–458.
19. Ragnell A. The secondary contracting tendency of free skin grafts; an experimental investigation on animals. *Br J Plast Surg* 1952;5:6–24.
20. Corps BV. The effect of graft thickness, donor site and graft bed on graft shrinkage in the hooded rat. *Br J Plast Surg* 1969;22:125–133.
21. Shew M, Kriet JD, Humphrey CD. Flap basics II: advancement flaps. *Facial Plast Surg Clin North Am* 2017;25:323–335.

Paper II



Laser Speckle Contrast Imaging of the Blood Perfusion in Glabellar Flaps Used to Repair Medial Canthal Defects

Johanna V. Berggren, M.D., Kajsa Tenland, M.D., Rafi Sheikh, M.D., PH.D., Jenny Hult, M.D., Karl Engelsberg, M.D., PH.D., *Sandra Lindstedt, M.D., PH.D., and Malin Malmjö, M.D., PH.D.

Lund University, Skåne University Hospital, Department of Clinical Sciences Lund, Ophthalmology and *Cardiothoracic Surgery, Lund, Sweden

Background: The glabellar flap is a common technique for surgical repair after tumor excision in the medial canthal area. However, the outcome may be affected by partial flap necrosis. Little is known about the impact of surgery on blood perfusion and the postoperative course of reperfusion due to the absence of reliable and noninvasive perfusion monitoring techniques. The aim of this study was to use a modern imaging technique to assess blood perfusion in glabellar flaps.

Methods: Glabellar flaps were used to repair medial canthal defects following tumor excision in 7 patients. Blood perfusion was monitored using laser speckle contrast imaging: during surgery, immediately postoperatively (0 weeks), and at follow-up, 1, 3, and 6 weeks after surgery.

Results: Perfusion decreased gradually along the length of the flap, and reached a minimum 15 mm from the flap base. Perfusion in the proximal 20 mm of the flap was completely restored after 1 week, while the distal part of the flap was gradually reperfused over 6 weeks. Both the functional and aesthetic surgical outcomes were excellent.

Conclusions: The rapid reperfusion of the glabellar flap may be explained by its connection to the vascular network via the flap pedicle. In flaps longer than 20 mm, the distal part can be considered a free skin transplant, and a combination of a glabellar flap and a free skin graft could then be considered.

(*Ophthalmic Plast Reconstr Surg* 2021;XX:00–00)

Reconstruction of the medial canthal region following tumor excision presents a challenge in maintaining the concavity of the canthus without distortion of the surrounding tissues, or the original eyebrow and eyelid contours and symmetry. Different surgical methods can be considered, such as laissez-faire, full-thickness skin grafting with or without a deep pericranial flap, a bilobed flap, or a rhomboid flap. However, the glabellar flap is a common choice because of it is a simple procedure in which excess skin from the lax glabellar skin region is advanced into the medial canthal defect, similarly to a V-Y flap.¹ A glabellar flap can also be extended inferiorly over the nose to repair defects of the middle and distal part of the nose.² Glabellar flaps have several advantages over a free full-thickness skin graft. Being a local skin flap, it will match the texture and color of

the periorbital skin, it has its own blood supply, and the contraction on healing is less than in skin grafts,³ all of which usually result in an excellent cosmetic result. However, there have been reports of both short-term and long-term problems associated with glabellar flap reconstructions, including lymphedema of the flap tip, necrosis of the tip or edges of the flap in the early postoperative period, undesirable scar formation, depression and fusion of the eyebrows, and contraction.⁴ The planning of the flap is thus crucial, and many factors must be taken into consideration.

Successful flap reconstruction depends on understanding the vascular supply and the process of revascularization. When the glabellar flap technique was developed a century ago, it was based on empirical observations of clinical outcomes, because perfusion monitoring techniques were not available. Perfusion monitoring has recently been implemented in various reconstructive surgical procedures, but has not yet been described in the glabellar flap.

Conventional clinical methods of estimating blood flow include the assessment of temperature, color, and capillary refill, but are highly subjective and depend on the experience of the surgeon. Over the years, more objective techniques have been developed for perfusion monitoring of the skin; however, the use of these techniques has not become widespread in clinical practice due to a number of disadvantages. Fluorescein angiography is an invasive method, the dye causes discoloration, and it is not possible to repeat the measurements within 24 hours.^{5,6} Thermal imaging has the advantage of being a noninvasive method; however, skin temperature is not solely dependent on perfusion.⁷ Tissue oxygenation measurements using spectroscopic techniques lack the spatial information needed to identify heterogeneous changes in perfusion.⁸ The need for reliable, fast, and noninvasive techniques to monitor perfusion in the entire surgical area has led to the introduction of laser-based techniques. Laser speckle contrast imaging (LSCI) is a noninvasive technique that has proven especially useful in clinical perfusion monitoring of free flaps, burns, and medium to large flap transfer in reconstructive surgery.^{9–11}

In the present study, the authors used LSCI for intraoperative and postoperative perfusion monitoring in glabellar flap reconstruction in 7 patients following tumor excision in the medial canthal area. Improved knowledge of the perfusion and reperfusion of the flap may help reduce the risk of complications such as partial flap necrosis and poor cosmetic outcome.

METHODS

Ethics. The study was evaluated and approved by the ethics committee at Lund University, Sweden. It was carried out in accordance with the

Accepted for publication September 9, 2021.

The authors have no conflicts of interest to disclose.

Address correspondence and reprint requests to Malin Malmjö, M.D., Ph.D., Department of Ophthalmology, Skåne University Hospital, Ögonklinik A, Admin, 2nd Floor, Kioskgatan 1, SE-221 85 Lund, Sweden. E-mail: malin.malmjo@med.lu.se

DOI: 10.1097/IOP.0000000000002082

principles laid down in the Declaration of Helsinki as amended in 2008. All patients gave their fully informed consent.

Subjects. Seven patients with tissue defects in the medial canthal region after tumor removal (6 basal cell carcinomas and 1 squamous cell carcinoma) were included in the study. The patient characteristics are given in Table 1. Patients unable to provide informed consent, or who were physically or mentally unable to cooperate during the local anesthetic procedure, were excluded.

Surgical Procedure. Local infiltration anesthesia with 20 mg/mL lidocaine (Xylocaine, AstraZeneca, Södertälje, Sweden) was used. Epinephrine was not included in the local anesthetic, as it would have interfered with the perfusion measurements by causing transient vasoconstriction. No patient underwent surgery under general anesthesia. Modified glabellar flap procedures have been developed over the years; however, the “classical” procedure, as described, for example, by Collin,¹ was used in the present study (Fig. 1). An inverted V-shaped incision was made in the midline of the brow with 1 limb extending down to the defect. The flap was undermined in the subcutaneous plane, still attached to a pedicle across the nose. The median width of the base of the flap (i.e., the width of the bottom of the inverted V) was 17 mm (range 15–19 mm). The flap was then rotated about its pivotal point, that is, the medial canthus, and sutured into the defect. Thereafter, the brow defect was closed subcutaneously using 4-0 absorbable sutures (Vicryl, Ethicon, Somerville, NJ, U.S.A.). The skin was then sutured with a running 6 to 0 nonabsorbable nylon suture (Ethicon, Somerville, NJ, U.S.A.). Bipolar diathermy (25 W, KLS Martin ME102, KLS Martin, Tuttingen, Germany) was used with caution, and diathermy at the base of the flap was avoided because repeated diathermy at the base of the flap has been found to significantly reduce blood perfusion.¹² No pressure dressing was applied. The superficial skin sutures were removed after 7 to 8 days. Surgery was carried out by 3 experienced, senior oculoplastic surgeons at the Department of Ophthalmology at the Skåne University Hospital in Lund, Sweden.

Laser Speckle Contrast Imaging. A PeriCam PSI NR System (Perimed AB, Stockholm, Sweden) was used for perfusion monitoring. An infrared 785 nm laser beam is dispersed over the skin region of interest by a diffuser. Dark and bright areas are created by random interference of the backscattered light, creating a speckle pattern.¹³ The variation in this pattern caused by moving red blood cells is analyzed by the system software, allowing the blood perfusion to be measured in arbitrary units (perfusion units). The system is able to monitor perfusion in an area up to 24 × 24 cm, and the speckle pattern is recorded in real time (up to 100 images per second) with high resolution (100 μm/pixel). Perfusion was monitored at the following times:

1. during surgery, immediately after dissection of the glabellar flap,
2. after the flap had been sutured in place (denoted 0 weeks),

3. at follow-up at the clinic, after 6 to 8 days (denoted 1 week),
4. after 20 to 25 days (denoted 3 weeks), and
5. after 41 to 49 days (denoted 6 weeks) after surgery.

The variation in the follow-up times was due to logistic reasons.

Calculations and Statistics. The perfusion in the glabellar flap was monitored along the length of the upper and lower parts of the flap and at a reference point in the flap base (see Fig. 1B). The perfusion along the flap is given as a percentage of the perfusion at the reference point and is presented as the median value and interquartile range. GraphPad Prism 9.0 (GraphPad Software Inc., San Diego, CA, U.S.A.) was used for calculations and statistical analysis. The Kruskal-Wallis test with Dunn’s post hoc test for multiple comparisons was used for statistical analysis. Significance was defined as $p < 0.05$ ($p > 0.05$ not significant, n.s.).

RESULTS

Perioperative Blood Perfusion. Perfusion decreased along the length of the upper part of the flap, being 75% (interquartile range, 45%–85%) at 5 mm, 76% (39%–83%) at 10 mm, 46% (35%–67%) at 15 mm, and 47% (36%–49%) 20 mm from the base of the flap. A similar gradual decrease in perfusion was seen in the lower part of the flap. The results are shown in Figure 2. After rotation and suturing of the flap into place, a nonsignificant tendency towards a further decrease in perfusion was seen in the upper part of the flap (to 24% (20%–29%) at 14 mm, while no further decrease was seen in the lower part. Perfusion reached a minimum 14 mm from the flap base in the upper part of the sutured flaps and 15 mm from the base in the lower part of the sutured flaps. The values obtained at these positions were 26% (upper part) and 22% (lower part) and were assumed to reflect movement artifacts and not blood perfusion.

Reperfusion During Follow-up. One week after surgery, perfusion was completely restored in the proximal 20 mm of the upper part of the flap (93%, range 44%–126%) and did not differ significantly from the perfusion measured after 3 and 6 weeks ($p = \text{n.s.}$). However, the perfusion at 25 mm was still impaired 1 week after surgery (61% range 32%–89%). The distal part of the flap was thereafter gradually reperfused, being 73% (34%–88%) after 3 weeks and 91% (72%–122%) after 6 weeks. A similar pattern of reperfusion was seen in the lower part of the flap. Figure 3 shows a representative example of the glabella flap immediately after, and 6 weeks after, surgery, together with the corresponding perfusion images. The results for the whole group are shown in Figure 4.

Surgical Outcome. The flaps were viable in all patients and healed well. The flap skin sutures came loose in the distal part of the flap in 1 patient and the defect was allowed to heal by secondary intention. Both the functional and esthetic results were excellent. No hematomas were observed at postoperative clinical examination, and there were no artifacts in the LSCI signal indicating the presence of hematomas. However, 1 patient dropped out of the study after the 1-week follow-up due to the need for further surgery, as a residual tumor was found.

DISCUSSION

Knowledge of blood perfusion and revascularization is crucial in reconstructive surgery. This is the first study to investigate the reperfusion of glabellar flaps used to repair medial canthal defects. The perfusion in the glabellar flap was clearly impaired immediately postoperatively, especially so in the distal part of the flap. However, reperfusion of the flaps occurred quickly, and the proximal 20 mm of the flaps was fully reperfused within a week after surgery. This is in line with previous studies on other types of reconstructive flaps, where rapid

TABLE 1. Patient characteristics

Number of men/women	2/5
Median age (range), years	77 (60–89)
No. patients using antihypertensive medication	4
No. patients with diabetes	4
No. patients with other cardiovascular diseases	2
No. patients using anticoagulant medication	2
No. patients using corticosteroid medication	0
No. smokers/former smokers (nonsmokers for the past 10 years)	2/2
No. patients treated with radiotherapy or previous surgery in the periorbital area	1

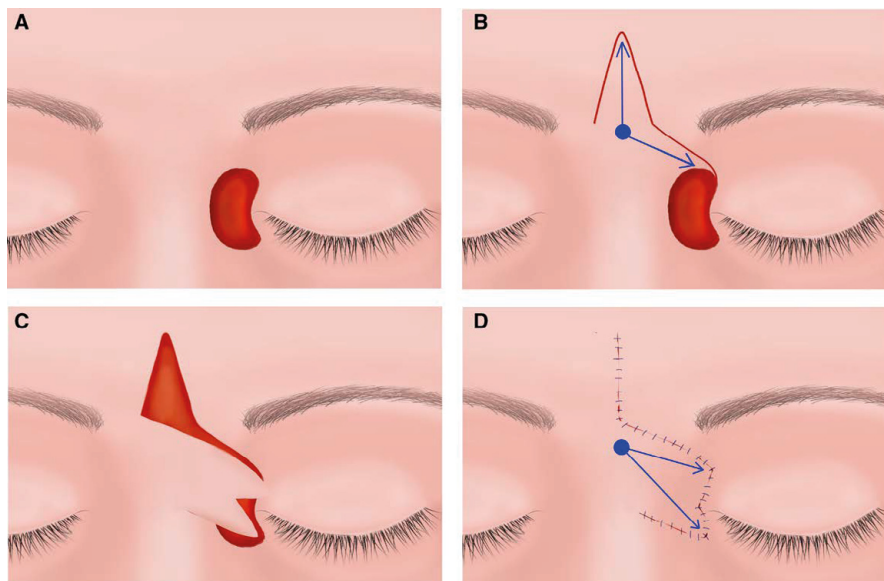


FIG. 1. Schematic illustration of the glabellar flap procedure. The flap is used to repair a medial canthal defect after tumor excision (A). The glabellar flap is first dissected from the midline of the brow with 1 limb extending down to the defect (B). The flap is then rotated about its base (C) and sutured into the defect, after which the glabellar defect is closed (D). LSCI was performed immediately after dissection, and after the flap had been sutured in place. Blood perfusion was measured along the length of the flap, in the upper and lower parts of the flap, as indicated by the blue arrows. Perfusion was then calculated as a percentage of the perfusion at a reference point in the flap base (blue dot). LSCI, laser speckle contrast imaging.

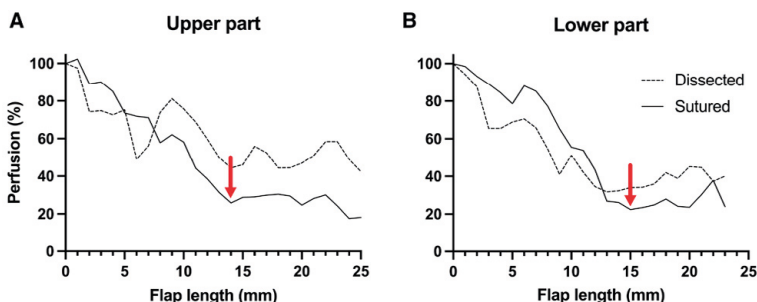


FIG. 2. Graphs showing the median blood perfusion in the 7 glabellar flaps as a percentage of the perfusion at the reference point, immediately after dissection, and after being rotated and sutured in place. Note the gradual decrease in perfusion along the length of the flaps, reaching a minimum at 14 and 15 mm, in the upper and lower parts of the sutured flaps, respectively (indicated by the red arrows).

reperfusion has been reported. In a recent LSCI study on the H-plasty procedure in the periorcular region, the bipedicle flaps were found to be fully reperfused within 1 week of surgery.¹⁴ In 1982, Young et al. studied the revascularization of pedicle skin flaps and new vascular connections between the distal viable region and the surrounding skin 3 to 4 days after surgery by injecting disulfine blue in a porcine model, and found that the whole flap had developed a collateral vascular supply after 7 to 10 days.¹⁵ In 1985, Cumming et al. used laser Doppler and a dermofluorometer in a porcine model, and observed that the perfusion in a panniculus carnosus myocutaneous flap was

adequate for survival without the pedicle 7 to 10 days after surgery.¹⁶ Using animal models and ligation of the flap pedicle, Tsur et al. studied the revascularization of axial flaps, and found that it was sufficient to sustain flap survival after 6 to 7 days in rats, and after 4 to 5 days in pigs.¹⁷ The rapid reperfusion of the proximal parts of the glabellar flap seen in the present study is presumably due to the vascular network connected to the flap via the pedicle, unlike a free skin graft, where reperfusion depends on angiogenesis throughout the graft. It is therefore not surprising that the reperfusion of glabellar flaps is more rapid.

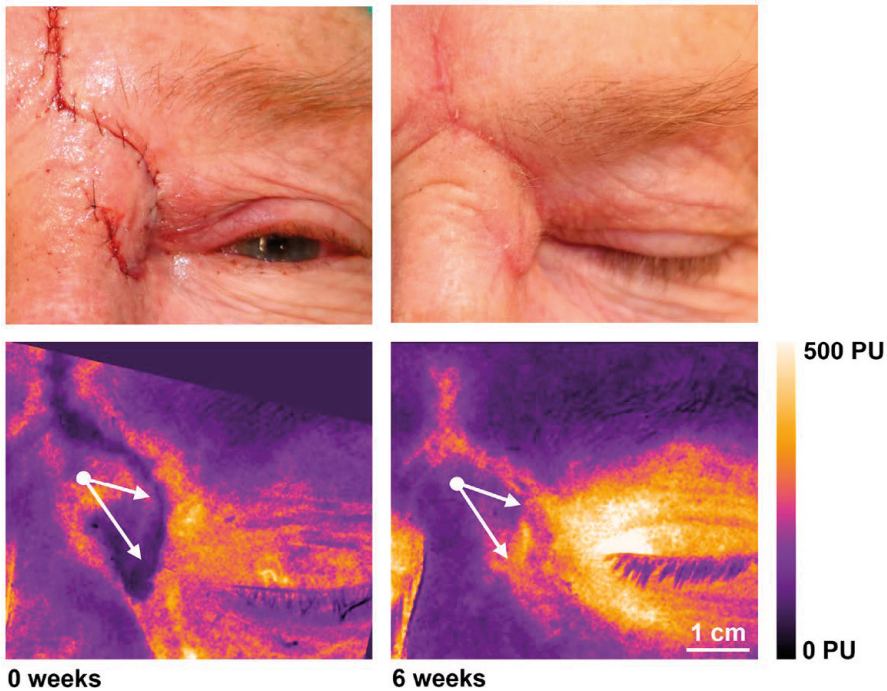


FIG. 3. Photographs and laser speckle contrast images of a glabellar flap immediately after surgery (0 weeks) and after 6 weeks (above). The LSCI recordings below show the variation in perfusion along the length of the upper and lower parts of the flap, as indicated by the white arrows. Note how the perfusion in the distal part of the flap is restored during healing. LSCI, laser speckle contrast imaging.

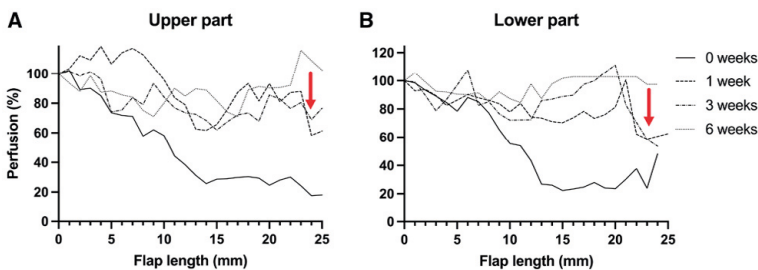


FIG. 4. Graphs showing the median blood perfusion in the upper and lower parts of the 7 glabellar flaps, immediately postoperatively (0 weeks), and at follow-up after 1, 3, and 6 weeks. It can be seen that complete reperfusion was achieved already after 1 week in the proximal 20 mm of the flaps, while reperfusion took longer in the distal parts of the flaps (red arrows).

In the present study, perfusion reached a minimum plateau in the distal parts of the glabellar flap, that is, ≥ 15 mm from the flap base. This is in line with a previous study by our group, in which it was shown that the perfusion in a human cutaneous upper eyelid flap was mainly preserved in the first 15 mm from the flap base, but very low beyond this.^{12,18} Furthermore, 6 weeks was required for the distal tip of the glabellar flap, beyond 20 mm, to be reperfused. Reperfusion of the flap tip thus follows the same pattern as the revascularization of a free skin graft, and presumably depends on angiogenesis. Indeed, the

authors have shown in previous studies that free full-thickness skin grafts in the periocular area require 7 weeks to become fully reperfused.^{19,20}

Considering that the distal part of the flap does not seem to be perfused, the combination of a glabellar flap and a free full-thickness skin graft could be considered in cases where a long flap is required. The survival rate of free skin grafts in the well-perfused periocular area is known to be high, as shown in previous studies on free full-thickness skin grafts used on their own to cover defects,¹⁹ or in combination with tarsoconjunctival

flaps.²⁰ Indeed, it is common practice to combine a glabellar flap with other local flaps in cases of very large medial canthal defects, to reduce the length of the flap. For instance, in a case report from 2017, Ogino et al. used a glabellar flap, an upper eyelid myocutaneous advancement flap, and a cheek rotation flap to cover a medial canthal defect, while the donor site of the glabellar flap was covered by a Rintala flap.²¹ In 2010, Chao et al. published a study on reconstruction using a combination of glabellar and orbicularis oculi myocutaneous advancement flaps.²² To repair canthal defects that extend relatively inferiorly, a glabellar flap can be combined with a cheek rotation flap (i.e., Mustardé's cheek rotational flap).²³ An alternative method of reducing the length of the glabellar flap could be to combine a glabellar flap with a free skin graft. It would be of interest to investigate the effects of these types of combined surgical procedures on perfusion in future studies. The results of the present study suggest that combining a glabellar flap with a free skin graft could be considered in cases where the length of the required flap is greater than 15 mm.

The glabellar flap is a type of rotational advancement flap, where the flap is dissected from the forehead, and then rotated and stretched to cover the medial canthal defect. The results of this study show that the perfusion immediately after dissection was satisfactory over the full length of the glabellar flap, while after being sutured in place in the tissue defect, the perfusion had decreased slightly. It is well known from previous studies that manipulation of a flap impairs perfusion. In one of our previous studies on upper eyelid flaps using LSCI, the authors found that stretching a nonrotated flap had only a slight effect on perfusion, and simply rotating the flap by 90° had no significant effect on perfusion. However, the combination of rotation and stretching led to a significant reduction in perfusion.¹⁸ This is in line with the results of our previous study on porcine eyelid flaps.²⁴ It, therefore, appears to be necessary to achieve a compromise between the length of the flap and the degree to which it must be rotated and stretched to cover a defect. The current study included only medial canthal defects, thus not extending much below the level of the eye. Glabellar flaps are sometimes used to repair defects of the middle and distal parts of the nose, requiring them to be extended further inferiorly over the nose. It is reasonable to assume that blood perfusion would be significantly affected in such cases, although this remains to be investigated in future studies.

As mentioned above, the authors have previously investigated the blood perfusion in other pedicle flaps from the eyelid, and found that the perfusion differed depending on the skin thickness and the underlying anatomy. Blood perfusion was found to be preserved to a greater extent distally in myocutaneous upper eyelid flaps containing orbicular muscle than in cutaneous flaps without orbicular muscle.²⁵ Perfusion was also found to be better preserved further distally in a full-thickness eyelid flap composed of both the anterior and posterior lamellae.²⁶ A glabellar flap consists of skin and subcutaneous fat in a region in which the skin is fairly thick compared with the upper eyelid skin. The region receives blood from the angular and supratrochlear arteries,²⁷ and LSCI monitoring of the skin microvascular blood perfusion shows that it is not as richly perfused as the upper eyelid. With this in mind, it can be concluded that perfusion depends on the flap thickness and the underlying muscular and vascular anatomy.

The median width of the base of the flap in the present study was 17 mm. It has previously been thought that the surviving length of a flap depends on its width.^{28,29} However, this can be questioned. For example, Daniel and Williams found that increasing the width of random advancement flaps did not result in an increase in the length (mm) of the flap surviving.³⁰

In 2016, it was shown that hypoperfusion and oxygenation of random flaps could not be predicted by the ratio of the width to the length, but depended on the length and thickness of the flap.³¹ In the present study, the width of the base of the flaps only varied slightly, between 15 and 19 mm, and the authors believe this had little effect on the perfusion, and it is thus more likely that the length of the flap was of greater importance for the perfusion at the tip of the flap.

There have been reports of problems in the short-term and long-term outcomes following glabellar flap reconstructions, including lymphedema of the flap tip, necrosis of the tip/edges of the flap in the early postoperative period, undesirable scar formation, depression and fusion of the eyebrows, and contraction.⁴ The risk of such complications may increase if the postoperative perfusion is insufficient, leading to ischemia in the flap. The results of the present study indicate that the risk may increase when the flaps are longer than 20 mm. Poor microvascular status of the patient may also constitute a risk factor. It is well known that cardiovascular disease, diabetes mellitus, smoking,³² and poor nutritional status³³ may influence the healing process, and therefore, most likely, reperfusion. However, no conclusions could be drawn regarding these factors in the present study due to the limited sample size. If it becomes possible in the future to monitor perfusion perioperatively in clinical practice, this may allow the surgical procedure to be tailored so as to avoid flap ischemia. This would hopefully reduce the risk of complications and improve surgical outcomes.

One major limitation of this study is the fact that perfusion was not monitored hourly in the immediate postoperative period. This means that it was not possible to determine whether the initial reduction in perfusion was due to the fact that the vessels were disrupted, or due to other surgical factors, such as surgical trauma, or temperature changes. Surgical vasospasm has been reported around the flap pedicle,³⁴ which may reduce the perfusion immediately postoperatively. However, it was not possible to monitor the blood flow for several hours after surgery as this would have meant keeping the patients at the clinic for an extended period.

In conclusion, the results of the present study suggest that glabellar flaps are reperfused quickly, and therefore provide an attractive alternative for the reconstruction of tissue defects in the medial canthal region. The major causes of glabellar flap necrosis are most likely a lack of surgical experience, inadequate planning, and careless flap dissection and/or raising. Rare cases of flap failure may be due to the flap being longer than that dictated by the microvascular status of the patient. In such cases, the glabellar flap should be shortened and combined, for example, with another myocutaneous advancement flap or a free graft. Perioperative LSCI monitoring may provide an attractive means of monitoring the perfusion of the flap during surgery and may make it possible to tailor the reconstructive procedure in each patient to avoid flap ischemia.

ACKNOWLEDGMENTS

The authors thank Jonas Blohmé for his surgical expertise and Cu Dybelius Ansson for technical support. Special thanks to all the surgical staff involved at Skåne University Hospital in Lund for their endless patience.

This study was supported by the Swedish Government Grant for Clinical Research (ALF), Skåne University Hospital (SUS) Research Grants, Skåne County Council Research Grants, Lund University Grant for Research Infrastructure, Crown Princess Margaret's Foundation (KMA), the Foundation for the Visually Impaired in the County of Malmöhus, The

Nordmark Foundation for Eye Diseases at Skåne University Hospital, Lund Laser Center Research Grant, the European Union's Horizon 2020 Programme for Research and Innovation, Carmen and Bertil Regnér's Foundation, and the Swedish Eye Foundation.

REFERENCES

- Collin JRO. *A manual of systematic eyelid surgery*. 3rd ed. Philadelphia, PA: Elsevier Inc.; 2006.
- Nolst Trenité GJ. *Rhinoplasty: Rhinoplasty: A Practical Guide to Functional and Aesthetic Surgery of the Nose*. 3rd ed. Kugler Publications; 1998.
- Shew M, Kriet JD, Humphrey CD. Flap basics II: advancement flaps. *Facial Plast Surg Clin North Am* 2017;25:323–335.
- Maloo AJ, Leatherbarrow B. The glabellar flap dissected. *Eye (Lond)* 2000;14 (Pt 4):597–605.
- Flower RW, Hochheimer BF. Indocyanine green dye fluorescence and infrared absorption choroidal angiography performed simultaneously with fluorescein angiography. *Johns Hopkins Med J* 1976;138:33–42.
- Lange K, Boyd LJ. The technique of the fluorescein test to determine the adequacy of circulation in peripheral vascular diseases, the circulation time and capillary permeability. *Bull NY Med CoU* 1943;6:78–81.
- Issing WJ, Naumann C. Evaluation of pedicled skin flap viability by pH, temperature and fluorescein: an experimental study. *J Craniomaxillofac Surg* 1996;24:305–309.
- Mahoney JL, Lista FR. Variations in flap blood flow and tissue PO₂: a new technique for monitoring flap viability. *Ann Plast Surg* 1988;20:43–47.
- Mahé G, Humeau-Heurtier A, Durand S, et al. Assessment of skin microvascular function and dysfunction with laser speckle contrast imaging. *Circ Cardiovasc Imaging* 2012;5:155–163.
- Mirdell R, Farnebo S, Sjöberg F, et al. Accuracy of laser speckle contrast imaging in the assessment of pediatric scald wounds. *Burns* 2018;44:90–98.
- Mirdell R, Farnebo S, Sjöberg F, et al. Interobserver reliability of laser speckle contrast imaging in the assessment of burns. *Burns* 2019;45:1325–1335.
- Nguyen CD, Hult J, Sheikh R, et al. Blood perfusion in human eyelid skin flaps examined by laser speckle contrast imaging—importance of flap length and the use of diathermy. *Ophthalmic Plast Reconstr Surg* 2018;34:361–365.
- Briers J. Laser speckle contrast imaging for measuring blood flow. *Opt Appl* 2007;XXXVII:139–152.
- Berggren J, Castelo N, Tenland K, et al. Revascularization after H-plasty reconstructive surgery in the periorbital region monitored with laser speckle contrast imaging. *Ophthalmic Plast Reconstr Surg* 2021;37:269–273.
- Young CM. The revascularization of pedicle skin flaps in pigs: a functional and morphologic study. *Plast Reconstr Surg* 1982;70:455–464.
- Cummings CW, Trachy RE. Measurement of alternative blood flow in the porcine panniculus carnosus myocutaneous flap. *Arch Otolaryngol* 1985;111:598–600.
- Tsur H, Daniller A, Strauch B. Neovascularization of skin flaps: route and timing. *Plast Reconstr Surg* 1980;66:85–90.
- Ansson CD, Berggren JV, Tenland K, et al. Perfusion in upper eyelid flaps: effects of rotation and stretching measured with laser speckle contrast imaging in patients. *Ophthalmic Plast Reconstr Surg* 2020;36:481–484.
- Berggren J, Castelo N, Tenland K, et al. Reperfusion of free full-thickness skin grafts in periorcular reconstructive surgery monitored using laser speckle contrast imaging. *Ophthalmic Plast Reconstr Surg* 2020;37:324–328.
- Berggren J, Tenland K, Ansson CD, et al. Revascularization of free skin grafts overlying modified Hughes tarsoconjunctival flaps monitored using laser-based techniques. *Ophthalmic Plast Reconstr Surg* 2019;35:378–382.
- Ogino A, Onishi K, Okada E, et al. Medial canthal reconstruction with multiple local flaps. *JPRAS Open* 2018;15:4–9.
- Chao Y, Xin X, Jianguing C. Medial canthal reconstruction with combined glabellar and orbicularis oculi myocutaneous advancement flaps. *J Plast Reconstr Aesthet Surg* 2010;63:1624–1628.
- Field LM, Dachow-Siwiec E, Szymanczyk J. Combining flaps. Medical canthal/lateral nasal root reconstruction utilizing glabellar “fan” and cheek rotation flaps – an O-to-Z variation. *J Dermatol Surg Oncol* 1994;20:205–208.
- Nguyen CD, Sheikh R, Dahlstrand U, et al. Investigation of blood perfusion by laser speckle contrast imaging in stretched and rotated skin flaps in a porcine model. *J Plast Reconstr Aesthet Surg* 2018;71:611–613.
- Berggren JV, Tenland K, Bunke J, et al. Blood perfusion of human upper eyelid skin flaps is better in myocutaneous than in cutaneous flaps [published online ahead of print July 21, 2021]. *Ophthalmic Plast Reconstr Surg*. doi: 10.1097/IOP.0000000000002015.
- Tenland K, Berggren JV, Dybelius Ansson C, et al. Blood perfusion in rotational full-thickness lower eyelid flaps measured by laser speckle contrast imaging. *Ophthalmic Plast Reconstr Surg* 2020;36:148–151.
- Kelly CP, Yavuzer R, Keskin M, et al. Functional anastomotic relationship between the supratrochlear and facial arteries: an anatomical study. *Plast Reconstr Surg* 2008;121:458–465.
- Gillies HD. *Plastic Surgery of the Face*. London: Frowde, Hodder, Stoughton; 1920:270.
- Milton SH. Pedicled skin-flaps: the fallacy of the length: width ratio. *Br J Surg* 1970;57:502–508.
- Daniel RK, Williams HB. The free transfer of skin flaps by microvascular anastomoses. An experimental study and a reappraisal. *Plast Reconstr Surg* 1973;52:16–31.
- Memarzadeh K, Sheikh R, Blohmé J, et al. Perfusion and oxygenation of random advancement skin flaps depend more on the length and thickness of the flap than on the width to length ratio. *Eplasty* 2016;16:e12.
- Guo S, Dipietro LA. Factors affecting wound healing. *J Dent Res* 2010;89:219–229.
- Arnold M, Barbul A. Nutrition and wound healing. *Plast Reconstr Surg* 2006;117(7 suppl):42S–58S.
- Hýza P, Veselý J, Schwarz D, et al. The effect of blood around a flap pedicle on flap perfusion in an experimental rodent model. *Acta Chir Plast* 2009;51:21–25.

Paper III



Revascularization After H-plasty Reconstructive Surgery in the Periorbital Region Monitored With Laser Speckle Contrast Imaging

Johanna Berggren, M.D.*, Nazia Castelo, M.D.*, Kajsa Tenland, M.D.*, Karl Engelsberg, M.D., Ph.D.*, Ulf Dahlstrand, M.D., Ph.D.*, John Albinsson, M.Sc., M.D.*, Rafi Sheikh, M.D., Ph.D.*, Sandra Lindstedt, M.D., Ph.D.†, and Malin Malmjö, MD, PhD

Departments of *Clinical Sciences Lund, Ophthalmology and †Cardiothoracic Surgery, Lund University, Skåne University Hospital, Lund, Sweden

Background: H-plasty reconstructive surgery is commonly used to close defects after tumor excision in the periorbital region. Revascularization of the bipedicle skin flaps is essential for healing. However, it has not previously been possible to study this revascularization in humans due to the lack of noninvasive perfusion monitoring techniques. The aim was to monitor perfusion in H-plasty flaps during surgery and during postoperative follow-up, using laser speckle contrast imaging.

Method: H-plasty, i.e., bipedicle random advancement skin flaps, was used for reconstruction of the eyelids after tumor removal in 7 patients. The median length and width of the skin flaps were 13 mm (range, 8–20 mm) and 10 mm (range, 5–11 mm), respectively. Blood perfusion was measured using laser speckle contrast imaging during surgery and at follow up 1, 3, and 6 weeks postoperatively, to monitor revascularization.

Results: Immediately postoperatively, the perfusion in the distal end of the flaps had fallen to 54% (95% CI, 38%–67%). The perfusion then quickly increased during the healing process, being 104% (86%–124%) after 1 week, 115% (94%–129%) after 3 weeks, and 112% (96%–137%) after 6 weeks. There was no clinically observable ischemia or tissue necrosis.

Conclusions: Revascularization of the H-plasty procedure flaps occurs quickly, within a week postoperatively, presumably due to the existing vascular network of the flap pedicle, and was not dependent on significant angiogenesis. This perfusion study confirms the general opinion that H-plasty is a good reconstructive technique, especially in the periorbital region with its rich vascular supply.

(*Ophthalmic Plast Reconstr Surg* 2021;37:269–273)

Accepted for publication June 24, 2020.

This study was supported by Agreement concerning research and education of doctors (ALF), Skåne University Hospital (SUS) Research Grants, Skåne County Council Research Grants, Lund University Grant for Research Infrastructure, Kronprinsessan Margaretas Arbetsnämnd för synskadade (KMA), the Foundation for the Visually Impaired in the County of Malmöhus, The Nordmark Foundation for Eye Diseases at Skåne University Hospital, Lund Laser Center Research Grant, the European Union's Horizon 2020 Programme for Research and Innovation, Carmen and Bertil Regner's Foundation, and the Swedish Eye Foundation.

The authors have no conflicts of interest to disclose.

Address correspondence and reprint requests to Malin Malmjö, MD, PhD, Department of Ophthalmology, Skåne University Hospital, Ögonklinik A, Admin, 2nd Floor, Kioskgatan 1, SE-221 85 Lund, Sweden. E-mail: malin.malmjso@med.lu.se

DOI: 10.1097/IOP.0000000000001799

H-plasty, using bipedicle advancement flaps, is often used to repair defects after tumor surgery in the head and neck region. There are several benefits of using advancement flaps compared to free skin grafts or secondary intention healing, including a good match of skin color and texture, the flaps have their own blood perfusion, and there is less contraction during healing.¹ Successful design of the advancement flaps depends on understanding the vascular supply and the process of revascularization.¹ To the best of the authors' knowledge, no study has yet been carried out to assess the perfusion in H-plasty procedures using modern imaging techniques.

Perfusion monitoring has traditionally been performed through clinical examination, as first described by the Italian Renaissance surgeon, Gaspare Tagliacozzi, i.e., by feeling the temperature of the skin, observing the color, and measuring the capillary refill time.² Over the years, techniques such as fluorescence angiography with sodium fluorescein³ and indocyanine green angiography⁴ and thermal imaging have been tried but are invasive techniques not appropriate for repeated monitoring. Laser-based techniques are noninvasive and have recently gained ground in the monitoring of flap perfusion during reconstructive surgery. Laser speckle contrast imaging (LSCI) is a noninvasive technique that provides rapid assessment of perfusion over a wide area with high resolution. The technique relies on the scattering of coherent laser light by moving particles in the illuminated tissue, forming a speckle pattern that contains information on the concentration and speed of the moving particles, i.e., blood cells.⁵ Laser speckle contrast imaging has been used in studies of microvascular blood perfusion in plastic reconstructive procedures,^{6–8} burns,⁹ and wound healing¹⁰ to gain deeper knowledge on blood perfusion and the healing process. It has also been used to detect systemic microvascular dysfunction in several vascular pathologies,¹¹ including Alzheimer's disease, schizophrenia, hypertension, renal disease, diabetes, peripheral vascular disease, atherosclerotic coronary artery disease, heart failure, and systemic sclerosis.¹² However, although LSCI can be used to assess perfusion in flap surgery, and theoretically provide objective measures for optimizing surgery, its use is not yet widespread in the clinical setting.

The aim of this study was to investigate the possibility of using LSCI to measure the blood perfusion and revascularization of the flaps in the H-plasty procedure in the periorbital area.

METHODS

Ethics. The experimental protocol was approved by the Ethics Committee at Lund University, Sweden. Research was carried out in accordance

with the ethical principles of the Declaration of Helsinki, as amended in 2008. Fully informed consent was obtained from all the participating patients.

Subjects. Seven patients, 1 woman and 6 men, undergoing reconstructive surgery after tumor excision in the periorbital area at Skåne University Hospital in Lund, Sweden, between March 2019 and December 2019 were included in the study. The median age was 73 years (45–91 years). Surgery was performed by 2 experienced senior surgeons. Medical factors that may affect microcirculation and healing were recorded. Three patients had cardiovascular disease, all of whom were taking anti-coagulation medication and this medication was not suspended. Two patients had known hypertension and were taking antihypertensive drugs. One of them was taking β -blockers at the time of surgery. No patient had diabetes, and none was taking steroid medication. One patient smoked on a daily basis, and 2 had quit smoking more than 40 years ago. No patient had had previous radiotherapy in the periorbital area. The characteristics of patients and flaps are presented in Table.

Surgical Procedure. Surgery was performed under local anesthesia using 20 mg/ml lidocaine (Xylocaine; AstraZeneca, Södertälje, Sweden). Adrenalin was not used to prevent interference with the perfusion measurements. An H-plasty reconstructive procedure was performed (see Fig. 1). Cutaneous bipedicle flaps were created by making 2 incisions through the skin and then subcutaneously undermining the flaps and the surrounding skin to allow flap movement and to minimize tension. In 5 patients, the flaps included the skin and the underlying orbicular muscle, while in the other 2, the flaps consisted of skin only. No Burow's triangle excisions were made. The median horizontal length of the flaps thus created was 13 mm (range, 8–20 mm), and the median vertical width was 10 mm (range, 5–11 mm). Diathermy (25 W, bipolar, KLS Martin ME102; KLS Martin, Tuttlingen, Germany) was used with caution and avoided at the base of the flap, as the authors have found in a previous study that repeated diathermy at the base of the flap significantly affected the blood perfusion and probably caused the flap to function more like a free graft than a flap.¹³ Resorbable 5-0 Vicryl sutures were placed subcutaneous to reduce tension on the suture lines, and the skin was sutured using nonresorbable 6-0 Ethilon sutures (both from Ethicon, Somerville, NJ, U.S.A.). No dressing was applied after surgery. Blood pressure was not monitored intraoperatively or postoperatively. The skin sutures were removed after 1 week.

Laser Speckle Contrast Imaging. Blood perfusion was monitored using an LSCI instrument (PeriCam PSI NR System; Perimed AB, Stockholm, Sweden). The skin area of interest is illuminated by an infrared 785 nm laser light. Dark and bright areas are created by interference of

the light backscattered from moving particles in the illuminated area, creating a speckled pattern. This pattern is recorded in real time by a camera, with up to 100 images per second, and at a spatial resolution up to 100 $\mu\text{m}/\text{pixel}$. Perfusion is automatically calculated by the system by analyzing the variations in the speckle pattern. Perfusion was assessed at the distal ends of the flaps, as shown in Figure 1B, and is expressed in arbitrary units, perfusion units.

Perfusion was monitored immediately postoperatively (denoted 0 weeks) and on 3 follow-up occasions. Due to logistic reasons, the time of the follow-up visits varied. The data were therefore grouped into the following time intervals: follow up at 7 to 8 days (denoted 1 week), 19 to 28 days (denoted 3 weeks), and 33 to 45 days (denoted 6 weeks).

Calculations and Statistics. The perfusion in the flap was calculated as a percentage of the perfusion at a reference point (baseline) just outside the flap, in undissected tissue (see Fig. 1B). The reference point was infiltrated with local anesthesia in the same way as the surgical area. The reference point was measured at each follow-up clinic visit. Biologic zero values were obtained by mechanically occluding the vasculature gently at the pedicle base using a Dieffenbach clamp, before suturing the flaps and the values were then subtracted. Values of perfusion, expressed as median values with 95% CIs, were obtained during surgery right after the flaps were sutured in place and on 3 follow-up occasions.

Statistical analysis was performed using the Kruskal–Wallis test with Dunn test for multiple comparisons and the Mann–Whitney test for single comparisons. Significance was defined as: $p < 0.05$ (*), $p < 0.01$ (**), $p < 0.001$ (***), $p < 0.0001$ (****), and $p > 0.05$ (not significant). Calculations and statistical analysis were performed using GraphPad Prism 8.3 (GraphPad software Inc., San Diego, CA, U.S.A.).

RESULTS

Surgical Outcome. All flaps were viable at follow up. One patient had to have secondary surgery due to postoperatively developed ectropion of the lower eyelid. Another patient also developed minimal ectropion but was satisfied with the result and did not want further surgery. Both functional and esthetic results were excellent in all other cases.

Blood Perfusion Monitoring. The perfusion at the distal end of the flaps decreased to 54% (95% CI, 38%–67%) during surgery. Revascularization was rapid, and perfusion had increased to 104% (95% CI, 86%–124%) 1 week after surgery ($p < 0.0001$). Perfusion remained high during the remaining follow-up period, being 115% (95% CI, 94%–129%) after 3 weeks and 112% (95% CI, 96%–137%) after 6 weeks, indicating hyperperfusion during the healing process. Figure 2 shows a

Patient characteristics

Patient	Gender	Age (y)	Tumor type	Tumor location	Flap size: length (horizontal) \times width (vertical) (mm)	Flap thickness
1	Male	86	Nodular basal cell carcinoma	Lower eyelid	Medial flap: 20 \times 10 Lateral flap: 10 \times 10	Skin and orbicularis muscle
2	Male	55	Squamous cell carcinoma in situ	Lower eyelid	Medial flap: 13 \times 10 Lateral flap: 13 \times 10	Skin and orbicularis muscle
3	Male	71	Infiltrative basal cell carcinoma	Lower eyelid	Medial flap: 10 \times 5 Lateral flap: 8 \times 7	Skin and orbicularis muscle
4	Male	91	Infiltrative basal cell carcinoma	Lower eyelid	Medial flap: 19 \times 10 Lateral flap: 10 \times 10	Skin
5	Male	73	Squamous cell carcinoma in situ	Upper eyelid	Medial flap: 13 \times 11 Lateral flap: 14 \times 10	Skin
6	Female	45	Nodular basal cell carcinoma	Lower eyelid	Medial flap: 15 \times 6 Lateral flap: 10 \times 10	Skin and orbicularis muscle
7	Male	82	Nodular basal cell carcinoma	Lower eyelid	Medial flap: 11 \times 10 Lateral flap: 13 \times 10	Skin and orbicularis muscle

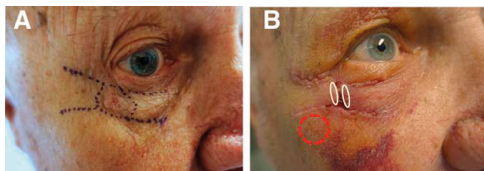


FIG. 1. Representative photographs showing the H-plasty procedure and the sites at which perfusion was measured. **A**, The location of a basal cell carcinoma in the lower eyelid, and dotted lines indicating its excision and the extent of the bipedicle advancement flaps. **B**, The result 1 week postoperatively. The white circles indicate where perfusion was measured at the distal ends of the flaps. The red circle indicates the area in which the reference value of perfusion (baseline) was measured.

representative example of perfusion monitored with LSCI, and Figure 3 shows the results for the whole group.

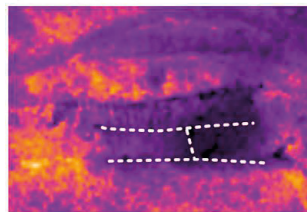
There was no significant difference in the perfusion in the flaps consisting of skin only (median = 102%; 95% CI, 94%–118%) compared to flaps consisting of skin and orbicularis muscle (107%; 95% CI, 72%–147%) ($p > 0.3$); or short (≤ 10 mm) (median = 97%, 95% CI, 81%–136%) compared to long flaps (> 10 mm) (median = 110%; 95% CI, 72%–147%) ($p > 0.3$); or medial (median = 96%; 95% CI, 81%–146%) compared to lateral raised flaps (114%; 95% CI, 72%–136%) ($p > 0.3$), recorded immediately postoperatively.

DISCUSSION

Good blood perfusion and revascularization are vital when performing reconstructive surgery using flaps. The results of the present study show that perfusion in the flaps formed in *H-plasty* reconstruction is impaired immediately after surgery. The authors have previously shown that the blood perfusion in flaps during a blepharoplasty procedure decreased gradually from the base to the tip of the flap; the flap being well perfused only in the proximal 1 cm ($\approx 40\%$ – 60%) and decreasing rapidly beyond 2 cm ($\approx 20\%$).^{8,13} Similar findings were made in the authors' previous studies on porcine skin flaps.^{14,15} The lengths of the flaps in the present study were 8 to 20 mm and had a median perfusion at the distal end of the flap of 54%, which is in line with the results of previous studies.


Revascularization of the flaps in this study was rapid, being 104% only 1 week after surgery. Revascularization has been studied extensively in flap models in animals, also showing that revascularization is rapid. Young¹⁶ studied the revascularization of pedicle skin flaps in a porcine model by injecting disulfine blue and observed new vascular connections between the distal viable region and the surrounding skin 3 to 4 days after surgery, and the whole flap had developed a collateral vascular supply 7 to 10 days after surgery. Cumming and Trachy¹⁷ used a porcine model to study perfusion in panniculus carnosus myocutaneous flaps using laser Doppler and a dermofluorometer and found that flap perfusion was adequate for survival without the pedicle 7 to 10 days after surgery. Tsui et al.¹⁸ studied revascularization of axial flaps in porcine and rat models and found that it was sufficient to sustain flap survival after 6 to 7 days in rats and after 4 to 5 days in pigs. They found that neovascularization started simultaneously from the wound edges and the wound bed, although adequate neovascularization from the wound bed appeared to be more important.¹⁸ These studies indicate rapid revascularization, which is supported by the authors' findings. The reason for the rapid revascularization in bipedicle advancement flaps is probably that there is already a vascular network connected to the circulation via the flap pedicle.

0 weeks




500 PU


1 week



3 weeks



6 weeks



0 PU

FIG. 2. Representative laser speckle contrast imaging (LSCI) from 1 patient who has undergone H-plasty on the lower left eyelid using bipedicle advancement flaps. The LSCI images show the perfusion of the flaps directly after surgery (0 weeks) and the revascularization after 1, 3, and 6 weeks postoperatively. The dotted white lines indicate the extent of the flaps. The scale bar is 10 mm. PU, perfusion units.

However, in a free skin graft, revascularization depends on angiogenesis throughout the graft, and revascularization can be expected to take longer. In a previous study, the authors examined the revascularization of free skin grafts in the Hughes procedure and found that 3 weeks were required to reach 50% revascularization and 8 weeks for complete revascularization.⁶

The H-plasty healed well in all cases, and no tissue necrosis was seen. This was expected, as the periorbital area is known to be forgiving for plastic reconstructive surgical

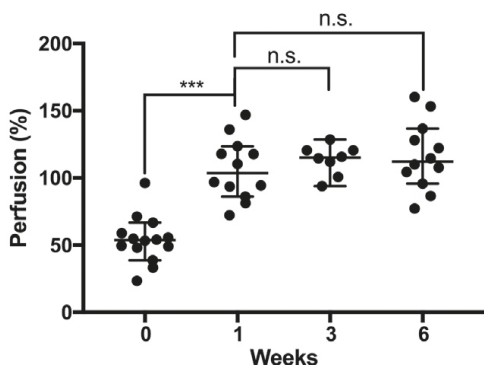


FIG. 3. Blood perfusion in the advancement flaps, immediately postoperatively (0 weeks), and at follow up after 1, 3, and 6 weeks. Data are expressed as the percentage (median values and 95% CIs) of the perfusion in a reference area just outside the flaps (100%, baseline) and values obtained in the occluded flap, intraoperatively (0%), were subtracted. n.s., not significant.

procedures due to the rich vascular supply. Random flaps are known to be more viable in the face than elsewhere, viability decreasing with the distance from the face.¹⁹ The results of this study may be useful in other areas of reconstructive surgery where the conditions for healing are not as favorable.

The values of perfusion were found to exceed the baseline values 1 to 3 weeks postoperatively. The wound healing process consists of 4 overlapping phases: hemostasis (0 to several hours after the trauma), inflammation together with vasodilation (1–3 days), proliferation with restoration of the vascular network (4–21 days), and remodeling (21 days to 1 year).²⁰ It is, therefore, not surprising to see hyperperfusion in the postoperative healing phase. If the perfusion had been monitored the area for a longer period, the authors may have seen the perfusion return to the baseline value.

One limitation of this study is that the effect of surgical vasospasm on the reduction in perfusion immediately postoperatively could not be determined. It is well known that surgical vasospasm may occur around the flap pedicle.²¹ To determine the contribution of surgical vasospasm, it would have been necessary to make measurements during the hours following surgery. However, patients often have to travel far for this kind of surgery, and it would have been unlikely that they would have agreed to remain at the hospital for several hours after surgery. Abstinence from the use of epinephrine in the local anesthetic also deviates from the practice of many surgeons, especially given that such additives are rarely withheld due to concerns regarding vasculopathic risk factors. However, it cannot be deduced from the results of the present study whether this had any impact on the results.

Another limitation is the limited size of the study group. Analyses were carried out with regard to the location, thickness, and length of the flap, but the residual did not reach statistical significance. It could be assumed that perfusion would be greater in skin flaps including orbicularis muscle. This was investigated in one of the authors' previous studies in pigs, showing higher perfusion in thick flaps than in thin flaps.¹⁵ A larger study must be performed in humans to investigate the effects of this. Nor was the sample size large enough to investigate whether age or impaired blood perfusion due, for example, to previous radiotherapy, cardiovascular disease, diabetes mellitus, or smoking affected the outcome of the surgery and the

revascularization process. Perfusion measurements in the patient who was a smoker showed that tissue perfusion was no worse intraoperatively or postoperatively than in any of the other patients. However, there were too few patients to draw any reliable conclusions.

No hematoma was seen in the patients at clinical examination postoperatively. The presence of a postoperative hematoma would most likely reduce the LSCI signal because the system uses an invisible near-infrared laser (785 nm), which is within the range of light absorption of hemoglobin. Stationary blood cells and cell remnants (after hemolysis) would most likely have a signal blocking effect, probably proportional to the thickness of the hematoma. In the authors' measurements, the authors did not observe any suspected artifacts in signal due to hematoma.

Laser speckle contrast imaging could easily be implemented in clinical routine in reconstructive surgery, because it is noninvasive, and the measurements are not very time-consuming. However, problems associated with motion artifacts must first be overcome. Methods of, at least partially, overcoming these, such as shorter sampling times or simultaneously recording the signal backscattered from an adjacent opaque surface, have been suggested.²² Laser speckle contrast imaging monitoring would be particularly important in flaps or grafts that risk failure, i.e., when the geometry or size of the flap indicates a risk of poor perfusion, or when the patient has poor microcirculation, as in the case of diabetics or smokers. If graft failure could be identified early, timely revision could be carried out and the healing process optimized. In procedures such as the Tagliacozzi flap and the paramedial flap procedure where the pedicle is usually cut after 3 weeks, when the revascularization of the mobilized tissue is deemed to be adequate, LSCI could be used to assess flap perfusion, allowing the pedicle to be cut earlier. This would also optimize the surgical outcome.

In conclusion, the results of the present study suggest that bipedicle advancement flaps in H-plasty procedures are adequately perfused postoperatively and that they are revascularized quickly, confirming the general surgical experience that the rich vascular supply of the periorbital region is forgiving for reconstructive surgery.

ACKNOWLEDGMENTS

This study would not have been possible without the help and encouragement of Maria Schalen and all the other surgical staff involved at Skåne University Hospital in Lund, Sweden.

REFERENCES

- Shew M, Kriet JD, Humphrey CD. Flap basics II: advancement flaps. *Facial Plast Surg Clin North Am* 2017;25:323–335.
- Pickard A, Karlen W, Ansermino JM. Capillary refill time: is it still a useful clinical sign? *Anesth Analg* 2011;113:120–123.
- Lange K, Boyd LJ. The technique of the fluorescein test to determine the adequacy of circulation in peripheral vascular diseases, the circulation time and capillary permeability. *NY Med Coll Flower & Fifth Ave Hosps* 1943:78.
- Flower RW, Hochheimer BF. Indocyanine green dye fluorescence and infrared absorption choroidal angiography performed simultaneously with fluorescein angiography. *Johns Hopkins Med J* 1976;138:33–42.
- Draijer M, Hondebrink E, van Leeuwen T, et al. Review of laser speckle contrast techniques for visualizing tissue perfusion. *Lasers Med Sci* 2009;24:639–651.
- Berggren J, Tenland K, Ansson CD, et al. Revascularization of free skin grafts overlying modified Hughes tarsoconjunctival flaps monitored using laser-based techniques. *Ophthalmic Plast Reconstr Surg* 2019;35:378–382.

7. Ansson CD, Sheikh R, Dahlstrand U, et al. Blood perfusion in Hewes tarsoconjunctival flaps in pigs measured by laser speckle contrast imaging. *JPRAS Open* 2018;18:98–103.
8. Ansson CD, Berggren JV, Tenland K, et al. Perfusion in upper eyelid flaps: effects of rotation and stretching measured with laser speckle contrast imaging in patients. *Ophthalmic Plast Reconstr Surg* 2020;36:481–484
9. Mirdell R, Farnebo S, Sjöberg F, et al. Accuracy of laser speckle contrast imaging in the assessment of pediatric scald wounds. *Burns* 2018;44:90–98.
10. Basak K, Dey G, Mahadevappa M, et al. Learning of speckle statistics for *in vivo* and noninvasive characterization of cutaneous wound regions using laser speckle contrast imaging. *Microvasc Res* 2016;107:6–16.
11. Holowatz LA, Thompson-Torgerson CS, Kenney WL. The human cutaneous circulation as a model of generalized microvascular function. *J Appl Physiol* (1985) 2008;105:370–372.
12. Mahé G, Humeau-Heurtier A, Durand S, et al. Assessment of skin microvascular function and dysfunction with laser speckle contrast imaging. *Circ Cardiovasc Imaging* 2012;5:155–163.
13. Nguyen CD, Hult J, Sheikh R, et al. Blood perfusion in human eyelid skin flaps examined by laser speckle contrast imaging—importance of flap length and the use of diathermy. *Ophthalmic Plast Reconstr Surg* 2018;34:361–365.
14. Nguyen CD, Sheikh R, Dahlstrand U, et al. Investigation of blood perfusion by laser speckle contrast imaging in stretched and rotated skin flaps in a porcine model. *J Plast Reconstr Aesthet Surg* 2018;71:611–613.
15. Memarzadeh K, Sheikh R, Blohmé J, et al. Perfusion and oxygenation of random advancement skin flaps depend more on the length and thickness of the flap than on the width to length ratio. *Eplasty* 2016;16:e12.
16. Young CM. The revascularization of pedicle skin flaps in pigs: a functional and morphologic study. *Plast Reconstr Surg* 1982;70:455–464.
17. Cummings CW, Trachy RE. Measurement of alternative blood flow in the porcine panniculus carnosus myocutaneous flap. *Arch Otolaryngol* 1985;111:598–600.
18. Tsur H, Daniller A, Strauch B. Neovascularization of skin flaps: route and timing. *Plast Reconstr Surg* 1980;66:85–90.
19. Stell PM. The viability of skin flaps. *Ann R Coll Surg Engl* 1977;59:236–241.
20. Reinke JM, Sorg H. Wound repair and regeneration. *Eur Surg Res* 2012;49:35–43.
21. Hýza P, Veselý J, Schwarz D, et al. The effect of blood around a flap pedicle on flap perfusion in an experimental rodent model. *Acta Chir Plast* 2009;51:21–25.
22. Mahé G, Rousseau P, Durand S, et al. Laser speckle contrast imaging accurately measures blood flow over moving skin surfaces. *Microvasc Res* 2011;81:183–188.

Paper IV



Blood Perfusion in Rotational Full-Thickness Lower Eyelid Flaps Measured by Laser Speckle Contrast Imaging

Kajsa Tenland, M.D.*, Johanna V. Berggren, M.D.*, Cu Dybelius Ansson, M.D.*, Jenny Hult, M.D.*, Ulf Dahlstrand, M.D.*, Sandra Lindstedt, M.D., Ph.D.†, Rafi Sheikh, M.D., Ph.D.*, and Malin Malmsjö, M.D., Ph.D.*

*Department of Clinical Sciences Lund, Ophthalmology, and †Department of Clinical Sciences Lund, Cardiothoracic Surgery, Lund University, Skåne University Hospital Lund, Sweden

Purpose: Large upper eyelid defects can be repaired by rotational full-thickness lower eyelid flaps. The aim was to measure the blood perfusion in such flaps, and how it is affected by the length of the flaps, and the degree of rotation and stretching.

Methods: Nine patients underwent the Quickert procedure for entropion repair in which a full-thickness eyelid flap of approximate width 0.5 cm and length 2 cm was dissected in the lower eyelid. This generates a full-thickness eyelid flap similar to that used to repair large upper eyelid defects. Perfusion was measured using laser speckle contrast imaging, before and after the flap was rotated 90° and 120°, and stretched using forces of 0.5, 1, and 2 N.

Results: Blood perfusion decreased gradually from the base to the tip of the flap; being 75% of the reference value 0.5 cm from the base, 63% at 1.0 cm, 55% at 1.5, 23% at 1.75 cm, and 4% at 2.0 cm. Rotating the flaps by 90° or 120° had little effect on the perfusion. Stretching reduced the perfusion from 63% to 32% at 2 N, when measured at 1 cm. The combination of stretching and rotation did not lead to any further decrease.

Conclusions: Blood perfusion in lower eyelid rotational flaps seems to be more sensitive to stretching than to rotation. Provided the flap is no longer than 1.5 cm, the perfusion will be greater than 20%, even when rotated, which should be sufficient for adequate survival and healing.

(*Ophthalmic Plast Reconstr Surg* 2020;36:148–151)

A number of surgical procedures can be used to repair full-thickness eyelid defects involving the eyelid margin, including direct closure, flaps, tissue grafts, or a combination of these.¹ Direct closure can be used to repair full-thickness eyelid defects of less than 25% of the width of the eyelid. However, when the removal of a tumor affects more than 50% of the width

of the eyelid, it is necessary to repair the eyelid using a flap or graft. A local flap is preferred because this has similar texture, thickness, and color, it may also provide eyelashes for the defect, and there is less contraction on healing than with skin grafts.² One technique that may be used for this is a full-thickness eyelid flap. For example, a large upper eyelid defect can be repaired by rotating the lower eyelid into the upper eyelid defect.³

It is well known that the survival of a flap is affected by its design. An adequate blood supply to the tissue is crucial for the healing of both skin flaps and grafts. However, the design of flaps is largely based on empirical observations of flap survival and information available in the literature.⁴ Methods used previously to measure blood perfusion during surgery have not been reliable. Fluorescein and disulfine blue dye have been used to measure perfusion and flap survival, but these methods are associated with underestimation or overestimation of flap survival by up to 30%.⁵ Recently developed techniques now allow easier and more reliable measurements of blood flow in plastic surgery. Laser speckle contrast imaging (LSCI) is a noninvasive technique that provides high-resolution images of the structure and function of the tissue with high reproducibility.⁶ The object is illuminated by laser light, and the backscattered light, which forms a random interference pattern called a speckle pattern, is used to determine perfusion.⁷ Movement, such as the flow of red blood cells in a tissue, causes the speckle pattern to change, allowing the blood perfusion to be quantified. Laser speckle contrast imaging is a fast, full-field technique for the imaging of microvascular perfusion.⁸ Current LSCI equipment can produce representative images of the perfusion in the surface of tissue over a relatively large area (up to 24 × 24 cm). Laser speckle contrast imaging is now an established technique in, for example, experimental research and plastic surgery.^{9–13}

The aim of this study was to measure blood perfusion using LSCI in full-thickness rotational eyelid flaps in humans and to investigate how perfusion is affected by the length of the flap, the degree of rotation, and stretching of the flap. This is the first time that perfusion has been measured in a full-thickness rotational eyelid flap during surgery in humans.

METHODS

Ethics. The experimental protocol for this study was approved by the Ethics Committee at Lund University, Sweden. The research adhered to the tenets of the Declaration of Helsinki as amended in 2008. All patients included in the study gave their fully informed consent.

Subjects. Patients admitted to the Department of Ophthalmology, Skåne University Hospital, for surgery to repair involutional entropion were consecutively recruited for the study during the period January to

Accepted for publication August 22, 2019.

Supported by the Swedish Government Grant for Clinical Research (ALF), Skåne University Hospital (SUS) Research Grants, Skåne County Council Research Grants, Lund University Grant for Research Infrastructure, Crown Princess Margaret's Foundation (KMA), the Foundation for the Visually Impaired in the County of Malmöhus, The Nordmark Foundation for Eye Diseases at Skåne University Hospital, Lund Laser Center Research Grant, the European Union's Horizon 2020 Programme for Research and Innovation, Carmen and Bertil Regné Foundation, and the Swedish Eye Foundation.

The authors have no conflicts of interest to disclose.

Address correspondence and reprint requests to Malin Malmsjö, M.D., Ph.D., Department of Ophthalmology, Skåne University Hospital, Ögonklinik A, Admin, 2nd Floor, Kioskgatan 1B, SE-221 85 Lund, Sweden. E-mail malin.malmsjo@med.lu.se

DOI: 10.1097/IOP.0000000000001496

May 2018. All patients had excessive eyelid laxity and were scheduled for entropion surgery using the Quic kert procedure.¹⁴ The patient's medical history was unknown before the day of surgery. Exclusion criteria were inability to provide informed consent, and physical or mental inability to cooperate during the local anesthetic procedure. No patients were excluded. Nine eyelids in 8 patients were included in the study. The patient's characteristics are given in the Table.

Surgical Procedure. Surgery was performed under local infiltration anesthesia with 20 mg/ml lidocaine (Xylocaine, AstraZeneca, Södertälje, Sweden). A modified Quic kert procedure was performed,¹⁴ in which a vertical incision was made through the eyelid, and through the tarsal plate, approximately 5 mm from the lateral canthus. A horizontal full-thickness incision was then made below the lower border of the tarsal plate. In this way, 2 full-thickness eyelid flaps were created, of which the medial one was the longer, and in which perfusion was measured. The median dimensions of the flaps were 0.5 cm (0.4–0.6) vertically and 2.1 cm (1.8–2.5) horizontally, and the median thickness was 0.3 cm (0.2–0.4). Perfusion measurements were performed 10 minutes after the creation of the flap to minimize the effect of surgical vasospasm. After perfusion measurements had been made, the distal part of the medial flap was resected to correct the excess eyelid laxity as part of the modified Quic kert procedure. The Quic kert procedure was then completed to correct the entropion. There were no adverse events, and the surgical results were good in all cases.

Laser Speckle Contrast Imaging. Blood perfusion was measured using LSCI (PeriCam PSI NR System, Perimed AB, Stockholm, Sweden). This system employs an infrared 785 nm laser beam that is spread over the surface of the skin by a diffuser, creating a speckle pattern (dark and bright areas formed by random interference of the light backscattered from the illuminated area). Blood perfusion is calculated automatically by the system by analyzing the variations in the speckle pattern. The speckle pattern is recorded in real time, at a rate of up to 100 images per second, with a high resolution of up to 100 $\mu\text{m}/\text{pixel}$. The technique has been used to monitor flap perfusion in other plastic reconstructive surgery procedure before both in humans and porcine models.^{9–13} It is well known that the skin perfusion is affected by cardiovascular status and the room temperature. The room temperature was standardized to 20°C. To conquer the problem with variability in perfusion between the subjects, the results were calculated as percent change (see Calculations and Statistics).

Study Protocol. A medium-sized corneal shield was used to protect the eye from laser irradiation (Ellman International Inc., Oceanside, NY). A thin plastic shield was applied under the flap to prevent interference due to the laser signal resulting from blood flow in the underlying tissues. Perfusion was imaged over the entire length of the flap. Perfusion was measured at the base of the flap (0 mm) before rotating or stretching the flap and was set to 100%. Perfusion was measured in the resected part of the flap and set to 0%. Perfusion was then measured every 0.25 cm a-

long the length of the flap, without any rotation or stretching of the flap. The flaps were then rotated manually by 90° and 120° and the perfusion determined again. Two sutures were attached to the distal end of the flap to stretch the flaps. The sutures were then attached to a line, which was threaded through a fixed pulley. Different weights were added (50, 100, and 200 g) to achieve stretching forces of 0.5, 1, and 2 N. The stretched flaps were then also rotated. One limitation of the present study was that the perfusion was not measured at different time points after completion of a rotational flap. The reason is that these were modified Quic kert procedures, the flap was shortened at the end of surgery and not sutured in place rotated. The relevance of postsurgical measurements would therefore be limited. Furthermore, performing these measurements at different time points after the creation of the flap would be unethical because it would extend the duration of the surgery. However, in a future study on true rotational flaps, this could be done after surgery has been completed.

For the completion of the entropion repair, part of the medial flap is resected to redress excess eyelid laxity. Perfusion was measured in the resected part of the flap to obtain a value of zero perfusion. After completion of the study protocol, the surgical procedure to correct entropion was performed according to normal practice.

The design of the flap and the perfusion measurements are illustrated in Figure 1.

Calculations and Statistics. Perfusion measured with LSCI is expressed in arbitrary units, perfusion units. Blood perfusion was calculated and expressed as a percent (median values and interquartile ranges) after normalization to the perfusion at the base of the flap (100%) and in the resected part (0%). Statistical analysis was performed using the Kruskal–Wallis test and Dunn's multiple comparison test. Significance was defined as $p < 0.05$ and $p > 0.05$ (not significant). All differences referred to in the text were statistically verified. Calculations and statistical analysis were performed using GraphPad Prism 7.0a (GraphPad Software Inc., San Diego, CA).

RESULTS

Blood perfusion decreased gradually from the base to the tip of the flap; being 75% of the reference value 0.5 cm from the base, 63% at 1.0 cm, 55% at 1.5, 23% at 1.75 cm, and 4% at 2.0 cm. Beyond 2.0 cm there was only minimal perfusion (Fig. 2A).

Rotating the flaps by 90° or 120° had little effect on the perfusion (Figs. 2B and 3). Stretching the flaps with a force of 0.5 or 1 N,

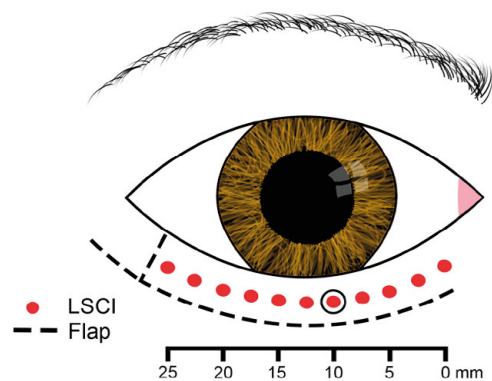


FIG. 1. Illustration of the full-thickness eyelid flap. Perfusion was measured using LSCI at 0.25 cm increments from the base of the flap. Comparisons between measurements with and without rotation and tension were made at a distance of 1 cm. LSCI, laser speckle contrast imaging.

Patient's characteristics

No. eyelids	9
No. patients	8
Median age (range), years	83 (53–97)
No. of patients using antihypertensive medication	5
No. of patients with diabetes mellitus	0
No. of patients with other cardiovascular diseases	1
No. of patients using anticoagulant medication	2
No of patients using corticosteroid medication	0
No. of smokers or former smokers (nonsmokers for the past 10 years)	0

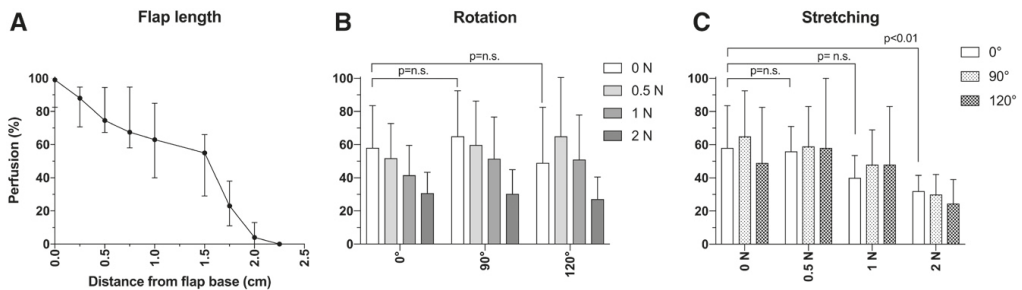


FIG. 2. Blood perfusion measured using LSCI in full-thickness rotational eyelid flaps, showing the effects of distance from the base (0–2 cm) (A), rotation (90° and 120°) (B), and stretching of the flap (0.5, 1, and 2 N) (C). Data are shown as medians and interquartile ranges. Statistical analysis was performed using Friedman's test with Dunnnett's multiple comparison test. Significance was defined as $p < 0.05$ and $p > 0.05$ (n.s.). Note that rotating the flaps had little effect on the perfusion while stretching the flaps significantly reduced the perfusion. LSCI, laser speckle contrast imaging; n.s., not significant.

with no rotation, resulted in a nonsignificant decrease in perfusion (from 63% to 56%, and 40%, 1.0 cm from the flap base, $p =$ not significant). When the higher force of 2 N was applied, the perfusion decreased to 32%, $p < 0.01$ (Figs. 2C and 4). At this force, the perfusion was lower along the entire length of the flap than in the unstretched flap.

No significant differences in perfusion were seen when stretching an already rotated flap. The perfusion when applying a force of 1 N to the unrotated flap was 42%, compared with 51% and 49% when the flap was rotated by 90° and 120°, respectively (measured 1 cm from the flap base). At the highest force of 2 N, the perfusion decreased to 29%, 30% and 28% in the unrotated, and in the 90° and 120° rotated flaps, respectively (Fig. 2).

DISCUSSION

The results of the present study show a decrease in perfusion along the length of the full-thickness rotational eyelid flaps in patients. Perfusion was found up to a distance of 1.5 cm from the base (~30%), but beyond this perfusion was minimal. This indicates that 1.5 cm is probably the maximum length for a rotational flap, with retained perfusion, especially as it was found that stretching reduced perfusion even further. However, in clinical practice, such flaps often must be longer to repair large defects. In cases where the tip of the flap survives in longer flaps, this is presumably due to the passive diffusion of oxygen and nutrients. The authors have indeed recently shown that a free full-thickness eyelid wedge graft 1 cm wide can be transposed to another eyelid without necrosis.¹⁵

Previous studies support the findings of perfusion being dependent on the length of the flap.^{9–11} The perfusion in full-thickness eyelid flaps in pigs¹¹ has been found to be higher than in this study in patients; being 80% 3 cm from the base of the flap. This may be because the pig eyelid is thicker, having a more extensive vascular network. Furthermore, some of the patients in the present study suffered from hypertension and/or cardiovascular disease, which may compromise blood flow. The mean age of the patients was 83 years, which may also have affected blood flow. Moreover, these patients were undergoing surgery for entropion, and the tissue may have been affected by inflammation or edema, both of which could compromise wound blood flow and/or healing.

Interestingly, perfusion in these full-thickness eyelid flaps was found to be better than in random pattern flaps.¹⁵ This may be because the eyelid can be regarded as an axial flap, or arterial flap, which is a myocutaneous flap containing a direct cutaneous artery along its longitudinal axis. A random skin flap,

however, lacks a specific vessel for vascularization and is perfused by musculocutaneous microcirculation in the tissue.¹⁶

Advancing a flap to cover a defect following tumor excision or trauma often requires stretching and/or rotation of the flap. When the flaps were stretched with a force of 2 N, perfusion decreased by 50%. The authors believe that a force of 2 N may be at the upper limit of that used clinically. However, the level of stretch that is seen clinically cannot be deduced from the present study, and there are no studies to confirm that 2 N may be clinically relevant. The true effect of stretch on a flap thus remains unknown. Rotation of the flap did not have any significant effect on perfusion in the present study. It is not unnatural to assume that rotating a skin flap would impair blood perfusion by strangulation of the blood vessels. In a previous study, in which perfusion was measured in random skin flaps in a porcine model, the perfusion was found to decrease significantly when the flap was manipulated by stretching and/or rotating it 90°.¹⁰ This may be due to differences in the structure of porcine and human skin.

One limitation of the present study is that blood perfusion was measured in a flap created for entropion repair. It was therefore not sutured into place, as would a full-thickness flap for the repair of a defect after tumor surgery, making long-term follow-up impossible. It is therefore not possible to conclude what degree of perfusion would be adequate for survival or healing of the flap. Neither could flap necrosis be evaluated. However, it is well known that eyelid flaps have a high survival rate, probably due to rich periorbital vascularization that benefits the diffusion of both oxygen and nutrients from the adjoining tissue and from the tear fluid. According to Tyers and Collin,¹⁷ many flaps survive even when they appear discolored during the first few days postoperatively. Another limitation of this study is that the base of all the flaps was medial. Indeed, there is generally a low risk of flap necrosis in eyelid surgery, so the usefulness of measuring perfusion for this particular procedure would be unlikely to change clinical management. It is well known that most of the blood flow to the eyelid is from the medial canthus,¹ and it can therefore not be ruled out that the results may have been different if the flap had been dissected extending from the lateral canthus, or in the upper eyelid. Another limitation is the sample size. Nine patients are just barely enough to allow statistical analysis of significance. However, the results display a clear-cut trend in decreased perfusion along the length of the flap and the results indeed reach statistical significance.

In conclusion, full-thickness rotational eyelid flaps are perfused in the proximal 1.5 cm, and the survival of longer

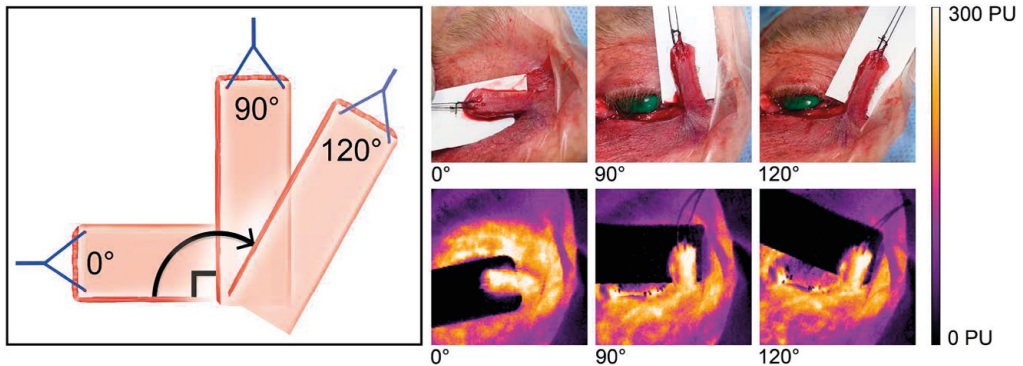


FIG. 3. Schematic illustration of flap rotation (**left**), together with photographs (**top row**), and corresponding laser speckle images (**bottom row**) showing the effects of rotation of a full-thickness eyelid flap by 90° and 120°. Purple color, Low blood perfusion; yellow/white color, high blood perfusion. It can be seen that rotating the flaps had little effect on the perfusion. PU, perfusion units.

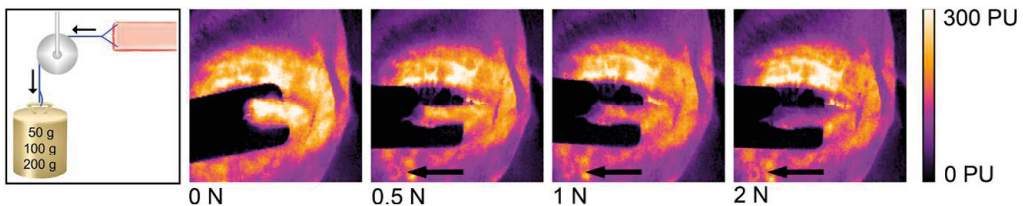


FIG. 4. Schematic illustration of flap stretching (**left**), together with LSCI images showing perfusion in a full-thickness eyelid flap stretched by 0.5, 1, and 2 N. Purple color, Low blood perfusion; yellow/white color high blood perfusion. It can be seen that stretching the flaps significantly reduced the perfusion. LSCI, laser speckle contrast imaging; PU, perfusion units.

flaps will be dependent on the passive diffusion of oxygen and nutrients. The application of tension to a flap reduced the perfusion, while rotation up to 120° did not seem to affect perfusion. Considering all the findings of this study, we conclude that a flap must be sufficiently long to allow it to be moved from the donor site to the recipient site, without applying too high a force, and it should be short enough to ensure adequate perfusion of the tip.

ACKNOWLEDGMENTS

We thank Helen Sheppard for her valuable help with the language, and all the surgical staff involved at Skåne University Hospital.

REFERENCES

- Codner MA, McCord CD, Mejia JD, et al. Upper and lower eyelid reconstruction. *Plast Reconstr Surg* 2010;126:231e–45e.
- Patriney JR, Marines HM, Anderson RL. Skin flaps in periorbital reconstruction. *Surv Ophthalmol* 1987;31:249–61.
- Collin JRO. *A Manual of Systematic Eyelid Surgery*. 3rd ed. Philadelphia, PA: Elsevier Inc, 2006:35–6.
- Gillies HD. *Plastic Surgery of the Face*. London, United Kingdom: Hodder and Stought, 1920.
- Myers B, Donovan W. An evaluation of eight methods of using fluorescein to predict the viability of skin flaps in the pig. *Plast Reconstr Surg* 1985;75:245–50.
- Eriksson S, Nilsson J, Stureson C. Non-invasive imaging of microcirculation: a technology review. *Med Devices (Auckl)*. 2014;7:445–452.
- Yamamoto Y, Ohura T, Nohira K, et al. Laserflowgraphy: a new visual blood flow meter utilizing a dynamic laser speckle effect. *Plast Reconstr Surg* 1993;91:884–94.
- Allen J, Howell K. Microvascular imaging: techniques and opportunities for clinical physiological measurements. *Physiol Meas* 2014;35:R91–R141.
- Memarzadeh K, Sheikh R, Blohme J, et al. Perfusion and oxygenation of random advancement skin flaps depend more on the length and thickness of the flap than on the width to length ratio. *Eplasty* 2016;16:e12.
- Nguyen CD, Sheikh R, Dahlstrand U, et al. Investigation of blood perfusion by laser speckle contrast imaging in stretched and rotated skin flaps in a porcine model. *J Plast Reconstr Aesthet Surg* 2018;71:611–3.
- Sheikh R, Memarzadeh K, Torbrand C, et al. Blood perfusion in a full-thickness eyelid flap, investigated by laser doppler velocimetry, laser speckle contrast imaging, and thermography. *Eplasty* 2018;18:e9.
- Nguyen CD, Hult J, Sheikh R, et al. Blood perfusion in human eyelid skin flaps examined by laser speckle contrast imaging—importance of flap length and the use of diathermy. *Ophthalmic Plast Reconstr Surg* 2018;34:361–5.
- Zötterman J, Bergkvist M, Iredahl F, et al. Monitoring of partial and full venous outflow obstruction in a porcine flap model using laser speckle contrast imaging. *J Plast Reconstr Aesthet Surg* 2016;69:936–43.
- Quickert M. The eyelids. Malposition of the lid. In: Sorby A, editor. *Modern Ophthalmology*. 2nd ed. London, United Kingdom: Butterworth, 1972:937–54.
- Memarzadeh K, Engelsberg K, Sheikh R, et al. Large eyelid defect repair using a free full-thickness eyelid graft. *Plast Reconstr Surg Glob Open* 2017;5:e1413.
- McGregor IA, Morgan G. Axial and random pattern flaps. *Br J Plast Surg* 1973;26:202–213.
- Tyers AG, Collin JRO. *Colour Atlas of Ophthalmic Plastic Surgery E-book*. 4th ed. Philadelphia, PA: Elsevier Inc, 2017:60.

Paper V



Reperfusion of Free Full-Thickness Skin Grafts in Periocular Reconstructive Surgery Monitored Using Laser Speckle Contrast Imaging

Johanna Berggren, M.D., *† Nazia Castelo, M.D., *† Kajsa Tenland, M.D., *† Ulf Dahlstrand, M.D., Ph.D., *† Karl Engelsberg, M.D., Ph.D., *†‡ Sandra Lindstedt, M.D., Ph.D., Rafi Sheikh, M.D., *† and Malin Malmsjö, M.D., Ph.D.*†

*Department of Clinical Sciences, Skåne University Hospital, Lund University; †Department of Ophthalmology, Skåne University Hospital, Lund University; and ‡Department of Cardiothoracic Surgery, Skåne University Hospital, Lund University, Lund, Sweden

Purpose: Free skin grafts are frequently used in reconstructive surgery. However, little is known about the course of reperfusion due to the previous lack of reliable perfusion monitoring techniques. The aim of this study was to use state-of-the-art laser speckle contrast imaging to monitor free skin grafts in the periocular area.

Methods: Seven patients needing surgery due to tumor removal or cicatricial ectropion in the periocular region underwent reconstructive surgery using free skin grafts from either the contralateral upper eyelid or the upper inner arm. The free skin grafts measured 10–30 mm horizontally and 9–30 mm vertically. Blood perfusion was monitored using laser speckle contrast imaging immediately postoperatively (0 weeks) and at follow-up after 1, 3, and 7 weeks.

Results: All grafts were reperfused gradually during healing, the median value being 46% in the central part of the graft after 1 week and 79% after 3 weeks. The grafts were completely reperfused after 7 weeks. No difference was observed in the rate of reperfusion between the center and periphery of the grafts ($p =$ not significant). The cosmetic and functional outcome was excellent in all but 1 patient, who developed ectropion that had to be surgically corrected.

Conclusions: Skin grafts in the periorbital area are fully reperfused after 7 weeks. The periocular area is known to be well-vascularized and thus forgiving to reconstructive surgery. Future investigations of the reperfusion of free skin grafts in other parts of the body or in higher-risk populations should be carried out.

(*Ophthalmic Plast Reconstr Surg* 2020;XX:00–00)

The tissue available in reconstructive surgery in the periocular area is often limited, and it may be difficult to ensure wound coverage. In cases where primary closure or closure using flaps

is not possible, free full-thickness skin grafts are often considered. In reconstructive surgery in the periocular area, skin grafts from the inside of the arm, the pre- and postauricular area, the supraclavicular fossa, or the contralateral upper eyelid above the skin crease, are often preferred.¹

The process of reperfusion has been studied since the latter half of the 1800s.^{2–4} However, the process of reperfusion of skin grafts is still not fully understood. Perfusion monitoring has long been performed through clinical examination, as first described by the Italian Renaissance surgeon, Gaspare Tagliacozzi, that is, by feeling the temperature of the skin, observing the color, and measuring the capillary refill time.⁵ This kind of clinical examination is rapidly and easily performed, and is still used by surgeons worldwide. However, the method is highly subjective and dependent on the experience of the surgeon. Technological developments have led to other observer-independent methods of evaluating perfusion. One of the most widely used is fluorescence angiography, a technique first introduced by Lange and Boyd in 1943⁶ to study blood perfusion in peripheral vascular diseases. Sodium fluorescein was originally used as the fluorescent agent, but in 1973 Flower and Hochheimer introduced indocyanine green into the fluorescence technique.⁷ The patient is given an intravenous injection of indocyanine green, and an image of the perfusion is obtained using an infrared camera. However, this technique is invasive, and is not suitable for monitoring perfusion over time. Thermal imaging is a noninvasive technique in which an infrared camera is used to detect heat. However, there is a delay between the change in perfusion and the change in temperature, and other mechanisms apart from perfusion may lead to changes in the temperature of the tissue, for example, other metabolic processes in the cells such as inflammatory responses. Methods such as intravenous injections of radioisotopes have been used in animal models,⁸ and the examination of histological sections after skin grafting has been performed in humans,⁹ however, these methods are not suitable in clinical practice.

Laser-based techniques have recently emerged, enabling the noninvasive monitoring of perfusion in the clinical setting. In laser speckle contrast imaging (LSCI) the skin area of interest is illuminated by infrared (785 nm) laser light. Dark and bright areas are created by interference of the light backscattered from moving particles in the illuminated area, creating a speckled pattern. This pattern is recorded in real-time by a camera, and the perfusion is automatically calculated by the system by analyzing the variations in the speckle pattern created by moving particles. It is generally believed that the measurement depth of LSCI is 300 μ m. After transplantation changes take place in both the

Accepted for publication August 27, 2020.

This study was supported by the Swedish Government Grant for Clinical Research (ALF), the European Union's Horizon 2020 programme for Research and Innovation, Skåne University Hospital (SUS) Research Grants, Skåne County Council Research Grants, Crown Princess Margaret's Foundation (KMA), the Foundation for the Visually Impaired in the County of Malmöhus, The Nordmark Foundation for Eye Diseases at Skåne University Hospital, the Diabetes Society of South-West Skåne, and the Swedish Eye Foundation.

Address correspondence and reprint requests to Malin Malmsjö, M.D., Ph.D., Skåne University Hospital, Ögonklinik A, Admin, 2nd floor, Kioskgatan 1, SE-221 85 Lund, Sweden. E-mail: malin.malmsjo@med.lu.se

DOI: 10.1097/IOP.0000000000001851

wound bed and the skin graft. According to microscopic observations in mice, preexisting graft vessels are believed to act as nonviable conduits during the revascularization process.¹⁰ One disadvantage of the LSCI technique is that the signal does not discriminate between the formation of capillaries and a change in the microvascular architecture of the graft and changes in the dimensions of capillaries leading to a change in blood flow. Neither do we know how the change in the papillary networks in the dermal-epidermal junction of skin after skin transplantation affect the measurement. We recently used LSCI to monitor the reperfusion of free, full-thickness skin grafts used as the anterior lamella in the modified Hughes procedure, where the free graft is placed on a tarsoconjunctival flap.¹¹ However, most free skin grafts in clinical practice are placed on a vascularized wound bed, rather than on a flap,¹² and the reperfusion of these kinds of grafts has not previously been studied using modern imaging technique. This study was performed to monitor the reperfusion of free skin grafts when placed on a vascularized wound bed in the periorcular area, using LSCI.

METHODS

Ethics. Ethical approval was obtained from the Ethics Committee at Lund University, Sweden. The research followed the Declaration of Helsinki as amended in 2008. Fully informed consent was obtained from all patients included in the study.

Subjects. A total of 7 patients, 2 women and 5 men, were included between October 2016 and March 2020. Three of the patients required reconstructive surgery following the excision of a basal cell carcinoma, and 2 following the excision of a squamous-cell skin carcinoma. Two patients had developed cicatricial ectropion; one caused by previous trauma and the other by previous tumor excision with successive shortening of the anterior lamella. The median age was 86 years (range 60–92 years). One patient was taking antihypertensive medication and 1 patient suffered from diabetes. Two patients with cardiovascular conditions were taking anticoagulants. None of the participants was currently a smoker, but 4 patients were former smokers who had quit smoking more than 5 years ago. No patient had previous radiotherapy in the periorcular area. More skin grafts were performed during this period, but due to logistic reasons, the authors were not able to include them all.

Surgical Procedure. Surgery was performed under local anesthesia using lidocaine (20 mg/ml) (Xylocaine; AstraZeneca, Södertälje,

Sweden). Epinephrine was avoided because of its vasoconstrictive effect, which would have influenced the LSCI measurements. The full-thickness skin graft was harvested from the contralateral upper eyelid ($n = 4$) or the inside of the upper arm ($n = 3$). After harvesting the graft, underlying adipose tissue and hair follicles were removed. The graft was then trimmed so as to be 1.5 times larger than the recipient site, to avoid wound contraction. The free skin grafts measured 10–30 mm horizontally and 9–30 mm vertically. The grafts were used to cover defects on the lower eyelid ($n = 3$), the upper eyelid ($n = 2$), the median canthal area ($n = 1$), or the upper cheek ($n = 1$). The graft was secured with continuous and/or simple interrupted 6-0 non-resorbable (Ethilon 6-0; Ethicon, Somerville, NJ) or resorbable 6-0 sutures (Vicryl 6-0; Ethicon). Great care was taken to minimize the tension when suturing the graft in place. Stab incisions were made in grafts larger than 15 mm to allow for drainage of fluid and adhesion to the recipient bed. A secure pressure dressing was applied over the surgical site to ensure that the graft maintained direct contact with the underlying wound bed, and to immobilize it during healing. The cotton bolster, secured with Tegaderm (3M Company, St. Paul, MN), remained in place until days 2–3. Great care was taken to avoid pressure on the graft, as it would most likely influence reperfusion. Frost sutures, using 4-0 non-resorbable sutures (Silk 4-0, Ethicon) were used in all patients receiving free skin grafts in the lower eyelid to provide upward tension, and were also left in place for 2–3 days. The patients were told to avoid trauma to the site and strenuous activity for 2 weeks after surgery. The sutures were removed after 1 week. Surgery was performed by 2 experienced senior surgeons at the Department of Ophthalmology at Skåne University Hospital, Lund, Sweden.

Perfusion Measurements. Blood perfusion was monitored using a PeriCam PSI NR System (Perimed AB, Stockholm, Sweden). Perfusion was monitored immediately postoperatively (denoted 0 weeks) and on 3 follow-up occasions. Due to logistic reasons, the time of the follow-up visits varied. The data were therefore grouped into the following time intervals: follow-up at 7–8 days (denoted 1 week), 21–28 days (denoted 3 weeks), and 39–54 days (denoted 7 weeks).

Calculations and Statistics. When using LSCI, perfusion is expressed in arbitrary units, that is, perfusion units. The results were normalized to the value of perfusion obtained at a reference point in intact skin just outside the graft (which was set to 100%) (Figure 1). The reference point was infiltrated with local anesthesia in the same way as the surgical area. The perfusion at the reference point was measured at each follow-up visit to the clinic. Zero perfusion values

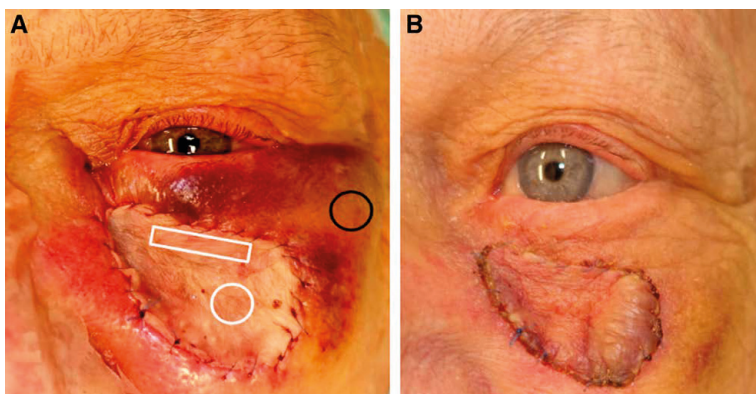


FIG. 1. Photograph of a free full-thickness skin graft immediately after surgery (**A**). Regions of interest (ROI) used for perfusion measurements are shown at the center (white circle) and along the periphery (white rectangle) of the graft. Perfusion was expressed as the percent of perfusion at a reference point just outside the graft (black circle). (**B**) The same graft 1 week after surgery.

were obtained from the graft immediately after suturing it in place. At this stage, the graft is completely avascular, and the perfusion values obtained are the result of a combination of movement artifacts and the biological zero, that is, the signal obtained from tissue in the absence of vascular flow. These immediate postoperative values were therefore set to 0%, and were subtracted from the perfusion values obtained at postoperative follow-up.

GraphPad Prism 7.0a (GraphPad Software Inc., San Diego, CA) was used for calculations and statistical analysis. Results are expressed as median values with 95% confidence intervals. Statistical analysis was performed using the Kruskal-Wallis test with Dunn's test for multiple comparisons. Significance was defined as: * $p < 0.05$, ** $p < 0.01$, *** $p < 0.001$, **** $p < 0.0001$, and $p > 0.05$ (not significant).

RESULTS

The perfusion results obtained with the PeriCam showed that the free skin grafts were rapidly reperfused (Figure 2). After 1 week the perfusion was 46% in the central part of the graft, and after 3 weeks 79%. However, after 3 weeks, 2 of the grafts were fully reperfused. Complete reperfusion, that is, that did not differ significantly from that in the surrounding tissue, was seen after 7 weeks ($p =$ not significant). No difference was observed between the perfusion at the center and along the periphery of the graft, indicating revascularization of the entire graft from the underlying wound bed.

All free skin grafts survived and healed well. There was no sign of ischemia or pressure necrosis. Both the cosmetic and functional outcome was excellent in all but 1 patient, who developed postoperative

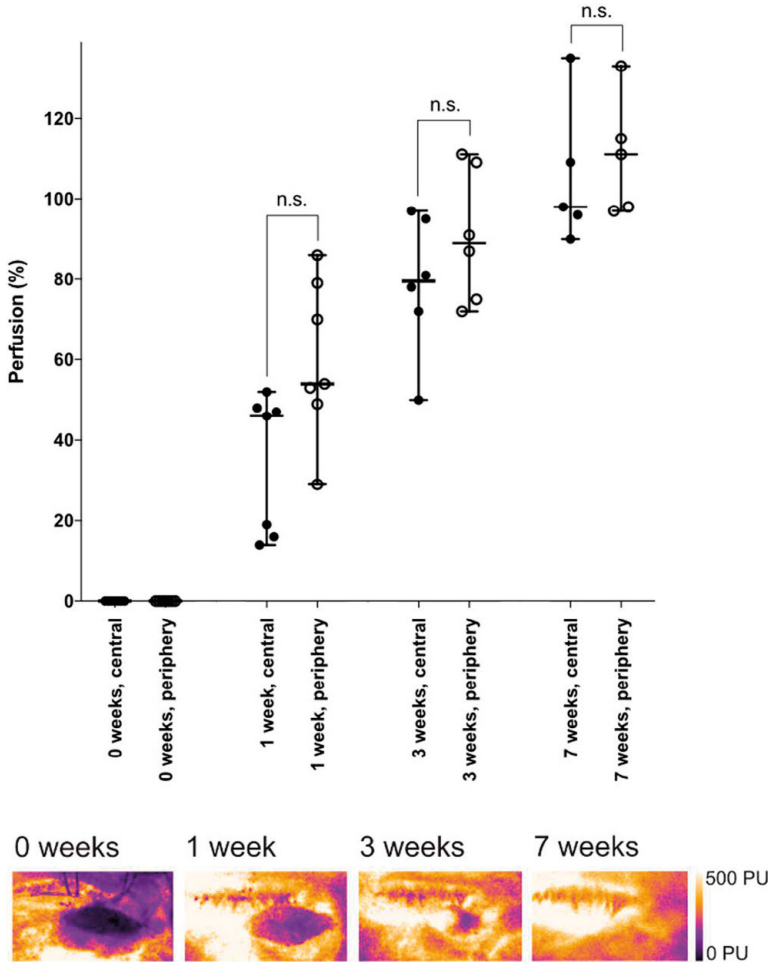


FIG. 2. Above: a scatterplot showing the blood perfusion in the free skin grafts, immediately postoperatively (0 weeks), and at follow-up after 1, 3, and 7 weeks. Perfusion was measured at the center and along periphery of the grafts. Data are expressed as the percentage (median values and range) after normalization to the perfusion at a reference point just outside the grafts (100%). It can be seen that reperfusion occurred simultaneously in the center and periphery of the graft, and that complete reperfusion was achieved after 7 weeks. Below: representative examples of laser speckle contrast images.

ciatricial ectropion of the lower eyelid, which was later surgically corrected. No complications were reported at the donor sites.

DISCUSSION

To the best of the authors' knowledge, this is the first study of the reperfusion of free skin grafts on a vascularized bed in the periocular region. We found that revascularization took place rapidly; reaching 79% in 3 weeks in the central part of the graft, and complete reperfusion after 7 weeks. Reperfusion of free full-thickness grafts has previously been studied in animals and other regions of the human body, using other techniques than LSCI. The process of revascularization takes place through anastomoses between blood vessels of the graft and the recipient, known as inoculation.^{13,14} Angiogenesis also takes place in the wound bed, and the new blood vessels invade the graft (ingrowth). Preexisting graft vessels have been shown to act as nonviable conduits for the invasion of new vessels.¹⁰

Skin graft reperfusion has mainly been studied using microscopy and histological examinations. In 1956, Converse and Rapaport¹⁵ used microscopy to study the results of full-thickness grafting on the radial aspect of the volar surface of the forearm in humans and found sluggish flow in the vessels in the graft on the third day postoperatively. Cyanotic discoloration was observed during the first 6–7 days, suggesting poor blood flow. These observations are consistent with our finding that the free full-thickness grafts are reperfused rapidly. Rapid reperfusion was also reported by Ohmori and Kurata⁸ in 1960 using intravenous injections of radioisotopes in a rabbit model, showing blood flow and isotope uptake in the graft 4 days postoperatively. In 1968, Clemmesen and Ronhovde⁹ took biopsies from humans after skin grafting, and found dilated vessels connected to the original vessels of the graft 3 days later. More recently, in 2006, Capla et al.¹⁶ observed vascular ingrowth in the periphery of full-thickness grafts in a mouse model on day 3 through histological examination. In 2008, Lindenblatt et al. described a mouse model that allowed continuous monitoring of the microcirculation during skin graft healing using repetitive intravital microscopy. They reported that capillary buds and sprouts were visible on day 2, and that the graft capillaries contained blood on day 3. They concluded that the original skin microcirculation was almost completely restored on day 5.¹⁷ Animal models such as the ones described above have been used in many studies on the healing of full-thickness skin autografts, but differences between the vascular systems in animals and humans prevent direct comparisons. This might explain the difference in time between those studies and the present one. The periocular area is known to be forgiving in reconstructive surgery, which may be due to the rich vascularization of this region. It should, however, be borne in mind that the skin grafts in this study were very thin, that is, only 2–3 mm thick. Skin grafts in other regions of the body may be thicker, which might influence the rate of reperfusion and the survival of the graft.

The LSCI signal was somewhat reduced in the weeks after surgery. It cannot be deduced from the present study whether this reduction was due to reduced perfusion in the graft, or because the graft was thicker than normal, non-transplanted skin. The graft is generally designed to be larger than the defect, and hence somewhat folded in order to allow shrinkage in the postoperative phase.

Several factors are thought to influence the survival of grafts; the underlying graft bed being one of the most important. Grafts placed on well-vascularized tissue are believed to be more likely to survive than those on a less vascularized tissue. A graft placed on a non-vascularized tissue, such as bone without periosteum, is not expected to survive.¹⁸ Grafts placed on poorly vascularized wound

beds have been found to be ischemic for longer periods than grafts placed on wound beds with better blood perfusion.¹⁹

When studying skin grafts in the modified Hughes procedure 2019, we found that the grafts overlying the tarsus was reperfused at the same rate, and survived as well as the grafts applied to orbicularis muscle.¹¹ We attributed these observations to the rich vascularization of the periocular area, and the fact that the grafts had been soaked in tear fluid, which is known to have the similar spectrum of nutrients as the blood.²⁰

The results of the study are mainly of interest to ophthalmic plastic surgeons. The main limitation of the present study is the limited number of participants, which did not allow subgroup analyses. Therefore, factors known to affect blood perfusion and compromise the oxygenation of tissue, such as smoking, diabetes, previous surgery, or radiation therapy, could not be taken into account. Furthermore, the size of the graft varied considerably between patients, which could have influenced the outcome. Again, the small number of patients did not allow any analysis of the effects of graft size on reperfusion. Another limitation of the present study is that perfusion measurements could not be made on a daily basis since it was impractical. The study was conducted in an outpatient clinic, and many of the patients had to travel far to attend follow-up.

In conclusion, free full-thickness skin grafts in the periocular area were found to be completely reperfused after 7 weeks. The periocular area is known to be well-vascularized and thus forgiving to reconstructive surgery. Future investigations should focus on the reperfusion of free skin grafts of different sizes, in other parts of the body, or in higher-risk populations.

ACKNOWLEDGMENT(S)

We would like to thank all the surgical staff involved at the Department of Ophthalmology, Skåne University Hospital, for their kind cooperation in this work. Helpful advice on language and linguistics was given by Helen Sheppard.

REFERENCES

- Collin J. *A Manual of Systematic Eyelid Surgery*. 3rd ed. Philadelphia, PA: Elsevier Inc., 2006.
- Bert P. *De la Greffe Animale*. Paris: Ballière et Fils, 1863.
- Hübscher C. Beiträge Hautverpflanzung nach Thiersch. *Beitr Klin Chir* 1888;4:395.
- Goldmann EE. Die kunstliche Ueberhautung offener Krebs durch Hauttransplantationen nach Thiersch. *Zentralbl All Pathol* 1890;1:505.
- Pickard A, Karlen W, Ansermino JM. Capillary refill time: is it still a useful clinical sign? *Anesth Analg* 2011;113:120–123.
- Lange K, Boyd LJ. Use of fluorescein method in establishment of diagnosis and prognosis of peripheral vascular diseases. *Arch Intern Med* 1944;74:175–184.
- Flower RW, Hochheimer BF. Indocyanine green dye fluorescence and infrared absorption choroidal angiography performed simultaneously with fluorescein angiography. *Johns Hopkins Med J* 1976;138:33–42.
- Ohmori S, Kurata K. Experimental studies on the blood supply to various types of skin grafts in rabbits using isotope P32. *Plast Reconstr Surg Transplant Bull* 1960;25:547–555.
- Clemmesen T, Ronhovde DA. Restoration of the blood-supply to human skin autografts. *Scand J Plast Reconstr Surg* 1968;2:44–46.
- Zarem HA, Zweifach BW, McGehee JM. Development of microcirculation in full thickness autogenous skin grafts in mice. *Am J Physiol* 1967;212:1081–1085.
- Berggren J, Tenland K, Ansson CD, et al. Revascularization of free skin grafts overlying modified Hughes tarsoconjunctival flaps monitored using laser-based techniques. *Ophthalmic Plast Reconstr Surg* 2019;35:378–382.
- Tenland K, Memarzadeh K, Berggren J, et al. Perfusion monitoring shows minimal blood flow from the flap pedicle to the tarsoconjunctival flap. *Ophthalmic Plast Reconstr Surg* 2019;35:346–349.

13. Clemmesen T. Experimental studies on the healing of free skin autografts. *Dan Med Bull* 1967;14:(suppl 2):1-73.
14. Clemmesen T. (The early circulation in split-skin grafts. Restoration of blood supply to split-skin autografts.). *Acta Chir Scand* 1964;127:1-8.
15. Converse JM, Rapaport FT. The vascularization of skin autografts and homografts; an experimental study in man. *Ann Surg* 1956;143:306-315.
16. Capla JM, Ceradini DJ, Tepper OM, et al. Skin graft vascularization involves precisely regulated regression and replacement of endothelial cells through both angiogenesis and vasculogenesis. *Plast Reconstr Surg* 2006;117:836-844.
17. Lindenblatt N, Calcagni M, Contaldo C, et al. A new model for studying the revascularization of skin grafts in vivo: the role of angiogenesis. *Plast Reconstr Surg* 2008;122:1669-1680.
18. Flowers RS. Unexpected postoperative problems in skin grafting. *Surg Clin North Am* 1970;50:439-456.
19. La P. *Transplantation of Tissues*. Baltimore: Williams & Wilkins, 1955.
20. Jalbert I. Diet, nutraceuticals and the tear film. *Exp Eye Res* 2013;117:138-146.

Review



Perfusion Monitoring During Oculoplastic Reconstructive Surgery: A Comprehensive Review

Johanna V. Berggren, M.D., Magne Stridh, M.D., Malin Malmsjö, M.D., PH.D.

Department of Clinical Sciences Lund, Skåne University Hospital, Lund University, Ophthalmology, Lund, Sweden

Purpose: Knowledge of how blood perfusion is affected during and after reconstructive surgery is of great importance to predict the survival of grafts and flaps. When commonly used reconstructive procedures were developed a century ago, they were based on empirical observations of clinical outcome.

Methods: This is a comprehensive literature review that summarizes the current state of knowledge regarding microvascular perfusion monitoring during oculoplastic procedures.

Results: Over the years, a number of techniques for perfusion monitoring have been developed as an attempt to be more objective than clinical examination using traditional methods such as observations of skin temperature, turgor, color, smell, and capillary refill time. There are limited publications regarding microvascular perfusion monitoring during reconstructive procedures in the periocular area. Modern laser-based techniques have been attractive due to their noninvasive nature.

Conclusions: Today, modern, noninvasive techniques are available to monitor perfusion during and after surgery. This has increased our knowledge on the perfusion in common oculoplastic surgery procedures. A detailed understanding of how blood perfusion is affected will hopefully allow the improvement of surgical techniques for better clinical outcome.

(*Ophthalmic Plast Reconstr Surg* 2021;00:00–00)

An adequate blood supply is important for the success of skin flap or free skin grafts in plastic reconstructive surgery, and oculoplastic surgeons must, therefore, have considerable knowledge on the perfusion in the periorbital area. However, the clinical rules of thumb concerning the design of flaps are mostly based on empirical observations and beliefs, rather than actual knowledge of blood perfusion. Several imaging techniques have been developed during the past decades offering high-resolution images of the structure and function of tissue. Peroperative monitoring can improve our understanding of how

blood perfusion is affected by surgical interventions and will hopefully allow surgical techniques to be improved, resulting in better clinical outcome. Despite the significant interest in blood perfusion among surgeons, knowledge regarding blood perfusion during and after reconstructive surgery in the periocular area is still limited. This article presents a comprehensive review of modern techniques for perfusion monitoring and the current state of knowledge regarding the effects on blood perfusion in the periocular area during and after reconstructive surgery.

VASCULAR ANATOMY

Knowledge of the arterial supply to the periocular area is essential when anticipating the effects of reconstructive surgery on blood perfusion. The vascular anatomy of the eyelids is illustrated in Fig. 1. The eyelids are mainly supplied by the internal carotid artery via the ophthalmic artery and secondarily by the external carotid artery, through the branches of the infraorbital, facial, and superficial temporal arteries. Branches of the lacrimal artery, i.e., the lateral superior and inferior palpebral arteries, run in the lateral to medial direction in the upper and lower eyelids. Together with the medial palpebral arteries, they create an anastomosis, forming the superior and inferior arterial arch of the eyelids.¹ The anatomy of the periocular vascular system has mostly been investigated by the dissection of human cadavers.² Novel perfusion and oxygenation monitoring techniques provide the opportunity to learn more about the physiology of blood perfusion in the periocular area in vivo.

TECHNIQUES FOR MONITORING BLOOD PERFUSION AND OXYGENATION

The assessment of the viability of tissue during and after surgery is of outermost importance, especially in complex surgical procedures. Clinical examination allows the surgeon to examine the status of perfusion using traditional methods such as observations of skin temperature, turgor, color, smell, and capillary refill time.³ Other techniques for the clinical evaluation of perfusion include bleeding following a pinprick test to assess the color (bright red vs. cyanotic) and speed of flow (brisk vs. slow).⁴ The observation of clinical signs is a highly subjective means of assessing perfusion and depends on the experience of the surgeon. There has thus been a need to develop techniques to monitor perfusion objectively. Brief descriptions of these techniques are given below.

Pharmacological Agents

Various pharmacological agents were employed in early studies on blood perfusion. For instance, in 1948, Hynes demonstrated a technique for estimating blood flow in pedicle skin flaps and tubes using the vasodilator activity of atropine.⁵ Conway et al. used the cutaneous histamine reaction to evaluate

Accepted for publication October 30, 2021.

This study was supported by the Swedish Government Grant for Clinical Research (Avtal om Läkarutbildning och Forskning), the European Union's Horizon 2020 Programme for Research and Innovation, Skåne University Hospital (Skånes Universitetssjukhus) Research Grants, Skåne County Council Research Grants, Crown Princess Margaret's Foundation (Kronprinsessan Margaretas Arbetsnämnd), the Foundation for the Visually Impaired in the County of Malmöhus, The Nordmark Foundation for Eye Diseases at Skåne University Hospital, the Diabetes Society of South-West Skåne, and the Swedish Eye Foundation. None of the authors has a financial interest in any of the products, devices, or drugs mentioned in this article.

Address correspondence and reprint requests to Johanna V. Berggren, M.D., Department of Ophthalmology, Skåne University Hospital, Ögonklinik A, Admin, 2nd Floor, Kioskgatan 1, SE-221 85 Lund, Sweden. E-mail: johanna.vennstrom_berggren@med.lu.se

DOI: 10.1097/IOP.0000000000002114

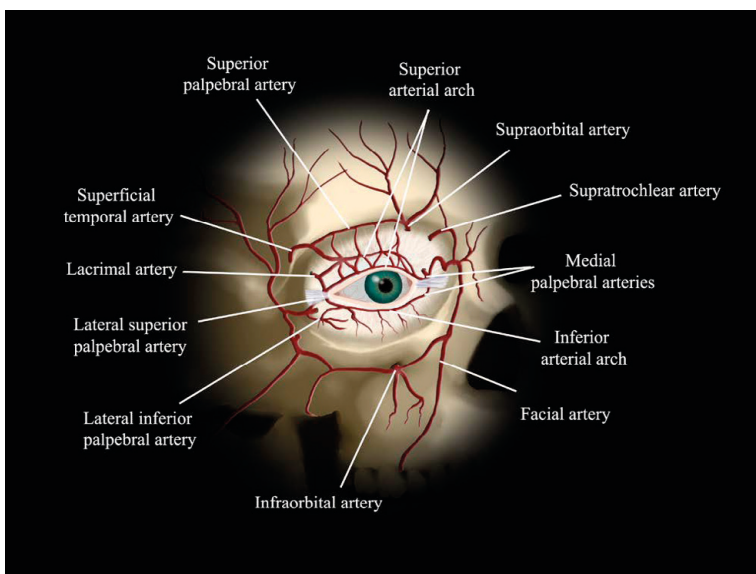


FIG. 1. The arterial supply of the periorcular area. Note how the lateral superior and inferior palpebral arteries, together with the medial palpebral arteries, create an anastomosis, forming the superior and inferior arterial arch of the eyelids.

the perfusion of tubed pedicles and flaps, as histamine is known to be a powerful vasodilator.⁶ However, these methods are invasive, they lack objectivity, and there is a risk of systemic reactions, making them less suitable.

Fluorescein Angiography

Fluorescein angiography has been a popular method due to its low cost and availability for intraoperative use. Sodium fluorescein is injected intravenously and diffuses across capillary walls into the extracellular fluid compartment. The tissue is illuminated with ultraviolet light (e.g., with a Wood's lamp), and the distribution of the fluorescent dye is observed. Fluorescent angiography has been a frequently used technique to facilitate tracing of the vasculature and has been used in many studies to monitor the blood perfusion in tissue.⁷⁻¹² Apart from being an invasive method, the dye discolors the tissue for up to 18 hours after injection, meaning that measurements cannot be repeated within 24 hours. There is also the risk of an allergic reaction to the dye, although this is relatively low. This technique has been further developed by the implementation of computer-aided digital morphometry to measure skin fluorescence. In 1996, Issing and Naumann reported that this technique gave a more reliable prediction of flap survival than pH and temperature monitoring.¹³

Indocyanine Green

Indocyanine green is another type of fluorescent dye, with absorption in the near-infrared range (790–805 nm). It is widely used in ophthalmology to examine choroidal blood flow and associated pathology. It has been proposed as an alternative to sodium fluorescein, since it has more favorable pharmacokinetics due to its protein-binding properties. There is less leakage from the capillaries, and it thus remains in the vessel longer, giving a clearer image of the vessel.¹⁴ However, its use in reconstructive surgery has been limited as it still requires an intravenous injection, and

repeated monitoring is time consuming and only possible after the dye from the previous injection has been cleared from the tissue.

Disulfine Blue

Disulfine blue dye, or similar dyes such as isosulfan blue or patent blue, is frequently used for lymphatic mapping and sentinel node biopsy in cancer surgery.¹⁵ It is also used to map fistulas before and after surgical excision.¹⁶⁻¹⁸ This technique has been shown experimentally to be useful for visualizing the perfusion of flaps.¹⁹ After injection, the dye collects in well-perfused areas and is visible to the naked eye without the need for an imaging system. However, it has been reported that blue discoloration can persist for over 12 months at the site of injection in 68% of treated patients²⁰ and that blue discoloration of the body may last for several hours.²¹⁻²³ Although rare, there are also reports of anaphylactic reactions to the dye.²¹⁻²³ This method is, therefore, not appropriate for use in the clinical setting.

pH Monitoring

Subcutaneous pH monitoring has been used to assess flap viability as inadequate tissue perfusion increases anaerobic metabolism, resulting in the accumulation of acidic metabolites. The use of subcutaneous or intramuscular probes has been demonstrated to be efficient in measuring pH to evaluate tissue viability, especially in muscle flaps where it is difficult to observe the color.²⁴ However, there is a substantial delay between a change in perfusion and in the pH, and the pH does not decrease until the process of necrosis has started. This method is, therefore, not suitable for predicting flap survival.

Radioactive Isotopes

Radioactive isotopes have been widely used to monitor myocardial perfusion^{25,26} and in porcine studies to study myocutaneous flap ischemia²⁷ and the microcirculation in

myocutaneous island flaps in pigs.²⁸ This method involves the injection of a radioactive isotope tracer into a vessel, immediately followed by scans with a gamma camera to visualize the distribution of the injected radioisotope. The uptake will be high in healthy, well-perfused tissue. Several isotopes have been used in flap surgery in humans, including sodium-22 and xenon-133. Apart from the fact that the method involves the handling of radioactive materials and waste, another drawback is that measurements cannot be repeated within 24 hours due to remaining background radioactivity.²⁹

Hydrogen Gas Clearance

Hydrogen gas clearance and radioactive isotopes are based on the same principle, but the risks associated with ionizing radiation are avoided. The subject breathes in a mixture of hydrogen and oxygen gas, and the level of hydrogen gas in the tissue is measured using implanted platinum probes. Repeated and quantitative measurements are also possible. The hydrogen is then eliminated via the lungs. This technique has not been found useful clinically since it requires a probe to be implanted in the tissue and provides only point measurements of perfusion.³⁰

Microdialysis

Microdialysis is used clinically in neurointensive care to monitor secondary cerebral ischemia after brain injury or intracranial hemorrhage. Microdialysis has primarily been used in preclinical animal studies but also in human studies to help understand, for example, skin inflammation and skin inflammatory disorders,³¹ and to monitor perfusion in the human femoral head³² and the brain.³³ Catheters, with membranes connected to a pump perfused with a suspension, are implanted in the tissue of interest. The suspension is adjusted so as to create an equilibrium between the pressure in the catheter and the interstitial fluid pressure. After the diffusion of plasma products such as glucose, lactate, pyruvate, and glycerol, a sample of the suspension is collected from the catheter and analyzed. A lactate/pyruvate ratio above 25 has been proposed by Ungerstedt and Rostami to indicate ischemia.³⁴ Hickner et al. used a microdialysis ethanol technique to determine the nutritive blood flow in skeletal muscle in a cat model and concluded that it was a simple and valid method in comparison to direct measurements.³⁵ The microdialysis technique has undergone much development since its first use in 1972,³⁶ but there is still a need for the implantation of a catheter, making it invasive and time-consuming. Furthermore, the temporal and spatial resolution are relatively low, and information on perfusion can only be obtained in a very limited volume.

Temperature Monitoring

It has been suggested that tissue temperature reflects perfusion. Skin temperature can be easily monitored using non-invasive, infrared cameras. However, skin temperature is not solely dependent on perfusion but is also affected by thermoregulating enzymes, core temperature, air temperature, humidity, light, and vasomotor responses. Although there is a delay in the change in skin temperature following a decrease in perfusion, the measurements are repeatable, and when properly performed, the sensitivity of surface-temperature monitoring using thermoelectric thermometers has been reported to be 98%, and the predictive value to be 75% when monitoring free flaps.³⁷

The Clark Electrode

The Clark electrode is an implantable probe that has been used to monitor flap oxygenation and predict viability.^{38,39} It has also been used as part of a postoperative warning system

for impaired flap oxygenation, leading to successful surgical interventions.⁴⁰ The electrode is enclosed in a semipermeable membrane, allowing tissue oxygen to diffuse into the electrode chamber, where it is reduced by a gold polarographic cathode. This produces an electric current that is proportional to tissue oxygenation. The electrode only allows a point measurement around the electrode, making it susceptible to the detection of nonrepresentable data in tissues with heterogeneous oxygenation.

Spectroscopic Methods

Oxygen saturation can also be assessed using spectroscopic methods, such as near-infrared spectroscopy. Tissue is exposed by light in the 690- to 1000-nm spectral range where different molecular components exhibit unique absorption features. The light that is not absorbed and is reflected by the tissue is measured, from which the absorbing species can be identified. Hemoglobin has different wavelength absorption peaks when it is oxygenated and deoxygenated, allowing the analysis of tissue oxygenation and perfusion. A small probe that both emits the light and detects the reflected light can either be implanted subcutaneously or placed on the skin surface. Techniques employing a wider spectral range (900–1700nm) have evolved that provide comprehensive information on blood perfusion and tissue response in human skin.^{41,42} Spectroscopic techniques exploit the spectral information obtained from the tissue, although they lack the spatial resolution needed to identify heterogeneous tissue oxygenation.

Pulse Oximetry

The most common clinical implementation of spectroscopic methods is pulse oximetry. This method compares the transmittance of light of two different wavelengths in the near-infrared spectral range (660 and 940nm) through tissue and is based on the fact that oxygenated and deoxygenated hemoglobin absorb light differently. The total amount of hemoglobin determines how much light is transmitted at both wavelengths. The volumetric changes in blood flow can also be determined continuously by measuring the transmittance several times per second. Surface-based pulse oximetry is widely used in the clinical setting to monitor oxygen saturation during anesthesia or failing vital functions over a relatively small surface area, such as the tip of a finger, a toe, or an earlobe.

Diffuse Optical Tomography

Diffuse optical tomography is an imaging modality employing near-infrared spectroscopy and is capable of providing a spatial map of oxygen saturation over a larger area. It is based on the same principle of absorption and reflection, as described above, but employs an array of probes that systematically emit and detect light from different locations, allowing a tomographic image of the sample to be constructed. The equipment is relatively compact and can be transported for bedside use. The disadvantage of diffuse optical tomography is that image stability is obtained at the expense of spatial resolution, which is limited to ≈ 1 cm. To overcome this obstacle, diffuse optical tomography is often combined with other imaging modalities with high spatial resolution, such as magnetic resonance imaging or ultrasound, which allows the clinician to interpret the diffuse optical tomography findings based on a more anatomically precise image.⁴³

Hyperspectral Imaging

Hyperspectral imaging is a noninvasive technique in which the tissue is irradiated using a white incandescent light source (broad spectrum), after which the reflected light is

processed to extract a map of spatially resolved reflectance spectra. Hyperspectral imaging has found use in the clinical setting in providing spatial maps of oxygen saturation of skin flaps, arms, and legs.^{44,45} As the technique employs white light, it could be used in the periorcular area, although this has not yet been done.

Standard Commercial Red Green Blue Cameras

Standard commercial Red Green Blue cameras capture images with spectral information corresponding to the sensitivity of human vision. Although the spectral information is not as extensive as that obtained with hyperspectral imaging methods, Red Green Blue cameras can be used to qualitatively assess changes in blood flow and oxygenation. Sheikh et al. demonstrated this by monitoring vasoconstriction of the superficial vascular plexus in human forearm skin following an injection of lidocaine and epinephrine.⁴⁶ Blanching of the skin led to slightly different responses in the three color channels, and the overall change in all three channels, compared to baseline values, allows monitoring of the relative changes in blood perfusion over time.

Magnetic Resonance Angiography

Magnetic resonance angiography has been found successful in monitoring arterial and venous occlusion experimentally, but its availability is so limited that it is of little practical use.

Photoacoustic Imaging

Photoacoustic imaging is regarded as one of the most promising noninvasive biomedical imaging techniques and offers molecular images with high spatial resolution.⁴⁷ The benefits of spectroscopic-based specificity and ultrasound imaging depth are combined. Photons are transmitted from a laser source are absorbed in the tissue and the thermoelastic response gives rise to acoustic waves. The detection of sound, using an ultrasound probe, to determine the light absorption affords photoacoustic imaging the unique feature of high spatial resolution. If the absorption spectra is analyzed by applying spectral unmixing, it is possible to extract molecular information, including relative concentrations of oxyhemoglobin and deoxyhemoglobin.⁴⁸ Using photoacoustic imaging, it is possible to map oxygen saturation at specific locations in the tissue, noninvasively.

Most of the studies in which photoacoustic imaging was used to assess the possibility of measuring oxygen saturation have so far been performed preclinically.^{49,50} Photoacoustic imaging was recently adapted for the examination of the temporal region in humans⁵¹ and was proven safe with regard to visual function.⁵² However, its future use in the periorcular area is envisaged, provided that the energy levels of the laser light are closely regulated and the eyes are protected. The pigment cells of the retina absorb light in the 680- to 970-nm wavelength range, and there is thus a risk of damage when using photoacoustic imaging. However, the most important factors are the absorption power and the focusing effect of the lens and cornea, and photoacoustic imaging with low energy levels and the eyes closed should not pose a risk. However, further studies are needed on the safety of the method before it can be applied in vivo. This technique has considerable potential for translation to the clinical setting since it allows noninvasive molecular imaging at high resolution at sufficient imaging depths, with diverse endogenous and exogenous contrast. Initial studies have shown that photoacoustic imaging can map tissue oxygenation in humans.^{53,54} A recent study proved the feasibility of preoperative vascular mapping in human thigh flap surgery,⁵⁵ and it may be a good indicator of the degree of tissue damage in patients with skin burns.^{55,56} Initial studies of eyelids show clear spectral differences between different anatomical structures,⁵⁷ and

tumors of the eyelids can be delineated to achieve a more precise excision.⁵⁸ Photoacoustic imaging is a promising technique for monitoring oxygenation during reconstructive surgery, but further studies are needed.

Laser Doppler Flowmetry

The first laser was introduced in 1960⁵⁹ and laser-based techniques are today the most frequently used clinically to assess microcirculation. Laser Doppler flowmetry is based on the Doppler principle. The skin is illuminated by coherent laser light at infrared or near-infrared wavelengths that penetrate the surface. Light particles hitting moving red blood cells undergo a change in wavelength, a so-called Doppler shift, while light particles encountering static structures will be reflected unchanged.⁶⁰ The signal is interpreted as perfusion and given in arbitrary units. Laser Doppler flowmetry allows changes in perfusion to be monitored in real time at the bedside. However, skin surface probes, or filament or needle probes, need to be inserted into the tissue and perfusion is only measured in a volume of about 1 mm³ around the probe.^{61,62}

Laser Doppler Perfusion Imaging

Laser Doppler perfusion imaging has been developed to overcome the problems associated with small sampling areas and the variability due to the spatial heterogeneity in the microcirculation of the skin. The scattered light, from the scanning laser beam, is detected by a photodetector, in the same way as in the laser Doppler flowmetry technique. In laser Doppler perfusion imaging, the wavelength of the reflected light is also affected by the movement of red blood cells (as described above). It has been used for tissue monitoring in conjunction with reconstructive surgery, but is not used to any great extent clinically. However, attempts have been made to overcome the long acquisition time, and the technique is used at some centers for burn wound assessment.^{43,63,64} The greatest drawback yet to be overcome is that any tissue motion during the lengthy scan will be interpreted by the system as falsely high blood flow, in addition to compromising the accuracy of flow in the various regions.

Laser Speckle Contrast Imaging

Laser speckle contrast imaging (LSCI) is often considered the most useful, noninvasive technique for clinical perfusion monitoring in reconstructive surgery. It was introduced in 1993 by Yamamoto et al., who reported a new visual blood flow meter employing a dynamic laser speckle effect.⁶⁵ The technique was initially introduced to evaluate retinal blood flow in various diseases, including glaucoma, retinopathy, and macular degeneration,^{66,67} and has evolved into a method with the potential to monitor perfusion during reconstructive surgery.⁶⁸⁻⁷⁰ The principle of LSCI is illustrated in Fig. 2. The area of interest is illuminated by an infrared laser at 785 nm. Interference of the light backscattered from moving particles in the illuminated area results in dark and bright areas, creating a speckled pattern. This speckled pattern is recorded in real time by a camera. The system then calculates movement in the tissue by analyzing the variations in the speckled pattern. The movement is interpreted as a measure of perfusion. The main advantage of LSCI is that it is completely noninvasive and does not require contact with the tissue. Other advantages include short acquisition times and high spatial resolution; the speckle pattern being recorded in real time at a rate of up to 100 images per second, with a high resolution of 100 $\mu\text{m}/\text{pixel}$. LSCI enables a relatively large area to be monitored, e.g., 24×24 cm, which makes it less sensitive to regional variations in microvasculature, generating data with

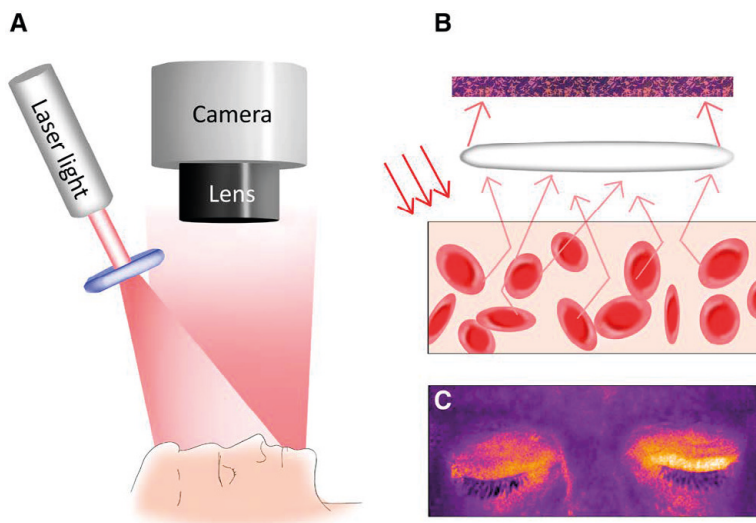


FIG. 2. The principle of laser speckle contrast imaging. **A,** The technique employs an infrared 785 nm laser beam that is diffusely reflected from the surface of the skin. The backscattered light forms an interference pattern consisting of dark and bright areas (speckle pattern) that are recorded by a camera. **B,** The variation in the speckle pattern is caused by movements in the tissue. Since the movements are mainly caused by moving red blood cells, the signal can be interpreted as perfusion. **C,** The speckle pattern is analyzed by the computer, and an image is presented on the monitor. White and yellow denote areas with high perfusion, while the dark areas show lower perfusion.

less interobserver variability than the laser Doppler technique.⁷¹ However, due to the absence of contact between the tissue and sensors, environmental conditions, such as room lighting, may affect the results.⁷²

Laser-based techniques are sensitive to tissue movement, e.g., due to breathing or other involuntary movements. Various methods of overcoming this problem have been suggested, such as shorter sampling times, careful selection of appropriate images for analysis, and simultaneous recording of the signal backscattered from an adjacent opaque surface.⁷³ The perfusion at a given point in time is also affected by the peripheral circulation of the patient, which will vary as a result of physical activity, smoking, food intake, and temperature. In order to compare measurements made at follow-up and between different individuals, the perfusion measured in, for instance, a skin flap must be normalized to a reference point outside the flap where the basal blood perfusion should be unaffected by surgery. Furthermore, the maximum penetration depth of laser-based techniques is about 0.3 to 1 mm, depending on the vascular anatomy and the concentration of red blood cells in the upper dermis.⁶² This means that perfusion is monitored in the outermost layer of the skin, while the spatial resolution in the deeper layers, which are of interest, for example, in the evaluation of burn injuries, is poor. Despite these drawbacks, LSCI is today the most commonly used technique for perfusion monitoring during reconstructive surgery⁶⁸⁻⁷⁰ and for the assessment of burns^{71,74-76} and wound healing.⁷⁷

PERFUSION AND OXYGENATION MONITORING IN OCULOPLASTIC SURGERY

The earliest records of plastic reconstructive surgery have been found in an ancient Egyptian document called the "Edwin Smith Papyrus," probably dating from the early dynastic period

around 1500 BC. This document describes a variety of surgical procedures. In 1920, Sir Harold Gillies performed groundbreaking surgery on disfigured soldiers following World War I, and many of these reconstructive surgical techniques are still used today, including skin grafts and the tubed pedicle, as presented in his textbook of plastic surgery.⁷⁸ Procedures for plastic reconstructive surgery were thus developed long before techniques were available for monitoring the oxygen saturation and blood perfusion in tissue, and knowledge was mainly empirical, based on observations of the rate of flap survival. Modern techniques now allow the systematic evaluation of the effects of surgical procedures on perfusion,⁷⁹ allowing improvements of existing surgical procedures and the development of new ones. The present review focuses specifically on the advances in perfusion monitoring in oculoplastic surgery.

Literature Search

In order to identify studies on blood perfusion and oxygen monitoring in the periocular area, a systematic Medline search was performed on PubMed. No restrictions were placed on the date of publication. Only articles published in English were included. The search terms included "reconstructive surgery," "oculoplastic," "periocular," "periorbital," "blood flow," "blood perfusion," "oxygen," "monitoring," "flap," "skin graft," "reperfusion," "revascularization," and "viability."

Rich Vascular Supply of the Periocular Region

The first tentative attempts to monitor perfusion in the periocular area confirmed the rich vascular supply. In 1996, Mannor et al. reported in a laser Doppler perfusion imaging study that the perfusion of the eyelids was an order of magnitude higher than that in, for example, the forearm.⁸⁰ Furthermore, the perfusion in pretarsal skin was twice as high as that in preseptal

skin, which may be explained by the arterial supply by the tarsal arcades. In 2018, Fei et al. investigated blood perfusion using a full-field laser perfusion imager, showing the highest cutaneous perfusion in the eyelid.⁸¹ The rich vascular supply of the periorbital region makes it forgiving to reconstructive surgery. However, deeper knowledge of the perfusion in the periocular area may increase our understanding of the effects of reconstructive surgery and hopefully facilitate the improvement of existing surgical procedures and lead to the development of novel surgical approaches. A description of the effects on perfusion during and after common oculoplastic procedures is given below.

Tarsalconjunctival Flaps

The modified Hughes tarsalconjunctival flap is one of the most commonly used techniques for reconstructing the posterior lamella of large full-thickness eyelid defects after cutaneous malignancy excision.⁸²⁻⁸⁴ This reconstructive technique is based on the combination of an avascular graft with a vascularized flap. It comprises a vascularized tarsalconjunctival flap from the upper eyelid to reconstruct the posterior lamella and a free skin graft to reconstruct the anterior lamella.⁸⁵ The conjunctival pedicle from the upper eyelid is divided once vascularization of the reconstructed lower eyelid is deemed to be adequate, usually after 3 to 4 weeks.⁸⁶ This makes the Hughes procedure a 2-stage procedure involving the occlusion of the eye during the process of vascularization, and there is thus much to gain from making the technique a 1-stage procedure, especially in older patients with impaired vision in the contralateral eye.

Surprisingly, recent perfusion monitoring studies have shown that the perfusion in the tarsalconjunctival flap is virtually nonexistent, but despite this, the free skin graft usually revascularizes and heals without necrosis. In a porcine model of tarsalconjunctival flaps, Memarzadeh et al. used laser Doppler velocimetry and a Clark electrode to show that blood perfusion and oxygenation decreased gradually during dissection and advancement of the tarsalconjunctival flap, and at the time when the flap was sutured into place, the perfusion was negligible.³⁹ Despite this, all the flaps survived, and there was no sign of necrosis in any of the histological samples collected.³⁹ In a later study, Tenland et al. showed minimal perfusion in tarsalconjunctival flaps in humans using laser Doppler flowmetry and LSCI.⁸⁷ In a different study, the revascularization of the overlying skin grafts was studied using LSCI, showing gradual reperfusion over 3 to 8 weeks.⁷⁰

The excellent graft survival despite the lack of perfusion in the underlying flap, may be due to nourishment of the tarsus and skin graft by the vascular supply of the remaining eyelid, the tarsalconjunctival flap being a secondary, nonessential contributor. Furthermore, the tarsalconjunctival flap and the free skin grafts are soaked in tear fluid, which is known to have a high level of oxygenation and the same spectrum of nutrients as the blood.⁸⁸

Others have questioned the importance of perfusion of the tarsalconjunctival flap for the survival of the overlying graft. Bartley et al. reported premature flap dehiscence 1 to 11 days postoperatively in 8 patients who underwent the modified Hughes procedure, and all the eyelids healed well.⁸⁹ Hargiss suggested a 2-tubed conjunctival flap for providing satisfactory vascular support equivalent to an apron flap.⁹⁰ Furthermore, Leibsohn and associates intentionally made a small optical buttonhole in the flap without affecting the healing.⁹¹ In 2 studies by McNab and colleagues, satisfactory results were achieved when the conjunctival pedicle was divided already after 2 weeks.^{92,93} A shorter interval before dividing the conjunctival pedicle has been suggested by others.^{94,95}

The pedicle in the tarsalconjunctival flap offers a vertical lift by supporting the skin graft of the anterior lamella during healing. However, the disadvantage of this procedure is that the eyelids must be sewed together for several weeks. Additionally, it has been shown by Klein-Theyer et al. that the Hughes tarsalconjunctival flap may cause tear film dysfunction and damage to the corneal surface by affecting the function of the Meibomian glands.⁹⁶ Based on the knowledge that the blood perfusion in tarsalconjunctival flaps is limited, a single-stage grafting procedure may be an attractive alternative, removing the need for postoperative eye occlusion.

Single-Stage Procedures

Free Bilamellar Grafts. Free bilamellar eyelid grafting is a single-stage procedure in which a full-thickness graft is taken from the opposing or contralateral eyelid to repair large eyelid defects. In 2020, Tenland et al. reported on 10 patients undergoing free bilamellar eyelid grafts, in which perfusion monitoring using LSCI showed rapid revascularization, being 90% after 8 weeks, and the clinical outcome was excellent.⁹⁷

The use of free bilamellar grafts is supported by others. Memarzadeh et al. described a case of an upper eyelid defect that was reconstructed using a free eyelid composite graft from the lower eyelid of the ipsilateral eye. There were no complications, and the graft healed well.⁹⁸ A similar outcome was described in a case of traumatic amputation of the lateral 2/3 of the upper eyelid, which was sutured in place and survived with good results even after 10 years.⁹⁹ There are numerous other case reports extending farther back in time supporting these findings,¹⁰⁰⁻¹⁰² as well as descriptions of the technique in textbooks.¹⁰³

However, there have also been reports of partial graft necrosis in free bilamellar grafts.¹⁰³ It may be that free bilamellar grafts need to be fairly small to facilitate rapid revascularization. The grafts in the study by Tenland et al. were less than 1 cm wide.⁹⁷ The use of free composite grafts is well-known from other specialties, for example, the repair of a nasal wing defect using a free composite graft from the outer ear.^{104,105} To the best of our knowledge, the use of a composite free graft of skin and cartilage from the ear for the repair of coloboma of the nose was first published in 1946 by Brown and Cannon.¹⁰⁶ Another factor that may be of importance for graft survival is the patient's microvascular status. Further studies are needed to investigate the effects of factors like this on perfusion and the final surgical outcome.

Free Bilamellar Grafts With a Vascularized Component.

An alternative to free bilamellar grafts, to minimize the risk of necrosis, is to combine them with vascularized tissue. In 1978, Putterman suggested a technique for the repair of upper eyelid defects by removing the skin from the composite graft, creating a composite graft that consisted of eyelid margin, conjunctiva, and tarsus, which was covered by a skin flap to aid its revascularization.¹⁰⁷ In 1984, Putterman described a revision of this procedure in which a composite graft was combined with a semicircular temporal skin flap.¹⁰⁸ In 1993, Werner et al. reviewed the records of 51 patients who had undergone composite grafting (conjunctiva and tarsus) combined with a skin flap since 1983 by Putterman. The authors agreed that this was a valuable method for eyelid reconstruction that provided acceptable cosmetic results.¹⁰⁹ It would be of great interest to monitor perfusion using this procedure, since this has yet not been done.

Hewes Flap Procedure. The Hewes flap procedure is a single-stage procedure in which a tarsalconjunctival eyelid flap, based at the lateral canthal tendon, is raised and rotated, and stretched to repair the posterior lamella, while a free skin graft is used for

the repair of the anterior lamella.¹¹⁰ Perfusion monitoring has been performed in a porcine model of the Hewes flap procedure, and the results showed fairly well-preserved perfusion in the flap despite rotating and stretching it to cover a defect in the opposing eyelid.⁶⁹ Perfusion monitoring of this procedure has not yet been performed in humans.

Canthotomy

Canthotomy is frequently used to mobilize extra tissue when repairing larger lower eyelid defects.¹¹¹ Laser Doppler monitoring in a porcine model showed that wedge resection in combination with canthotomy reduced blood perfusion in the eyelid: the closer the canthotomy to the wedge resection, the lower the blood perfusion.¹¹² This is probably due to the fact that the lateral palpebral arteries that give rise to the marginal and peripheral arcades supplying the eyelid are cut.¹¹³ There are well developed anastomoses to the eyelid from the anterior ciliary arteries through the conjunctiva and from branches of the external carotid artery system, and an alternative explanation could be that the canthotomy disrupts the additional blood supply from these dermal plexus anastomoses. With this in mind, it can be speculated whether an internal cantholysis without a canthotomy, i.e., a preserved anastomotic plexus, would lead to less of a decrease in the perfusion.¹¹⁴ It may be particularly important to consider this in cases of large eyelid defects, in which lateral canthotomy is required to alleviate tension. This is seldom a problem in cases of direct closure of an eyelid defect since perfusion is unaffected on both sides of the defect. However, if avascular grafts are required to fill the defect, such as in a composite graft⁹⁷⁻¹⁰² or synthetic grafts, it should be considered whether it is wise to perform a canthotomy, as this would reduce the blood perfusion. Another procedure that should perhaps not be combined with canthotomy is the tarsoconjunctival flap in the modified Hughes procedure, since it has been shown that there is only minimal blood supply to the tarsus.^{38,87} A reconstructive procedure in which perfusion has not been studied is the use of periosteal flaps to lengthen and repair eyelids, sometimes combined with synthetic grafts. It would be interesting to monitor changes in perfusion following these procedures. In conclusion, it is necessary to consider the risk of reduced perfusion to the eyelids resulting from canthotomy, in particular, when using avascular grafts.

There may be other reasons to avoid canthotomy if it is not absolutely necessary. Thaller avoided canthotomy by closing eyelid defects under extreme tension.¹¹⁵ The eye bulb acted as an expander, and postoperative outcomes after 2 months were excellent, both cosmetically and functionally, especially in lower eyelids. Thaller recommended avoiding canthotomy since it counteracts the expansion of the eyelid.¹¹⁵⁻¹¹⁷ With careful suturing of a composite graft, i.e., firm suturing of the tarsus, closing the defect under tension to avoid canthotomy may be a better approach.

Random Pattern Skin Flaps

Skin defects are often reconstructed with a local skin flap, since they better match the color and texture of the periorbital skin, have their own blood supply, and exhibit less contraction upon healing than free skin grafts.¹¹⁸ Successful design of the flaps depends on understanding the vascular supply and the process of revascularization. In a random pattern skin flap, the blood supply is derived from many small unspecified vessels (i.e., diffuse perfusion in the microvascular network, without blood supply from a larger blood vessel). Recent studies indicate that the dissection of a random advancement flap will result in hypoperfusion and that oxygenation depends on different

factors, such as the length and thickness of the flap,³⁹ whether it consists of skin only or skin and orbicularis muscle,¹¹⁹ whether it is stretched or rotated,⁶⁸ and whether its base is subjected to diathermy.¹²⁰ A more detailed description of how the perfusion is affected is given below.

Flap Length. Clinical rules of thumb often governed the design of flaps, and the viable length of a flap is thought to depend on the width of its pedicle. In 1920, Sir Harold Gillies suggested that a flap should not be longer than the width of its base.⁷⁸ This principle became foundational and continued to evolve throughout the 20th century. In 1970, Milton et al. used a porcine model to study the surviving area of rectangular, different sized flaps.¹²¹ The surviving area was found to have a constant ratio to the base of the flaps, and it was concluded that a constant area-to-base ratio was required, with the proviso that there is an upper limit on the surviving length that cannot be increased by increasing the width of the base.¹²² These are all anecdotal studies, and the development of perfusion monitoring techniques offers the opportunity to carry out detailed studies of how the length:width ratio influences the perfusion in advancement flaps.

Laser Doppler perfusion imaging and Clark electrode oxygenation measurements in a porcine model showed that it is not possible to predict the degree of perfusion and oxygenation of a random advancement skin flap by the length:width ratio but rather is correlated to the length of the flap.^{39,123} This has also been confirmed using LSCI in human skin flaps dissected in the upper eyelid during the blepharoplasty procedure, in which the medial end of the flap remained attached, to mimic a flap.^{68,120} It has been shown that perfusion is primarily maintained in the first 15 mm from the flap base in human cutaneous upper eyelid flaps but is very limited at greater distances.¹²⁰ In a similar study, the base was made 10 mm wide, and the blood perfusion was seen to decrease in a similar manner.⁶⁸ Clinically, the length of an eyelid skin flap should allow it to be moved from the donor to the recipient site, while still containing sufficient vascular elements to ensure viability of the tissue. Based on the results of the above studies, the distal part of a long flap appears to function as a free graft^{68,120} but with the advantage that it matches the color and texture of the recipient site. The early principle regarding the maximum area or length of a flap being dependent on the width of the base⁷⁸ might have had some important degree of truth, but technical advances, such as incorporating surgical delay, have allowed the use of extended flaps beyond the acute survival length.

Flap Thickness. Perfusion monitoring has provided clear evidence that the thickness of a random pattern flap is of great importance for its perfusion and oxygenation.³⁹ In a recent study by the authors, the perfusion was monitored using LSCI in patients undergoing blepharoplasty, in which the medial end of the flap remained attached, to mimic a frequently used flap. The results showed that blood perfusion was better preserved in myocutaneous flaps than in flaps that consisted only of cutaneous tissue.¹¹⁹ These results are consistent with those of a previous study on porcine flaps, using laser Doppler perfusion imaging and Clark electrode oxygenation monitoring, in which a thick flap, which was dissected all the way through the subcutaneous tissue down to the muscle fascia, had better perfusion and oxygenation than a thin flap, which was only dissected halfway through the subcutaneous tissue.³⁹ The better perfusion in myocutaneous flaps can probably be explained by the vascular anatomy of the upper eyelid. The deeper segmental artery of the area gives off branches that run perpendicularly toward the surface of the skin, penetrating muscle layers and adipose tissue. The cutaneous microcirculation is organized into a deeper

plexus at the junction between the dermis and the underlying subdermal fat and a plexus approximately superficial to the basement membrane. The more extensive vascular network in the dermal and subdermal vascular plexuses will allow higher perfusion of the myocutaneous flap. Making a thick flap, i.e., including the underlying orbicularis muscle, may be of particular importance in patients with poor microcirculation needing a long flap for reconstructive surgery.

Stretching and Rotating Flaps. Flaps are commonly stretched and rotated to cover a defect. In advancement flaps, adjacent tissue is stretched linearly. In rotation flaps, adjacent tissue is pivoted around an axis to close a defect, essentially rotating the skin into the defect. It is often necessary to both rotate and stretch skin flaps in order to cover defects. LSCI of upper eyelid flaps in humans showed that only rotation of the flap by 90° had no significant effect on perfusion,⁶⁸ which is in line with the results of previous studies on porcine and human eyelid flaps.^{68,124} Stretching the nonrotated flaps affected the perfusion slightly. However, the combination of stretching and rotating the flap reduced the blood perfusion markedly.⁶⁸ This is consistent with the results of other studies on porcine and human eyelid flaps.^{123,124} A compromise must thus be found between the length of the flap and the degree to which it is stretched, especially in cases of long flaps. This may be of particular importance when using synthetic grafts, or when combining, for instance, buccal mucosa, periosteal flaps, and skin-muscle flaps.

Effects of Diathermy. Cauterization of blood vessels is common to prevent excessive bleeding during surgical procedures in the periorbital region. Little could be found in the literature on the effects of diathermy on flap perfusion. In a study on upper eyelid skin flaps using LSCI, it was found that diathermy, especially repeated diathermy, of the base of the flap had detrimental effects on perfusion.¹²⁰ Similar results were found in a Hewes tarsoconjunctival flap in a porcine model.⁶⁹ The observations suggest that the use of diathermy should be carefully considered, especially in cases of long thin flaps that are poorly perfused. Repeated diathermy of the base of the flap most likely causes the flap to function more like a free skin graft than a flap.

H-plasty

The H-plasty procedure involves the use of bipedicle advancement flaps with a random blood supply. The procedure is commonly used to repair defects after tumor surgery in the head and neck region. LSCI during H-plasty procedures in the periorbital region showed impaired perfusion immediately after surgery. The lengths of the bipedicle flaps were 8 to 20 mm, and the median perfusion at the distal end of the flap was 54%. Reperfusion occurred rapidly, presumably due to the existing vascular network of the flap pedicle, and the flaps were fully reperfused after 1 week. The H-plasty healed well in all cases, and no tissue necrosis was seen.¹²⁵ Random flaps are known to be more viable in the face than elsewhere, viability decreasing with the distance from the face.¹²²

Glabellar Flaps

Repair of the medial canthal area after tumor excision can be challenging for the surgeon, and the glabellar flap is a common choice. This is a V-Y flap, based on a random blood supply, allowing the advancement of skin from the lax glabellar skin region into the medial canthal area.¹¹⁰ Perfusion monitoring of the glabella flap procedure has recently been performed, showing that during surgery, perfusion decreased

along the length of flap, with a further slight decrease upon rotation and suturing of the flap into place, reaching a minimum 15 mm from the flap base. Reperfusion was almost completely restored already after a week, which may be explained by its connection to the vascular network via the flap pedicle. This confirms the general opinion that the glabellar flap is a good reconstructive technique, especially in the periorbital region with its rich vascular supply.¹²⁶ However, there have been reports of both short- and long-term problems associated with glabellar flap reconstruction, including necrosis of the tip or edges of the flap in the early postoperative period.¹²⁷

Axial Flaps

Large upper eyelid defects can be repaired by rotational full-thickness lower eyelid flaps.¹¹⁰ LSCI was performed in a case in which removal of a basal cell carcinoma on the upper eyelid resulted in a defect measuring 26 mm horizontally and 10 mm vertically. The defect was repaired by advancing and rotating a full-thickness flap from the lower eyelid by 180°. Perfusion of the flap decreased by 50% during surgery but was almost completely restored 5 weeks later at flap division (91%).¹²⁸ In a study including 9 patients undergoing the Quickert procedure due to entropion, the tissue was dissected to mimic a full-thickness lower eyelid flap of approximate width 0.5 cm and length 2 cm.¹²⁴ The results indicated that these full-thickness eyelid flaps were better perfused than random pattern skin flaps on the eyelid^{68,120} and could be made 15 mm long with retained perfusion.¹²⁴ Similar results were obtained using laser Doppler velocimetry, LSCI, and thermography in full-thickness eyelid flaps in a porcine model.¹²⁹ The fact that full-thickness eyelid flaps are so well perfused is most probably due to the fact that this is an axial flap, or arterial flap, which is a myocutaneous flap containing a direct cutaneous artery along its longitudinal axis, in this case the anastomosis of the medial and lateral palpebral arteries. A random skin flap, however, does not have a specific vessel for vascularization and is perfused by musculocutaneous microcirculation in the tissue.¹³⁰

Free Skin Grafts

The tissue available for reconstructive surgery in the periocular area is often limited, and it may be difficult to ensure wound coverage. In cases where primary closure or closure using flaps is not possible, free full-thickness skin grafts are often considered. In oculoplastic surgery, a skin graft from the upper eyelid above the skin crease is often preferable, since it matches the color and texture and often heals well. If there is insufficient skin on the upper eyelid, or a local skin flap is not possible, free skin grafts from the inside of the arm, the pre- or postauricular area, or the supraclavicular fossa can be considered.¹¹⁰ Using a free full-thickness skin graft instead of a long flap is especially preferable when excising a tumor where the borders are difficult to define. If the primary excision is found not to be complete, it is easier to perform a secondary excision to remove the remaining tumor if the tissue is not distorted by a flap.

The authors monitored the reperfusion of free full-thickness skin grafts, taken from the upper eyelid or the upper inner arm, grafted to the periocular area, using LSCI. Reperfusion was found to be rapid and was completely restored within 7 weeks after surgery.¹³¹ Several factors are thought to influence the survival of grafts; the underlying graft bed being one of the most important. Grafts placed on well-vascularized tissue are believed to be more likely to survive than those on a less vascularized tissue.¹³² However, in a LSCI study on skin grafts overlying tarsoconjunctival flaps when using the modified Hughes

procedure 2019, we found that the grafts overlying the tarsus were reperfused within 3 to 8 weeks, despite overlying a tarsoconjunctival flap,⁷⁰ which has been reported to be avascular.⁸⁷ We attributed these observations to the rich vascularization of the periocular area and the fact that the grafts had been soaked in tear fluid, which is known to have similar nutrients to those in blood.⁸⁸

The process of revascularization of free skin grafts has been extensively studied in animal studies in several areas but not the periocular area.^{133–137} It is believed that anastomoses initially develop between graft and host vessels. A new system of blood vessels then extends into the graft from sprouting angiogenesis in the wound bed.^{138,139}

Preexisting graft vessels have been shown to act as nonviable conduits for the ingrowth of the endothelium of new vessels.¹⁴⁰ In 1956, Converse and Rapaport reported sluggish flow in the vessels in full-thickness skin grafts on the forearm in humans on the third day postoperatively, based on microscopic observations.¹³³ In 1960, Ohmori and Kurata used intravenous injections of radioisotopes in a rabbit model, showing blood flow and isotope uptake in the graft 4 days postoperatively.¹³⁴ Rapid reperfusion was also reported by Clemmesen and Ronhovde in 1968 who found dilated vessels connected to the original vessels of the graft in biopsies from humans 3 days after surgery.¹³⁵ In 2006, Capla et al. observed vascular ingrowth in the periphery of full-thickness grafts on day 3 in a mouse model upon histological examination.¹³⁶ In 2008, Lindenblatt et al. studied skin graft healing in a mouse model using repetitive intravitral microscopy and saw capillary buds and sprouts on day 2 and blood in the graft capillaries on day 3. The original skin microcirculation was almost completely restored on day 5.¹³⁷ This is in line with the studies of free skin grafts in the periocular area showing rapid revascularization.^{70,131}

Local Anesthesia With Epinephrine in the Periocular Area

Epinephrine (adrenaline) is used in conjunction with local anesthetics to minimize bleeding during surgical procedures. Epinephrine has been shown to reduce bleeding (by vasoconstriction), prolong the analgesic effect,¹⁴¹ and reduce the systemic effects of local anesthetic agents (lidocaine).^{142,143} Surgeons usually wait several minutes for epinephrine to act before commencing surgery in order to minimize bleeding. The optimal delay often advocated in textbooks is 7 to 10 minutes.¹⁴⁴ The optimal delay often advocated in textbooks is 7 to 10 minutes.¹⁴⁴ However, in 2013, McKee et al., used oxygen spectroscopy to monitor the relative hemoglobin concentration in the skin of the arms in healthy volunteers and observed the lowest cutaneous hemoglobin level 26 minutes after injection.¹⁴⁵ This was later confirmed in another study by the same authors, when measuring the blood loss from the skin in patients during carpal tunnel release surgery. In their later study, they observed a significant reduction in bleeding when skin incision was delayed by 30 minutes, compared to 7 minutes.¹⁴⁶ However, these findings differ markedly from clinical experience in oculoplastic surgery. The optimal concentration of epinephrine to achieve vasoconstriction is also the subject of debate. Since epinephrine may affect systemic hemodynamics, there is a risk of disturbances such as hypertension and arrhythmia, making it important to define the lowest concentration of epinephrine that produces local vasoconstriction.^{147,148}

In order to resolve these controversies, the effect of a local anesthetic with adrenaline on perfusion and oxygen saturation in the periocular region has been studied in detail. In a study on porcine eyelid flaps, using laser Doppler velocimetry, LSCI, and diffuse reflectance spectroscopy, maximum

hypoperfusion was achieved at a dose of 10 µg epinephrine/mL. Furthermore, the time from the injection of epinephrine to the stabilization of hypoperfusion was 75 seconds.¹⁴⁸ These findings were later confirmed in studies on human forearms.^{42,46} Bleeding was measured in patients undergoing upper eyelid blepharoplasty¹⁴⁹ and in a porcine model.¹⁵⁰ The time taken to reach maximal hemostatic effect was found to be 7 minutes. Waiting longer did not reduce bleeding further. In a recent LSCI study on a local anesthetic with epinephrine in patients undergoing blepharoplasty surgery, minimal perfusion was obtained already after approximately 2 minutes.¹⁵¹ Taken together, the findings above indicate that a concentration of 10 µg/mL epinephrine is adequate to ensure vasoconstriction before oculoplastic surgery and that incision need only be delayed for about 2 to 7 minutes.

FUTURE PERSPECTIVES

Modern imaging techniques such as LSCI allow the monitoring of blood perfusion during and after reconstructive surgery, e.g., reconstructive periocular surgery using free skin grafts combined with flaps. There are several surgical procedures in which blood perfusion has not been studied using modern imaging techniques, and it would be of interest to monitor the changes in perfusion and the reperfusion in more complex reconstructive procedures and when combining flaps and free grafts.

Studies of larger groups would allow subgroup analyses, allowing factors known to affect blood perfusion and compromise the oxygenation of tissue, such as smoking, diabetes, previous surgery, and radiation therapy, to be investigated. It would also be of interest to study other factors that may promote wound healing, such as vitamin D.

The periocular area is known for its rich vascular supply, and flap survival may be higher than in other less forgiving areas of the body with lower blood perfusion. The design of flaps and free full-thickness skin grafts may be more important for the outcome and survival of tissue in other areas on the body, where flap viability, graft failure, and dehiscence wounds constitute greater problems. Perfusion monitoring may be useful in such cases for the early identification of flap failure.

Further development of techniques not affected by motion artifacts, which currently limit the use of laser-based techniques, will hopefully be seen. Photoacoustic imaging is a promising laser-based technique with the potential to limit the effects of motion artifacts due to its innovative combination of laser excitation and ultrasound detection. Other optically based noninvasive techniques cannot match photoacoustic imaging regarding imaging depth, which can provide a spatial map of oxygenated and deoxygenated hemoglobin at depths down to 2 cm in the tissue. A problem associated with the use of photoacoustic imaging around the eye is that even very low photon doses can cause damage to the eye since, due to its coherence, laser light is more readily focused by the lens onto the retina. Methods employing incoherent light sources are, therefore, desirable, making hyperspectral imaging better suited to characterize the reflected light from a white light source to determine the molecular composition of tissue. Hyperspectral imaging could thus provide a functional map describing the oxygen saturation without the complications associated with laser-based methods, although this information is limited to the surface. Combining the detailed depth-resolved information provided by photoacoustic imaging with the surface-resolved information provided by hyperspectral imaging could prove to be an optimal solution for the comprehensive characterization of the molecular composition of tissue.

CONCLUSIONS

Modern imaging techniques allow detailed perfusion monitoring in flaps and in free skin grafts. This provides opportunities to improve current surgical procedures and thus the outcome and to better understand the healing process. Improved knowledge on perfusion and reperfusion will help surgeons in their choice of reconstructive technique and enable more tailored approaches for each patient.

ACKNOWLEDGMENTS

We would particularly like to thank Jenny Hult and Rafi Sheikh for the figures. We are also most grateful to Elin Bohman for carefully reading the manuscript and giving valuable clinical input.

References

- Codner MA, McCord CD, Mejia JD, et al. Upper and lower eyelid reconstruction. *Plast Reconstr Surg* 2010;126:231e–245e.
- Ghosh SK. Human cadaveric dissection: a historical account from ancient Greece to the modern era. *Anat Cell Biol* 2015;48:153–169.
- Pickard A, Karlen W, Ansermino JM. Capillary refill time: is it still a useful clinical sign? *Anesth Analg* 2011;113:120–123.
- Dagum AB, Dowd AJ. Simple monitoring technique for muscle flaps. *Microsurgery* 1995;16:728–729.
- Hynes W. A simple method of estimating blood flow with special reference to the circulation in pedicled skin flaps and tubes. *Br J Plast Surg* 1948;1:159–171.
- Conway H, Stark RB, Joslin D. Cutaneous histamine reaction as a test of circulatory efficiency of tubed pedicles and flaps. *Surg Gynecol Obstet* 1951;93:185–189.
- Dingwall JA, Lord JV. The fluorescein test in the management of tubed (pedicle) flaps. *Bull. Johns Hopkins Hosp.*, 1943(73): p. 129.
- Lange K, Boyd LJ. The use of fluorescein to determine the adequacy of the circulation. *M. Clin. North America*, 1942(26): p. 943.
- Lange K. *Vascular prerequisites for successful skin grafting*. SURGERY, 1944(85): p. 15.
- Lange K. The use of fluorescein dyes as tracers in biology and medicine. *J Electrochem Soc* 1949(95): p. 131C.
- Lange K, Boyd LJ. The technique of the fluorescein test to determine the adequacy of circulation in peripheral vascular diseases, the circulation time and capillary permeability. *Bull. New York Med. Coll, Flower and Fifth Ave. Hosp.*, 1943(6): p. 78.
- Myers, MB. Prediction of skin sloughs at the time of operation with the use of fluorescein dye. *Surgery* 1962;51:158–62.
- Issing WJ, Naumann C. Evaluation of pedicled skin flap viability by pH, temperature and fluorescein: an experimental study. *J Craniomaxillofac Surg* 1996;24:305–309.
- Owens SL. Indocyanine green angiography. *Br J Ophthalmol* 1996;80:263–266.
- Albertini JJ, Lyman GH, Cox C, et al. Lymphatic mapping and sentinel node biopsy in the patient with breast cancer. *JAMA* 1996;276:1818–1822.
- Botros M, Kesar V, Seoud T, et al. *Methylene Blue Dye for Visual Confirmation of Enterocutaneous Fistula: 2979*. Official journal of the American College of Gastroenterology | ACG, 2017. 112.
- Deshmukh AS, Bansal NK, Kropp KA. Use of methylene blue in suspected colovesical fistula. *J Urol* 1977;118:819–820.
- Kiong KL, Tan NC, Skanthakumar T, et al. Salivary fistula: blue dye testing as part of an algorithm for early diagnosis. *Laryngoscope Investig Otolaryngol* 2017;2:363–368.
- Wolff KD, Böckmann R, Nolte D, et al. [Limitations of blood supply to the skin flap in face lift surgery]. *Mund Kiefer Gesichtschir* 2005;9:1–5.
- Gumus M, Gumus H, Jones SE, et al. How long will I be blue? Prolonged skin staining following sentinel lymph node biopsy using intradermal patent blue dye. *Breast Care (Basel)* 2013;8:199–202.
- Haque RA, Wagner A, Whisken JA, et al. Anaphylaxis to patent blue V: a case series and proposed diagnostic protocol. *Allergy* 2010;65:396–400.
- Kumar S, Dhillon R, Shah S, et al. Patent blue dye allergy and the deep inferior epigastric perforator free flap: a unique interaction. *Clin Case Rep* 2018;6:581–584.
- Yusim Y, Livingstone D, Sidi A. Blue dyes, blue people: the systemic effects of blue dyes when administered via different routes. *J Clin Anesth* 2007;19:315–321.
- Raskin DJ, Erk Y, Spira M, et al. Tissue pH monitoring in microsurgery: a preliminary evaluation of continuous tissue pH monitoring as an indicator of perfusion disturbances in microvascular free flaps. *Ann Plast Surg* 1983;11:331–339.
- Gibbons RJ. Myocardial perfusion imaging. *Heart* 2000;83:355–360.
- Prvulovich E. Myocardial perfusion scintigraphy. *Clin Med (Lond)* 2006;6:263–266.
- Hjortdal VE, Hansen ES, Hauge E. Myocutaneous flap ischemia: flow dynamics following venous and arterial obstruction. *Plast Reconstr Surg* 1992;89:1083–1091.
- Hjortdal VE, Hansen ES, Henriksen TB, et al. The microcirculation of myocutaneous island flaps in pigs studied with radioactive blood volume tracers and microspheres of different sizes. *Plast Reconstr Surg* 1992;89:116–22; discussion 123–4.
- Tsuchida Y. Age-related changes in skin blood flow at four anatomic sites of the body in males studied by xenon-133. *Plast Reconstr Surg* 1990;85:556–561.
- Glogovac SV, Bitz DM, Whiteside LA. Hydrogen washout technique in monitoring vascular status after replantation surgery. *J Hand Surg Am* 1982;7:601–605.
- Baumann KY, Church MK, Clough GF, et al. Skin microdialysis: methods, applications and future opportunities—an EAACI position paper. *Clin Transl Allergy* 2019;9:24.
- Bøgehoj M, Emmeluth C, Overgaard S. Blood flow and microdialysis in the human femoral head. *Acta Orthop* 2007;78:56–62.
- Morgan ME, Singhal D, Anderson BD. Quantitative assessment of blood-brain barrier damage during microdialysis. *J Pharmacol Exp Ther* 1996;277:1167–1176.
- Ungerstedt U, Rostami E. Microdialysis in neurointensive care. *Curr Pharm Des* 2004;10:2145–2152.
- Hickner RC, Ekelund U, Mellander S, et al. Muscle blood flow in cats: comparison of microdialysis ethanol technique with direct measurement. *J Appl Physiol* (1985) 1995;79:638–647.
- Delgado JM, DeFeudis FV, Roth RH, et al. Dialyrod for long term intracerebral perfusion in awake monkeys. *Arch Int Pharmacodyn Ther* 1972;198:9–21.
- Khouri RK. Avoiding free flap failure. *Clin Plast Surg* 1992;19:773–781.
- Memarzadeh K, Gustafsson L, Blohmé J, et al. Evaluation of the microvascular blood flow, oxygenation, and survival of tarsoconjunctival flaps following the modified hughes procedure. *Ophthalmic Plast Reconstr Surg* 2016;32:468–472.
- Memarzadeh K, Sheikh R, Blohmé J, et al. Perfusion and oxygenation of random advancement skin flaps depend more on the length and thickness of the flap than on the width to length ratio. *Eplasty* 2016;16:e12.
- Khatri N, Zhang S, Kale SS. Current techniques for postoperative monitoring of microvascular free flaps. *J Wound Ostomy Continence Nurs* 2017;44:148–152.
- Bruins AA, Geboers DGJP, Bauer JR, et al. The vascular occlusion test using multispectral imaging: a validation study: the VASOIMAGE study. *J Clin Monit Comput* 2021;35:113–121.
- Bunke J, Sheikh R, Reistad N, et al. Extended-wavelength diffuse reflectance spectroscopy for a comprehensive view of blood perfusion and tissue response in human forearm skin. *Microvasc Res* 2019;124:1–5.
- Carp SA, Fang Q. *Diffuse Optical Imaging, in Pathobiology of Human Disease*, LM McManus and RN Mitchell, Editors. 2014, Academic Press: San Diego. pp. 3925–3942.
- Calina MA, Parasca SV, Miclosa S, et al. Blood oxygenation monitoring using hyperspectral imaging after flap surgery. *Spectroscopy Letters* 2017;50:150–155.
- Chiang N, Jain JK, Sleight J, et al. Evaluation of hyperspectral imaging technology in patients with peripheral vascular disease. *J Vasc Surg* 2017;66:1192–1201.

46. Sheikh R, Bunke J, Thorisdottir RL, et al. Hypoperfusion following the injection of epinephrine in human forearm skin can be measured by RGB analysis but not with laser speckle contrast imaging. *Microvasc Res* 2019;121:7–13.
47. Steinberg I, Huland DM, Vermesh O, et al. Photoacoustic clinical imaging. *Photoacoustics* 2019;14:77–98.
48. Xia J, Danielli A, Liu Y, et al. Calibration-free quantification of absolute oxygen saturation based on the dynamics of photoacoustic signals. *Opt Lett* 2013;38:2800–2803.
49. Liu C, Liang Y, Wang L. Single-shot photoacoustic microscopy of hemoglobin concentration, oxygen saturation, and blood flow in sub-microseconds. *Photoacoustics* 2020;17:100156.
50. Rich LJ, Seshadri M. Photoacoustic imaging of vascular hemodynamics: validation with blood oxygenation level-dependent MR imaging. *Radiology* 2015;275:110–118.
51. Sheikh R, Cinthio M, Dahlstrand U, et al. Clinical translation of a novel photoacoustic imaging system for examining the temporal artery. *IEEE Trans Ultrason Ferroelectr Freq Control* 2019;66:472–480.
52. Sheikh R, Hammar B, Naumovska M, et al. Photoacoustic imaging for non-invasive examination of the healthy temporal artery - systematic evaluation of visual function in healthy subjects. *Acta Ophthalmol* 2021;99:227–231.
53. Bunke J, Merdasa A, Sheikh R, et al. Photoacoustic imaging for monitoring of local changes in oxygen saturation following adrenaline injection in human forearm skin. *Biomedical Optics Express* 2021;12:4084–4096.
54. Merdasa A, Bunke J, Naumovska M, et al. Photoacoustic imaging of the spatial distribution of oxygen saturation in an ischemia-reperfusion model in humans. *Biomed Opt Express* 2021;12:2484–2495.
55. Tsuge I, Saito S, Yamamoto G, et al. Preoperative vascular mapping for anterolateral thigh flap surgeries: a clinical trial of photoacoustic tomography imaging. *Microsurgery* 2020;40:324–330.
56. Wu Z, Duan F, Zhang J, et al. *In vivo* dual-scale photoacoustic surveillance and assessment of burn healing. *Biomed Opt Express* 2019;10:3425–3433.
57. Dahlstrand U, Sheikh R, Berggren J, et al. Spectral signatures in the different layers of the human eyelid by photoacoustic imaging. *Lasers Surg Med* 2020;52:341–346.
58. Dahlstrand U, Sheikh R, Malmström M. Photoacoustic imaging for intraoperative micrographic control of the surgical margins of eyelid tumours. *Acta Ophthalmol* 2020;98:e264–e265.
59. Maiman TH. Stimulated optical radiation in ruby. *Nature* 1960;87:493–494.
60. Ware B. Optical techniques in biological research. In: Rousseau D, ed. *Optical Techniques in Biological Research*, 2002;32: 32–33.
61. Allen J, Howell K. Microvascular imaging: techniques and opportunities for clinical physiological measurements. *Physiol Meas* 2014;35:R91–R141.
62. Fredriksson I, Fors C, Johansson J. Laser Doppler Flowmetry—a Theoretical Framework; 2007. Accessed August 29, 2019. www.imt.liu.se/bit/ldf/ldfmain.html.
63. Draijer M, Hondebrink E, van Leeuwen T, et al. Twente optical perfusion camera: system overview and performance for video rate laser Doppler perfusion imaging. *Opt Express* 2009;17:3211–3225.
64. He D, Nguyen HC, Hayes-Gill BR, et al. Laser Doppler blood flow imaging using a CMOS imaging sensor with on-chip signal processing. *Sensors (Basel)* 2013;13:12632–12647.
65. Yamamoto Y, Ohura T, Nohira K, et al. Laserflowgraphy: a new visual blood flow meter utilizing a dynamic laser speckle effect. *Plast Reconstr Surg* 1993;91:884–894.
66. Cheng H, Yan Y, Duong TQ. Temporal statistical analysis of laser speckle images and its application to retinal blood-flow imaging. *Opt Express* 2008;16:10214–10219.
67. Heeman W, Steenbergen W, van Dam G, et al. Clinical applications of laser speckle contrast imaging: a review. *J Biomed Opt* 2019;24:1–11.
68. Ansson CD, Berggren JV, Tenland K, et al. Perfusion in upper eyelid flaps: effects of rotation and stretching measured with laser speckle contrast imaging in patients. *Ophthalmic Plast Reconstr Surg* 2020;36:481–484.
69. Ansson CD, Sheikh R, Dahlstrand U, et al. Blood perfusion in Haves tarsalconjunctival flaps in pigs measured by laser speckle contrast imaging. *JPRAS Open* 2018;18:98–103.
70. Berggren J, Tenland K, Ansson CD, et al. Revascularization of free skin grafts overlying modified Hughes tarsalconjunctival flaps monitored using laser-based techniques. *Ophthalmic Plast Reconstr Surg* 2019;35:378–382.
71. Mirdell R, Farnebo S, Sjöberg F, et al. Interobserver reliability of laser speckle contrast imaging in the assessment of burns. *Burns* 2019;45:1325–1335.
72. Mahé G, Humeau-Heurtier A, Durand S, et al. Assessment of skin microvascular function and dysfunction with laser speckle contrast imaging. *Circ Cardiovasc Imaging* 2012;5:155–163.
73. Mahé G, Rousseau P, Durand S, et al. Laser speckle contrast imaging accurately measures blood flow over moving skin surfaces. *Microvasc Res* 2011;81:183–188.
74. Mirdell R, Farnebo S, Sjöberg F, et al. Accuracy of laser speckle contrast imaging in the assessment of pediatric scald wounds. *Burns* 2018;44:90–98.
75. Mirdell R, Farnebo S, Sjöberg F, et al. Using blood flow pulsatility to improve the accuracy of laser speckle contrast imaging in the assessment of burns. *Burns* 2020;46:1398–1406.
76. Mirdell R, Iredahl F, Sjöberg F, et al. Microvascular blood flow in scalds in children and its relation to duration of wound healing: a study using laser speckle contrast imaging. *Burns* 2016;42:648–654.
77. Basak K, Dey G, Mahadevappa M, et al. Learning of speckle statistics for *in vivo* and noninvasive characterization of cutaneous wound regions using laser speckle contrast imaging. *Microvasc Res* 2016;107:6–16.
78. Gillies H. *Plastic Surgery of the Face*. Plastic Surgery of the Face. 1920. Hodder and Stoughton. p. 22.
79. Eriksson S, Nilsson J, Stureson C. Non-invasive imaging of microcirculation: a technology review. *Med Devices (Auckl)* 2014;7:445–452.
80. Mannor GE, Wardell K, Wolfley DE, et al. Laser Doppler perfusion imaging of eyelid skin. *Ophthalmic Plast Reconstr Surg* 1996;12:178–185.
81. Fei W, Xu S, Ma J, et al. Fundamental supply of skin blood flow in the Chinese Han population: measurements by a full-field laser perfusion imager. *Skin Res Technol* 2018;24:656–662.
82. Hughes WL. A new method for rebuilding a lower lid. Report of a case. *Arch Ophthalmol*, 1937;17:1008–1017.
83. Hughes WL. Reconstruction of the lids. *Am J Ophthalmol*, 1945;28:1203–1211.
84. Hughes WL. Total lower lid reconstruction: technical details. *Trans Am Ophthalmol Soc* 1976;74:321–329.
85. Collin J. A manual of systematic eyelid surgery. 3rd ed. 2006. Philadelphia, Pennsylvania: Elsevier Inc.
86. Rohrich RJ, Zbar RI. The evolution of the Hughes tarsalconjunctival flap for the lower eyelid reconstruction. *Plast Reconstr Surg* 1999;104:518–22; quiz 523; discussion 524–6.
87. Tenland K, Memarzadeh K, Berggren J, et al. Perfusion monitoring shows minimal blood flow from the flap pedicle to the tarsalconjunctival flap. *Ophthalmic Plast Reconstr Surg* 2019;35:346–349.
88. Jalbert I. Diet, nutraceuticals and the tear film. *Exp Eye Res* 2013;117:138–146.
89. Bartley GB, Messenger MM. The dehiscent Hughes flap: outcomes and implications. *Trans Am Ophthalmol Soc* 2002;100:61–5; discussion 65.
90. Hargiss JL. Bipedicle tarsalconjunctival flap. *Ophthalmic Plast Reconstr Surg* 1989;5:99–103.
91. Leibsohn JM, Dryden R, Ross J. Intentional buttonholing of the Hughes' flap. *Ophthalmic Plast Reconstr Surg* 1993;9:135–138.
92. McNab AA. Early division of the conjunctival pedicle in modified Hughes repair of the lower eyelid. *Ophthalmic Surg Lasers* 1996;27:422–424.
93. McNab AA, Martin P, Bengler R, et al. A prospective randomized study comparing division of the pedicle of modified hughes flaps at two or four weeks. *Ophthalmic Plast Reconstr Surg* 2001;17:317–319.
94. Doxanas MT. Orbicularis muscle mobilization in eyelid reconstruction. *Arch Ophthalmol* 1986;104:910–914.
95. Lowry JC, Bartley GB, Litchy WJ. Electromyographic studies of the reconstructed lower eyelid after a modified Hughes procedure. *Am J Ophthalmol* 1995;119:225–228.

96. Klein-Theyer A, Horwath-Winter J, Dieter FR, et al. Evaluation of ocular surface and tear film function following modified Hughes tarsoconjunctival flap procedure. *Acta Ophthalmol* 2014;92:286–290.
97. Tenland K, Berggren J, Engelsberg K, et al. Successful free bilamellar eyelid grafts for the repair of upper and lower eyelid defects in patients and laser speckle contrast imaging of revascularization. *Ophthalmic Plast Reconstr Surg* 2021;37:168–172.
98. Memarzadeh K, Engelsberg K, Sheikh R, et al. Large eyelid defect repair using a free full-thickness eyelid graft. *Plast Reconstr Surg Glob Open* 2017;5:e1413.
99. Berggren JV, Tenland K, Hult J, et al. Successful repair of a full upper eyelid defect following traumatic amputation by simply suturing it back in place. *JPRAS Open* 2019;19:73–76.
100. CALLAHAN A. The free composite lid graft. *AMA Arch Ophthalmol* 1951;45:539–545.
101. Youens WT, Westphal C, Barfield FT, Jr, et al. Full thickness lower lid transplant. *Arch Ophthalmol* 1967;77:226–229.
102. Fox SA. Autogenous free full-thickness eyelid grafts. *Am J Ophthalmol* 1969;67:941–945.
103. Smith B, Cherubini T. Oculoplastic Surgery. St. Louis, C.V. Mosby Co., 1970, pp. 30–32.
104. Adams C, Ratner D. Composite and free cartilage grafting. *Dermatol Clin* 2005;23:129–40, vii.
105. Klinger M, Maione L, Villani F, et al. Reconstruction of a full-thickness alar wound using an auricular conchal composite graft. *Can J Plast Surg* 2010;18:149–151.
106. Brown JB, Cannon BS. Composite free grafts of skin and cartilage from ear. *Surg Gynec Obst* 1946;82:253–255.
107. Putterman AM. Viable composite grafting in eyelid reconstruction. *Am J Ophthalmol* 1978;85:237.
108. Putterman AM. Combined viable composite graft and temporal semicircular skin flap procedure. *Am J Ophthalmol* 1984;98:349–354.
109. Werner MS, Olson JJ, Putterman AM. Composite grafting for eyelid reconstruction. *Am J Ophthalmol* 1993;116:11–16.
110. Collin JRO. A Manual of Systematic Eyelid Surgery. New York 1989; Churchill Livingstone (2nd edition):72–98.
111. Perry JD, Mehta MP, Lewis CD. Internal cantholysis for repair of moderate and large full-thickness eyelid defects. *Ophthalmology* 2013;120:410–414.
112. Berggren JV, Tenland K, Memarzadeh K, et al. The effect of canthotomy on blood perfusion during the repair of lower eyelid defects. *Ophthalmic Plast Reconstr Surg* 2020;36:135–138.
113. Erdogmus S, Govsa F. The arterial anatomy of the eyelid: importance for reconstructive and aesthetic surgery. *J Plast Reconstr Aesthet Surg* 2007;60:241–245.
114. Rubinstein TJ, Perry JD. Re: “the effect of canthotomy on blood perfusion during the repair of lower eyelid defects”. *Ophthalmic Plast Reconstr Surg* 2020;36:423.
115. Thaller VT, Madge SN, Chan W, et al. Direct eyelid defect closure: a prospective study of functional and aesthetic outcomes. *Eye (Lond)* 2019;33:1393–1401.
116. Thaller VT, Vahdani K. The magic suture in periocular reconstruction. *Eye (Lond)* 2021;35:2892–2894.
117. Vahdani K, Thaller VT. Re: “the effect of canthotomy on blood perfusion during the repair of lower eyelid defects”. *Ophthalmic Plast Reconstr Surg* 2020;36:422–423.
118. Shew M, Kriet JD, Humphrey CD. Flap basics II: advancement flaps. *Facial Plast Surg Clin North Am* 2017;25:323–335.
119. Berggren JV, Tenland K, Bunke J, et al. Blood perfusion of human upper eyelid skin flaps is better in myocutaneous than in cutaneous flaps. *Ophthalmic Plast Reconstr Surg* 2021.
120. Nguyen CD, Hult J, Sheikh R, et al. Blood perfusion in human eyelid skin flaps examined by laser speckle contrast imaging—importance of flap length and the use of diathermy. *Ophthalmic Plast Reconstr Surg* 2018;34:361–365.
121. Milton SH. Pedicled skin-flaps: the fallacy of the length: width ratio. *The British journal of surgery* 1970;57:502–508.
122. Stell PM. The viability of skin flaps. *Ann R Coll Surg Engl* 1977;59:236–241.
123. Nguyen CD, Sheikh R, Dahlstrand U, et al. Investigation of blood perfusion by laser speckle contrast imaging in stretched and rotated skin flaps in a porcine model. *J Plast Reconstr Aesthet Surg* 2018;71:611–613.
124. Tenland K, Berggren JV, Dybelius Ansson C, et al. Blood perfusion in rotational full-thickness lower eyelid flaps measured by laser speckle contrast imaging. *Ophthalmic Plast Reconstr Surg* 2020;36:148–151.
125. Berggren J, Castelo N, Tenland K, et al. Revascularization after H-plasty reconstructive surgery in the periorbital region monitored with laser speckle contrast imaging. *Ophthalmic Plast Reconstr Surg* 2021;37:269–273.
126. Berggren JV, Tenland K, Sheikh R, et al. Laser speckle contrast imaging of the blood perfusion in glabellar flaps used to repair medial cantal defects. *Ophthalmic Plast Reconstr Surg* 2021; p. In press.
127. Maloof AJ, Leatherbarrow B. The glabellar flap dissected. *Eye (Lond)* 2000;14 (Pt 4):597–605.
128. Berggren JV, Sheikh R, Hult J, et al. Laser speckle contrast imaging of a rotational full-thickness lower eyelid flap shows satisfactory blood perfusion. *Ophthalmic Plast Reconstr Surg* 2021;37:e139–e141.
129. Sheikh R, Memarzadeh K, Torbrand C, et al. Blood perfusion in a full-thickness eyelid flap, investigated by laser doppler velocimetry, laser speckle contrast imaging, and thermography. *Eplasty* 2018;18:e9.
130. McGregor IA, Morgan G. Axial and random pattern flaps. *Br J Plast Surg* 1973;26:202–213.
131. Berggren J, Castelo N, Tenland K, et al. Reperfusion of free full-thickness skin grafts in periocular reconstructive surgery monitored using laser speckle contrast imaging. *Ophthalmic Plast Reconstr Surg* 2021;37:324–328.
132. Flowers RS. Unexpected postoperative problems in skin grafting. *Surg Clin North Am* 1970;50:439–456.
133. Converse JM, Rapaport FT. The vascularization of skin autografts and homografts; an experimental study in man. *Ann Surg* 1956;143:306–315.
134. Ohmori S, Kurata K. Experimental studies on the blood supply to various types of skin grafts in rabbits using isotope P32. *Plast Reconstr Surg Transplant Bull* 1960;25:547–555.
135. Clemmesen T, Ronhovde DA. Restoration of the blood-supply to human skin autografts. *Scand J Plast Reconstr Surg* 1968;2:44–46.
136. Capla JM, Ceradini DJ, Tepper OM, et al. Skin graft vascularization involves precisely regulated regression and replacement of endothelial cells through both angiogenesis and vasculogenesis. *Plast Reconstr Surg* 2006;117:836–844.
137. Lindenblatt N, Calcagni M, Contaldo C, et al. A new model for studying the revascularization of skin grafts in vivo: the role of angiogenesis. *Plast Reconstr Surg* 2008;122:1669–1680.
138. Clemmesen T. (The early circulation in split-skin grafts. restoration of blood supply to split-skin autografts.). *Acta Chir Scand* 1964;127:1–8.
139. Clemmesen T. Experimental studies on the healing of free skin autografts. *Dan Med Bull* 1967;14:Suppl 2:1–Suppl 273.
140. Zarem HA, Zweifach BW, McGehee JM. Development of microcirculation in full thickness autogenous skin grafts in mice. *Am J Physiol* 1967;212:1081–1085.
141. Bunke J, Sheikh R, Hult J, et al. Buffered local anesthetics reduce injection pain and provide anesthesia for up to 5 hours. *J Plast Reconstr Aesthet Surg* 2018;71:1216–1230.
142. Fink BR, Aasheim GM, Levy BA. Neural pharmacokinetics of epinephrine. *Anesthesiology* 1978;48:263–266.
143. Larrabee WF, Jr, Lanier BJ, Mickle D. Effect of epinephrine on local cutaneous blood flow. *Head Neck Surg* 1987;9:287–289.
144. Collin R, Rose GA. Plastic and orbital surgery. London: BMJ Books; 2001. viii, 192 s.p.
145. McKee DE, Lalonde DH, Thoma A, et al. Optimal time delay between epinephrine injection and incision to minimize bleeding. *Plast Reconstr Surg* 2013;131:811–814.
146. McKee DE, Lalonde DH, Thoma A, et al. Achieving the optimal epinephrine effect in wide awake hand surgery using local anesthesia without a tourniquet. *Hand (NY)* 2015;10:613–615.

147. Frank SG, Lalonde DH. How acidic is the lidocaine we are injecting, and how much bicarbonate should we add? *Can J Plast Surg* 2012;20:71–73.
148. Sheikh R, Dahlstrand U, Memarzadeh K, et al. Optimal epinephrine concentration and time delay to minimize perfusion in eyelid surgery: measured by laser-based methods and a novel form of extended-wavelength diffuse reflectance spectroscopy. *Ophthalmic Plast Reconstr Surg* 2018;34:123–129.
149. Hult J, Sheikh R, Nguyen CD, et al. A waiting time of 7 min is sufficient to reduce bleeding in oculoplastic surgery following the administration of epinephrine together with local anaesthesia. *Acta Ophthalmol* 2018;96:499–502.
150. Sheikh R, Hult J, Bunke J, et al. Maximal haemostatic effect is attained in porcine skin within 7 min of the administration of a local anaesthetic together with epinephrine, refuting the need for a 30 min waiting time. *JPRAS Open* 2019;19:77–81.
151. Bunke J, Merdasa A, Stridh M, et al. The effect of epinephrine in local anesthetics in oculoplastic surgery – perfusion and oxygenation monitoring by laser speckle contrast imaging and hyperspectral imaging. *Ophthalmic Plast Reconstr Surg* 2021. In press.

