



Title	Tube-ovarian abscess in a patient with cri du chat syndrome: A case report
Author(s)	Fujimori, Mimori; Kyojuka, Hyo; Sugeno, Misa; Jin, Toki; Ito, Fumihito; Suzuki, Daisuke; Ishii, Tsutomu; Nomura, Yasuhisa
Citation	Fukushima Journal of Medical Science. 68(1): 57-61
Issue Date	2022
URL	http://ir.fmu.ac.jp/dspace/handle/123456789/1649
Rights	© 2022 The Fukushima Society of Medical Science. This article is licensed under a Creative Commons [Attribution-NonCommercial-ShareAlike 4.0 International] license.
DOI	10.5387/fms.2021-31
Text Version	publisher

This document is downloaded at: 2022-08-01T17:30:28Z

[Case report]



Tubo-ovarian abscess in a patient with cri du chat syndrome : A case report

Mimori Fujimori¹⁾, Hyo Kyojuka¹⁾, Misa Sugeno¹⁾, Toki Jin¹⁾, Fumihito Ito¹⁾, Daisuke Suzuki¹⁾,
Tsutomu Ishii²⁾ and Yasuhisa Nomura¹⁾

¹⁾Department of Obstetrics and Gynecology, Ohta Nishinouchi Hospital, 2-5-20 Nishinouchi, Koriyama City, Fukushima, Japan, ²⁾Department of Pediatrics, Fukushima National Hospital, 13 Ashidazuka, Sukagawa City, Fukushima, Japan

(Received November 9, 2021, accepted February 16, 2022)

Abstract

A tubo-ovarian abscess is an infection that occurs as a sequela of pelvic inflammatory disease. There is no reported association between a tubo-ovarian abscess and cri du chat syndrome in the medical literature. Herein, we report the case of a 44-year-old woman with cri du chat syndrome who was subsequently diagnosed with a tubo-ovarian abscess. After emergent laparotomy, simple total hysterectomy, and bilateral adnexectomy, the patient was discharged 13 days postoperatively without complications.

Key words : cri du chat syndrome, prognosis, tubo-ovarian abscess

Introduction

Cri du chat syndrome (CdCS) is a well-delineated clinical entity with a neonatal incidence of 1/50,000. The clinical picture is well known in younger patients, typified by a high-pitched cry, psychomotor retardation, microcephaly, growth rate failure, and craniofacial abnormalities such as a round face, hypertelorism, broad nasal bridge, downward slanting of the palpebral fissures, and micrognathia¹⁾. The survival rate of CdCS is high, and the morbidity is low after the first year of life²⁾. The mortality in a series studied by Niebuhr was approximately 10%, of whom 75% died during the first month of life and up to 90% died within the first year³⁾. Nevertheless, despite accumulated evidence on the clinical features and prognosis of CdCS, little is known regarding long-term complications of this rare genetic chromosomal disorder.

Tubo-ovarian abscess (TOA) occurs as a sequela of pelvic inflammatory disease (PID)⁴⁾. Since the infection involved in the pathogenesis of TOA is usually polymicrobial with mixed aerobic-anaerobic organisms, life-threatening sepsis can occur in the

event of abscess rupture⁵⁾. Most patients are women of reproductive age⁶⁾.

Herein, we present a case of TOA in an older patient with CdCS who underwent total abdominal hysterectomy and bilateral adnexectomy.

Case report

A 44-year-old Japanese woman was diagnosed with CdCS in infancy. She also had a history of epilepsy. Shortly after birth, she was diagnosed with CdCS based on chromosomal examination (Fig. 1). She was unable to communicate due to severe intellectual disability. Severe scoliosis was also observed; she could not walk and had been hospitalized since birth.

Menarche occurred at 22 years of age. At the time of presentation, the duration of the patient's menstrual cycle was 24-36 days. She sometimes groaned and agonized during menstruation, in a way suggestive of dysmenorrhea. She had complications such as a high-pitched bark, low-set ears, increased intercanthal distance, saddle nose, and scoliosis. However, she did not have heart disease or

Corresponding author : Mimori Fujimori E-mail : mimori9209@gmail.com

©2022 The Fukushima Society of Medical Science. This article is licensed under a Creative Commons [Attribution-NonCommercial-ShareAlike 4.0 International] license.
<https://creativecommons.org/licenses/by-nc-sa/4.0/>

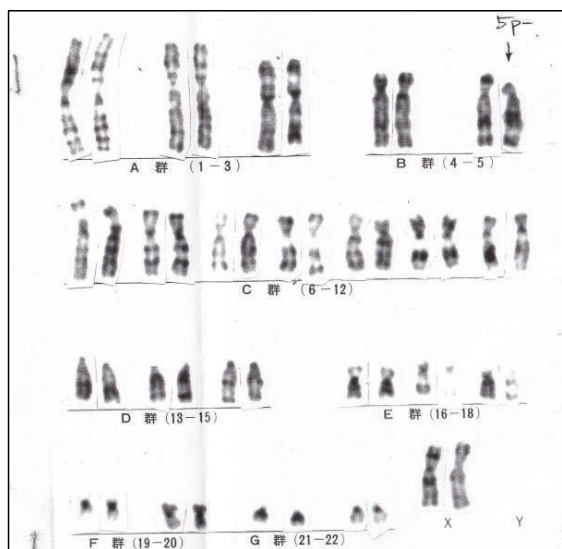


Fig. 1. Chromosome testing
The short arm of chromosome 5 is missing (arrow).

complications due to urinary and genital malformations.

The patient presented with fever (38.0°C) and pyuria. Laboratory results showed a white blood

cell count of $8.3 \times 10^3/\text{mm}^3$ and a C-reactive protein (CRP) level of 20.86 mg/dL. She was administered ceftazidime intravenously for the fever and pyuria. The fever persisted despite antibiotic administration, and while there was no muscle guarding, the patient had an expression of anguish. Blood investigations performed after 3 days showed little improvement in the inflammatory response. Therefore, an additional antibiotic was administered intravenously. Contrast-enhanced computed tomography revealed swelling of the adnexa with a contrast-enhanced effect, suggestive of an adnexal abscess. It was unclear whether the adnexal abscess originated from the left or the right side (Fig. 2).

The patient was transferred to our hospital for the treatment of fever and abscess. At the time of admission, the abdomen was greatly distended, but no obvious nodules were palpable. She had an expression of anguish and groaned during examination, probably due to pain, but communication was otherwise difficult. Laboratory tests revealed a white blood cell count of $7.5 \times 10^3/\text{mm}^3$ and a CRP of

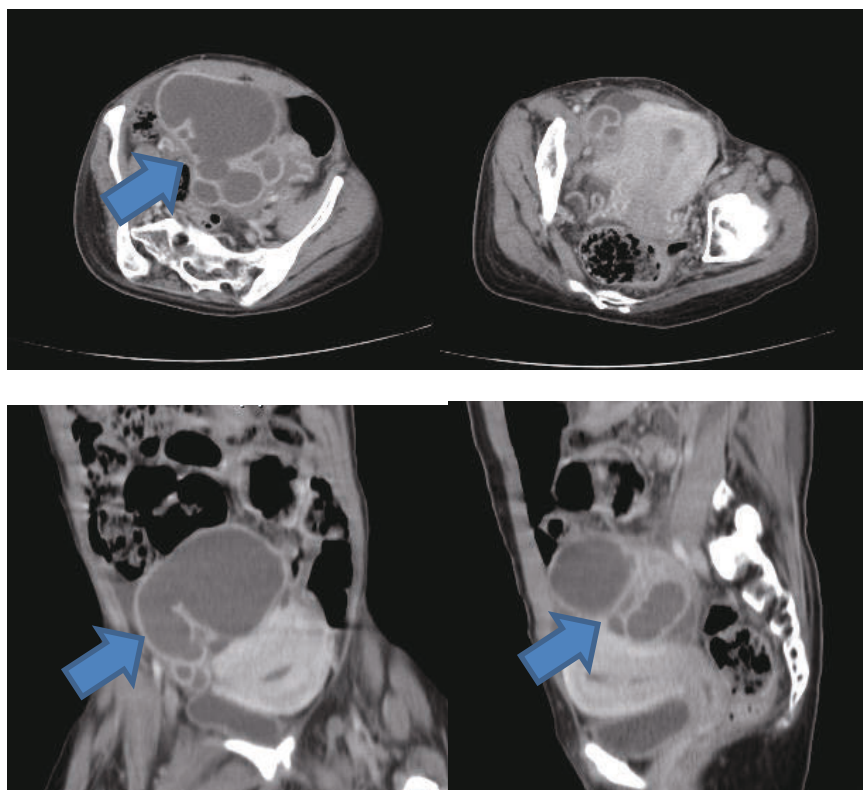


Fig. 2. Contrast-enhanced CT image of the patient with cri du chat syndrome and TOA
A thick-walled mass with fold-like boundaries and an enlarged fallopian tube are observed on the right side of the uterus; a multilocular cystic structure is also observed in the ovary. A TOA can be observed in the right adnexa (arrow).
CT, computed tomography; TOA, tubo-ovarian abscess

5.34 mg/dL that gradually improved. Therefore, antibiotic administration was continued. We planned a simple total hysterectomy and bilateral adnexectomy for curative treatment, eliminating the possibility of malignant disease, and preventing future gynecological problems while continuing curative therapy. These aspects were explained to the patient's legal representative, from whom written informed consent was obtained. Preoperative echocardiography did not reveal any malformations.

During laparotomy, the right fallopian tube was swollen due to the abscess. The uterus, ovaries, and fallopian tubes had moderate adhesions. "Blueberry spots" due to endometriosis were found to be scattered throughout the abdominal cavity. No organisms were detected in the blood or ascites cultures. Pathological examination revealed the presence of endometriosis, in addition to a right TOA (Fig. 3).

Pathological examination revealed an abscess in the right adnexa, with swelling 6.5 cm in greatest dimension. Uterine adenomyosis and some fibroids were confirmed in the uterus based on pathological examination. Although no abscess was found in the left adnexa, endometriosis was observed in both adnexa.

The postoperative course was uneventful; abdominal pain gradually decreased with an increase in oral intake. Antibiotic administration was discontinued on the 5th postoperative day. Blood tests performed on the 9th postoperative day showed improvement, with a white blood cell count of $4.2 \times 10^3/\text{mm}^3$ and a CRP of 0.73 mg/dL.

On the 13th postoperative day, the patient was transferred to the referring hospital, where she had initially presented, to complete treatment. We ad-

vised the patient's legal representative that estrogen replacement therapy could prevent ovarian deficiency symptom in future.

Discussion

TOA is a form of PID, which constitutes a spectrum of diseases that range from subclinical or mild illness to more severe manifestations, requiring management with antimicrobial therapy, while surgery is reserved for patients with suspected TOA rupture or those with a poor response to antibiotics⁷. TOAs are more common among women of reproductive age but can also exist in sexually inactive individuals, adolescents, post-menopausal women, and virgins^{4,8-10}.

Several risk factors for TOA have been identified, including young age, multiple sexual partners, sexually transmitted infections such as chlamydia and gonorrhea, uterine instrumentation, and in vitro fertilization¹¹. Although we could not identify the causative organism in the present case, the most commonly cultured bacteria from TOAs include *Escherichia coli*, *Bacteroides fragilis*, other *Bacteroides* species, *Peptostreptococcus*, *Peptococcus*, and aerobic streptococci¹¹. The underlying pathogenesis involves an ascending lower genital tract infection that leads to salpingitis¹¹. Therefore, TOA usually occurs because of sexual activity and sexually transmitted diseases and is uncommon in a sexually non-active woman⁴. Our patient had a "blueberry spot" noted on laparotomy, which was suggestive of endometriosis¹². Women with endometriosis are more likely to develop TOA than those without endometriosis¹³. Vichinsartvichai *et al.* proposed the following possible pathogenesis: endometriosis,

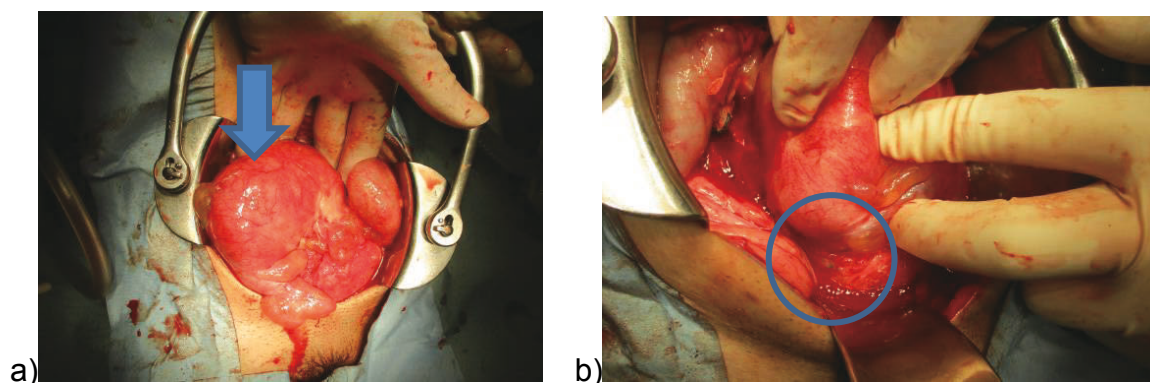


Fig. 3. Intraoperative images of the laparotomy procedure

a) Right TOA (arrow)

b) "Blueberry spot" due to endometriosis scattered in the abdominal cavity (blue circles)
TOA, tubo-ovarian abscess

which is itself an immunodeficiency disease, leads to impairment in the ability of the immune system to combat infections, facilitating the development of TOA¹⁴.

A study has reported that the prevalence of endometriosis increases in the presence of a uterine malformation, with a probability of approximately 40%¹⁵. However, no uterine malformation was found in this patient.

CdCS, also known as 5p minus syndrome or cat-cry syndrome, is a chromosomal disorder that was first described by Lejeune *et al.* in 1963¹⁶. In general, the complication rate of genital malformations in patients with CdCS is similar to that in normal individuals. In the present case, the patient was bedridden and required assistance in all daily activities. Laparotomy showed evidence of endometriosis, suggesting that TOA was caused by chronic abdominal inflammation and not due to sexual activity. Although studies have reported a 10% mortality rate for CdCS, 90% of deaths occur within the first year³. Formal evaluations of long-term complications are lacking; to the best of our knowledge, this is the first study reporting TOA as a long-term complication of CdCS. The salient findings of the present study are as follows. First, this appears to be the first report of TOA in a patient diagnosed with CdCS. Second, the presence of endometriosis could affect the occurrence of TOA. Third, TOA does not necessarily occur only in sexually active women. Healthcare providers should be mindful of gynecological complications in CdCS patients.

Conflict of interest disclosure

The authors have no conflicts of interest to declare.

Contributors

All authors were involved in the clinical care of the patient and contributed to the conception, drafting, review, and revision of the manuscript. All authors have read and approved the final version of the manuscript and take full responsibility for the work.

Funding

This work did not receive any specific grants from funding agencies.

Patient consent

Informed consent was obtained from the legal representative of the patient for publication of this work.

Provenance and peer review

This case report was peer reviewed.

References

1. Van Buggenhout GJ, Pijkels E, Holvoet M, Schaap C, Hamel BC, Fryns JP. Cri du chat syndrome : Changing phenotype in older patients. *Am J Med Genet*, **90** : 203-215, 2000. doi : 10.1002/(sici)1096-8628(20000131)90 : 3 < 203 : aid-ajmg5 > 3.0.co ; 2-a.
2. Mainardi PC. Cri du Chat syndrome. *Orphanet J Rare Dis*, **1** : 33, 2006. doi : 10.1186/1750-1172-1-33.
3. Niebuhr E. The Cri du Chat syndrome : epidemiology, cytogenetics, and clinical features. *Hum Genet*, **44** : 227-275, 1978. doi : 10.1007/BF00394291.
4. Leong S, Bowditch J. Tubo-ovarian abscess in a non-sexually active female. *Aust N Z J Obstet Gynaecol*, **41** : 228-229, 2001. doi : 10.1111/j.1479-828x.2001.tb01216.x.
5. Osborne NG. Tubo-ovarian abscess : pathogenesis and management. *J Natl Med Assoc*, **78** : 937-951, 1986.
6. Kairys N, Roepke C. Tubo-Ovarian Abscess. 2021 Jul 18. In : StatPearls [Internet]. Treasure Island (FL) : StatPearls Publishing ; 2021 Jan.
7. Lareau SM, Beigi RH. Pelvic inflammatory disease and tubo-ovarian abscess. *Infect Dis Clin North Am*, **44** : 693-708, 2008. doi : 10.1016/j.idc.2008.05.008.
8. Mollen CJ, Pletcher JR, Bellah RD, Lavelle JM. Prevalence of tubo-ovarian abscess in adolescents diagnosed with pelvic inflammatory disease in a pediatric emergency department. *Pediatr Emerg Care*, **22** : 621-625, 2006. doi : 10.1097/01.pec.0000227868.23568.9d.
9. Gockley AA, Manning-Geist BL, Boatman AA, Gu X, Cohen S. Tubo-ovarian abscesses in postmenopausal women : Clinical presentation and outcomes. *Maturitas*, **125** : 20-26, 2019.
10. Murata T, Endo Y, Furukawa S, *et al.* Successful laparoscopic resection of ovarian abscess caused by *Staphylococcus aureus* in a 13-year-old girl : a case report and review of literature. *BMC Women's Health*, **21** : 198, 2021.
11. Gao Y, Qu P, Zhou Y, Ding W. Risk factors for the

- development of tubo-ovarian abscesses in women with ovarian endometriosis : a retrospective matched case-control study. *BMC Women's Health*, **21** : 43, 2021.
12. Yukumi S, Suzuki H, Morimoto M, *et al.* A case of thoracic endometriosis-related pneumothorax in a menopausal woman. *Gen Thorac Cardiovasc Surg*, **68** : 1584-1586, 2020. doi : 10.1007/s11748-020-01381-8. Epub 2020 May 14.
 13. Grammatikakis I, Evangelinakis N, Salamalekis G, *et al.* Prevalence of severe pelvic inflammatory disease and endometriotic ovarian cysts : a 7-year retrospective study. *Clin Exp Obstet Gynecol*, **36** : 235-236, 2009.
 14. Vichinsartvichai P. Bilateral tubo-ovarian abscesses presenting with huge pelvic mass after repeated intrauterine inseminations in a woman with severe endometriosis. *J Obstet Gynaecol Res*, **44** : 792-796, 2018. doi : 10.1111/jog.13570. Epub 2018 Jan 5.
 15. Dovey S, Sanfilippo J. Endometriosis and the adolescent. *Clin Obstet Gynecol*, **53** : 420-428, 2010.
 16. Lejeune J, Lafourcade J, Berger R, *et al.* 3 cases of partial deletion of the short arm of a 5 chromosome. *C R Hebd Seances Acad Sci*, **257** : 3098-3102, 1963.