

Smile Design

Mechanical Considerations



Marzieh Alikhasi, DDS, MS^{a,*}, Parisa Yousefi, DDS, MS^b,
Kelvin I. Afrashtehfar, DDS, MSc, Dr med dent, FDS RCSEng, FRCD(C)^{c,d,*}

KEYWORDS

- Artificial intelligence • Augmented reality • Dentures • Digital technology • Esthetics
- Patient satisfaction • Prosthodontics

KEY POINTS

- Adherence to the primary reconstruction principles permits achieving durable esthetic outcomes.
- Dental clinicians should provide a realistic image of the expected esthetic outcomes to their patients.
- The use of digital treatment planning tools does not undermine the significance of the prosthodontic concepts that were born during the fully conventional era.

INTRODUCTION

A smile is a facial expression of emotions through the contraction of facial expression muscles to display the maxillary teeth, which can commonly influence how an individual fits and functions in society.¹ The lips act as the smile framework exposing teeth referred to as the esthetic zone.^{2,3} Smile designing refers to the cosmetic and esthetic teeth reconstruction that is primarily displayed during smiling. Esthetic dentistry is not a separate discipline or field of dentistry⁴; instead, it is the ultimate goal of most therapeutic interventions and procedures performed in different dental specialties.^{5,6} In the recent years, dental interventions seem to be more frequently becoming appearance-driven, and thus, both patients and dental clinicians mainly emphasize on esthetic dental and facial aspects of treatments. Consequently, reconstructive

^a Dental Implant Research Center, Dentistry Research Institute, Tehran University of Medical Sciences, Tehran 1439955991, Iran; ^b Department of Prosthodontics, School of Dentistry, Isfahan University of Medical Sciences, Hezar Jarib Street, Isfahan 8174673461, Isfahan Province, Iran; ^c Evidence-Based Practice Unit, Disciplines of Prosthodontology and Implantology, Division of Restorative Dental Sciences, Clinical Sciences Department, Ajman University College of Dentistry, PO Box 346 Ajman City, Ajman Emirate, UAE; ^d Department of Reconstructive Dentistry & Gerodontology, School of Dental Medicine (ZMK), Faculty of Medicine, University of Bern, Freiburgstrasse 7, Bern 3010, BE, Switzerland

* Corresponding authors.

E-mail addresses: malikhasi@razi.tums.ac.ir (M.A.); kelvin.afraشتهfar@zmk.unibe.ch (K.I.A.)

dentistry pursues objectives beyond the reconstruction of severely carious or damaged teeth.

Misconceptions About Reconstructive Dental Procedures to Enhance the Appearance

Increasing people's awareness regarding the importance and impact of healthy teeth and beautiful smile on various aspects of life such as social acceptance and self-confidence,^{7,8} and frequent exposure to patterns advertised as a measure of beauty in social networks has increased the demand for a smile makeover procedures.^{9,10} When patient awareness is minimal or distorted, their altered perceptions could persuade them to demand results that do not mimic nature. For instance, patients' perception of an ideal smile could correspond to having super white and oversized teeth.¹¹ However, patients should also be well aware of such treatments' consequences, risks, and limitations of such treatments. For example, ceramic veneers that reportedly require no tooth preparation have received significant publicity and continue to be available by various trade names. As a result, many patients that seek a smile enhancement procedure believe that optimal smile esthetics can be achieved only by "prepless" veneers. Although tooth structure preservation is a priority, some cases require a less conservative approach as 0.3 mm thick ceramic veneer can reduce one tone (eg, A3 to A2). Masking of an achromatic abutment requires more aggressive preparations to modify several shade tones.¹² Besides, it is well established that ceramic veneers bonded to enamel have high survival and retrievability of sound enamel even with no-prep veneers is not possible.^{13,14} It is fundamental to realize that each case is different, and one solution does not fit all. This appeals to the personalized medicine concept.

Dental clinicians and technicians achieve ideal esthetic results in prosthodontics when performing a correct individualized diagnosis, planning, and execution considering the tooth position, tooth preparation design, contour and color of restoration and stump, and material selection. Also, preprosthetic corrective orthodontics may be an adjunct to upright a mesially tilted molar or improve the teeth' position within the arch or occlusion to offer less aggressive prosthetic preparations and favor the longevity and prognosis of the overall prognosis treatment.¹⁵⁻¹⁷ In other cases, preprosthetic surgical alterations such as recontouring of gingival margin may be required to achieve favorable esthetic results.¹⁸

Prosthodontic Digital Diagnostic Aids

Digital technology can be used to visually predict the esthetic treatment outcome and present it to patients, increasing the patient treatment acceptance rate. Many of these software programs are based on the concept of digital smile design (DSD) approach introduced by Ackermann¹⁹ and Coachman.²⁰ Objective transfer of such computer-aided designs (CADs) from the software applications such as Adobe Photoshop, PowerPoint, and Keynote to the oral environment is not always feasible. Some newer generations of such programs enable three-dimensional (3D) and even four-dimensional designs (simulating movements) to overcome many of the abovementioned limitations.^{21,22} However, it should be noted that this virtual smile proposal could sometimes be unrealistic and unachievable due to the skeletal relations, occlusion, and dental arch form are overlooked. Nonetheless, the use of novel advanced digital tools does not undermine the significance of adherence to the main prosthodontic principles. The creation of a pleasing smile requires simultaneous consideration of psychological, biological, and mechanical factors. Introduction of esthetic wheel and defining esthetic dimensions are attempts to find the influential factors involved

in the creating of an attractive smile.^{23,24} The mechanical features that are integrated into prosthodontic treatment are further discussed.

MECHANICAL FACTORS

Mechanical factors may be considered as the cornerstone of reconstructive dentistry. **Fig. 1** denotes the 4 aspects of a tooth that should be considered when restoring a natural maxillary tooth, dental implant, or even using a denture tooth in the esthetic zone. Generally, patients and some dental clinicians only focus on the labial/buccal and incisal aspects to achieve dental esthetics and neglect the cervical (emergence profile) and lingual aspects. The 4 aspects should be correctly addressed in reconstructions to achieve optimal long-term esthetic and functional outcomes respecting biological factors.

Incisal Edge

Patients' expectations from dental reconstructions in the esthetic zone often depend on the incisal edge's location and form. Patients usually demand longer incisors than their existing teeth. Different optimal mean and range values of incisal edge show at rest have been proposed according to the age and sex of the patient. Most often, 2 to 4 mm of incisal edge show is preferred at rest. The entire cervico-incisal length of the anterior maxillary teeth should be preferably visible when smiling. The width/height ratio and the height/face ratio are among the indices used to calculate the ideal amount of tooth show. It appears that the final value should better be determined based on the individual preferences and conditions of each patient.^{8,25,26} First, the

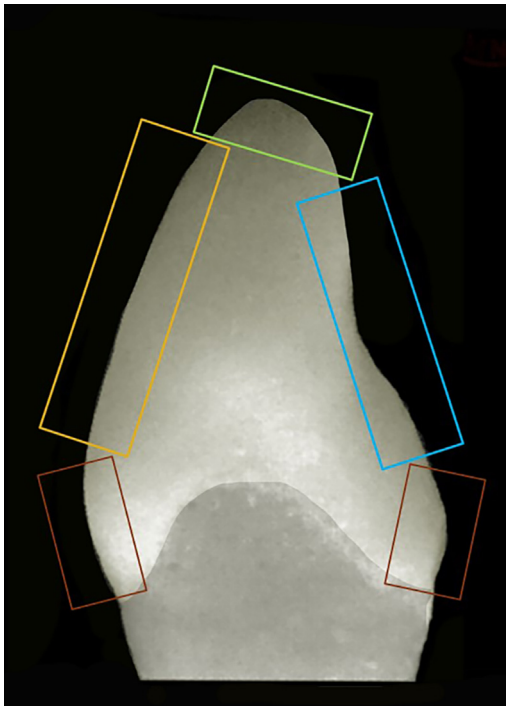


Fig. 1. Incisal (green), occlusal (blue), labial (yellow), and cervical (red) parts of a tooth or implant should be considered for reconstruction.

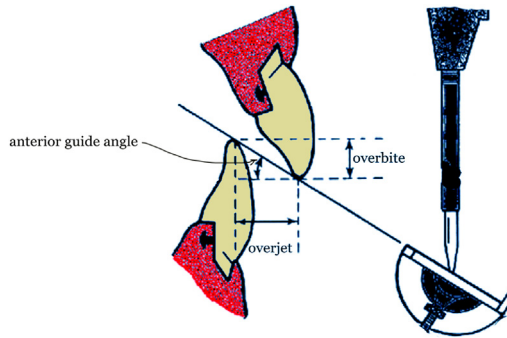


Fig. 2. Increasing the crown height often increases the overbite and anterior guidance.

amount of incisal edge display of the 2 central incisors is determined, and then the presumed value is tried in. We can use these methods for the primary assessment of the presumed values:

- Clinically designed mock-up: The clinician generates a mock-up in the patient's mouth with incremental composite resin without acid-etching or adhesive
- Conventional laboratory designed mock-up: A diagnostic wax-up is transferred to the patient's mouth via a silicone index
- Use of two-dimensional designing software programs
- Use of exclusive 3D DSD software programs

When DSD software programs are used, the required photographs are obtained, the incisal edge location and the amount of incisal display are determined as the starting point. In the conventional workflow, a diagnostic wax-up should be first done. For diagnostic waxing, technicians often calculate the correct length/width ratio of central incisors (70%–85%) as the starting point.²⁷ Thus, in most cases, the crown height obtained by digital mock-up design is often different from that obtained by diagnostic wax-up on a cast.²⁸ Photographs or videos can be obtained to guide technicians for conventional laboratory waxing. Restorative dentists should assess whether increasing the crown height is feasible within the prosthodontic parameters below mentioned:

- Crown/root ratio
- Anterior guidance
- Posterior disclusion
- Phonetics
- Envelope of motion

A patient that undergoes a crown lengthening that includes osteotomy for leveling of the gingival margin and zenith loses part of the bone support. Increasing the crown height for esthetic purposes can further aggravate the situation because the increased crown/root ratio can affect the longevity and survival of the respective tooth. Moreover, increasing the crown height alters the overbite and anterior guidance (**Fig. 2**). Although achieving a mutually protected occlusion is optional, the magnitude of posterior teeth disclusion due to the mandibular excursions should be within normal limits (range: 1–4 mm).²⁹ Higher values promote lateral forces with unfavorable direction and detrimental magnitude on anterior teeth.³⁰ Furthermore, if not accompanied by increased overjet (infrequently feasible), increased overbite can limit the envelope of function (**Fig. 3**), and lead to patient discomfort and dissatisfaction.³¹

In addition to the incisal edge position, the incisal plane is a critical factor. In the conventional workflow, a face-bow transfers the current incisal slope relative to the horizontal plane to the articulator. Reference horizontal plane is parallel to the pupils or, in case of facial asymmetry, parallel to the correct horizontal plane of the patient's face to the laboratory. In the digital workflow, this transfer is performed by drawing the respective lines on the face and teeth.³² To determine the incisal plane, the lower lip curvature (smile line) can be used in software programs. In the conventional workflow, this line can be somewhat drawn on the cast. A consonant smile can be achieved when an imaginary line running from the incisal edges of the maxillary incisors follows the smile line curvature correctly.

Labial Surface

The labial surface is the second determining factor that affects dental esthetics. Mesiodistal width is one of the parameters that should be considered to form the labial surface correctly. The golden ratio has long been used to achieve optimal symmetry, dominance, and dental proportions in the anterior maxillary teeth.³³ Different criteria have been proposed to determine the mesiodistal dimensions of teeth, such as the recurring esthetic dental proportion, golden proportion, facial analysis, and repeated ratio.³⁴⁻³⁶ In the digital workflow, proportion tools are used to determine these proportions. However, these ideal proportions cannot be achieved in all cases. Factors that interfere with achieving ideal tooth width proportions include:

- Interdental spaces
- Crowding
- Microdontia

The labial surface convexity also affects the visible width of teeth. The buccal corridor must be minimal in an ideal smile but should not be eliminated (**Fig. 4A** and

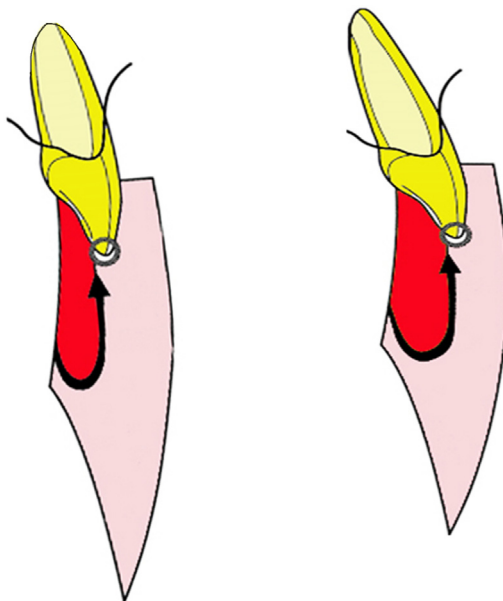


Fig. 3. Changing tooth length without increased overjet limits the envelope of function.

B).^{37–39} When a tooth dimension is determined, the outline should be defined, which refers to designing the tooth shape based on the patient's personality, facial form, and preferences.^{8,26} The technician manually generates a conventional wax-up by taking all factors into account, whereas in the digital workflow, this process is supported by CAD software programs. The dental outline is determined using software programs teeth libraries. Designing software programs facilitate this process such that even novice dental clinicians may have difficulties molding the tooth shape directly with composite resins or indirectly on wax to achieve a correct tooth form and shape. However, an experienced operator who digitally designs by CAD can create an acceptable smile in a shorter time.⁴⁰

Occlusal Surface

A comfortable and stable occlusion is the key to a long-term successful prosthetic treatment. Centric occlusion, centric relation, vertical dimension of occlusion, and eccentric movements are among the primary parameters to consider when restoring occlusal parts. Occlusion is less commonly affected in cases whereby only the labial surface is veneered without an incisal overlap design (ie, window preparation). In such cases, the only occlusal modification is related to the incisal edge height. Nonetheless, many patients that seek esthetic dental reconstructions require alterations of the occlusal surface due to the following specific conditions:

- Tooth wear (attrition, erosion)
- Requiring an increase in vertical height
- Jaw mal-relationship
- Dental caries
- Structural damage (fractures, craze lines)

Occlusal aspects may be neglected in esthetic treatments, leading to unpredictable and unstable treatment outcomes. Despite the primary concepts regarding the inability to increase the vertical occlusal height, stable results may be achieved if it is performed correctly.¹⁴ Correct occlusal management and equilibration require ample knowledge and adequate expertise in the field. Some noteworthy key points in this respect include:

- The envelope of function should not be limited as the patient feels that teeth are trapped or locked in a limited area (see [Fig. 3](#)).⁴¹

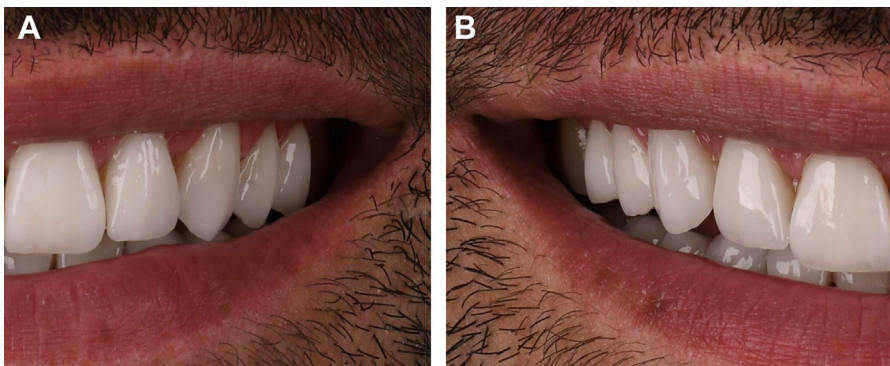


Fig. 4. (A) Acceptable uniform buccal corridor. (B) The corridor is not uniform and is prominent in the molar area.

- A mutually protected occlusion should be achieved.
- Reconstruction should be performed with normal disclusion of posterior teeth in eccentric movements.
- The concavity of the cingulum area should be correctly designed to allow freedom in centric and correct guidance⁴² (Fig. 5A and B).

The interim restoration is a blueprint of the future definitive reconstruction while being easily modified while assessing all these parameters. CAD files do not substitute interim restorations because the prototype shall be tested intraorally even if the patient accepts the 2D design. CAD/computer-aided manufacturing technology (CAM) has been used to fabricate interim restorations, and temporary materials used for milling or printing are more homogenous than direct temporary composites or acrylic materials.⁴³

Cervical Region

The cervical region of the teeth is both esthetically and biologically important due to the proximity to the gingival margin. As mentioned earlier, the entire crown height and even part of the gingiva may be visible in a beautiful smile. The cervical tooth contour and periodontal health play a pivotal role in the treatment outcome. Dental restorations, once considered as "cosmetic solutions," should be removed when causing significant inflammation to the adjacent gingiva. Thus, concepts such as emergence profile and axial contours, as well as supracrestal attachment (formerly known as biologic width), should emulate nature and avoid overcontoured restorations or invading soft tissues. The cervical region analysis includes the assessment of gingival morphology, interdental papilla condition, gingival zenith position, gingival line, and gingival contour.

PSYCHOLOGICAL FACTORS

People try to cover their mouth or hide their teeth when they are dissatisfied with their smile appearance. This could be seen when a subject presents misalignment, discoloration, staining, or missing teeth. Investigations have revealed that having an attractive smile is directly linked to higher self-confidence and satisfaction.^{1,3,44} A clinician is required to evaluate the patient's chief complaints by thoroughly analyzing the patient's mental state before designing a treatment plan.⁴⁵ The potential of artificial intelligence (AI) and virtual reality/augmented reality (VR/AR) technologies are solutions that rapidly evolved and can help patients and clinicians visualize treatment outcomes

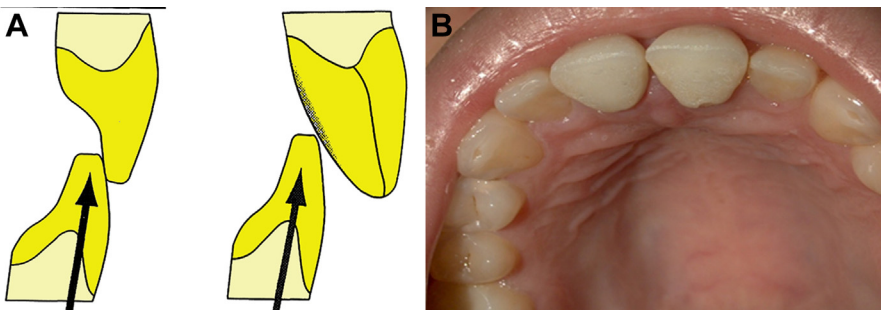


Fig. 5. (A) The anatomic contour does not follow a concave outline and lacks a stable contact. (B) Convex cingulum area increases traumatic forces on the tooth.

before any clinical intervention.^{46–51} The goal is to have the clinician's treatment plan and the patient's demands as close to each other as possible. In many cases, the reason for patients' dissatisfaction with their smile appearance does not depend on technical issues. These are situations in which patients need serious psychological counseling to become aware of the true nature of their problem.^{52,53}

BIOLOGICAL FACTORS

The condition of several intraoral and extraoral elements such as the periodontium complex, perioral muscles, skeletal components of the jaws, and how the expression of a smile communicates with adjacent components, including the nose and chin, all have undeniable effects on the beauty of a smile. Therefore, all specialists involved in the treatment should confirm the smile design. In most cases, the ideal status of the factors mentioned is a serious precondition for achieving an ideal outcome in smile design.

SUMMARY

As long as the demand for enhancing teeth appearance increases, restorative materials and technologies will continue developing to meet society's needs. The main advances have occurred in bleaching techniques, dental restorative materials, smile designing programs, prosthetic techniques, and bonding agents. The incorporation of digital 3D designing into AI and machine learning has also contributed to this process. The use of modern digital tools requires adequate knowledge about the tooth form and shape principles that have been sufficiently revised and documented. The mechanical, biological, and psychological factors should not be overlooked to achieve favorable esthetics. The durability of an esthetic restoration depends on adherence to the established principles of reconstruction.

CONFLICT OF INTEREST AND SOURCE OF FUNDING

The authors do not have any financial interests, either directly or indirectly, in the products or information enclosed in the article.

CLINICS CARE POINTS

- The creation of a pleasing smile requires simultaneous consideration of psychological, biological, and mechanical factors.
- If not accompanied by increased overjet, increased overbite can limit the envelope of function, and lead to patient discomfort and dissatisfaction.
- Reconstruction should be performed with normal disclusion of posterior teeth in eccentric movements.
- Concepts such as emergence profile and axial contours, as well as supracrestal attachment should emulate nature and avoid overcontoured restorations or invading soft tissues.

REFERENCES

1. Beall AE. Can a new smile make you look more intelligent and successful? *Dent Clin North Am* 2007;51(2):289–97.

2. Salama H, Salama M, Garber D, et al. Developing optimal peri-implant papillae within the esthetic zone: guided soft tissue augmentation. *J Esthet Restor Dent* 1995;7(3):125–9.
3. Afrashtehfar KI, Assery MK, Bryant SR. Aesthetic parameters and patient-perspective assessment tools for maxillary anterior single implants. *Int J Dent* 2021;2021.
4. Heymann HO, Paravina RD, Blatz MB. Advances in esthetic dentistry 2021. *J Esthet Restor Dent* 2021;33(1):5–6.
5. Touyz LZ, Raviv E, Harel-Raviv M. Cosmetic or esthetic dentistry? *Quintessence Int* 1999;30(4).
6. Goldstein RE. Study of need for esthetics in dentistry. *J Prosthet Dent* 1969;21(6):589–98.
7. Van der Geld P, Oosterveld P, Van Heck G, et al. Smile attractiveness: self-perception and influence on personality. *Angle Orthod* 2007;77(5):759–65.
8. Del Monte S, Afrashtehfar KI, Emami E, et al. Lay preferences for dentogingival esthetic parameters: a systematic review. *J Prosthet Dent* 2017;118(6):717–24.
9. Wooi M. Smile makeover generation? *Br Dent J* 2021;230(7):387.
10. Dorfman WM. A real-life hollywood success story: how extreme makeovers can make you a star. *J Indiana Dent Assoc* 2006;85(1):8–12.
11. Magne P, Salem P, Magne M. Influence of symmetry and balance on visual perception of a white female smile. *J Prosthet Dent* 2018;120(4):573–82.
12. Coachman C, Gurel G, Calamita M, et al. The influence of tooth color on preparation design for laminate veneers from a minimally invasive perspective: case report. *Int J Periodontics Restorative Dent* 2014;34(4).
13. Gurel G, Sesma N, Calamita MA, et al. Influence of enamel preservation on failure rates of porcelain laminate veneers. *Int J Periodontics Restorative Dent* 2013;33(1).
14. Layton DM, Clarke M. A systematic review and meta-analysis of the survival of non-feldspathic porcelain veneers over 5 and 10 years. *Int J Prosthodont* 2013;26(2).
15. Bidra AS, Uribe F. Preprosthetic orthodontic intervention for management of a partially edentulous patient with generalized wear and malocclusion. *J Esthet Restor Dent* 2012;24(2):88–100.
16. Wiskott A, Schatz J, Belser U. Preprosthetic orthodontics. 1. theoretical bases. *Schweiz Monatsschr Zahnmed* 1988;98(4):372–82.
17. Alfallaj H. Pre-prosthetic orthodontics. *Saudi Dent J* 2020;32(1):7–14.
18. Nemcovsky C, Artzi Z, Moses O. Preprosthetic clinical crown lengthening procedures in the anterior maxilla. *Practical procedures & aesthetic dentistry. Pract Proced Aesthet Dent* 2001;13(7):581–8, quiz 9.
19. Ackerman MB, Ackerman JL. Smile analysis and design in the digital era. *J Clin Orthod* 2002;36(4):221–36.
20. Coachman C, Paravina RD. Digitally enhanced esthetic dentistry-From treatment planning to quality control. *J Esthet Restor Dent*, 28 (Suppl 1), 2016, S3-4.
21. Marchand L, Touati R, Fehmer V, et al. Latest advances in augmented reality technology and its integration into the digital workflow. *Int J Comput Dent* 2020;23(4):397–408.
22. Kurbad A. The use of 'extended reality'(augmented reality) in esthetic treatment planning Der Einsatz der "erweiterten Realität "(Augmented Reality) in der ästhetischen Planung. *Int J Comput Dent* 2020;23(2):149–60.
23. Gürel G. The fifth dimension in esthetic dentistry. Bulgaria: University of Sofia; 2021.

24. Koirala S. Smile design wheel™: a practical approach to smile design. *Cosmet dentistry* 2009;3(3):24–8.
25. Witt M, Flores-Mir C. Laypeople's preferences regarding frontal dentofacial esthetics: periodontal factors. *J Am Dent Assoc* 2011;142(8):925–37.
26. Parrini S, Rossini G, Castorflorio T, et al. Laypeople's perceptions of frontal smile esthetics: A systematic review. *Am J Orthod Dentofacial Orthop* 2016;150(5): 740–50.
27. Blatz M, Chiche G, Bahat O, et al. Evolution of aesthetic dentistry. *J Dent Res* 2019;98(12):1294–304.
28. Cattoni F, Teté G, Calloni AM, et al. Milled versus moulded mock-ups based on the superimposition of 3D meshes from digital oral impressions: a comparative in vitro study in the aesthetic area. *BMC Oral Health* 2019;19(1):1–8.
29. Narang P, Shetty S, Prasad K. An in vivo study to determine the range of posterior teeth disclusion on working side in canine-guided occlusion. *Indian J Dent Res* 2012;23(6):814.
30. Kerstein RB. Reducing chronic masseter and temporalis muscular hyperactivity with computer-guided occlusal adjustments. *Compend Contin Educ Dent* 2010; 31(7):530–4.
31. Dawson PE. *Envelope of function, Functional occlusion-e-book: from TMJ to smile design*. Canada: Isevier Health Sciences; 2006. p. 141–8.
32. Lepidi L, Galli M, Mastrangelo F, et al. Virtual articulators and virtual mounting procedures: where do we stand? *J Prosthodont* 2021;30(1):24–35.
33. Londono J, Ghasemi S, Lawand G, et al. Evaluation of the golden proportion in the natural dentition: A systematic review and meta-analysis. *J Prosthet Dent* 2021;(S0022-3913-7). doi: S0022-3913(21)00415-7, In press.
34. Liao P, Fan Y, Nathanson D. Evaluation of maxillary anterior teeth width: a systematic review. *J Prosthet Dent* 2019;122(3):275–81, e7.
35. Akl MA, Mansour DE, Mays K, et al. Mathematical tooth proportions: a systematic review. *J Prosthodont* 2021. <https://doi.org/10.1111/jopr.13420>. In press.
36. Ward DH. Proportional smile design: using the recurring esthetic dental proportion to correlate the widths and lengths of the maxillary anterior teeth with the size of the face. *Dental Clin* 2015;59(3):623–38.
37. Nimbalkar S, Oh YY, Mok RY, et al. Smile attractiveness related to buccal corridor space in 3 different facial types: a perception of 3 ethnic groups of Malaysians. *J Prosthet Dent* 2018;120(2):252–6.
38. Mollabashi V, Abolvardi M, Akhlaghian M, et al. Smile attractiveness perception regarding buccal corridor size among different facial types. *Dental Med Probl* 2018;55(3):305–12.
39. Oshagh M, Zarif NH, Bahramnia F. Evaluation of the effect of buccal corridor size on smile attractiveness. *Eur J Esthet Dent* 2010;5(4):370–80.
40. Cheng C-W, Ye S-Y, Chien C-H, et al. Randomized clinical trial of a conventional and a digital workflow for the fabrication of interim crowns: an evaluation of treatment efficiency, fit, and the effect of clinician experience. *J Prosthet Dent* 2021; 125(1):73–81.
41. Khanna N. *The envelope of function: understanding and importance*, . *Functional Aesthetic Dentistry*. 1st. Switzerland: Springer; 2020. p. 35–53. https://doi.org/10.1007/978-3-030-39115-7_3.
42. UTZ KH, Müller F, Lückerrath W, et al. The lateral leeway in the habitual intercus-pation: experimental studies and literature review. *J Oral Rehabil* 2007;34(6): 406–13.

43. Myagmar G, Lee J-H, Ahn J-S, et al. Wear of 3D printed and CAD/CAM milled interim resin materials after chewing simulation. *J Adv Prosthodont* 2021; 13(3):144.
44. Afrashtehfar KI, Bryant SR. Understanding the lived experience of north american dental patients with a single-tooth implant in the upper front region of the mouth: protocol for a qualitative study. *JMIR Res Protoc* 2021;10(6):e25767.
45. Gamer S, Tuch R, Garcia LT. MM House mental classification revisited: Intersection of particular patient types and particular dentist's needs. *J Prosthet Dent* 2003;89(3):297–302.
46. Mörch C, Atsu S, Cai W, et al. Artificial intelligence and ethics in dentistry: a scoping review. *J Dent Res* 2021;100(13):1452–60.
47. Revilla-León M, Gómez-Polo M, Vyas S, et al. Artificial intelligence models for tooth-supported fixed and removable prosthodontics: a systematic review. *J Prosthet Dent* 2021. doi: S0022-3913(21)00309-7, In press.
48. Revilla-León M, Gómez-Polo M, Vyas S, et al. Artificial intelligence applications in restorative dentistry: a systematic review. *J Prosthet Dent* 2021. doi: S0022-3913(21)00087-1, In press.
49. Chen Y-w, Stanley K, Att W. Artificial intelligence in dentistry: current applications and future perspectives. *Quintessence Int* 2020;51(3):248–57.
50. Touati R, Richert R, Millet C, et al. Comparison of two innovative strategies using augmented reality for communication in aesthetic dentistry: a pilot study. *J Healthc Eng* 2019;2019.
51. Fallahi HR, Keyhan SO, Cheshmi B, et al. Augmented reality: new horizons in oral and maxillofacial surgery, . *Integrated procedures in facial cosmetic surgery*. 1st. Switzerland: Springer; 2021. p. 593–7. https://doi.org/10.1007/978-3-030-46993-1_51.
52. Rodríguez CP, Judge RB, Castle D, et al. Body dysmorphia in dentistry and prosthodontics: a practice based study. *J Dent* 2019;81:33–8.
53. Panossian AJ, Block MS. Evaluation of the smile: facial and dental considerations. *J Oral Maxillofac Surg* 2010;68(3):547–54.