

Imaging-Based, Patient-Specific Three-Dimensional Printing to Plan, Train, and Guide Cardiovascular Interventions: A Systematic Review and Meta-Analysis

Benedikt Bernhard, MD ^{a,1}, Joël Illi, MSc ^{a,b,1}, Martin Gloeckler, MD ^a, Thomas Pilgrim, MD ^a, Fabien Praz, MD ^a, Stephan Windecker, MD ^a, Andreas Haerberlin, MD, PhD ^{a,c}, Christoph Gräni, MD, PhD ^{a,c,*}

^aDepartment of Cardiology, Inselspital, Bern University Hospital, University of Bern, Bern, Switzerland

^bSwiss MedTech Center, Switzerland Innovation Park Biel/Bienne AG, Switzerland

^cTranslational Imaging Center, Sitem Center, University of Bern, Switzerland

Received 14 December 2021; accepted 14 April 2022; online published-ahead-of-print xxx

Background	To tailor cardiovascular interventions, the use of three-dimensional (3D), patient-specific phantoms (3DPSP) encompasses patient education, training, simulation, procedure planning, and outcome-prediction.
Aim	This systematic review and meta-analysis aims to investigate the current and future perspective of 3D printing for cardiovascular interventions.
Methods	We systematically screened articles on Medline and EMBASE reporting the prospective use of 3DPSP in cardiovascular interventions by using combined search terms. Studies that compared intervention time depending on 3DPSP utilisation were included into a meta-analysis.
Results	We identified 107 studies that prospectively investigated a total of 814 3DPSP in cardiovascular interventions. Most common settings were congenital heart disease (CHD) (38 articles, 6 comparative studies), left atrial appendage (LAA) occlusion (11 articles, 5 comparative, 1 randomised controlled trial [RCT]), and aortic disease (10 articles). All authors described 3DPSP as helpful in assessing complex anatomic conditions, whereas poor tissue mimicry and the non-consideration of physiological properties were cited as limitations. Compared to controls, meta-analysis of six studies showed a significant reduction of intervention time in LAA occlusion (n=3 studies), and surgery due to CHD (n=3) if 3DPSPs were used (Cohen's d=0.54; 95% confidence interval, 0.13 to 0.95; p=0.001), however heterogeneity across studies should be taken into account.
Conclusions	3DPSP are helpful to plan, train, and guide interventions in patients with complex cardiovascular anatomy. Benefits for patients include reduced intervention time with the potential for lower radiation exposure and shorter mechanical ventilation times. More evidence and RCTs including clinical endpoints are needed to warrant adoption of 3DPSP into routine clinical practice.
Keywords	Patient specific phantoms • 3D printing • Additive manufacturing • Cardiovascular intervention • Personalized medicine

*Corresponding author at: Department of Cardiology, University Hospital Bern, Inselspital Bern, Freiburgrstrasse 18, 3010 Bern, Switzerland; Email: christoph.graeni@insel.ch; Twitter: @chrisgraeni

¹Contributing first authors.

© 2022 The Author(s). Published by Elsevier B.V. on behalf of Australian and New Zealand Society of Cardiac and Thoracic Surgeons (ANZSCTS) and the Cardiac Society of Australia and New Zealand (CSANZ). This is an open access article under the CC BY license (<http://creativecommons.org/licenses/by/4.0/>).

Please cite this article in press as: Bernhard B, et al. Imaging-Based, Patient-Specific Three-Dimensional Printing to Plan, Train, and Guide Cardiovascular Interventions: A Systematic Review and Meta-Analysis. Heart, Lung and Circulation (2022), <https://doi.org/10.1016/j.hlc.2022.04.052>

Introduction

Cardiac imaging using cardiac magnetic resonance imaging (CMR) and cardiac computed tomography (CCT) has undergone a rapid development within the last decades, today depicting cardiac anatomy and physiology with excellent temporal and spatial resolution. Four-dimensional image datasets, as well as advanced post-processing techniques, have laid the basis for the large number of personalised invasive structural cardiac interventions, available today. Translation of imaging data to physic patient-specific models is the next frontier in this respect that could facilitate further refinements and patient-specific tailoring of interventions. Three dimensional (3D) printing, also known as rapid prototyping or additive manufacturing, is a promising technology well-established for individualisation of treatment in orthopedic surgery [1], whereas its use in cardiovascular medicine is yet to be defined. Extension in the field of cardiovascular medicine needs to take into consideration varying size of structures according to the cardiac cycle, difficult delineation of soft-tissues and the cardiac valves and the inclusion of functional properties [2]. Patient-specific 3D printed phantoms (3DPSP) meeting these requirements cannot only enhance medical and patient education, but can also be used to plan, train, simulate, and guide cardiovascular interventions. Obtaining accurate 3DPSP of complex anatomic structures allows *ex vivo* visualisation and delineation of complex spatial relationships in various cardiovascular disease settings [3]. Although the translation of clinically indicated cardiac imaging to 3DPSP does not expose the patient to additional risk, several challenges remain to be overcome before 3D printing will meet widespread clinical acceptance for individualisation of cardiovascular interventions. The scope of this systematic review is to analyse utility of 3D printing in cardiovascular interventions as well as its limitations. Current applications and future directions will be discussed to help interventional cardiologists and surgeons find the ideal targets for 3D printing.

Methods

Two independent reviewers (i.e., authors B.B. and J.I.) conducted a systematic literature query on the databases Medline and EMBASE using the key terms “3D printing,” “3D phantom,” or “additive manufacturing,” plus one of the terms “cardiovascular,” “cardiac,” “aorta,” “aortic-, mitral-, tricuspid-, or pulmonary valve,” “coronary arteries,” “left atrial appendage,” “congenital heart disease,” or “hypertrophic cardiomyopathy” for “All fields” search (Figure 1). All fields search tools also included Medical Subject Headings (MeSH) terms. Any inconsistencies were discussed and reconciled by a third reviewer (i.e., author C.G.). Inclusion criteria were the prospective use of at least one 3DPSP in cardiovascular intervention, published between 1 January 2005 and 1 May 2021, and the investigation of human data as the subject in a peer-reviewed article. Cardiovascular intervention was defined as open surgery or transcatheter intervention of the heart and its

structures, the ascending aorta, the aortic arch, and the descending aorta above the coeliac trunk. Studies that printed 3D models for other purposes than personalised medicine (e.g., non-personalised models for validation of imaging modalities) and articles about tissue engineering or bioprinting were excluded, as well as reviews and case reports on applications that had previously been investigated by other studies. Included studies were screened for cross-references fulfilling our inclusion criteria.

Meta-analysis and forest plotting were performed using Meta-Essentials Version 1.5 for Microsoft Excel [4]. Combined effect size is provided by Cohen’s *d* (mean difference/standard deviation), which was determined by a random-effect model. Weak effects are represented by $d < 0.3$; $d = 0.3–0.8$ indicates medium effect size, whereas strong effects are mirrored by $d > 0.8$. In this model, we included all studies that provided data for mean intervention time and its standard deviation in a group with 3DPSP compared to a control group without 3DPSP. For studies that provided median intervention time and its range, we estimated mean and variance according to Hozo *et al.* [5]. The extent of heterogeneity was estimated by *Q*-statistics (“Cochrane’s *Q*” test). I^2 and T^2 were provided to quantify inconsistencies of results across studies as an estimate of the standard deviation of the distribution of effect sizes [6]. Although no clearly defined cut-off exists, $I^2 = 30%–60%$ usually refers to moderate heterogeneity, whereas substantial heterogeneity might be indicated by $I^2 > 60%$. Results were considered significant if the two-sided *p*-value was ≤ 0.05 . This review was conducted in accordance to the Preferred Reporting Items for Systematic Reviews and Meta-Analyses (PRISMA) guidelines [7], and ethical approval was waived, as no human subjects are involved in this study.

Results

After removing duplicate records, we identified 2,227 articles corresponding to our key search terms, of which a total of 86 articles fulfilled inclusion criteria (Figure 1). Another 21 studies were added via cross-references, resulting in a total of 107 included studies. The number of newly published articles on the use of 3DPSP in cardiovascular intervention has been constantly rising within the last 16 years with approximately half of the identified study being published after 2017 and a trend towards an increase in the number of models obtained in each study using December 2017 as a cutoff (6.4 ± 9.1 vs 8.9 ± 11.8 ; $p = 0.241$) (Figure 2). The included studies with cumulative 814 3DPSP encompass case reports with one patient included ($n = 38$), case series with less than 10 patients ($n = 38$), larger observational and descriptive studies ($n = 18$), comparative studies with a control group with no 3DPSP ($n = 12$), and one randomised controlled trial (Table 1).

Congenital Heart Disease

A total of 38 studies prospectively investigating 3DPSP to guide cardiovascular intervention in congenital heart

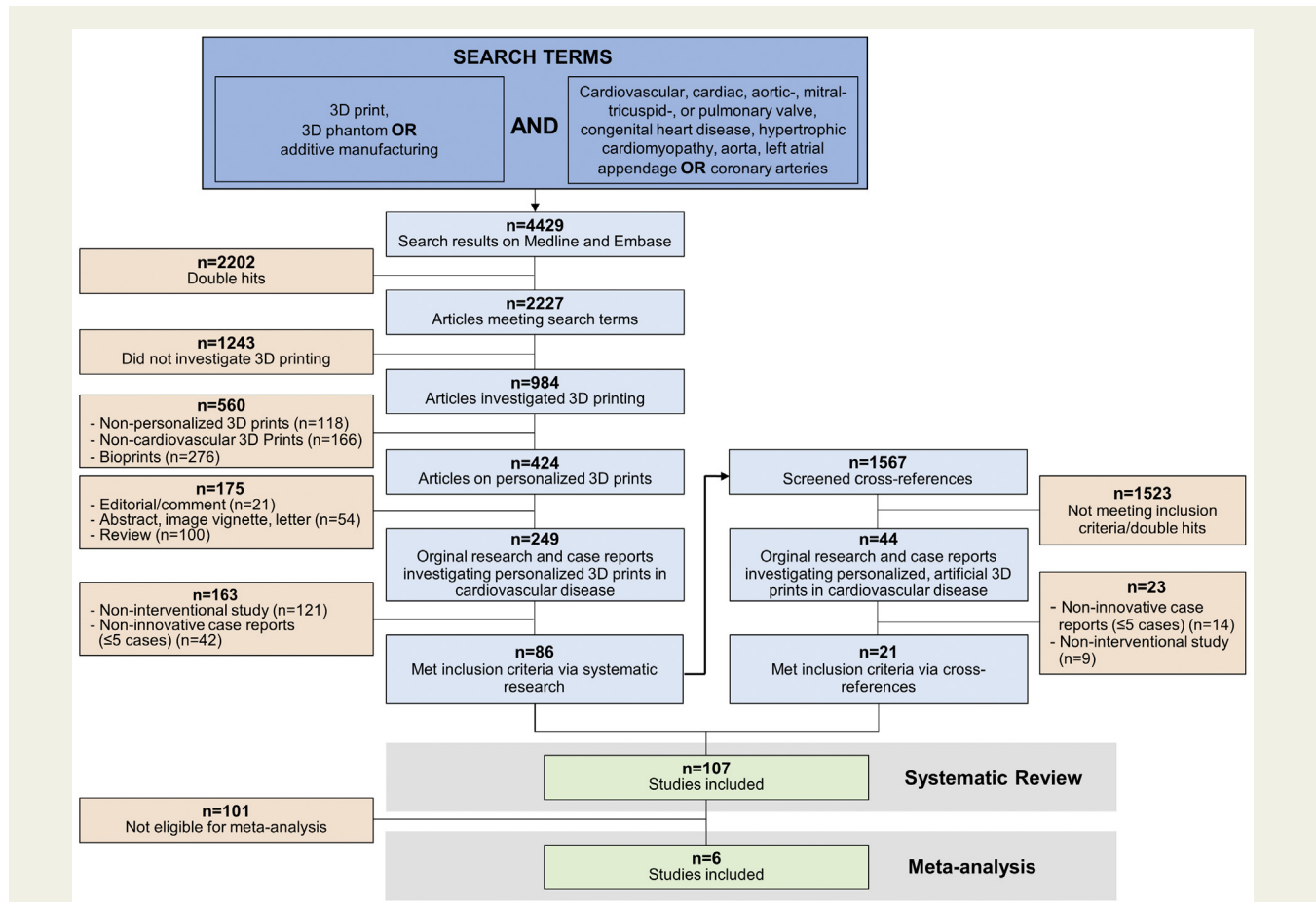


Figure 1 Consort flow of the study selection process. Non-personalised three-dimensional (3D) prints also included animal studies, and articles using personalized 3D models for validation of imaging modalities. Prospective interventional studies were defined by the production and the use of a 3D printed model prior to the intervention. Case reports with less than 5 patients were excluded if larger studies in the same setting existed.

disease (CHD) of which six studies systematically compared 3DPSP to standard therapy and included a control group without 3DPSP. Across all studies, 329 3DPSP were manufactured, rendering CHD the field with the widest application of 3DPSP in cardiovascular interventions. Mottl-Link et al. [8] reported one of the first cases in which a 3DPSP was considered to impact patient management in CHD. A CMR-derived 3DPSP was intraoperatively shown to the surgeon to identify the location of coronary arteries and other structures enabling a complex operation. Valverde et al. [9] extended the use of 3DPSP to the field of transcatheter cardiovascular interventions and reported 3DPSP being a valuable adjunct in planning and simulating endovascular stenting in transverse aortic arch hypoplasia. Following this approach, feasibility of 3DPSP to identify the optimal prosthesis in terms of size for transcatheter closure of atrial septal defect or patent ductus arteriosus was demonstrated [10,11]. Also, 3DPSP can enrich patient counselling [12–14] and affect clinical decision making [15]. In the largest multicentre case-crossover study of CHD to date, decisions on the therapeutic management made by review of imaging data only were

compared to decisions based on imaging data and an additional 3DPSP. In nearly half of the included 40 patients (n=19), application of 3DPSP changed the surgical decision and helped to redefine the surgical approach [15]. Compared to standard therapy without 3DPSP, 3DPSP-guided surgery due to CHD might affect operation duration [16,17], aortic cross-clamp time, mechanical ventilation time, and intensive care unit time [11,18]. A benefit of 3DPSP in terms of outcome was reported in a retrospective analysis of 30 patients who underwent device closure for multiple atrial septal defects. Compared to a control group using fluoroscopic guidance, patients treated after previous training on 3DPSP showed lower frequency of occluding device replacement and prevalence of residual shunts, which is also associated with lower costs [19]. Allocation to the use of 3DPSP was in none of the latter studies randomised and results should therefore interpreted with caution. Heterogeneity between studies and the wide spectrum of CHD reduces the generalisability of the findings; nevertheless, CHD is the setting with the largest experience and the broadest body of evidence for the use of 3DPSP in cardiovascular intervention.

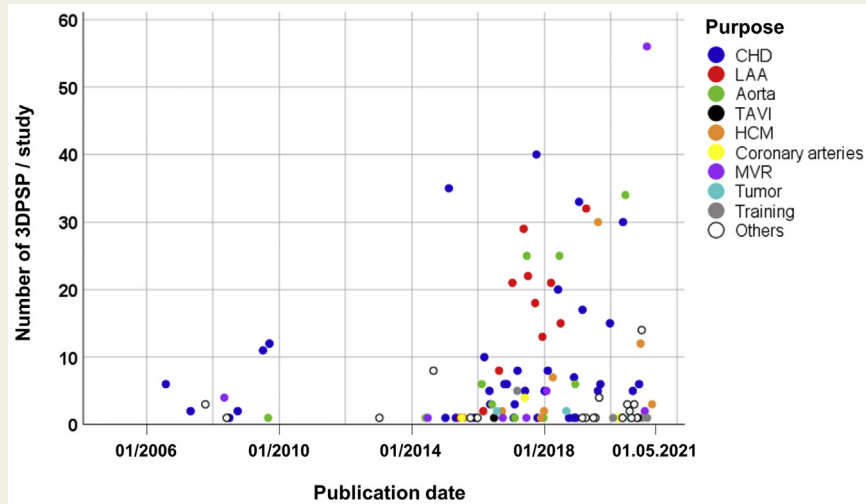


Figure 2 Number and cohort size of articles prospectively investigating 3DPSP in cardiovascular intervention in this review. Abbreviations: 3DPSP, three-dimensional printed patient-specific phantom; CHD, congenital heart disease; HCM, hypertrophic cardiomyopathy; LAA, left atrial appendage; MVR, mitral valve repair or replacement; TAVI, transcatheter aortic valve implantation.

Left Atrial Appendage Closure

The size, shape, and position of the left atrial appendage (LAA) are highly variable, which predisposes utilization of 3DPSP in the setting of LAA closure. Available evidence from 11 studies, including one RCT demonstrated the value of a total of 182 3DPSP for device sizing and a reduction of intervention time. Liu *et al.* [20] reported in a case series of eight patients that the device size predicted by the 3DPSP is fully consistent with the device size chosen during the intervention and was able to predict technical challenges during the intervention as well as the presence of peri-device leaks. Additional studies corroborated these findings with high agreement and showed that device sizing by 3DPSP does better predict the final implanted device size (accurate in 95%, 100%, 100%, and 96.9%, respectively) than transoesophageal echocardiography, which underestimated the final size in 10, 4, 7, and 13 cases (45%, 45%, 47%, and 40.6%, respectively) [21–24]. Comparative studies observed a decrease in intervention and fluoroscopy time and an increased likelihood for the absence of peri-device leak if a 3DPSP was considered peri-interventional [22,24,25]. Li *et al.* [26] performed the only RCT that prospectively investigated 3DPSP in cardiovascular intervention where 42 patients were randomised to undergo LAA occlusion guided by 3DPSP or standard therapy guided by transoesophageal echocardiography and CCT. In the 3DPSP group, no residual shunts occurred and radiation exposure was significantly reduced compared to the control group in which three mild residual shunt cases were observed [26].

Aortic Disease

3DPSP can be applied in the planning and guiding of catheter-based, as well as in surgical treatment of various

aortic disease and influence decision-making in planning endovascular aortic repair (EVAR). Review on an additional 3DPSP was reported to change the management decision in 20% of cases compared to review of the CCT images alone in patients with aortic aneurysm [27]. Training residents in EVAR on 3DPSP prior to the intervention was demonstrated to reduce fluoroscopy and intervention time, and lower contrast agent application compared to a control group without training ($n=10$) [28]. It remains to be determined whether similar associations might have been observed if a non-personalised model had been used. Larger case series evaluated 3DPSP as a valuable instrument in catheter-based, as well as in the surgical treatment of complex aortic disease [29,30]. Tong *et al.* [31] demonstrated feasibility to fenestrate stent-grafts on 3DPSP before endovascular repair of aortic aneurysm in 34 patients. Before the intervention stents were implanted into a 3DPSP to identify the positions of branches requiring fenestration. With the novel approach, only two branch arteries of 107 fenestrations secured by 102 bridging stent grafts were lost across the intervention.

Available evidence consistently demonstrated safety, reliability, and accuracy of 3DPSP in aortic disease, and paved the way for comparative studies or RCT that could support broader applications of 3DPSP in aortic disease.

Mitral Valve Repair and Replacement

In the included six studies investigating 3DPSP in mitral valve (MV) interventions, 66 3DPSP were evaluated with only one study including more than five cases. Izzo *et al.* [32] demonstrated the use of a 3DPSP to size the valve prosthesis prior to transcatheter MV replacement. Furthermore, 3DPSP were evaluated for risk assessment of left ventricular outflow tract

Table 1 Studies included in this systematic review.

First author	Year	n	Type	Imaging Modality	Setting	Comments
Ngan et al. [86]	2006	6	Systematic study	CCT	CHD	3DPSP to plan surgery in pulmonary atresia
Sodian et al. [87]	2007	2	Case series	CCT or CMR	CHD	3DPSP for surgical planning in various settings
Mottl-Link et al. [8]	2008	1	Case report	CMR	CHD	3DPSP to assess intracardiac anatomy in complex CHD
Sodian et al. [76]	2008	1	Case report	CCT	Others	3DPSP to plan SAVR after previous coronary artery bypass
Sodian et al. [88]	2008	2	Case series	CCT or CMR	CHD	3DPSPs to guide heart transplantation due to severe CHD
Jacobs et al. [54]	2008	3	Case series	CCT or CMR	Others	3DPSP in ventricular aneurysm or malignant cardiac tumour
Kim et al. [89]	2008	4	Case series	CCT	CHD	3DPSP guidance on surgical revision of VSD and various other cases
Sodian et al. [90]	2009	1	Case report	CCT	Aorta	3DPSP to guide closure of an anastomotic leak after aortic arch replacement
Riesenkampff et al. [91]	2009	11	Case series	CCT or CMR	CHD	3DPSP to assess intracardiac anatomy in complex CHD prior surgery
Shiraishi et al. [92]	2010	12	Case series	CCT	CHD	Rubber-like urethane 3DPSP to train cutting and suturing prior CHD-surgery
Schmauss et al. [53]	2013	1	Case report	CMR	Others	3DPSP in the resection of a cardiac fibroma
Schmauss et al. [93]	2014	1	Case report	CCT	Aorta	3DPSP for planning surgery in complex aortic arch aneurysm.
Dankowski et al. [94]	2014	1	Case report	CCT	MVR	Production of a 3DPSP prior percutaneous mitral annuloplasty
Farooqi et al. [95]	2015	1	Case report	CMR	CHD	3DPSP for planning in a patient with double outlet right ventricle
Valverde e al. [9]	2015	1	Case report	CMR	CHD	3DPSP to guide stenting of transverse aortic arch hypoplasia
Watanabe et al. [61]	2015	1	Case report	CCT	Others	3DPSP to plan percutaneous coronary intervention in occluded RCA
Yang et al. [36]	2015	1	Case report	CCT	HCM	Guidance of a 3DPSP on septal myectomy
Otton et al. [96]	2015	1	Case report	CCT	LAA	LAA occlusion guiding and occlusion device sizing on 3DPSP
Son et al. [51]	2015	1	Case report	CCT	Others	3DPSP in the resection of a cardiac schwannoma
Fujita et al. [46]	2015	1	Case report	CCT	TAVI	Training of TAVI on a 3DPSP
Lazkani et al. [65]	2015	1	Case report	CCT	Others	3DPSP to guide surgical therapy of a post-infarct VSD
Schmauss et al. [97]	2015	8	Case series	CCT or CMR	Others	3DPSP in perioperative planning in various cardiac disease
Ma et al. [98]	2015	35	Systematic study	CCT	CHD	3DPSP to guide VSD repair
Kiraly et al. [99]	2016	1	Case report	CCT	CHD	3DPSP in surgical repair of Norwood-1 complex aortic arch obstruction
Bharati et al. [100]	2016	1	Case report	CMR	CHD	Planning surgery due to double outlet right ventricle on 3DPSP
Izzo et al. [32]	2016	1	Case report	CCT	MVR	3DPSP for planning of transcatheter MVR

Table 1. (continued).

First author	Year	n	Type	Imaging Modality	Setting	Comments
Al Jabbari <i>et al.</i> [55]	2016	2	Case series	CCT	Others	3DPSP to guide resection of secondary malignant cardiac tumours
Pellegrino <i>et al.</i> [101]	2016	2	Case series	CCT	LAA	LAA occlusion guiding by 3DPSP
Hossien <i>et al.</i> [102]	2016	3	Case series	CCT	Aorta	3DPSP guidance on treatment of type A aortic dissection
Garekar <i>et al.</i> [103]	2016	5	Case series	CCT or CMR	CHD	Evaluation of the accuracy of 3DPSP in complex CHD
Tam <i>et al.</i> [27]	2016	6	Case series	CCT	Aorta	Evaluation the impact of 3DPSP on decision making in EVAR
Wang <i>et al.</i> [10]	2016	6	Case series	CCT	CHD	Planning percutaneous transcatheter closure of ASD on 3DPSP
Liu <i>et al.</i> [20]	2016	8	Case series	3DTOE	LAA	3DPSPs for sizing of LAA occlusion devices
Olivieri <i>et al.</i> [104]	2016	10	Systematic study	CCT or CMR	CHD	3DPSP to enhance postoperative intensive care of patients with CHD
Benke <i>et al.</i> [105]	2017	1	Case report	CCT	Aorta	3DPSP to plan surgery due to aortic pseudoaneurysm
Pluchinotta <i>et al.</i> [106]	2017	1	Case report	CCT	Aorta	Simulated stenting of aortic coarctation on a 3DPSP
Biglino <i>et al.</i> [14]	2017	1	Case report	CCT	CHD	Planning surgery in CHD and educate patients and parents on 3DPSP
Hamatani <i>et al.</i> [37]	2017	1	Case report	CCT	HCM	Training and guidance of a 3DPSP on septal myocardial ablation
Sardari Nia <i>et al.</i> [107]	2017	1	Case report	3DTOE	MVR	3DPSP to plan of endoscopic MV repair
Smith <i>et al.</i> [108]	2017	1	Case report	CCT	CHD	Use of a 3DPSP prior heart transplantation due to severe CHD
Hermesen <i>et al.</i> [35]	2017	2	Case series	CCT	HCM	Guidance of a 3DPSP on septal myectomy
McGovern <i>et al.</i> [109]	2017	3	Case series	CCT	CHD	3DPSP in the management of patients with univentricular circulation
Vodiskar <i>et al.</i> [110]	2017	3	Case series	CCT	CHD	3DPSP in planning surgery for complex CHD
Velasco Forte <i>et al.</i> [60]	2017	4	Case series	CCT or CMR	Others	3DPSP to plan intervention in patients with coronary artery fistulae
Kappanayil <i>et al.</i> [111]	2017	5	Case series	CMR	CHD	3DPSP to plan prior surgery in complex CHD.
Bhatla <i>et al.</i> [112]	2017	6	Case series	CCT or CMR	CHD	3DPSP to guide management decisions in patients with CHD
Hell <i>et al.</i> [21]	2017	22	Comparative study	CCT	LAA	3DPSP to size the occlusion device prior LAA closure
Valverde <i>et al.</i> [15]	2017	40	Comparative study	CCT or CMR	CHD	Multicenter study evaluating the impact of 3DPSP on decision making in CHD
Li <i>et al.</i> [26]	2017	21	RCT	CCT	LAA	RCT evaluating the use of 3DPSP in the setting of LAA occlusion
Yoo <i>et al.</i> [56]	2017	5	Systematic study	CCT or CMR	Training	Hands-on surgical training on 3DPSP of patients with CHD
Olejník <i>et al.</i> [113]	2017	8	Systematic study	CCT	CHD	Evaluation of the accuracy of 3DPSP of patients with CHD
Song <i>et al.</i> [114]	2017	18	Systematic study	3DTOE	LAA	3DPSP to guide LAA occlusion
Torres <i>et al.</i> [28]	2017	25	Systematic study	CCT	Aorta	Training residents on EVAR on 3DPSP

Table 1. (continued).

First author	Year	n	Type	Imaging Modality	Setting	Comments
Goitein et al. [115]	2017	29	Systematic study	CCT	LAA	3DPSP to guide LAA occlusion device sizing
Aroney et al. [116]	2018	1	Case report	CCT	CHD	3DPSP to plan percutaneous closure of a cardiac fistula
Riggs et al. [50]	2018	2	Case series	CCT or CMR	Others	Guidance on pediatric tumour debulking by a 3DPSP
Andrushchuk et al. [39]	2018	2	Case series	CCT	HCM	Combination of virtual simulated myectomy and 3DPSP in HCM
Parimi et al. [117]	2018	5	Case series	Angiography	CHD	Producing 3DPSP from angiography for interventions in CHD
Sun et al. [118]	2018	5	Case series	CCT	CHD	Planning intervention on 3DPSP in patients with Kommerell's diverticulum
Gomes et al. [30]	2018	6	Case series	CCT	Aorta	3DPSP to guide endovascular repair in various aortic disease
Marone et al. [29]	2018	25	Case series	CCT	Aorta	Use of 3DPSP to plan and guide aortic surgery
Zhao et al. [18]	2018	8	Comparative study	CCT	CHD	3DPSP to plan surgery in complex CHD
Obasare et al. [22]	2018	13	Comparative study	CCT	LAA	3DPSPs for sizing of LAA occluders
Ciobotaru et al. [25]	2018	21	Comparative study	CCT	LAA	Comparison of a pro- and retrospective use of 3DPSP in LAA-occlusion
Ryan et al. [17]	2018	33	Comparative study	CCT or CMR	CHD	Comparison of the procedure time of CHD-surgery dependent on 3DPSP use
El Sabbagh et al. [33]	2018	5	Systematic study	CCT	MVR	3DPSP for outcome-prediction and valve sizing in MVR
Guo et al. [38]	2018	7	Systematic study	CCT	HCM	3DPSP for planning and patient educating prior septal myectomy
Hoashi et al. [119]	2018	20	Systematic study	CCT	CHD	3DPSP to guide young consultant surgeons in biventricular repair
Brun et al. [120]	2019	1	Case report	CCT	CHD	Combination of virtual reality and 3DPSP to guide surgery in CHD
Barabás et al. [80]	2019	1	Case report	CCT	Others	LVAD cannula placement with the help of a 3DPSP
Al-Hijji et al. [70]	2019	1	Case report	CCT	Others	3DPSP to guide transapical closure of a LVOT pseudoaneurysm
Mohamed et al. [69]	2019	1	Case report	CCT	Others	Guidance on LV pseudoaneurysm closure by a 3DPSP
Aroney et al. [67]	2019	4	Case series	CCT or CMR	Others	Complex cases of cardiac fistulae repair guided by 3DPSP
Xu et al. [121]	2019	15	Case series	CCT	CHD	3DPSP in planning surgery for anomalous pulmonary venous connection
Xu et al. [122]	2019	17	Case series	CCT	CHD	3DPSP to plan surgery in complex CHD
Han et al. [16]	2019	6	Comparative study	CCT	CHD	Comparison of the procedure time of CHD surgery dependent on 3DPSP use
Matsubara et al. [11]	2019	7	Comparative study	CCT	CHD	3DPSP to guide percutaneous closure of patent ductus arteriosus
Hachulla et al. [23]	2019	15	Comparative study	CCT	LAA	3DPSP for sizing of LAA occlusion devices
Alabbady et al. [123]	2019	1	Case report	CCT	Others	3DPSP to plan repair of an aorto-right ventricular fistula

Table 1. (continued).

First author	Year	n	Type	Imaging Modality	Setting	Comments
Fan et al. [24]	2019	32	Comparative study	3DTOE	LAA	LAA occlusion guiding and occlusion device sizing on 3DPSP
Andrushchuk et al. [41]	2019	30	Systematic study	CCT	HCM	Combination of virtual simulated myectomy and 3DPSP in HCM
Ali et al. [52]	2020	1	Case report	CCT	Others	Use of a 3DPSP to plan surgical revision of cardiac myxoma
Niizeki et al. [63]	2020	1	Case report	CCT	Others	3DPSP to plan percutaneous coronary intervention in coronary anomaly
Young et al. [62]	2020	1	Case report	CCT	Others	3DPSP for development of a new catheter in occluded RCA
Miller et al. [79]	2020	1	Case report	CCT	Others	3DPSP to simulate LVAD implantation in a failing systemic RV
Kanawati et al. [66]	2020	1	Case report	CCT	Others	Planning CRT-D implantation in complex CHD
Motwani et al. [78]	2020	1	Case report	CCT	Others	Transcatheter closure of paravalvular regurgitation guided by 3DPSP
Spring et al. [73]	2020	1	Case report	CCT	Others	Use of a 3DPSP to plan tricuspid valve-in-valve replacement
Shetty et al. [71]	2020	1	Case report	CMR	Others	3DPSP to guide surgical closure of submitral aneurysm
Basman et al. [47]	2020	1	Case report	CCT	TAVI	3DPSP to achieve a TAVI valve-in-valve procedure
ElGuindy et al. [77]	2020	2	Case series	3DTOE	MVR	Planning paravalvular leak interventions after MVR on 3DPSP
Shearn et al. [72]	2020	2	Case series	CCT	Others	3DPSP to guide Ozaki repair of bicuspid aortic valve
Vukicevic et al. [75]	2020	3	Case series	CCT or 3DTOE	Others	3DPSP for planning Mitraclip implantation
He et al. [124]	2020	5	Case series	CCT	CHD	Closure of multiple ASD guided by a 3DPSP
Perens et al. [125]	2020	6	Case series	CCT or CMR	CHD	3DPSP-guidance on surgical revision of complex CHD
Pizzuto et al. [68]	2020	3	Case series	CCT	Others	Guidance on LV pseudoaneurysm closure by a 3DPSP
Li et al. [19]	2020	30	Comparative study	CCT	CHD	Comparison of 3DPSP- and TOE guided ASD closure to fluoroscopic guidance
Nam et al. [57]	2020	1	Systematic study	CCT	Training	Repetitive training of VSD closure on 3DPSP
Hussein et al. [58]	2020	1	Systematic study	-	Training	Repetitive training of arterial switch procedure on 3DPSP
Hussein et al. [59]	2020	1	Systematic study	-	Training	Repetitive surgical training on 3DPSP of CHD
Wang et al. [40]	2020	12	Systematic study	CCT	HCM	Training septal myectomy on 3DPSP
Borracci et al. [64]	2020	14	Systematic study	-	Others	3DPSP to plan adult cardiovascular surgery
Harb et al. [74]	2020	4	Case series	CCT	Others	3DPSP to tailor surgical tricuspid valve repair
Tong et al. [31]	2020	34	Systematic study	CCT	Aorta	3DPSP to fenestrate stent grafts in aortic disease

Table 1. (continued).

First author	Year	n	Type	Imaging Modality	Setting	Comments
Kim et al. [126]	2021	3	Case series	CCT	HCM	3DPSP in pre-interventional planning and training in HCM
Cen et al. [127]	2021	5	Case series	CCT	CHD	Combination of virtual reality and 3DPSP in pulmonary atresia
Wang et al. [34]	2021	56	Comparative study	CCT	MVR	3DPSP to predicted LVOT obstruction after MVR.

Abbreviations: 3DPSP, three-dimensional printed patient specific phantom; ASD, atrial septum defect; CCT cardiac computed tomography; CHD, congenital heart disease; CMR, cardiac magnet resonance imaging; CRT-D, cardiac resynchronisation therapy–dual; EVAR, endovascular aortic repair; HCM, hypertrophic cardiomyopathy; LAA, left atrial appendage; LVAD, left ventricular assist device; LVOT, left ventricular outflow tract; MVR, mitral valve replacement/repair; RCA, right coronary artery; RCT, randomised controlled trial; SAVR, surgical aortic valve replacement; TAVI, transcatheter aortic valve implantation; TOE, transoesophageal echocardiography; VSD, ventricular septum defect.

obstruction (LVOTO) after MV replacement. Combined with virtual models, it was possible to predict LVOTO by simulation of MV implantation into the 3DPSP [33,34]. Simulated MV replacement on a flexible silicone 3DPSP and testing it in a mock circulatory system was superior in terms of LVOTO-prediction if compared to a digital model, a rigid anatomical 3DPSP made of resin, or the flexible silicone models without dynamic testing [34]. However, the lack of cardiac cycle simulation must be considered as a limitation of 3DPSP in this setting.

Hypertrophic Cardiomyopathy

Eight (8) studies were identified prospectively enrolling patients undergoing 3DPSP guided intervention for hypertrophic cardiomyopathy (HCM). Case reports demonstrated feasibility of 3DPSP to train and guide septal myectomy [35–37] and for patient education prior intervention [38]. Andrushchuk et al. [39] developed an innovative approach in which a 3D print of the severely hypertrophic septum was conducted as a first step. In a second step, computer simulation was used to model the same septum after an optimal virtual myectomy. Thus, the targeted septum, as well as the resected part, were reprinted as 3D model. Both models, the native and the virtually treated one with its resected fragment guided the surgeon during the intervention in two cases. Besides these case reports, three prospective studies including more than five subjects systematically investigated 3DPSP before myectomy [38,40,41]. Authors evaluated them as a helpful tool in the planning of the intervention and for intraoperative guiding to achieve optimal septum thickness, whereas comparative studies are lacking.

Transcatheter Aortic Valve Implantation

Most studies investigating 3DPSPs in transcatheter aortic valve implantation (TAVI) were conducted retrospectively and are not part of this systematic review. They could prove the concept of valve sizing and prediction of paravalvular

regurgitation on a 3DPSP [42–45]. Two (2) prospective case reports demonstrated feasibility to train TAVI on a 3DPSP [46,47]. Basman et al. [47] described successful valve-in-valve implantation in a 65-year-old man guided by a 3DPSP. Prior ex vivo implantation of different valves on the model and consecutive seal analysis helped to choose an adequate valve size and lead to a satisfying result in this patient. Further studies on 3DPSP in the setting of TAVI are warranted. The potential of 3DPSP comprises the selection of optimal valve type and size, and the prediction of annulus rupture and coronary artery obstruction (also see Figure 3), particularly in case of valve-in-valve TAVI [48]. 3DPSP of the aortic root and the vascular access may provide further guidance on the feasibility of transfemoral TAVI or if alternative access or surgical aortic valve replacement should be favoured.

Cardiac Tumours

Cardiac and pericardial tumours represent a rare, but large spectrum of different entities with highly variable location, anatomy, and haemodynamic consequences [49]. Involved structures are difficult to delineate and might be anatomically inaccessible which often complicates planning of surgery and defining the optimal extent of tumour debulking. In such settings 3DPSP were applied to guide surgery in pediatric cardiac tumours (n=2) [50], cardiac schwannoma (n=1) [51], cardiac myxoma (n=1) [52], cardiac fibroma (n=1) [53], high-grade sarcoma (n=1) [54], as well as secondary cardiac tumours (n=2) [55]. All authors described an enhancement of the preoperative management of these patients and found 3DPSPs helpful in the planning of the optimal interventional approach. However, no comparative study and no case series including more than two patients exists that systematically investigated 3DPSP in the setting of cardiac tumours.

Training of Interventions

Four (4) studies systematically investigated 3DPSP for training of cardiovascular interventions. In the largest study to date, surgeons (n=50) evaluated the quality of the models

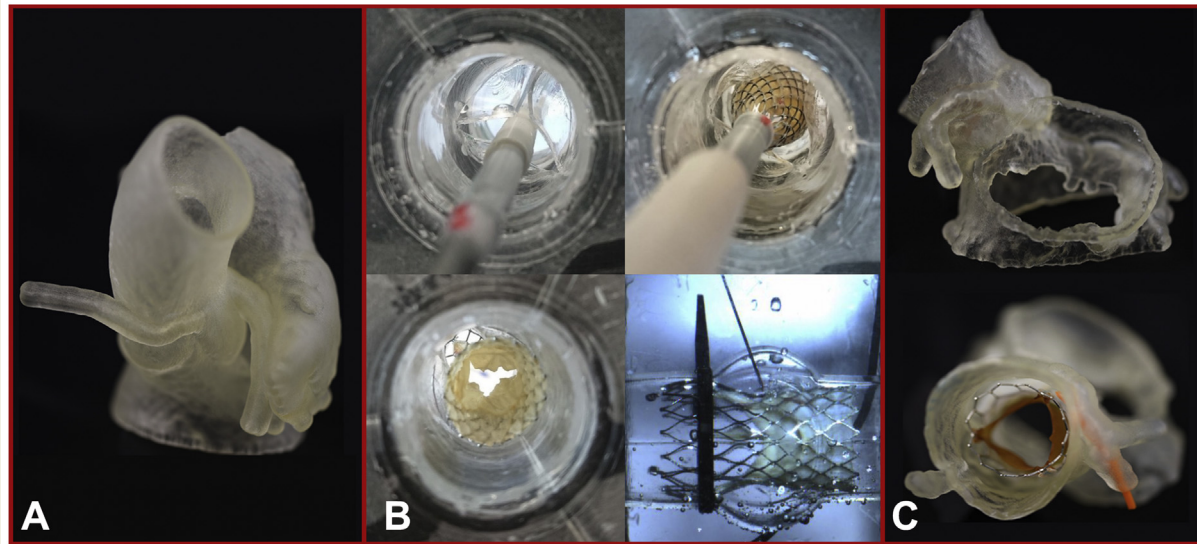


Figure 3 Selected 3DPSP used for the planning of cardiovascular interventions. (A) CCT images of a patient with coronary anomaly translated into a 3D printed phantom (compliant PolyJet 3DPSP) for planning of complex percutaneous coronary artery intervention. (B) Silicone casted aortic root model made from a fused deposition modelling negative used for simulated transcatheter aortic valve implantation and postprocedural testing of paravalvular leakage with dye injection. (C) Compliant multi-material printed PolyJet 3DPSP aortic root translated from CCT imaging for planning transcatheter aortic valve implantation. Abbreviations: 3DPSP, three-dimensional printed patient-specific phantom; CCT, cardiac computed tomography.

as acceptable (88%) and agreed that the model provided necessary information on the pathology (>85%). However, consistency and elasticity of the materials, especially of valves was mostly rated as different to human tissue [56]. Repetitive training on a 3DPSP led to shorter operation time in a simulated ventricular septum defect (VSD)-closure [57], arterial switch procedure [58], and various other CHD interventions [59].

Other Interventions

Other applications of 3DPSP in cardiovascular interventions have been described in case reports and case series only. Four (4) articles described cumulative seven 3DPSP in coronary artery interventions and evaluated them positively with high impact on decision-making [60–63]. Furthermore, 3DPSP were evaluated as helpful in the planning of adult cardiothoracic surgery [64], post-infarct VSD [65], cardiac resynchronisation device lead implantation [66], or the treatment of complex cardiac fistulae [67]. Other case reports and case series described the emerging role of 3DPSP in left ventricular pseudoaneurysm [68–70] and aneurysm of congenital origin [71]. Successful planning of valve interventions others than CHD, TAVI, and mitral valve repair/replacement (MVR) on 3DPSP were described during Ozaki repairs of the aortic valve [72], tricuspid valve-in-valve replacement [73], surgical tricuspid valve repair [74], and transcatheter tricuspid valve repair by MitraClip (Abbott, Menlo Park, CA, USA) implantation [75]. In the setting of surgical aortic valve replacement (SAVR), 3DPSP was used

to plan surgery after previous coronary artery bypass graft [76], or transcatheter closure of paravalvular regurgitation after SAVR [77,78]. Moreover, 3DPSP can be used to simulate left ventricular assist devices implantation [79], and ease left ventricular inflow cannula placement with the help of a 3D printed exoskeleton [80].

Meta-Analysis on the Impact of 3DPSP on Intervention Time

Seven (7) studies reported data about intervention times after 3DPSP application compared to controls without 3DPSP use. One (1) study [11] provided only mean and interquartile range of procedural times and hence was not eligible for inclusion. Among the remaining six studies (Table 2), three investigated 3DPSP in LAA occlusion [19,22,24] and three in surgery due to CHD [16–18]. Taking into account heterogeneity between the settings and the range of intervention times we forego from determining a weighted mean difference and analysed data by the combined effect size instead. Including these studies into a random-effects model, we found a significant association between the use of 3DPSP and a reduction in the intervention time (Cohen's $d=0.54$; 95% confidence interval 0.13–0.95; $p=0.001$, I^2 53.3%) (Figure 4).

Discussion

The salient findings of the present analysis can be summarised as follows (Figure 5). There has been increasing interest to apply 3DPSP to cardiovascular interventions during the

Table 2 Studies included into meta-analysis.

Authors	Y	Setting	N		Control arm imaging	Mean intervention time (min±SD)		Mean Difference (min)
			3DPSP	Control		3DPSP	Control	
Zhao et al. [18]	2018	Surgical repair of double outlet right ventricle	8	17	CCT and echocardiography	251.7±35.8	285.1±83.4	-33.4
Obasare et al. [22]	2018	LAA occlusion	13	9	2D TOE	70±20	107±53	-37
Ryan et al. [17]	2018	Surgery due to complex CHD	33	113	CMR or CCT	220±111	229.3±102	-9.3
Han et al. [16]	2019	Surgery due to complex CHD	6	6	CCT	256.3±49.5	304.3±102.4	-48
Fan et al. [24]	2019	LAA occlusion	32	72	3D TOE	41.7±7.2	73.7±37.9	-32
Li et al. [26]	2017	LAA occlusion	21	21	CCT and TOE	96.4±12.5	101.2±13.6	-4.8

Abbreviations: 3DPSP, three-dimensional printed patient specific phantom; CCT, cardiac computed tomography; CHD, congenital heart disease; CMR, cardiac magnet resonance imaging; LAA, left atrial appendage; TOE, transoesophageal echocardiography.

last decade, as indicated by a large and increasing number of studies since 2017. All reports consistently evaluated 3DPSP as helpful and enhancing in the planning and guiding of cardiovascular interventions, however no effect on clinical endpoints has been shown. Comparative studies indicate shorter procedure- and fluoroscopy times if the intervention is trained, planned, or guided by 3DPSP. This observation is confirmed by our meta-analysis with regard to intervention time. Only one RCT exists to date, which supports the use of 3DPSP in the setting of LAA closure, confirming previous findings in terms of a decline in radiation exposure.

Despite these encouraging findings, several limitations of 3DPSP require attention. Most studies were of descriptive and observational character and no prospective study exists that included more than 100 patients. No study demonstrated an effect on clinical outcomes including mortality, need for re-intervention, or hospitalisations. 3DPSP can only depict information that was assessed by the imaging

modality they are derived from. Hence, the quality of the image acquisition directly affects the anatomic accuracy of 3DPSP, and limits the gain of knowledge they might provide when compared to imaging data alone and virtual 3D models. Poor imitation of tissue characteristics is another important limitation, especially in the setting of direct printing techniques using rigid materials [81]. Depicting of deformations within the cardiac cycle as well as of cardiac valves is often lacking, particularly in single-material models [56]. Furthermore, availability of high-quality 3D printers is limited [82]. High costs for 3D printing, but also for finalised commercially available models, might be a deterrent, in particular for complex multi-material models that might be up to USD\$2,500 [83]. Quantification and generalisation of total cost is challenging since most 3D prints are conducted in the research environment in which a quantification of costs is often not possible and also vary greatly due to different requirements on the finalised models and the

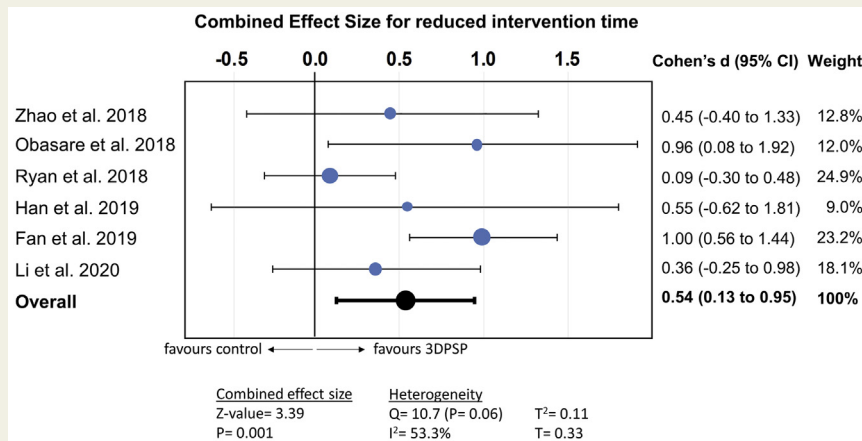


Figure 4 Forest plot for combined effect size on a reduction of intervention time with three-dimensional printed patient-specific phantom (3DPSP).

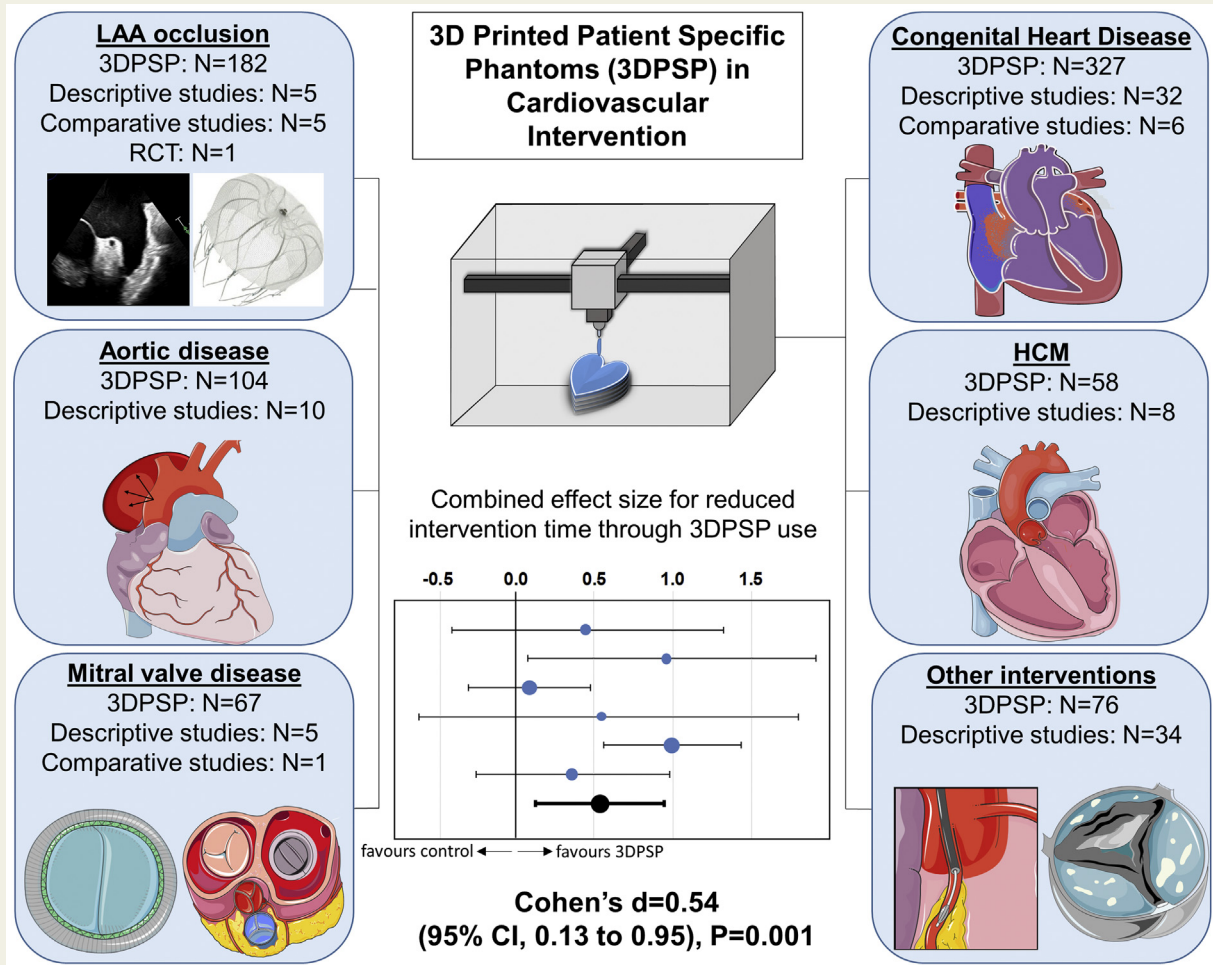


Figure 5 Abstract Figure—current applications of 3DPSP. Current applications of prospectively used 3D printed patient-specific phantoms (3DPSP) in cardiovascular intervention. Abbreviations: HCM, hypertrophic cardiomyopathy; LAA, left atrial appendage. (modified from freely available Servier Medical Art templates, smart.servier.com)

experience of the printing team (going along with the time required for printing). Costs for buying 3D printers and segmentation software and also personal costs are the main determinants in the calculation, whereas in comparison, clearly definable costs for printing materials are often negligible. However, also low-cost printed heart models have proven to show excellent correlation to anatomical structures [84].

Irrespective of these limitations, the reviewed studies demonstrate the technical feasibility of 3D printing to plan and guide cardiovascular interventions. Two-dimensional visualisation of 3D models on a screen cannot provide the same information and ease of orientation to understand complex anatomic relationships like a printed model of high quality [85]. Moreover, the opportunity for tactile feedback makes 3DPSP an accessible tool in clinical decision-making in a user-friendly fashion. Becoming familiar with patient-specific conditions in a training or planning process on a 3DPSP prior to intervention speeds up interventional

procedures. This might especially apply to interventions with highly variable anatomic structures such as the LAA or in the setting of CHD. The reduction of mechanical ventilation time, aortic cross-clamp time, as well as of fluoroscopy time, and dose might favourably impact on patient outcomes. 3DPSP can be derived from clinically indicated standard imaging not going along with longer scanning time or increased radiation exposure, hence no potential harm is expected for patients. Although the advantage of 3DPSP is difficult to measure and remains subjective in most cases, we conclusively see the strengths of 3DPSP in I. the simulation of the individual patient anatomy prior cardiovascular intervention thereby improving outcomes and providing safety (i.e., prevention of device embolisation in LAA- or valve interventions or visualisation of rare anatomy in CHD prior surgery); II. device selection and modification (i.e., choosing the optimal type and optimal size of LAA-occluders or prosthetic valves in order to prevent paravalvular leak or size mismatch, or the modification of aortic stent grafts); and

III. education and training of fellows in cardiovascular interventions.

Limitations of This Review and Meta-Analysis

The findings of this review should be interpreted in light of several limitations that go beyond the limitations of the individual studies included. Although search terms tried to cover the full spectrum of research on 3DPSP in cardiovascular intervention, rare fields of applications may have been missed by our keywords search. Exclusion of studies that retrospectively investigated 3DPSP in cardiovascular intervention was necessary to reduce the large number of studies meeting our inclusion criteria but might result in missing important findings. Furthermore, a possible publication bias should also be considered. Cases in which manufacturing 3DPSP in an adequate quality has failed or the models were not considered to be helpful might not be published or did not reach significance for acceptance in journals. Our meta-analysis is based on only six studies with a small total number of patients (n=113 3DPSP vs 238 controls) in different settings (LAA closure and surgery due to CHD), hence heterogeneity should be taken into account and reduces generalisability of our findings to other cardiovascular interventions guided by 3DPSP. Local expertise and volume in imaging and the intervention, as well as operator's experience might bias our findings. Although $I^2=53.3\%$ referred to moderate heterogeneity, Cochran's Q was not significant, indicating that the association of 3DPS to reduced intervention time was consistent across studies.

Conclusions

Three-dimensional patient-specific phantoms is helpful to plan, train, and guide interventions in patients with complex cardiovascular anatomy. Benefits for patients include reduced intervention time, with the potential to lower radiation exposure and shorten mechanical ventilation. More evidence is needed to warrant adoption of 3DPSP into routine clinical practice although future applications are vast.

Conflicts of Interest

Dr. Windecker has received research grants to his institution from Abbott, Amgen, Boston, Biotronik, and St. Jude Medical, he has received no speaker fee. Dr. Pilgrim has received research grants to his institution from Edwards Lifesciences, Symetis, and Biotronik; has received speaker fees from Boston Scientific; and has received reimbursement for travel expenses from St. Jude Medical. Dr. Praz is a consultant for Edwards Lifesciences. Dr. Gräni received research funding from Swiss National Science Foundation and Innosuisse outside of the submitted work. Further Dr. Gräni received travel fees from Amgen and Bayer outside of the submitted work. All other authors report no conflicts.

References

- [1] Levesque JN, Shah A, Ekhtiari S, Yan JR, Thornley P, Williams DS. Three-dimensional printing in orthopaedic surgery: a scoping review. *EFORT Open Rev.* 2020;5:430–41.
- [2] Vukicevic M, Mosadegh B, Min JK, Little SH. Cardiac 3D printing and its future directions. *JACC Cardiovasc Imaging.* 2017;10:171–84.
- [3] Noecker AM, Chen JF, Zhou Q, White RD, Kopcak MW, Arruda MJ, et al. Development of patient-specific three-dimensional pediatric cardiac models. *ASAIO J.* 2006;52:349–53.
- [4] Suurmond R, van Rhee H, Hak T. Introduction, comparison, and validation of Meta-Essentials: a free and simple tool for meta-analysis. *Res Synth Methods.* 2017;8:537–53.
- [5] Hozo SP, Djulbegovic B, Hozo I. Estimating the mean and variance from the median, range, and the size of a sample. *BMC Med Res Methodol.* 2005;5:13.
- [6] Higgins JP, Thompson SG. Quantifying heterogeneity in a meta-analysis. *Stat Med.* 2002;21:1539–58.
- [7] Liberati A, Altman DG, Tetzlaff J, Mulrow C, Gotzsche PC, Ioannidis JP, et al. The PRISMA statement for reporting systematic reviews and meta-analyses of studies that evaluate health care interventions: explanation and elaboration. *J Clin Epidemiol.* 2009;62:e1–34.
- [8] Mottl-Link S, Hübner M, Kühne T, Rietdorf U, Krueger JJ, Schnackenburg B, et al. Physical models aiding in complex congenital heart surgery. *Ann Thorac Surg.* 2008;86:273–7.
- [9] Valverde I, Gomez G, Coserria JF, Suarez-Mejias C, Uribe S, Sotelo J, et al. 3D printed models for planning endovascular stenting in transverse aortic arch hypoplasia. *Catheter Cardiovasc Interv.* 2015;85:1006–12.
- [10] Wang Z, Liu Y, Xu Y, Gao C, Chen Y, Luo H. Three-dimensional printing-guided percutaneous transcatheter closure of secundum atrial septal defect with rim deficiency: first-in-human series. *Cardiol J.* 2016;23:599–603.
- [11] Matsubara D, Kataoka K, Takahashi H, Minami T, Yamagata T. A patient-specific hollow three-dimensional model for simulating percutaneous occlusion of patent ductus arteriosus. *Int Heart J.* 2019;60:100–7.
- [12] Biglino G, Capelli C, Leaver LK, Schievano S, Taylor AM, Wray J. Involving patients, families and medical staff in the evaluation of 3D printing models of congenital heart disease. *Commun Med.* 2015;12:157–69.
- [13] Biglino G, Capelli C, Wray J, Schievano S, Leaver LK, Khambadkone S, et al. 3D-manufactured patient-specific models of congenital heart defects for communication in clinical practice: feasibility and acceptability. *BMJ Open.* 2015;5:e007165.
- [14] Biglino G, Koniordou D, Gasparini M, Capelli C, Leaver LK, Khambadkone S, et al. Piloting the use of patient-specific cardiac models as a novel tool to facilitate communication during clinical consultations. *Pediatr Cardiol.* 2017;38:813–8.
- [15] Valverde I, Gomez-Ciriza G, Hussain T, Suarez-Mejias C, Velasco-Forte MN, Byrne N, et al. Three-dimensional printed models for surgical planning of complex congenital heart defects: an international multicentre study. *Eur J Cardiothorac Surg.* 2017;52:1139–48.
- [16] Han F, Co-Vu J, Lopez-Colon D, Forder J, Bleiweis M, Reyes K, et al. Impact of 3D printouts in optimizing surgical results for complex congenital heart disease. *World J Pediatr Congenit Heart Surg.* 2019;10:533–8.
- [17] Ryan J, Plasencia J, Richardson R, Velez D, Nigro JJ, Pophal S, et al. 3D printing for congenital heart disease: a single site's initial three-year experience. *3D Print Med.* 2018;4:10.
- [18] Zhao L, Zhou S, Fan T, Li B, Liang W, Dong H. Three-dimensional printing enhances preparation for repair of double outlet right ventricular surgery. *J Card Surg.* 2018;33:24–7.
- [19] Li P, Fang F, Qiu X, Xu N, Wang Y, Ouyang WB, et al. Personalized three-dimensional printing and echoguided procedure facilitate single device closure for multiple atrial septal defects. *J Interv Cardiol.* 2020;2020:1751025.
- [20] Liu P, Liu R, Zhang Y, Liu Y, Tang X, Cheng Y. The value of 3D printing models of left atrial appendage using real-time 3D transesophageal echocardiographic data in left atrial appendage occlusion: applications toward an era of truly personalized medicine. *Cardiology.* 2016;135:255–61.
- [21] Hell MM, Achenbach S, Yoo IS, Franke J, Blachutzki F, Roether J, et al. 3D printing for sizing left atrial appendage closure device: head-to-head

- comparison with computed tomography and transoesophageal echocardiography. *EuroIntervention*. 2017;13:1234–41.
- [22] Obasare E, Mainigi SK, Morris DL, Slipczuk L, Goykhman I, Friend E, et al. CT based 3D printing is superior to transesophageal echocardiography for pre-procedure planning in left atrial appendage device closure. *Int J Cardiovasc Imaging*. 2018;34:821–31.
- [23] Hachulla AL, Noble S, Guglielmi G, Agulleiro D, Müller H, Vallée JP. 3D-printed heart model to guide LAA closure: useful in clinical practice? *Eur Radiol*. 2019;29:251–8.
- [24] Fan Y, Yang F, Cheung GS, Chan AK, Wang DD, Lam YY, et al. Device sizing guided by echocardiography-based three-dimensional printing is associated with superior outcome after percutaneous left atrial appendage occlusion. *J Am Soc Echocardiogr*. 2019;32:708–719.e1.
- [25] Ciobotaru V, Combes N, Martin CA, Marijon E, Maupas E, Bortone A, et al. Left atrial appendage occlusion simulation based on three-dimensional printing: new insights into outcome and technique. *EuroIntervention*. 2018;14:176–84.
- [26] Li H, Qingyao Bingshen, Shu M, Lizhong, Wang X, et al. Application of 3D printing technology to left atrial appendage occlusion. *Int J Cardiol*. 2017;231:258–63.
- [27] Tam MD, Latham TR, Lewis M, Khanna K, Zaman A, Parker M, et al. A pilot study assessing the impact of 3-d printed models of aortic aneurysms on management decisions in EVAR planning. *Vasc Endovascular Surg*. 2016;50:4–9.
- [28] Torres IO, De Luccia N. A simulator for training in endovascular aneurysm repair: The use of three dimensional printers. *Eur J Vasc Endovascular Surg*. 2017;54:247–53.
- [29] Marone EM, Auricchio F, Marconi S, Conti M, Rinaldi LF, Pietrabissa A, et al. Effectiveness of 3D printed models in the treatment of complex aortic diseases. *J Cardiovasc Surg*. 2018;59:699–706.
- [30] Gomes EN, Dias RR, Rocha BA, Santiago JAD, Dinato FJS, Saadi EK, et al. Use of 3D printing in preoperative planning and training for aortic endovascular repair and aortic valve disease. *Braz J Cardiovasc Surg*. 2018;33:490–5.
- [31] Tong YH, Yu T, Zhou MJ, Liu C, Zhou M, Jiang Q, et al. Use of 3D printing to guide creation of fenestrations in physician-modified stent-grafts for treatment of thoracoabdominal aortic disease. *J Endovasc Ther*. 2020;27:385–93.
- [32] Izzo RL, O'Hara RP, Iyer V, Hansen R, Meess KM, Nagesh SVS, et al. 3D printed cardiac phantom for procedural planning of a transcatheter native mitral valve replacement. *Proc SPIE Int Soc Opt Eng*. 2016;9789:978908.
- [33] El Sabbagh A, Eleid MF, Matsumoto JM, Anavekar NS, Al-Hijji MA, Said SM, et al. Three-dimensional prototyping for procedural simulation of transcatheter mitral valve replacement in patients with mitral annular calcification. *Catheter Cardiovasc Interv*. 2018;92:E537–49.
- [34] Wang H, Song H, Yang Y, Wu Z, Hu R, Chen J, et al. Morphology display and hemodynamic testing using 3D printing may aid in the prediction of LVOT obstruction after mitral valve replacement. *Int J Cardiol*. 2021;331:296–306.
- [35] Hermsen JL, Burke TM, Seslar SP, Owens DS, Ripley BA, Mokadam NA, et al. Scan, plan, print, practice, perform: development and use of a patient-specific 3-dimensional printed model in adult cardiac surgery. *J Thorac Cardiovasc Surg*. 2017;153:132–40.
- [36] Yang DH, Kang JW, Kim N, Song JK, Lee JW, Lim TH. Myocardial 3-dimensional printing for septal myectomy guidance in a patient with obstructive hypertrophic cardiomyopathy. *Circulation*. 2015;132:300–1.
- [37] Hamatani Y, Amaki M, Kanzaki H, Yamashita K, Nakashima Y, Shibata A, et al. Contrast-enhanced computed tomography with myocardial three-dimensional printing can guide treatment in symptomatic hypertrophic obstructive cardiomyopathy. *ESC Heart Fail*. 2017;4:665–9.
- [38] Guo HC, Wang Y, Dai J, Ren CW, Li JH, Lai YQ. Application of 3D printing in the surgical planning of hypertrophic obstructive cardiomyopathy and physician-patient communication: a preliminary study. *J Thorac Dis*. 2018;10:867–73.
- [39] Andrushchuk U, Adzintsov V, Nevyglas A, Model H. Virtual and real septal myectomy using 3-dimensional printed models. *Interact Cardiovasc Thorac Surg*. 2018;26:881–2.
- [40] Wang Y, Guo H, Wang S, Lai Y. Effectiveness of a patient-specific 3-dimensional printed model in septal myectomy of hypertrophic cardiomyopathy. *Pak J Med Sci*. 2020;36:1678–82.
- [41] Andrushchuk U, Adzintsov V, Niavyhlyas A, Model H, Ostrovsky Y. Early results of optimal septal myectomy using 3-dimensional printed models. *Kardiologicheskii Zhurnal*. 2019;16:74–80.
- [42] Ripley B, Kelil T, Cheezum MK, Goncalves A, Di Carli MF, Rybicki FJ, et al. 3D printing based on cardiac CT assists anatomic visualization prior to transcatheter aortic valve replacement. *J Cardiovasc Comput Tomogr*. 2016;10:28–36.
- [43] Hosny A, Dilley JD, Kelil T, Mathur M, Dean MN, Weaver JC, et al. Pre-procedural fit-testing of TAVR valves using parametric modeling and 3D printing. *J Cardiovasc Comput Tomogr*. 2019;13:21–30.
- [44] Reiff C, Zhingre Sanchez JD, Mattison LM, Iaizzo PA, Garcia S, Raveendran G, et al. 3-dimensional printing to predict paravalvular regurgitation after transcatheter aortic valve replacement. *Catheter Cardiovasc Interv*. 2020;96:E703–10.
- [45] Qian Z, Wang K, Liu S, Zhou X, Rajagopal V, Meduri C, et al. Quantitative prediction of paravalvular leak in transcatheter aortic valve replacement based on tissue-mimicking 3d printing. *JACC Cardiovasc Imaging*. 2017;10:719–31.
- [46] Fujita T, Saito N, Minakata K, Imai M, Yamazaki K, Kimura T. Transfemoral transcatheter aortic valve implantation in the presence of a mechanical mitral valve prosthesis using a dedicated TAVI guidewire: utility of a patient-specific three-dimensional heart model. *Cardiovasc Interv Ther*. 2017;32:308–11.
- [47] Basman C, Seetharam K, Pirelli L, Kliger CA. Transcatheter aortic valve-in-valve-in-valve implantation with three-dimensional printing guidance: a case report. *J Card Surg*. 2020;35:1676–80.
- [48] Hatoum H, Lilly SM, Crestanello J, Dasi LP. A case study on implantation strategies to mitigate coronary obstruction in a patient receiving transcatheter aortic valve replacement. *J Biomech*. 2019;89:115–8.
- [49] Bussani R, Castrichini M, Restivo L, Fabris E, Porcari A, Ferro F, et al. Cardiac tumors: diagnosis, prognosis, and treatment. *Curr Cardiol Rep*. 2020;22:169.
- [50] Riggs KW, Dsouza G, Broderick JT, Moore RA, Morales DLS. 3D-printed models optimize preoperative planning for pediatric cardiac tumor debulking. *Transl Pediatr*. 2018;7:196–202.
- [51] Son KH, Kim KW, Ahn CB, Choi CH, Park KY, Park CH, et al. Surgical planning by 3d printing for primary cardiac schwannoma resection. *Yonsei Med J*. 2015;56:1735–7.
- [52] Ali M, Pham AN, Pooley RA, Rojas CA, Mergo PJ, Pham SM. Three-dimensional printing facilitates surgical planning for resection of an atypical cardiac myxoma. *J Card Surg*. 2020;35:2863–5.
- [53] Schmauss D, Gerber N, Sodian R. Three-dimensional printing of models for surgical planning in patients with primary cardiac tumors. *J Thorac Cardiovasc Surg*. 2013;145:1407–8.
- [54] Jacobs S, Grunert R, Mohr FW, Falk V. 3D-imaging of cardiac structures using 3D heart models for planning in heart surgery: a preliminary study. *Interact Cardiovasc Thorac Surg*. 2008;7:6–9.
- [55] Al Jabbari O, Abu Saleh WK, Patel AP, Igo SR, Reardon MJ. Use of three-dimensional models to assist in the resection of malignant cardiac tumors. *J Card Surg*. 2016;31:581–3.
- [56] Yoo SJ, Spray T, Austin EH 3rd, Yun TJ, van Arsdell GS. Hands-on surgical training of congenital heart surgery using 3-dimensional print models. *J Thorac Cardiovasc Surg*. 2017;153:1530–40.
- [57] Nam JG, Lee W, Jeong B, Park EA, Lim JY, Kwak Y, et al. Three-dimensional printing of congenital heart disease models for cardiac surgery simulation: evaluation of surgical skill improvement among inexperienced cardiothoracic surgeons. *Korean J Radiol*. 2021;22:706–13.
- [58] Hussein N, Honjo O, Haller C, Coles JG, Hua Z, Van Arsdell G, et al. Quantitative assessment of technical performance during hands-on surgical training of the arterial switch operation using 3-dimensional printed heart models. *J Thorac Cardiovasc Surg*. 2020;160:1035–42.
- [59] Hussein N, Honjo O, Barron DJ, Haller C, Coles JG, Yoo SJ. The incorporation of hands-on surgical training in a congenital heart surgery training curriculum. *Ann Thorac Surg*. 2021;112:1672–80.
- [60] Velasco Forte MN, Byrne N, Valverde Perez I, Bell A, Gómez-Ciriza G, Krasemann T, et al. 3D printed models in patients with coronary artery fistulae: anatomical assessment and interventional planning. *EuroIntervention*. 2017;13:e1080–3.
- [61] Watanabe H, Saito N, Tatsushima S, Tazaki J, Toyota T, Imai M, et al. Patient-specific three-dimensional aortocoronary model for percutaneous coronary intervention of a totally occluded anomalous right coronary artery. *J Invasive Cardiol*. 2015;27:E139–42.
- [62] Young L, Harb SC, Puri R, Khatri J. Percutaneous coronary intervention of an anomalous coronary chronic total occlusion: the added value of three-dimensional printing. *Catheter Cardiovasc Interv*. 2020;96:330–5.
- [63] Niizeki T, Iwayama T, Kumagai Y, Ikeno E, Saito N, Kimura T. Pre-procedural planning using a three-dimensional printed model for

- percutaneous coronary intervention in an anomalous coronary artery. *Am J Case Rep.* 2020;21:e923007.
- [64] Borracci RA, Ferreira LM, Alvarez Gallesio JM, Tenorio Núñez OM, David M, Eyheremendy EP. Three-dimensional virtual and printed models for planning adult cardiovascular surgery. *Acta Cardiol.* 2021;76:534–43.
- [65] Lazkani M, Bashir F, Brady K, Pophal S, Morris M, Pershad A. Post-infarct VSD management using 3D computer printing assisted percutaneous closure. *Indian Heart J.* 2015;67:581–5.
- [66] Kanawati J, Kanawati AJ, Rowe MK, Khan H, Chan WK, Yee R. Utility of 3-D printing for cardiac resynchronization device implantation in congenital heart disease. *HeartRhythm Case Rep.* 2020;6:754–6.
- [67] Aroney N, Markham R, Putrino A, Crowhurst J, Wall D, Scalia G, et al. Three-dimensional printed cardiac fistulae: a case series. *Eur Heart J Case Rep.* 2019;3:ytz060.
- [68] Pizzuto A, Santoro G, Baldi C, Celi S, Cuman M, Anees AJ, et al. 3D model-guided transcatheter closure of left ventricular pseudoaneurysm: a case series. *J Cardiovasc Med (Hagerstown).* 2021;22:e1–7.
- [69] Mohamed E, Telila T, Osaki S, Jacobson K. Percutaneous closure of left ventricle pseudoaneurysm using 3D printed heart model for procedure planning: a novel approach. *Catheter Cardiovasc Interv.* 2019;94:874–7.
- [70] Al-Hijji MA, Guerrero M, Rihal CS, Eleid MF. Transapical percutaneous closure of rapidly expanding post-surgical left ventricular outflow tract pseudoaneurysm. *Catheter Cardiovasc Interv.* 2019;94:859–62.
- [71] Shetty I, Lachma RN, Manohar P, Rao PSM. 3D printing guided closure of submitral aneurysm-an interesting case. *Indian J Thorac Cardiovasc Surg.* 2020;36:506–8.
- [72] Shearn AIU, Ordoñez MV, Rapetto F, Caputo M, Biglino G. Rapid prototyping flexible aortic models aids sizing of valve leaflets and planning the Ozaki repair. *JACC Case Rep.* 2020;2:1137–40.
- [73] Spring AM, Pirelli L, Basman CL, Kliger CA. The importance of pre-operative imaging and 3-D printing in transcatheter tricuspid valve-in-valve replacement. *Cardiovasc Revasc Med.* 2021;28S:161–5.
- [74] Harb SC, Spiliaris N, Griffin BP, Svensson LG, Klatt RS, Bakaeen FG, et al. Surgical repair for primary tricuspid valve disease: individualized surgical planning with 3-dimensional printing. *JACC Case Rep.* 2020;2:2217–22.
- [75] Vukicevic M, Faza NN, Avenatti E, Durai PC, El-Tallawi KC, Filippini S, et al. Patient-specific 3-dimensional printed modeling of the tricuspid valve for mitralclip procedure planning. *Circulation Cardiovasc Imaging.* 2020;13:e010376.
- [76] Sodian R, Schmauss D, Markert M, Weber S, Nikolaou K, Haeberle S, et al. Three-dimensional printing creates models for surgical planning of aortic valve replacement after previous coronary bypass grafting. *Ann Thorac Surg.* 2008;85:2105–8.
- [77] ElGuindy A, Osman A, Elborae A, Nagy M. The utility of 3D printed models in complex percutaneous paravalvular leak interventions. *Glob Cardiol Sci Pract.* 2020;2020:e202027.
- [78] Motwani M, Burley O, Luckie M, Cunningham C, Pisaniello AD, Hasan R, et al. 3D-printing assisted closure of paravalvular leak. *J Cardiovasc Comput Tomogr.* 2020;14:e66–8.
- [79] Miller JR, Singh GK, Woodard PK, Eghtesady P, Anwar S. 3D printing for preoperative planning and surgical simulation of ventricular assist device implantation in a failing systemic right ventricle. *J Cardiovasc Comput Tomogr.* 2020;14:e172–4.
- [80] Barabás JJ, Hartyánszky I, Kocher A, Merkely B. A 3D printed exoskeleton facilitates HeartMate III inflow cannula position. *Interact Cardiovasc Thorac Surg.* 2019;29:644–6.
- [81] Hermesen JL, Yang R, Burke TM, Dardas T, Jacobs LM, Verrier ED, et al. Development of a 3-D printing-based cardiac surgical simulation curriculum to teach septal myectomy. *J Thorac Cardiovasc Surg.* 2018;156:1139–1148.e3.
- [82] Illmann CF, Hosking M, Harris KC. Utility and access to 3-dimensional printing in the context of congenital heart disease: an international physician survey study. *CJC Open.* 2020;2:207–13.
- [83] Ho DR, Luery SE, Ghosh RM, Maehara CK, Silvestro E, Whitehead KK, et al. Cardiovascular 3-d printing: value-added assessment using time-driven activity-based costing. *J Am Coll Radiol.* 2020;17:1469–74.
- [84] Lau I, Wong YH, Yeong CH, Abdul Aziz YF, Md Sari NA, Hashim SA, et al. Quantitative and qualitative comparison of low- and high-cost 3D-printed heart models. *Quant Imaging Med Surg.* 2019;9:107–14.
- [85] Sun L, Fukuda T, Tokuhara T, Yabuki N. Differences in spatial understanding between physical and virtual models. *Front Archit Res.* 2014;3:28–35.
- [86] Ngan EM, Rebeyka IM, Ross DB, Hirji M, Wolfaardt JF, Seelaus R, et al. The rapid prototyping of anatomic models in pulmonary atresia. *J Thorac Cardiovasc Surg.* 2006;132:264–9.
- [87] Sodian R, Weber S, Markert M, Rassoulain D, Kaczmarek I, Lueth TC, et al. Stereolithographic models for surgical planning in congenital heart surgery. *Ann Thorac Surg.* 2007;83:1854–7.
- [88] Sodian R, Weber S, Markert M, Loeff M, Lueth T, Weis FC, et al. Pediatric cardiac transplantation: three-dimensional printing of anatomic models for surgical planning of heart transplantation in patients with univentricular heart. *J Thorac Cardiovasc Surg.* 2008;136:1098–9.
- [89] Kim MS, Hansgen AR, Wink O, Quaipe RA, Carroll JD. Rapid prototyping: a new tool in understanding and treating structural heart disease. *Circulation.* 2008;117:2388–94.
- [90] Sodian R, Schmauss D, Schmitz C, Bigdeli A, Haeberle S, Schmoeckel M, et al. 3-dimensional printing of models to create custom-made devices for coil embolization of an anastomotic leak after aortic arch replacement. *Ann Thorac Surg.* 2009;88:974–8.
- [91] Riesenkauff E, Rietdorf U, Wolf I, Schnackenburg B, Ewert P, Huebler M, et al. The practical clinical value of three-dimensional models of complex congenitally malformed hearts. *J Thorac Cardiovasc Surg.* 2009;138:571–80.
- [92] Shiraishi I, Yamagishi M, Hamaoka K, Fukuzawa M, Yagihara T. Simulative operation on congenital heart disease using rubber-like urethane stereolithographic biomodels based on 3D datasets of multislice computed tomography. *Eur J Cardiothorac Surg.* 2010;37:302–6.
- [93] Schmauss D, Juchem G, Weber S, Gerber N, Hagl C, Sodian R. Three-dimensional printing for perioperative planning of complex aortic arch surgery. *Ann Thorac Surg.* 2014;97:2160–3.
- [94] Dankowski R, Baszko A, Sutherland M, Firek L, Kałmucki P, Wróblewska K, et al. 3D heart model printing for preparation of percutaneous structural interventions: description of the technology and case report. *Kardiol Pol.* 2014;72:546–51.
- [95] Farooqi KM, Gonzalez-Lengua C, Shenoy R, Sanz J, Nguyen K. Use of a three dimensional printed cardiac model to assess suitability for biventricular repair. *World J Pediatr Congenit Heart Surg.* 2016;7:414–6.
- [96] Otton JM, Spina R, Sulas R, Subbiah RN, Jacobs N, Muller DW, et al. Left atrial appendage closure guided by personalized 3d-printed cardiac reconstruction. *JACC Cardiovasc Interv.* 2015;8:1004–6.
- [97] Schmauss D, Haeberle S, Hagl C, Sodian R. Three-dimensional printing in cardiac surgery and interventional cardiology: a single-centre experience. *Eur J Cardiothorac Surg.* 2015;47:1044–52.
- [98] Ma XJ, Tao L, Chen X, Li W, Peng ZY, Chen Y, et al. Clinical application of three-dimensional reconstruction and rapid prototyping technology of multislice spiral computed tomography angiography for the repair of ventricular septal defect of tetralogy of Fallot. *Genet Mol Res.* 2015;14:1301–9.
- [99] Kiraly L, Tofeig M, Jha NK, Talo H. Three-dimensional printed prototypes refine the anatomy of post-modified Norwood-1 complex aortic arch obstruction and allow presurgical simulation of the repair. *Interact Cardiovasc Thorac Surg.* 2016;22:238–40.
- [100] Bharati A, Garekar S, Agarwal V, Merchant SA, Solanki N. MRA-based 3D-printed heart model-an effective tool in the pre-surgical planning of DORV. *BJR Case Rep.* 2016;2:20150436.
- [101] Pellegrino PL, Fassini G, Di Biase M, Tondo C. Left atrial appendage closure guided by 3d printed cardiac reconstruction: emerging directions and future trends. *J Cardiovasc Electrophysiol.* 2016;27:768–71.
- [102] Hossien A, Gelsomino S, Maessen J, Autschbach R. The interactive use of multi-dimensional modeling and 3d printing in preplanning of type a aortic dissection. *J Card Surg.* 2016;31:441–5.
- [103] Garekar S, Bharati A, Chokhandre M, Mali S, Trivedi B, Changela VP, et al. Clinical application and multidisciplinary assessment of three dimensional printing in double outlet right ventricle with remote ventricular septal defect. *World J Pediatr Congenit Heart Surg.* 2016;7:344–50.
- [104] Olivieri LJ, Su L, Hynes CF, Krieger A, Alfares FA, Ramakrishnan K, et al. “Just-In-Time” Simulation Training Using 3-D Printed Cardiac Models After Congenital Cardiac Surgery. *World J Pediatr Congenit Heart Surg.* 2016;7:164–8.
- [105] Benke K, Barabás JJ, Daróczy L, Sayour AA, Szilveszter B, Pólos M, et al. Routine aortic valve replacement followed by a myriad of complications: role of 3D printing in a difficult cardiac surgical case. *J Thorac Dis.* 2017;9:E1021–4.
- [106] Pluchinotta FR, Giugno L, Carminati M. Stenting complex aortic coarctation: simulation in a 3D printed model. *EuroIntervention.* 2017;13:490.

- [107] Sardari Nia P, Heuts S, Daemen J, Luyten P, Vainer J, Hoorntje J, et al. Preoperative planning with three-dimensional reconstruction of patient's anatomy, rapid prototyping and simulation for endoscopic mitral valve repair. *Interact Cardiovasc Thorac Surg.* 2017;24:163–8.
- [108] Smith ML, McGuinness J, O'Reilly MK, Nolke L, Murray JG, Jones JFX. The role of 3D printing in preoperative planning for heart transplantation in complex congenital heart disease. *Ir J Med Sci.* 2017;186:753–6.
- [109] McGovern E, Kelleher E, Snow A, Walsh K, Gadallah B, Kutty S, et al. Clinical application of three-dimensional printing to the management of complex univentricular hearts with abnormal systemic or pulmonary venous drainage. *Cardiol Young.* 2017;27:1248–56.
- [110] Vodiskar J, Kütting M, Steineseifer U, Vazquez-Jimenez JF, Sonntag SJ. Using 3D physical modeling to plan surgical corrections of complex congenital heart defects. *Thorac Cardiovasc Surgeon.* 2017;65:31–5.
- [111] Kappanayil M, Koneti NR, Kannan RR, Kottayil BP, Kumar K. Three-dimensional-printed cardiac prototypes aid surgical decision-making and preoperative planning in selected cases of complex congenital heart diseases: early experience and proof of concept in a resource-limited environment. *Ann Pediatr Cardiol.* 2017;10:117–25.
- [112] Bhatla P, Tretter JT, Ludomirsky A, Argilla M, Latson LA Jr, Chakravarti S, et al. Utility and scope of rapid prototyping in patients with complex muscular ventricular septal defects or double-outlet right ventricle: does it alter management decisions? *Pediatr Cardiol.* 2017;38:103–14.
- [113] Olejník P, Nosal M, Havran T, Furdova A, Cizmar M, Slabej M, et al. Utilisation of three-dimensional printed heart models for operative planning of complex congenital heart defects. *Kardiol Pol.* 2017;75:495–501.
- [114] Song H, Zhou Q, Zhang L, Deng Q, Wang Y, Hu B, et al. Evaluating the morphology of the left atrial appendage by a transesophageal echocardiographic 3-dimensional printed model. *Medicine (Baltimore).* 2017;96:e7865.
- [115] Goitein O, Fink N, Guetta V, Beinart R, Brodov Y, Konen E, et al. Printed MDCT 3D models for prediction of left atrial appendage (LAA) occluder device size: a feasibility study. *EuroIntervention.* 2017;13:e1076–9.
- [116] Aroney N, Putrino A, Scalia G, Walters D. 3D printed cardiac fistula: guiding percutaneous structural intervention. *Catheter Cardiovasc Interv.* 2018;92:E478–80.
- [117] Parimi M, Buelter J, Thanugundla V, Condoor S, Parkar N, Danon S, et al. Feasibility and validity of printing 3d heart models from rotational angiography. *Pediatr Cardiol.* 2018;39:653–8.
- [118] Sun X, Zhang H, Zhu K, Wang C. Patient-specific three-dimensional printing for Kommerell's diverticulum. *Int J Cardiol.* 2018;255:184–7.
- [119] Hoashi T, Ichikawa H, Nakata T, Shimada M, Ozawa H, Higashida A, et al. Utility of a super-flexible three-dimensional printed heart model in congenital heart surgery. *Interact Cardiovasc Thorac Surg.* 2018;27:749–55.
- [120] Brun H, Bugge RAB, Suther LKR, Birkeland S, Kumar R, Pelanis E, et al. Mixed reality holograms for heart surgery planning: first user experience in congenital heart disease. *Eur Heart J Cardiovasc Imaging.* 2019;20:883–8.
- [121] Xu J, Tian Y, Yin J, Wang J, Xu W, Shi Z, et al. Utility of three-dimensional printing in preoperative planning for children with anomalous pulmonary venous connection: a single center experience. *Quant Imaging Med Surg.* 2019;9:1804–14.
- [122] Xu JJ, Luo YJ, Wang JH, Xu WZ, Shi Z, Fu JZ, et al. Patient-specific three-dimensional printed heart models benefit preoperative planning for complex congenital heart disease. *World J Pediatr.* 2019;15:246–54.
- [123] Alabbady AM, Sattur S, Bauch TD, Harjai KJ. Aorto-right ventricular fistula and paravalvular leak after transcatheter aortic valve implantation. *JACC Case Rep.* 2019;1:859–64.
- [124] He L, Cheng GS, Du YJ, Zhang YS. Feasibility of device closure for multiple atrial septal defects with an inferior sinus venosus defect: procedural planning using three-dimensional printed models. *Heart Lung Circ.* 2020;29:914–20.
- [125] Perens G, Chyu J, McHenry K, Yoshida T, Finn JP. Three-dimensional congenital heart models created with free software and a desktop printer: assessment of accuracy, technical aspects, and clinical use. *World J Pediatr Congenit Heart Surg.* 2020;11:797–801.
- [126] Kim W, Lim M, Jang YJ, Koo HJ, Kang JW, Jung SH, et al. Novel resectable myocardial model using hybrid three-dimensional printing and silicone molding for mock myectomy for apical hypertrophic cardiomyopathy. *Korean J Radiol.* 2021;22:1054–65.
- [127] Cen J, Liufu R, Wen S, Qiu H, Liu X, Chen X, et al. Three-dimensional printing, virtual reality and mixed reality for pulmonary atresia: early surgical outcomes evaluation. *Heart Lung Circ.* 2021;30:296–302.