

# The golden jackal (*Canis aureus*): A new host for *Echinococcus multilocularis* and *Trichinella britovi* in Switzerland<sup>#</sup>

C.F. Frey<sup>1</sup>, W.U. Basso<sup>1</sup>, S. Zürcher-Giovannini<sup>2</sup>, I. Marti<sup>2</sup>, S. Borel<sup>2</sup>, S. Guthruff<sup>2</sup>, D. Gliga<sup>1</sup>, B. Lundström-Stadelmann<sup>1</sup>, F.C. Origgi<sup>2§</sup>, M.-P. Ryser-Degiorgis<sup>2</sup>

<sup>1</sup>Institute of Parasitology, Department of Infectious Diseases and Pathobiology, Vetsuisse Faculty, University of Bern, Switzerland; <sup>2</sup>Institute for Fish and Wildlife Health, Department of Infectious Diseases and Pathobiology, Vetsuisse Faculty, University of Bern, Switzerland; <sup>§</sup>Current affiliation: Institute of Animal Pathology, Department of Infectious Diseases and Pathobiology, Vetsuisse Faculty, University of Bern, Switzerland

## Der Goldschakal (*Canis aureus*): Ein neuer Wirt für *Echinococcus multilocularis* und *Trichinella britovi* in der Schweiz

Der Goldschakal (*Canis aureus*) ist eine neue Wildkanidenart in der Schweiz, deren Verbreitung offiziell überwacht wird. Alle toten Tiere werden einer pathologischen Untersuchung unterzogen, um Basisdaten zur Gesundheit der Tierart zu sammeln. Dabei wird auch auf Parasiten untersucht, insbesondere auf meldepflichtige, zoonotische Parasiten wie *Trichinella* spp. oder *Echinococcus* spp. Zwischen 2016 und 2021 wurden fünf tote Goldschakale aus vier Kantonen aufgefunden. In einem Fall wurden nur fixierte Organe zugeschiedt, was eine parasitologische Untersuchung verunmöglichte. Alle während der Sektion oder in den koprologischen Untersuchungen gefundenen Parasitenstadien wurden morphologisch bestimmt. Taeniiden-Eier und adulte Bandwürmer wurden zudem molekularbiologisch identifiziert. Zusätzlich wurde von jedem Tier Zungen- und Zwerchfellmuskulatur mittels künstlicher Verdauung auf *Trichinella* spp. untersucht und dabei gefundene Larven mittels Multiplex-PCR identifiziert. Parasitologisch wurden bei einem Tier Hakenwurmeier, bei einem anderen sowohl adulte Würmer wie auch Eier von *Echinococcus multilocularis* und bei einem Fall keine Parasiten gefunden. Bei einem weiteren Fall wurden Eier von *E. multilocularis* und *Toxocara canis*, sowie Sporozysten von *Sarcocystis* sp. beobachtet. In der Muskulatur desselben Tieres wurden Larven von *T. britovi* nachgewiesen. Das Programm zur Gesundheitsüberwachung von geschützten Karnivoren erlaubte es, den Goldschakal als weiteren Wirt für die endemischen Parasiten *E. multilocularis* und *T. britovi* zu identifizieren. JägerInnen, LandwirtInnen und andere Personen, welche in Kontakt mit Goldschakalen kommen könnten, sollten sich diesem Gesundheitsrisiko bewusst sein und sowohl Kot wie auch Tierkörper mit Vorsicht behandeln.

**Schlüsselwörter:** *Canis aureus*, Gesundheitsüberwachung, Parasit, Wildtier, Zoonose

## Summary

The golden jackal (*Canis aureus*) is a wild canid new to Switzerland. It is an officially monitored species and all deceased individuals are submitted for post-mortem examination to collect baseline health data. This includes parasitological examinations, with an emphasis on zoonotic, reportable infections, such as those caused by *Trichinella* spp. or *Echinococcus* spp. From 2016 to 2021, five golden jackals originating from four Swiss cantons were submitted for full post-mortem examination. In one case only organ samples were available, and therefore parasitological examination was not possible. Parasite stages recovered during necropsy, as well as by routine coproscopical techniques, were morphologically identified. Taeniid eggs and adult tapeworms were processed for molecular species identification. Additionally, tongue and diaphragm were analysed for *Trichinella* spp. by the artificial digestion technique followed by multiplex-PCR in positive cases. Of the four jackals investigated for parasites, hookworm eggs were detected in one animal, both adult worms and eggs of *Echinococcus multilocularis* were present in another case, and one animal was free of parasites. Eggs of *E. multilocularis* as well as eggs of *Toxocara canis* and sporocysts of *Sarcocystis* sp. were detected in the intestinal content, and *Trichinella britovi* larvae were found in the muscle samples of the last case. The health monitoring programme in place for protected carnivores in Switzerland allowed us to add the golden jackal to the list of hosts for the endemic zoonotic parasites *E. multilocularis* and *T. britovi* in this country. Hunters, farmers, and other persons who could come in contact with golden jackals should be aware of the associated health risk and handle faeces and carcasses with caution.

**Keywords:** *Canis aureus*, health monitoring, parasites, wildlife, zoonosis

<https://doi.org/10.17236/sat00338>

Eingereicht: 07.07.2021  
Angenommen: 25.11.2021


<sup>#</sup>Prof. Dr. med. vet  
Peter Deplazes zur  
Pensionierung gewidmet.

The golden jackal (*Canis aureus*): A new host for *Echinococcus multilocularis* and *Trichinella britovi* in Switzerland

C. Frey et al.

## Introduction

The golden jackal (*Canis aureus*) is a wild canid native to Eurasia, with size and coat colour in between that of the red fox (*Vulpes vulpes*) and the grey wolf (*Canis lupus*) (Figure 1). In recent years, this species has been experiencing a rapid large-scale geographic expansion from Southeast Europe and the Caucasus to the Balkan and more recently almost all over Europe.<sup>22, 31, 35</sup> A single jackal was first documented by camera trapping in Switzerland in 2011. Since then, further sporadic observations of individual jackals have been recorded.<sup>23</sup> Jackals are protected under the Swiss law and an officially mon-



**Figure 1:** Phototrap pictures taken at the same site in Switzerland. From top to bottom: grey wolf (*Canis lupus*), golden jackal (*Canis aureus*), red fox (*Vulpes vulpes*). Copyright: Foundation KORA.

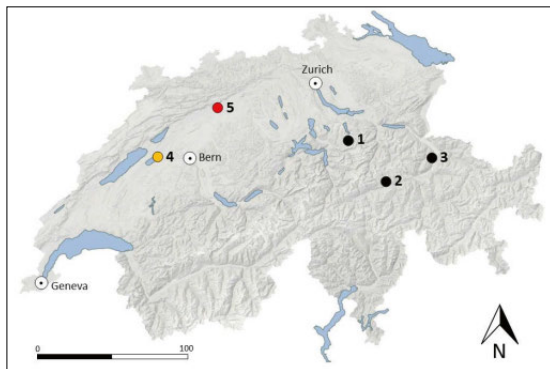
itored species in Switzerland. Therefore, all deceased animals are submitted to the Institute for Fish and Wildlife Health (FIWI) in Bern for post-mortem examination, with the aim to collect baseline data on the health of this large carnivore. Examination is carried out according to a standardized protocol for protected wild mammal species in Switzerland, including the documentation of morphological features, in-depth pathological examination, and extensive sample collection.<sup>32</sup> The procedure includes an assessment of parasites, with an emphasis on zoonotic, reportable parasites such as *Trichinella* spp. and *Echinococcus* spp.

Former investigations have shown that golden jackals harbour many different parasites, mostly species shared with domestic dogs.<sup>18</sup> In Europe, they have been identified as final hosts for *Echinococcus granulosus* s.l. in Hungary, Bulgaria, and Italy, and for *E. multilocularis* in Hungary, Serbia, Croatia, and Austria.<sup>1, 2, 18, 24, 34, 37</sup> They have also been identified as hosts for *Trichinella* spp. in Bulgaria, Romania, former Yugoslavia, and Croatia.<sup>18</sup> Species identification revealed them to be hosts for *T. britovi* in Romania, Serbia, and Latvia, for *T. spiralis* in Serbia, Bulgaria, and Hungary, and for *T. nativa* in Latvia.<sup>3, 4, 37, 42</sup>

*Echinococcus multilocularis* is highly endemic in Switzerland. The red fox is the most important definitive host with regional prevalences of up to 60% and arvicolid rodents as intermediate hosts.<sup>7, 19, 28, 39</sup> Domestic dogs and cats were also identified as definitive hosts in Switzerland, with prevalence ranging from 0.3 to 7% in dogs and from 0.4 to 3.0% in cats.<sup>5, 6, 17</sup> Besides, cases of alveolar echinococcosis after infection with *E. multilocularis* eggs were reported locally in humans and in some animal species such as domestic dogs, non-human primates in captivity, pigs, and Eurasian beavers (*Castor fiber*).<sup>7, 10, 11, 14, 17, 21, 25, 30</sup>

Further recorded definitive hosts of *E. multilocularis* in Europe include the arctic fox (*Vulpes lagopus*), the raccoon dog (*Nyctereutes procyonoides*), the grey wolf, and the wild cat (*Felis silvestris*).<sup>27, 29</sup> Domestic and wild cats mainly harbour small numbers of mostly non-gravid worms, playing only a minor role in the maintenance of the parasite's life cycle.<sup>27, 29</sup>

With regard to *Trichinella* spp., *T. britovi* is regularly found in wild carnivores in Switzerland, with prevalences of 1.6% in red fox and about 27% in lynx (*Lynx lynx*).<sup>13</sup> Moreover, in 2020 *T. spiralis* was found in a lynx, indicating that also this *Trichinella* species occurs in Switzerland (unpublished author data). The systematic post-mortem examination of protected large carnivores such as wolf, brown bear (*Ursus arctos*), lynx and golden jackal allows for the rapid detection of new host species



**Figure 2:** Map of Switzerland with relief (shades of grey), main lakes (blue areas), and the cities of Geneva, Bern and Zurich, depicting the geographical origin of five golden jackals (cases 1–5) analysed post-mortem at the University of Bern, 2016–2021. Orange: positive for *Echinococcus multilocularis*. Red: positive for both *E. multilocularis* and *Trichinella britovi*.

for endemic parasites, but also for parasites that might be introduced by newly occurring species.

Here, we report the first discovery of *E. multilocularis* and *T. britovi* in golden jackals in Switzerland.

## Materials & Methods

### Animals

Since the first occurrence of the species in Switzerland in 2011, four golden jackal carcasses and organ samples of a fifth animal (all adult males) were submitted for analysis. Details concerning the submission year, geographical origin and cause of death are summarized in Table 1 and Figure 2.

### Parasitological examinations

The gastro-intestinal tract of the four entire carcasses was inspected for the presence of parasites at necropsy, and routine histopathology was carried out on the major organs (heart, lungs, liver, spleen, kidney, stomach, intestine, lymph node, reproductive organ and skeletal muscle) of all the investigated animals. Subsequently, a combined sedimentation-flotation method was used to examine the intestinal content more thoroughly.<sup>8</sup> Parasite stages recovered by these techniques were identified based on morphological criteria.<sup>8</sup> Furthermore, muscle samples of tongue and diaphragm (> 10 g per animal) were analysed by the artificial digestion method for the presence of *Trichinella* spp. larvae.<sup>12, 15</sup>

### Molecular analyses

DNA was extracted from taeniid eggs and *Trichinella* spp. larvae with the Quick-DNA Fecal/Soil Microbe Miniprep kit (Zymo Research, Irvine, USA) and the DNeasy blood and tissue kit (QIAGEN, Hilden, Germany), re-

spectively, following the manufacturer's instructions. For molecular species-identification of tapeworm DNA, a multiplex PCR discriminating between *E. granulosus* s.l., *E. multilocularis* and other cestodes was performed according to Trachsel et al.<sup>40</sup> In brief, DNA of the NADH dehydrogenase subunit 1 of *E. multilocularis* was specifically detected by the primer pair Cest1 (5'-TGCTGATTTGTAAAGTTAGTGATC) and Cest2 (5'-CATAAATCAATGAAACAACAACAAG) resulting in a 395 bp amplification product; primers Cest3 (5'-YGAYTCTTTTTAGGGGAAGGTGTG) and Cest5 (5'-GCGGTGTGTACMTGAGCTAAAC) targeted the DNA of the small subunit of ribosomal RNA (rrnS) of *Taenia* spp. and some other cestodes resulting in a 267 bp amplification product; the rrnS region of *E. granulosus* s.l. was targeted by primers Cest4 (5'-GTTTTTGTGTGTTACATTAATAAGGGTG) and Cest5, resulting in a 117 bp amplification product. *Trichinella* spp. was also identified using a multiplex PCR.<sup>41</sup> Briefly, the PCR reaction contained a total of ten primer pairs: one primer pair targeting the expansion segment V (ESV; primers 5'-GTTCCATGTGAACAGCAGT and 5'-CGAAAA-CATACGACAACACTGC), two primer pairs targeting the ITS-1 region (5'-GCTACATCCTTTTGTATCTGTT and 5'-AGACACAATATCAACCACAGTACA; 5'-GCGGAAGGATCATTATCGTGTA and 5'-TGGATTA-CAAAGAAAACCATCACT), and two primer pairs targeting the ITS-2 region (5'-GTGAGCGTAATAAAGGTGCAG and 5'-TTCATCACACATCTTCCACTA; 5'-CAATTGAAAACCGCTTAGCGTGTTT and 5'-TGATCTGAGGTGCGACATTCC). This multiplex PCR resulted in a banding pattern that allowed identification of *T. spiralis*, *T. nativa*, *T. britovi*, *T. pseudospiralis*, *Trichinella* T5, *Trichinella* T6, and *T. nelsoni*.

The golden jackal (*Canis aureus*): A new host for *Echinococcus multilocularis* and *Trichinella britovi* in Switzerland

C. Frey et al.

**Table 1:** Summarized information on the five golden jackals assessed so far in Switzerland.

| Case Nr | Year | Canton | Cause of death             | Coproscopy & PCR  | AD & PCR                      |
|---------|------|--------|----------------------------|---|-------------------------------|
| 1       | 2016 | SZ     | disease*                   | Hookworm eggs   | negative                      |
| 2       | 2016 | GR     | shot (mistaken as fox)     | not done  | not done                      |
| 3       | 2019 | GR     | killed by wolf (suspicion) | negative  | negative                      |
| 4       | 2019 | FR     | hit by car                 | <i>E. multilocularis</i> eggs & adults**  | negative                      |
| 5       | 2021 | BE     | hit by car                 | <i>E. multilocularis</i> eggs & adults**<br><i>Toxocara canis</i> eggs<br><i>Sarcocystis</i> sp. sporocysts | <i>Trichinella britovi</i> ** |

AD = artificial digestion, SZ = Schwyz, GR = Graubünden, FR = Fribourg, BE = Bern, \*nephropathy and cardiomyopathy with emaciation, \*\*morphological and molecular identification.

The golden jackal (*Canis aureus*): A new host for *Echinococcus multilocularis* and *Trichinella britovi* in Switzerland  
C. Frey et al.

## Results

*Echinococcus multilocularis* was microscopically identified in two out of the four examined jackals (cases 4 & 5; Table 1) (Figure 3). In both cases, amplicons of the expected size for *E. multilocularis* (395 bp) were obtained after multiplex PCR and gel electrophoresis.

Larvae of *Trichinella* spp., molecularly identified as *T. britovi*, were recovered from one out of four animals (case 5). Other parasites detected in faecal samples

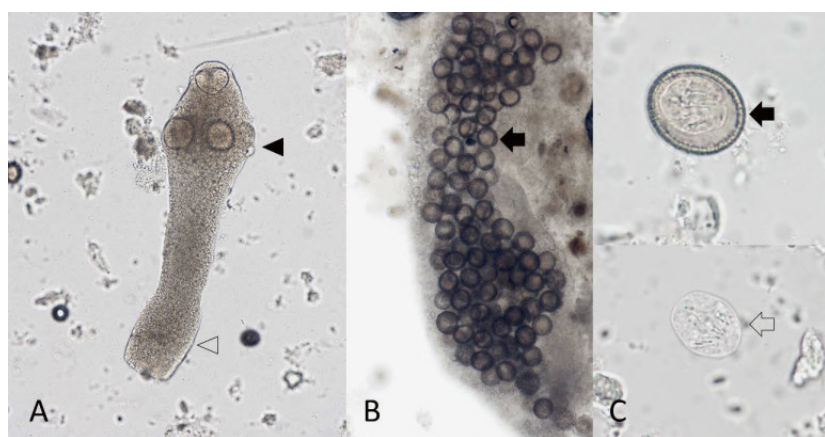
included *Toxocara canis* (eggs) (case 5), *Sarcocystis* sp. (sporocysts) (case 5), and undetermined hookworm (eggs) (case 1) (Table 1). The histopathological examinations of the intestines of case 4, revealed the presence of a mild to moderate eosinophilic infiltration within the lamina propria and the crypts along with multiple intralesional sections of cestode parasites consistent with *Echinococcus* sp. containing immature eggs within the end proglottid. (Figure 4).

## Discussion

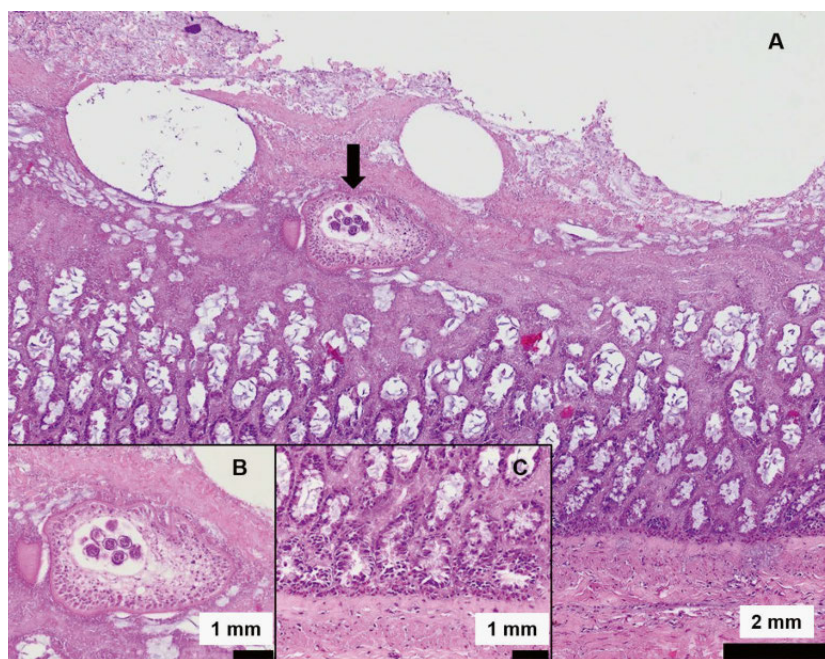
A health surveillance programme has been in place in Switzerland for large predators for more than 20 years, initiated for lynx, but later extended to other species, including the golden jackal upon its arrival in the country. The golden jackal has been only sporadically observed in Switzerland so far. Accordingly, until May 2021 only a few dead individuals have been investigated. However, systematic parasitological investigations already revealed the occurrence of several zoonotic parasites, including *E. multilocularis*, *T. britovi* and *T. canis*. Eggs from potential zoonotic hookworms were also found.

The substantial geographical expansion and increase in numbers of the golden jackal throughout Europe has raised some concern, because jackals are hosts to a wide variety of canine parasites and might transport them over long distances.<sup>18</sup> The risk of introduction to non-endemic countries not only of vector-borne parasites such as *Dirofilaria immitis*, *Thelazia callipaeda*, *Angiostrongylus vasorum* (among others), but also of *E. multilocularis*, has been addressed by several authors.<sup>2, 9, 16, 20, 22, 26, 34, 36, 37, 38</sup> Jackals could potentially also introduce new species of *Trichinella* spp. to non-endemic regions.<sup>37</sup> It is important to note that the golden jackal is a species native to South-Eastern Europe and some authors therefore call for EU-wide legal protection of this wild canid.<sup>31</sup> Whatever the political decisions in this respect will be, there is a consensus among scientists that golden jackals should be monitored for their health status.<sup>4, 18, 33, 37</sup>

Large predators are valuable indicators of the occurrence of meat-borne parasites, as they may feed on infected prey and accumulate parasites throughout their lives. Therefore, they can be useful to monitor the occurrence of endemic zoonotic parasites. The number of golden jackals in Switzerland is still very low, which is in agreement with the fact that only adult males, possibly lone individuals searching for new territories, have been found here but no females or offspring yet.<sup>23</sup> Low population numbers mean that golden jackals are not able to sustain parasite cycles like that of *E. multilocularis* on their own, but if the local prevalence is high in red foxes, golden jackals may also contribute to parasite main-



**Figure 3:** Scolex (solid arrowhead) with first immature proglottid (open arrowhead) (A), gravid proglottid (B), eggs (solid arrows) (B and C), and hatched oncosphere (open arrow) (C) of *E. multilocularis* from the faeces of a golden jackal (*Canis aureus*) (case 4).



**Figure 4:** Mild to moderate eosinophilic enteritis with intralesional parasite (arrow) (A). Magnification of the adult cestode with immature eggs within the end proglottid, compatible with *Echinococcus* sp. (B). Eosinophilic infiltration in the lamina propria and the crypts of the small intestine (C).

tenance in the environment, and possibly to its spread over long distance.<sup>2, 27</sup> Importantly, in the near future the golden jackal may establish as a population and gain in epidemiological significance.

## Conclusions

The health monitoring programme for large predators allowed us to add the golden jackal to the list of hosts for the reportable zoonotic parasites *E. multilocularis* and *T. britovi* in Switzerland. Although the golden jackal is new to Switzerland, the identified parasites are endemic and do not represent a new threat to public health. Nevertheless, hunters, farmers, ecologists, veterinarians, and other persons potentially coming in contact with golden jackals should be aware of the potential shedding of zoonotic eggs by these animals and handle faeces and carcasses with caution.

## Acknowledgments

The health monitoring programme for protected species carried out at the Institute for Fish and Wildlife Health is supported by the Federal Office of Environment. We thank the concerned cantonal hunting inspectors and game wardens for reporting and submitting the golden jackal carcasses for investigation. The reference function for trichinellosis of the Institute of Parasitology, University of Bern, is supported by the Federal Food Safety and Veterinary Office. We thank Christine Salvisberg, Ursula Kurath and Larissa Hofmann (Institute of Parasitology, University of Bern) for excellent technical assistance. Pictures of the three wild canids were kindly provided by Fridolin Zimmermann (Foundation KORA). This manuscript is dedicated to Prof. Peter Deplazes for his outstanding achievements in parasitology, especially concerning *E. multilocularis*.

The golden jackal (*Canis aureus*): A new host for *Echinococcus multilocularis* and *Trichinella britovi* in Switzerland

C. Frey et al.

## Le chacal doré (*Canis aureus*): Un nouvel hôte pour *Echinococcus multilocularis* et *Trichinella britovi* en Suisse

Le chacal doré (*Canis aureus*) est un canidé sauvage nouvellement présent en Suisse. Il s'agit d'une espèce officiellement surveillée et tous les individus morts sont soumis à un examen post-mortem afin de recueillir des données sanitaires de base. Cela inclut un examen parasitologique mettant l'accent sur les infections zoonotiques à déclaration obligatoire, telles que celles causées par *Trichinella* spp. ou *Echinococcus* spp. De 2016 à 2021, cinq chacals dorés originaires de quatre cantons suisses ont été soumis à un examen post-mortem complet. Dans un cas, seuls des échantillons d'organes ont été envoyés, l'examen parasitologique n'a pas été possible pour cet animal. Les stades parasitaires trouvés lors de l'examen pathologique et de la coprologie de routine ont été identifiés morphologiquement. Les espèces de ténias (œufs et stades adultes) ont été déterminées par des techniques de biologie moléculaire. En outre, la recherche de *Trichinella* spp. a été effectuée sur du tissu musculaire lingual et diaphragmatique par la technique de digestion artificielle suivie d'une PCR multiplex dans les cas positifs. Sur les quatre chacals ayant fait l'objet d'une recherche de parasites, des œufs d'ankylostomes ont été détectés chez un animal, des vers adultes et des œufs d'*Echinococcus multilocularis* étaient présents chez un autre animal, et aucun parasite n'a été trouvé dans un autre cas. Chez le dernier cas, des œufs d'*E. multilocularis* ainsi que des œufs de *Toxocara canis* et des sporocystes de *Sarcocystis* sp. ont été détectés dans le contenu intestinal, et des larves de *Trichinella britovi* ont été trouvées dans les échantillons de muscle. Le

## Lo sciacallo dorato (*Canis aureus*): un nuovo ospite per l'*Echinococcus multilocularis* e la *Trichinella britovi* in Svizzera

Lo sciacallo dorato (*Canis aureus*) è un canide selvatico nuovo per la Svizzera. È una specie sorvegliata ufficialmente e tutti gli individui morti sono sottoposti a un esame post-mortem per raccogliere dati di base sulla salute dell'animale. Questo include un esame parassitologico con particolare attenzione alle infezioni zoonotiche notificabili, come quelle causate da *Trichinella* spp. o *Echinococcus* spp. Dal 2016 al 2021, cinque sciacalli dorati di quattro cantoni svizzeri sono stati sottoposti a un esame post-mortem completo. In un caso, sono stati inviati solo campioni di organi, poiché l'esame parassitologico non era possibile per questo animale. Gli stadi dei parassiti trovati durante l'esame patologico e la coprologia di routine sono stati identificati morfologicamente. Le specie di tenie (uova e stadi adulti) sono state determinate con tecniche di biologia molecolare. Inoltre, la *Trichinella* spp. è stata ricercata sul tessuto muscolare linguale e diaframmatico utilizzando la tecnica di digestione artificiale seguita da PCR multiplex nei casi positivi. Tra i quattro sciacalli testati per i parassiti, sono state rilevate uova di anchilostoma in un animale, vermi adulti e uova di *Echinococcus multilocularis* in un altro, e nessun parassita è stato trovato nell'ultimo. Nell'ultimo caso, uova di *E. multilocularis*, così come uova di *Toxocara canis* e sporocisti di *Sarcocystis* sp. sono state rilevate nel contenuto intestinale mentre le larve di *Trichinella britovi* sono state rilevate nei campioni di muscolo. Il programma di sorveglianza sanitaria dei carnivori protetti in Svizzera ha quindi aggiunto lo sciacallo dorato alla lista degli ospiti dei parassiti zoonotici endemici *E. multilocularis* e *T.*

The golden jackal (*Canis aureus*): A new host for *Echinococcus multilocularis* and *Trichinella britovi* in Switzerland

C. Frey et al.

programme de surveillance sanitaire mis en place pour les carnivores protégés en Suisse a donc permis d'ajouter le chacal doré à la liste des hôtes des parasites zoonotiques endémiques *E. multilocularis* et *T. britovi*. Les chasseurs, agriculteurs et autres personnes susceptibles d'entrer en contact avec le chacal doré doivent être conscients du risque sanitaire associé et manipuler les fèces et les carcasses avec précaution.

**Mots clés:** *Canis aureus*, surveillance sanitaire, parasites, faune sauvage, zoonoses

### Schacal mellen (*Canis aureus*), in niev hospitont per *Echinococcus multilocularis* e *Trichinella britovi* en Svizra

Il schacal mellen (*Canis aureus*) ei ina spezia nova da tgauns selvadis en Svizra. La derasaziun vegn survegliada officialmein. Tut ils animals carpai vegnan examinai patologicamein per rimnar informaziuns da basa sur dalla sanadad da quella spezia. En quei mument vegn era intercuret g sin prasits, spezialmein parasits zoonotics ch'ins ei obligaus d'annunziar sco *Trichinella* spp. ni *Echinococcus* spp. Denter 2016 e 2021 han ins anflau en quater cantuns tschun schacals mellens carpai. En in cass ei vegniu tarmess en mo organs fixai, aschia ch'igl ei stau nunpusseivel d'intercurrir parasitologiamain. Tut ils stadis da parasits, anflai durent la secziun ni l'examinaziun coprologica, ein vegni classificai morfologicamein. Ovs da taeniids e viarms plats adults ein vegni examinai ultra da quei era molecularbiologicamein. Supplementarmain ei vegniu intercuret g da mintga animal musculatura dalla lieunga e dil diafragma sin *Trichi-*

*britovi*. Cacciatori, agricoltori e altri che possono entrare in contatto con lo sciacallo dorato dovrebbero essere consapevoli del rischio sanitario associato e maneggiare con cura feci e carcasse.

**Parole chiave:** *Canis aureus*, sorveglianza sanitaria, parassiti, fauna selvatica, zoonosi

*nella* spp. cun la tecnica da digestiun artificziala, e las larvas anfladas ein vegnidas indentificadas cun multiplex-PCR. Parasitologicamein ei vegniu anflau tier in animal ovs dil vierm gavunau, tier in auter schebein viarms adults sco era ovs da *Echinococcus multilocularis*. Tier in auter animal han ins anflau negins parasits. En in cass supplementar ei vegniu observau ovs da *E. multilocularis* e *Toxocara canis*, sco era sporozistas da *Sarcocystis* sp. Ella musculatura dil medem animal ein larvas da *T. britovi* vegnidas demussadas. Il programm da survegionza dalla sanadad da carnivors schurmegiai lube-scha dad identificar il schacal mellen sco hospitont supplementar per ils parasits endemics *E. multilocularis* e *T. britovi*. Catschaduras e catschadurs, puras e purs ed autras persunas che savessan vegnir en contact cul schacal mellen, duessan esser pertscharts da quella resca per lur sanadad e tractar ton ils excrements sco era ils cadavers da quels animals cun precauziun.

**Plaids-clav:** *Canis aureus*, survegionza dalla sanadad, parasit, animal selvadi, zoonosa

## Literaturnachweis

- 1 Bagó F, Hoelzl F, Knauer F, Küber-Heiss A, Smith S: Rapid and reliable detection of *Echinococcus multilocularis* from faeces using droplet digital PCR. *Acta Parasitol.* 2021; 66(2): 553–559.
- 2 Balog T, Nagy G, Halász T, Csányi E, Zomborszky Z, Csivincsik Á: The occurrence of *Echinococcus* spp. in golden jackal (*Canis aureus*) in southwestern Hungary: Should we need to rethink its expansion? *Parasitol. Int.* 2021; 80:102214.
- 3 Blaga R, Gherman C, Seucom D, Cozma V, Boireau P: First identification of *Trichinella* sp. in golden jackal (*Canis aureus*) in Romania. *J. Wildl. Dis.* 2008; 44(2): 457–459.
- 4 Deksne G, Segliņa Z, Jahundoviča I, Esīte Z, Bakasejevs E, Bagrade G, Keidāne D, Interisano M, Marucci G, Tonanzi D, Pozio E, Kirjušina M: High prevalence of *Trichinella* spp. in sylvatic carnivore mammals of Latvia. *Vet. Parasitol.* 2016; 231: 118–123.
- 5 Deplazes P, Alther P, Tanner I, Thompson R C, Eckert J: *Echinococcus multilocularis* coproantigen detection by enzyme-linked immunosorbent assay in fox, dog, and cat populations. *J Parasitol.* 1999; 85(1):115–21.
- 6 Deplazes P, van Knapen F, Schweiger A, Overgaauw PAM: Role of pet dogs and cats in the transmission of helminthic zoonoses in Europe, with a focus on echinococcosis and toxocarosis. *Vet. Parasitol.* 2011; 182(1): 41–53.
- 7 Deplazes P, Rinaldi L, Alvarez Rojas CA, Torgerson PR, Harandi MF, Romig T, Antolova D, Schurer JM, Lahmar S, Cringoli G, Magambo J, Thompson RC, Jenkins EJ: Global distribution of alveolar and cystic echinococcosis. *Adv. Parasitol.* 2017; 95: 315–493.
- 8 Deplazes P, von Samson-Himmelstjerna G, Zahner H., Joachim A., Mathis A., Taubert A., Strube C: *Parasitologie für die Tiermedizin.* 2020 4. Ed. Thieme p. 550.
- 9 Duscher GG, Küber-Heiss A, Richter B, Suchentrunk F: A golden jackal (*Canis aureus*) from Austria bearing *Hepatozoon canis*—import due to immigration into a non-endemic area? *Ticks Tick Borne Dis.* 2013; 4(1–2): 133–137.
- 10 Eckert J, Deplazes P: Biological, epidemiological, and clinical aspects of echinococcosis, a zoonosis of increasing concern. *Clin. Microbiol. Rev.* 2004; 17: 107–135.
- 11 EFSA: The EU summary report on trends and sources of zoonoses, zoonotic agents and food-borne outbreaks in 2013. *EFSA J.* 2015; 13:3991.
- 12 European Commission, 2015: Commission Implementing Regulation (EU) 2015/1375 of 10 August 2015 laying down specific rules on official controls for *Trichinella* in meat. *Off. J. EU. L.* 2015; 212, 7–34. [http://data.europa.eu/eli/reg\\_impl/2015/1375/oj](http://data.europa.eu/eli/reg_impl/2015/1375/oj).
- 13 Frey CF, Schuppers ME, Müller N, Ryser-Degiorgis MP, Gottstein B: Assessment of the prevalence of *Trichinella* spp. in red foxes and Eurasian lynxes from Switzerland. *Vet. Parasitol.* 2009; 159(3–4):295–299.
- 14 Frey CF, Marreros N, Renneker S, Schmidt L, Sager H, Hentrich B, Milesi S, Gottstein B: Dogs as victims of their own worms: Serodiagnosis of canine alveolar echinococcosis. *Parasit. Vectors.* 2017; 10(1):422.
- 15 FSVO (Federal Food Safety and Veterinary Office Switzerland): Technische Weisungen über Trichinellenuntersuchung von Schlachttierkörpern und Fleisch von Hauschweinen, Pferden, Wildschweinen, Bären und Nutrias sowie weiteren empfänglichen Wildtierarten, vom 01.06.2017.
- 16 Gavrilović P, Marinković D, Vidanović D, Dobrosavljević I, Gavrilović A: Are golden jackals (*Canis aureus*) definitive hosts for *Angiostrongylus vasorum*? *Transbound. Emerg. Dis.* 2019; 66(6): 2305–2310.
- 17 Gottstein B, Saucy F, Deplazes P, Reichen J, Demierre G, Busato A, Zuercher C, Pugin P: Is high prevalence of *Echinococcus multilocularis* in wild and domestic animals associated with disease incidence in humans? *Emerg. Infect. Dis.* 2001; 7(3):408–412.
- 18 Gherman CM, Mihalca AD: A synoptic overview of golden jackal parasites reveals high diversity of species. *Parasit. Vectors.* 2017; 10(1):419.
- 19 Hauser M, Basso W, Deplazes P: Kontamination landwirtschaftlicher Nutzflächen durch Hunde- und Fuchskot. *Schweiz Arch Tierheilkd.* 2015; 157(8):449–455.
- 20 Ionič AM, Matei IA, D'Amico G, Daskalaki AA, Juránková J, Ionescu DT, Mihalca AD, Modrý D, Gherman CM: Role of golden jackals (*Canis aureus*) as natural reservoirs of *Dirofilaria* spp. in Romania. *Parasit. Vectors.* 2016; 9:240.
- 21 Janovsky M, Bacciarini L, Sager H, Gröne A, Gottstein B: *Echinococcus multilocularis* in a European beaver from Switzerland. *J. Wildl. Dis.* 2002; 38(3):618–620.
- 22 Klitgaard K, Chriél M, Isbrand A, Jensen TK, Bødker R: Identification of *Dermacentor reticulatus* ticks carrying *Rickettsia raoultii* on migrating jackal, Denmark. *Emerg. Infect. Dis.* 2017; 23(12):2072–2074.
- 23 KORA: <https://www.kora.ch/index.php?id=80>. Accessed June 14, 2021.
- 24 Lalošević D, Lalošević V, Simin V, Miljević M, Cabrilo B, Bjelić Čabrilo O: Spreading of multilocular echinococcosis in southern Europe: the first record in foxes and jackals in Serbia, Vojvodina Province. *Eur. J. Wildl. Res.* 2016; 62:793–796.
- 25 Meyer A, Olias P, Schüpbach G, Henzi M, Barmettler T, Hentrich B, Gottstein B, Frey CF: Combined cross-sectional and case-control study on *Echinococcus multilocularis* infection in pigs in Switzerland. *Vet. Parasitol.* X. 2020; 4:100031.
- 26 Mitková B, Hrazdilová K, D'Amico G, Duscher GG, Suchentrunk F, Forejtek P, Gherman CM, Matei IA, Ionič AM, Daskalaki AA, Mihalca AD, Votýpka J, Hulva P, Modrý D: Eurasian golden jackal as host of canine vector-borne protists. *Parasit. Vectors.* 2017; 10(1):183.
- 27 Oksanen A, Siles-Lucas M, Karamon J, Possenti A, Conraths FJ, Romig T, Wysocki P, Mannocci A, Mipatrini D, La Torre G, Boufana B, Casulli A: The geographical distribution and prevalence of *Echinococcus multilocularis* in animals in the European Union and adjacent countries: a systematic review and meta-analysis. *Parasit. Vectors.* 2016; 9(1):519.
- 28 Otero-Abad B, Armua-Fernandez MT, Deplazes P, Torgerson PR, Hartnack S: Latent class models for *Echinococcus multilocularis* diagnosis in foxes in Switzerland in the absence of a gold standard. *Parasit. Vectors.* 2017; 10(1): 612. doi: 10.1186/s13071-017-2562-1.
- 29 Otranto D, Cantacessi C, Dantas-Torres F, Brianti E, Pfeffer M, Genchi C, Guberti V, Capelli G, Deplazes P: The role of wild canids and felids in spreading parasites to dogs and cats in Europe. Part II: Helminths and arthropods. *Vet. Parasitol.* 2015; 213(1–2):24–37.
- 30 Rehmann P, Gröne A, Gottstein B, Sager H, Müller N, Völlm J, Bacciarini LN: Alveolar echinococcosis in the zoological garden Basle. *Schweiz Arch. Tierheilkd.* 2005; 147(11):498–502.

The golden jackal (*Canis aureus*): A new host for *Echinococcus multilocularis* and *Trichinella britovi* in Switzerland

C. Frey et al.

- The golden jackal (*Canis aureus*): A new host for *Echinococcus multilocularis* and *Trichinella britovi* in Switzerland  
C. Frey et al.
- <sup>31</sup> Rutkowski R, Krofel M, Giannatos G, Ćirović D, Männil P, Volokh AM, Lanszki J, Heltai M, Szabó L, Banea OC, Yavruyan E, Hayrapetyan V, Kopaliani N, Miliou A, Tryfonopoulos GA, Lymberakis P, Penezić A, Pakeltyté G, Suchecka E, Bogdanowicz W: A European concern? Genetic structure and expansion of golden jackals (*Canis aureus*) in Europe and the Caucasus. *PLoS One*. 2015: 10(11):e0141236.
- <sup>32</sup> Ryser-Degiorgis M-P, Segner H: National competence center for wildlife diseases in Switzerland: Mandate, development and current strategies. *Schweiz. Arch. Tierheilkd*. 2015: 157(5):255–266.
- <sup>33</sup> Shamsian A, Pozio E, Fata A, Navi Z, Moghaddas E: The Golden jackal (*Canis aureus*) as an indicator animal for *Trichinella britovi* in Iran. *Parasite*. 2018: 25:28.
- <sup>34</sup> Sindičić M, Bujanić M, Štimac I, Martinković F, Tuškan N, Špehar M, Konjević D: First identification of *Echinococcus multilocularis* in golden jackals in Croatia. *Acta Parasitol*. 2018: 63(3): 654–656.
- <sup>35</sup> Spassov N, Acosta-Pankov I: Dispersal history of the golden jackal (*Canis aureus moreoticus* Geoffroy, 1835) in Europe and possible causes of its recent population explosion. *Biodivers. Data J*. 2019: 7:e34825. doi: 10.3897/BDJ.7.e34825.
- <sup>36</sup> Sukara R, Chochlakis D, Ćirović D, Penezić A, Mihaljica D, Ćakić S, Valčić M, Tselentis Y, Psaroulaki A, Tomanović S: Golden jackals (*Canis aureus*) as hosts for ticks and tick-borne pathogens in Serbia. *Ticks Tick Borne Dis*. 2018: 9(5): 1090–1097.
- <sup>37</sup> Széll Z, Marucci G, Pozio E, Sréter T: *Echinococcus multilocularis* and *Trichinella spiralis* in golden jackals (*Canis aureus*) of Hungary. *Vet. Parasitol*. 2013: 197(1–2): 393–396.
- <sup>38</sup> Széll Z, Bacsadi Á, Szeredi L, Nemes C, Fézer B, Bakcsa E, Kalla H, Tolnai Z, Sréter T: Rapid spread and emergence of heartworm resulting from climate and climate-driven ecological changes in Hungary. *Vet. Parasitol*. 2020: 280:109067.
- <sup>39</sup> Tanner F, Hegglin D, Thoma R, Brosi G, Deplazes P: *Echinococcus multilocularis* in Graubünden: Verbreitung bei Füchsen und Vorkommen potentieller Zwischenwirte. *Schweiz. Arch. Tierheilk*. 2006: 148: 501–510.
- <sup>40</sup> Trachsel D, Deplazes P, Mathis A: Identification of taeniid eggs in the faeces from carnivores based on multiplex PCR using targets in mitochondrial DNA. *Parasitology*. 2007: 134(6):911–920.
- <sup>41</sup> Zarlenga DS, Chute MB, Martin A, Kapel CM: A multiplex PCR for unequivocal differentiation of all encapsulated and non-encapsulated genotypes of *Trichinella*. *Int. J. Parasitol*. 1999: 29: 1859–1867.
- <sup>42</sup> Zivojinovic M, Sofronic-Milosavljevic L, Cvetkovic J, Pozio E, Interisano M, Plavsic B, Radojicic S, Kulisic Z: *Trichinella* infections in different host species of an endemic district of Serbia. *Vet. Parasitol*. 2013: 194(2–4):136–138.

## Korrespondenzadresse

Caroline Frey  
Institute of Parasitology, Department of Infectious Diseases  
and Pathobiology, Vetsuisse Faculty, University  
Länggassstrasse 122  
CH-3012 Bern  
Telefon: +41 31 684 24 18  
E-Mail: caroline.frey@vetsuisse.unibe.ch