



A RARE PRESENTATION OF GENITOURINARY TUBERCULOSIS MIMICKING ABDOMINAL TUMOR

Ivana Goić-Barišić^{1,2}, Ivo Milas^{3†}, Igor Barišić^{2,4}, Boris Lukšić^{2,3}, Anita Novak^{1,2}, Žana Rubić^{1,2}, Irena Perić^{2,5} and Marija Tonkić^{1,2}

¹Department of Microbiology, Split University Hospital Center, Split, Croatia;

²University of Split, School of Medicine, Split, Croatia;

³Department of Infectious Diseases, Split University Hospital Center, Split, Croatia;

⁴Department of Diagnostic and Interventional Radiology, Split University Hospital Center, Split, Croatia;

⁵Department of Pulmonary Diseases, Split University Hospital Center, Split, Croatia

SUMMARY – Genital tuberculosis is a rare and unexpected disease in European countries including Croatia. Diagnosis of female genital tract tuberculosis is challenging and is rarely pin-pointed by clinical symptoms because of their low specificity. The authors decided to present a case of genitourinary tuberculosis in a young, immunocompetent fertile woman with high clinical suspicion of abdominal tumor mass. Although considered a disease of the past, rare clinical presentation of genital tuberculosis should be expected and taken into account.

Key words: *Tuberculosis; Genitourinary tract; Young women; Abdominal tumor*

Introduction

Tuberculosis (TB) is a life-threatening chronic granulomatous inflammatory disease caused by *Mycobacterium tuberculosis* (*M. tuberculosis*), an aerobic bacterium and predominantly presenting with pulmonary disease¹. It remains a world-wide problem despite discovery of the causative organism for more than a century ago. TB of the genitourinary tract is rare, but can become a secondary complication in women diagnosed with TB of the lungs². TB of the kidneys usually spreads by a hematogenous route from pulmonary disease, although it occasionally may be secondary to TB of the gastrointestinal

tract or bone. By the time of diagnosis of renal TB, the primary source of pulmonary infection may be inactive or calcified³. The true prevalence of renal TB is underestimated because radiological signs may be absent. Moreover, tubercle bacilli are found in 7%-29% of urine samples in patients with extrarenal TB⁴. Genital TB is usually secondary to renal tuberculous infection, and spread may be hematogenous, *via* the lymphatic system, or by direct spread from adjacent organs. Female genital TB usually is a symptomless disease diagnosed during investigations for infertility⁵. Symptomatic disease usually presents with pelvic pain or menstrual irregularities⁶. Croatia is a high-fleeting country with a population of 4.5 million people, which has recently become a European Union Member State. TB incidence rates have been slowly decreasing to reach a rate of 13/100 000 in 2013 and 2014⁷. We report on a case of genitourinary TB in a young, immunocompetent fertile woman with high clinical suspicion of abdominal tumor mass.

Correspondence to: Prof. Ivana Goić-Barišić, MD, PhD, Department of Microbiology, Split University Hospital Center, Spinčićeva 1, HR-21000 Split, Croatia
E-mail: igoic@kbsplit.hr

Received March 16, 2016, accepted September 12, 2016

Case Report

A 27-year-old female patient was admitted to the Emergency Room of the Split University Hospital Center after two months of abdominal distension, recurrent diarrhea, and occasional pelvis cramps. She had no past medical history of any chronic disease or known contact with TB, and had normal menstrual history. On presentation, the body axillary temperature was 39 °C and laboratory findings obtained upon admission showed high inflammatory parameters (erythrocyte sedimentation rate (ESR) 60 mm/h, C-reactive protein (CRP) 118 mg/L, and white blood cell count (WBC) $8 \times 10^9/L$). Cardiopulmonary status was normal, and physically the patient had no palpable mass in the abdomen. Ultrasound examination showed adnexal masses with mixed echoes, sized up to 8 cm. She was treated with antimicrobial therapy intravenously for ten days (ceftriaxone, metronidazole, garmycin) for suspicion of tubo-ovarian abscesses. Routine microbiological urine culture and cervical smears were sterile. After therapy she was afebrile, with decrease in laboratory inflammatory parameters, but presenting nonspecific pain in the pelvis. Additional laboratory testing showed increase in cancer antigen

Ca-125 (188 U/mL) and repeat ultrasound revealed that dimension of the adnexa was the same as at therapy initiation. Diagnostic laparotomy showed bowels in firm adhesion together and with peritoneum in the small pelvis, and fibrin deposits in the entire visceral and parietal peritoneum. The uterus and adnexa could not be displayed. Due to possible malignancy, ascites and biopsy specimens were sent for cytologic, histopathologic and routine microbiologic analyses. The histopathologic diagnosis was chronic granulomatous inflammation. Histochemical staining of the tissue did not prove acid resistant bacteria. Fibrin deposits and ascites were sterile on routine microbiologic analysis. After laparotomy, the patient's body temperature was 39 °C, and the repeat laboratory findings were ESR 68 mm/h, WBC $8 \times 10^9/L$, CRP 218 mg/L and Ca-125 170 U/mL, with tumor markers CEA, CA 19-9 and CA 15-3 within the normal ranges. Postlaparotomy multi-slice computed tomography revealed solid masses of 6-7 cm in size on both ovaries, accompanied by enlarged retroperitoneal lymph nodes and adhesion of intestine coils in terms of carcinosis. The radiologic diagnosis was bilateral tumor of the ovaries and carcinosis of the peritonei (Fig. 1).

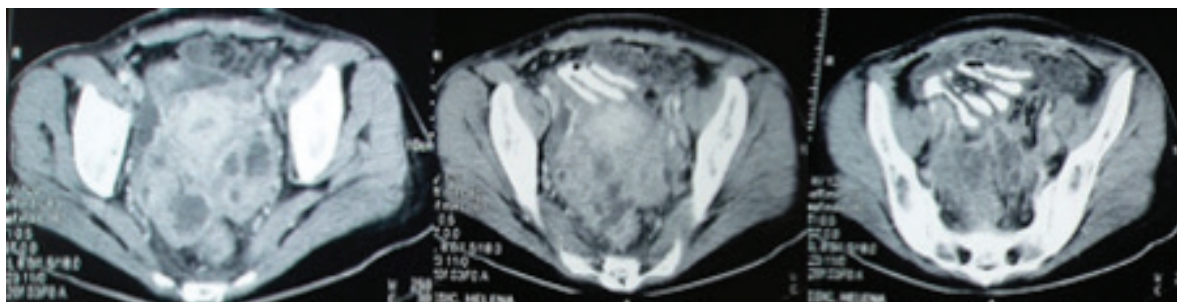


Fig. 1. Postoperative multi-slice computed tomography revealed solid masses on both ovaries accompanied by enlarged retroperitoneal lymph nodes and adhesion of intestinal coils in terms of carcinosis. The radiological diagnosis was bilateral tumor of the ovaries and carcinosis of the peritoneums.

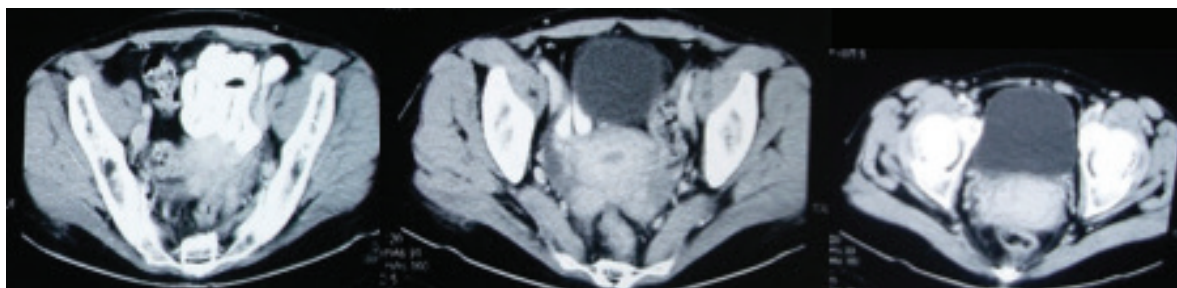


Fig. 2. One month after initiation of antituberculosis therapy, multi-slice computed tomography showed significant regression of abdominal mass.

After histopathologic examination of tumor mass from abdominal laparotomy, only one urine sample was obtained for specific microbiologic testing for *M. tuberculosis*. The sample was cultured on solid (Lowenstein-Jensen) and liquid media (Mycobacteria Growth Indicator Tube, MGIT). The liquid culture gave a positive signal after 7 days of incubation, and three weeks of sampling we had culture on solid medium. In the meantime, the patient was transferred to the Department of Infectious Diseases, Split University Hospital Center, where antituberculous therapy was introduced.

Drug susceptibility testing was performed by the proportional methods on Lowenstein-Jensen medium. The isolated strain was susceptible to isoniazid (0.2 µg/mL), rifampicin (40 µg/mL), ethambutol (2 µg/mL), and streptomycin (10 µg/mL). The patient was treated with a three-drug regimen of isoniazid (300 mg/day), rifampicin (600 mg/day) and ethambutol (1500 mg/day) for nine months. Within a month of the initiation of antituberculosis therapy, abdominal computed tomography showed regression of the abdominal mass along with resolution of fatigue, two-kilogram weight gain, and complete resolution of persistent evening pyrexia and lower abdominal pain (Fig. 2).

Discussion

Tuberculosis is one of the world's most important communicable diseases. Early detection and early treatment of TB patients are the key principles of TB control. Delayed diagnosis and treatment increase the severity of the disease and can lead to the harder-to-treat forms of TB⁸. Extra-pulmonary TB is also a significant cause of morbidity and mortality, and affects lymph nodes, intestine, bone, joints, meninges, and genitourinary tract^{8,9}. Although in some cases genital TB is thought to be the primary infection^{10,11}, presentation of the disease as abdominal tumor is uncommon. Genitourinary TB is usually a secondary complication of pulmonary TB. The prevalence of female genital TB varies from 1% to 19%, depending on the country¹¹. In most cases, it begins with a focus in the endosalpinx and spreads to the endometrium, the ovaries, occasionally to the cervix, and rarely to the vagina¹². Diagnosis is often difficult because TB has a variety of clinical and radiological findings. All imaging findings may be normal in patients with early genitourinary TB. Genitourinary calcification

may occur in patients with diabetes mellitus and schistosomiasis¹³. Differential diagnosis of an adnexal mass is wide. Congenital megacalyx and focal papillary necrosis may mimic renal TB radiologically. Papillary necrosis can result from TB. Tuberculous testicular granuloma may mimic testicular neoplasm on ultrasonographic images¹⁴.

Infection with *M. tuberculosis* is usually asymptomatic because immunity rapidly develops. For genitourinary TB, which is considered a rare extrapulmonary form, a period of 5-40 years has been reported from initial infection and onset of symptoms¹⁵. As the symptoms and findings can resemble those of ovarian tumors, confirmation of TB can only be made when the causative mycobacterium is isolated from clinical sample. Cancer antigen 125 (CA-125) is usually elevated in ovarian cancer. According to literature data, serum CA-125 level has been found to be rarely raised in the presence of pulmonary TB and peritoneal TB^{14,15}, which can make it difficult to establish the diagnosis of TB. However, recently published data have confirmed that the value of cancer antigen may be useful in monitoring therapeutic responses in certain cases of active TB in female patients¹⁶. The case presented fits the diagnostic dilemma, and although considered a disease of the past, rare clinical presentation should be expected and taken into account.

References

1. Gonzalez OY, Adams G, Teeter LD, Bui TT, Musser JM, Graviss EA. Extra-pulmonary manifestations in a large metropolitan area with a low incidence of tuberculosis. *Int J Tuberc Lung Dis.* 2003;7:1178-85.
2. Neonakis IK, Spandidos DA, Petinaki E. Female genital tuberculosis: a review. *Scand J Infect Dis.* 2011;43(8):564-72. doi: 10.3109/00365548.2011.568523
3. Lin YL, Fan YC, Cheng CY, Sue YM, Hsu YH, Hou CC, Chen TH, Chen TW. The case: sterile pyuria and an abnormal abdominal film. "Autonephrectomy" of right kidney. *Kidney Int.* 2008;73:131-3.
4. Lenk S, Schroeder J. Genitourinary tuberculosis. *Curr Opin Urol.* 2001;1:93-8. doi: 10.1097/00042307-200101000-00014
5. Namavar Jahromi B, Parsanezhad ME, Ghane-Shirazi R. Female genital tuberculosis and infertility. *Int J Gynaecol Obstet* 2001;75:269-72. doi: 10.1016/s0020-7292(01)00494-5
6. Lamba H, Byrne M, Goldin R, Jenkins C. Tuberculosis of the cervix: case presentation and a review of the literature. *Sex Transm Infect.* 2002;78:62-3.

7. Jurcev-Savicevic A, Mulic R, Ban B, Kozul K, Bacun-Ivcek L, Valic J, *et al.* Risk factors for pulmonary tuberculosis in Croatia: a matched case-control study. *BMC Public Health*. 2013;13:991. doi: 10.1186/1471-2458-13-991
8. Lönnroth K, Castro KG, Chakaya JM, Chauhan LS, Floyd K, Glaziou P, Raviglione MC. Tuberculosis control and elimination 2010-50: cure, care, and social development. *Lancet*. 2010;375(9728):1814-29. doi: 10.1016/S0140-6736(10)60483-7
9. Sutherland AM, Glen ES, MacFarlane JR. Transmission of genito-urinary tuberculosis. *Health Bull (Edinb)*. 1982;40:87-91.
10. Richards MJ, Angus D. Possible sexual transmission of genitourinary tuberculosis. *Int J Tuberc Lung Dis*. 1998;2:439.
11. Varma TR. Genital tuberculosis and subsequent fertility. *Int J Gynecol Obstet*. 1991;35:11.
12. Sharma JB, Roy KK, Pushparaj M, Kumar S, Malhotra N, Mittal S. Laparoscopic findings in female genital tuberculosis. *Arch Gynecol Obstet*. 2008;278:359-64.
13. Doenhoff MJ. A role for granulomatous inflammation in the transmission of infectious disease: schistosomiasis and tuberculosis. *Parasitology*. 1997;115:113-25.
14. Jung YY, Kim JK, Cho KS. Genitourinary tuberculosis: comprehensive cross-sectional imaging. *AJR Am J Roentgenol*. 2005;184:143-50. doi: 10.2214/ajr.184.1.01840143
15. Zajackowski T. Genitourinary tuberculosis: historical and basic science review: past and present. *Cent European J Urol*. 2012;65:182-7. doi: 10.5173/cej.2012.04.art1
16. Kim ES, Park KU, Song J, Lim HJ, Cho YJ, Yoon H, *et al.* The clinical significance of CA-125 in pulmonary tuberculosis. *Tuberculosis*. 2013;93:222-6. doi: 10.1016/j.tube.2012.10.014

Sažetak

KLINIČKI PRIKAZ GENITOURINARNE TUBERKULOZE SA SUMNJOM NA ABDOMINALNU NEOPLAZMU

I. Goić-Barišić, I. Milas[†], I. Barišić, B. Lukšić, A. Novak, Ž. Rubić, I. Perić i M. Tonkić

Genitalna tuberkuloza rijetka je i neočekivana bolest u zemljama Europske unije uključujući i Hrvatsku. Postavljanje dijagnoze tuberkuloze genitalnog sustava otežano je nespecifičnim simptomima. Prikazujemo slučaj genitourinarne tuberkuloze kod mlade imunokompetentne žene generativne dobi gdje je klinička dijagnoza upućivala na abdominalnu neoplazmu. U vremenu velikih društvenih promjena prisutnih posljednjih godina rijetke kliničke prezentacije tuberkuloze i dalje su moguće kao diferencijalna dijagnoza.

Ključne riječi: *Tuberkuloza; Genitourinarni sustav; Mlada žena; Abdominalni tumor*