

RECONSTRUCTION OF THE SCALP AND CALVARIA DEFECTS

ZVONIMIR ZORE¹, SREĆKO BUDI², IRINA FILIPOVIĆ ZORE³, LJILJANA ŠTEFANČIĆ¹,
STELA MARIĆ¹ and ZDENKO STANEC²

¹University Hospital for Tumors, "Sestre milosrdnice" University Hospital, Zagreb, Croatia

²Department of Plastic, Reconstructive and Esthetic Surgery, "Dubrava" University Hospital,
Zagreb, Croatia

³Faculty of Dental Medicine Zagreb, Department of Oral Surgery, Zagreb, Croatia

Summary

Defects of the scalp and calvaria most frequently occur as a result of invasive growth of intra- or extracranial malignant or benign tumors, or as a result of trauma.

During a five-year period, from 2004 to 2008, 21 patients (12 men and 9 women) underwent reconstructive surgery for scalp and calvaria defects at the Department of Plastic Surgery, "Dubrava" University Hospital. The patients were divided into groups with regard to the etiology of the defect, size, depth, reconstruction technique, number of surgical procedures, complications and duration of hospitalization. Different local flaps were successfully used for reconstruction of small and medium-sized defects of the scalp and calvaria, while large defects were reconstructed using free microvascular flaps.

Successful treatment of the scalp and calvaria defects depends on accurate indication and the choice of an appropriate reconstruction technique.

KEYWORDS: *defects of the scalp and calvaria, reconstruction*

REKONSTRUKCIJA DEFEKATA SKALPA I KALVARIJE

Sažetak

Defekti skalpa i kalvarije najčešće su posljedica invazivnog rasta intra- ili ekstrakranijalnih zloćudnih ili dobroćudnih tumora ili traume.

Tijekom petogodišnjeg razdoblja, od 2004. do 2008. godine, u Klinici za plastičnu kirurgiju KB Dubrava 21 bolesnik (12 muškaraca i 9 žena, srednja dob - 61 godina) bio je podvrgnut rekonstrukcijskom kirurškom zahvatu zbog defekata sklapa i kalvarije. Bolesnici su podijeljeni u skupine s obzirom na etiologiju defekta, veličinu, dubinu, rekonstrukcijski postupak, broj kirurških zahvata, komplikacije i trajanje hospitalizacije. Za male i srednje velike defekte skalpa i kalvarije uspješno su korišteni različiti lokalni režnjevi, a za velike defekte slobodni mikrovasularni režnjevi.

Uspjeh zbrinjavanja ovih defekata skalpa i kalvarije ovisi o pravilnoj indikaciji i izboru adekvatne kirurške tehnike za rekonstrukciju.

KLJUČNE RIJEČI: *defekti skalpa i kalvarije, rekonstrukcija*

INTRODUCTION

Defects of the scalp and calvaria most frequently occur as a result of invasive growth of intra- or extracranial malignant or benign tumors, or

as a result of trauma. The most frequent traumatic injuries are laceratocontusive wounds, burns, electric current shocks or avulsion injuries. Lacerations and smaller defects of the scalp following necrectomy or debridement and meticulous ho-

meostasis can be primarily closed by undermining in the subgaleal layer, or, if necessary, by incisions with a galeal knife or thermocautery.

Defects of partial thickness, with preserved periosteal layer, can be successfully reconstructed by autotransplantation of the skin of partial thickness. For defects of the scalp of full thickness, where the tabula externa calvaria is exposed, primary or delayed coverage with a skin transplant can be used for reconstruction on granulations resulting from removal of the tabula externa calvaria (1). For smaller defects the most frequently used and best method of reconstruction is application of a local flap with or without incising the galia aponeurosis (2, 3). Moderately large defects of full thickness are most often reconstructed by a larger local flap and coverage of the donor region with a skin transplant or so-called multiple axial flaps, such as tree flap and two-flap technique (4). Large defects of full thickness can be reconstructed by large local flaps, such as a single subtotal flap or pericranial flap for defects up to a maximum 7x12 cm (5).

Tissue expanders are frequently used up to 400 ml capacity, and local flaps. Today methods of free transfer of microvascular flaps have been accepted as the standard for reconstruction of larger defects of the scalp. Miller and coworkers carried out the first successful replantation of a completely avulsive scalp by microvascular anastomoses (6). McClean and Buncke performed successful reconstruction of the scalp by free microvascular transfer from the omentum (7). A myocutaneous free microvascular flap of latissimus dorsi muscle was first successfully used to cover a scalp defect as early as 1978 (8). Today a whole range of free microvascular flaps is used in reconstructive surgery for treatment of scalp and calvaria defects, such as: rectus abdominis, forearm flap, scapular flap, etc.

Autologous and alloplastic materials are used for reconstruction of defects of the calvaria. The majority of authors prefer autologous materials because of the low incidence of infection and loss of such material in the reconstruction of the calvarial contour (9,10). Of the autologous materials rib and calvarial bone graft from the parietal region are used for larger defects (11). For reconstruction of smaller defects bone paste in combination with elastomer or fibrin is used (5). Of the alloplastic materials methylmethacrylate or bone cement are most frequently used. Depending on

the wound contamination alloplastic materials have a higher incidence of infection, i.e. 3.7 - 37%, than autologous materials, which is their greatest drawback (12).

PATIENTS AND METHODS

During a five-year period, from 2004 to 2008, 21 patients (12 men and 9 women) underwent reconstructive surgery for scalp and calvaria defects at the Department of Plastic Surgery, "Dubrava" University Hospital (Table 1).

All the patients were monitored continually by regular check-ups. The mean age of the patients was 61 years, the youngest was aged 14 years and the oldest one was 86 years of age.

The patients were divided into groups with regard to etiology, extent and depth of the defect, type of reconstructive operation, number of surgical procedures per patient, local complications and duration of hospitalization (Table 1, 2).

In 12 patients, the defect was of tumor etiology (malignant 10, benign 2) and in 9 patients the defect was caused by traumatic injury (fresh 6, old 3). With regard to size, 14 defects were less than 6 cm in diameter, 7 were 6-10 cm and 5 were more than 10 cm in diameter. There were 15 defects of incomplete thickness, 12 of full thickness and 5 involved

Table 1.

PATIENTS AND DISEASE CHARACTERISTICS

	Number of patients
Year	
2004	2
2005	2
2006	4
2007	4
2008	9
Defects etiology	
Tumors	
Malignant	10
Benign	2
Traumatic	
Fresh	6
Old	3
Size of defects (diameter cm)	
< 6	14
6 – 10	7
> 10	6
Depth of defects	
Incomplete	15
Complete	12
Bone	5

Table 2.

SURGICAL PROCEDURES

Reconstructive op. / Total performed	No. of procedures per patient			Complications			Hospitalization / days
	one	two	three	necrosis	thrombosis	recurrence	
Thiersch 5	5	0	0	0	0	0	2.8
Loc. flap 17	17	3	1	2	0	3	15.2
Free flap 5	5	1	3	2	2	1	56.2

the bone. Autotransplantation of the skin of incomplete thickness was used to reconstruct 5 defects. A local flap was used to reconstruct 17 defects and 5 defects were reconstructed with a free myocutaneous or fasciocutaneous microsurgical flap.

In case of acutely traumatized patients the scalp defect and/or calvaria defect was treated by primary or primarily postponed procedure.

RESULTS

The results of this study show (Table 1) a trend towards an increase in the number of patients with defects of the scalp and calvaria, and a higher incidence in the male population. The majority of the defects were of tumor etiology, and malignant extra- or intracranial tumors were most frequent. Of the traumatic defects the majority of the patients had defects of the scalp and calvaria, caused by thermal injuries (Table 1). With regard to the size of the defects, smaller defects were predominant and moderately large and large defects occurred equally. Most of the injuries did not involve the full thickness of the scalp (Table 1). For reconstruction of smaller and moderately large defects of the scalp the techniques of local flaps, random flaps or axial flaps were used (one, two or three flaps), autotransplantation of the skin of incomplete thickness according to Thiersch, and for large defects free microvascular flaps were used (latissimus dorsi myocutaneous, radial forearm fasciocutaneous, VRAM and replantatio avulsed scalp). In two patients with acute deep scalp burns and involved calvaria, excising of necrotic bone of the tabula externa calvaria was performed prior to reconstruction of the defect by local flap. In three patients craniotomy was performed because of a local advanced malignant process and infiltration of the bone, and cranioplasty was done with Methylmethacrylate. Reconstruction of the dura with

fascia lata was carried out in one patient. The number of surgical procedures per patient, duration of hospitalization and also growth complications in the group of patients with defects of incomplete thickness reconstructed by autotransplantation of skin, according to patients with larger defects of the scalp and/or calvaria reconstructed with free flaps. Complications were satisfactorily resolved by repeated operations, so that no complete loss of any local or free flap occurred. One patient died 18 months after reconstruction of a defect of the scalp and calvaria latissimus by muscular flap, due to progression of a malignant process.

DISCUSSION

The study shows an increase in the incidence of defects of the scalp and calvaria during the five-year period, both of tumor (mainly malignant) and traumatic etiology (mainly fresh burns). The majority of the defects were smaller than 6 cm in diameter and most involved incomplete thickness of the affected scalp. For reconstruction of defects of incomplete thickness, apart from AT skin according to Thiersch, the majority of the defects, even large defects (>10 cm in diameter) of full thickness with exposed or involved bone calvaria, were reconstructed by local flaps: random, one, two or three axial flaps and Juri flap (Figure 1). Excision of the tabula externa calvaria was performed in two patients with deep burns and necrotic bone. In two patients prior surgical procedure comprised implantation of a tissue expander. In two patients no complications occurred apart from marginal necrosis of the flap immediately after the operation. During subsequent monitoring local recurrence of a malignant tumor occurred in three patients. The relatively short hospitalization, few complications and surgical procedures under-

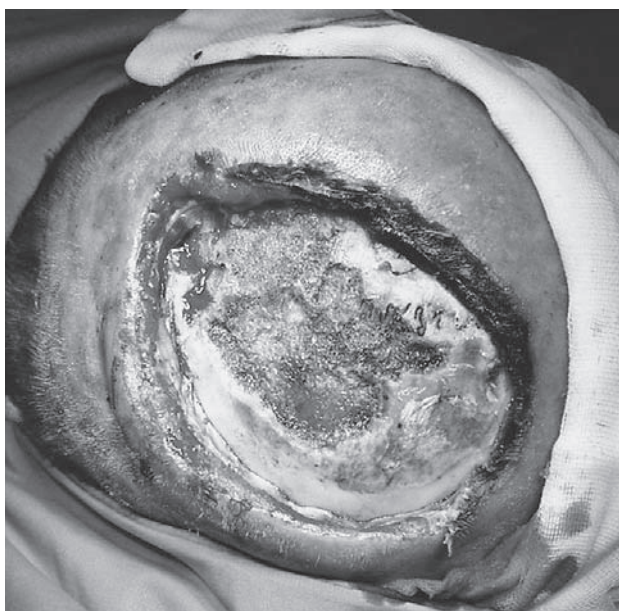


Figure 1a. Complete scalp defect. Preoperative view.

taken indicate that the chosen methods of reconstruction of scalp and calvaria defects were successful. Today local flaps are the standard method of reconstruction of such defects and are recommended by numerous authors, who have published the results of their experimental studies (13,14). Our experience and successful results corroborate the opinion of Guerissi et al. who reported successful treatment of large scalp defects of up to 60% of the surface by the technique of local flaps and considered them to be a simple and safe method of reconstruction. They had no postoperative complications. Defects of the calvaria after resection were not primarily reconstructed (15). Mandell et al. and Tepavicharova et al. have good experiences with scalp flaps in reconstruction of large defects (10 %- 60 % of the scalp surface area). There were no postoperative complications (16, 17). In the case of acute deep burns we treated defects of the scalp and calvaria in a classical way, by necrectomy of the soft tissues and resection of the necrotic bones prior to covering by a local flap. Bizhko et al. performed necrectomy of the soft tissues only, without resection of the bones, and reconstructed scalp defects by axial flap in 22 patients with deep scalp and calvaria burns. Bone regeneration was satisfactory and confirmed by radiography (18). We reconstructed large defects of the scalp and calvaria by free microvascular

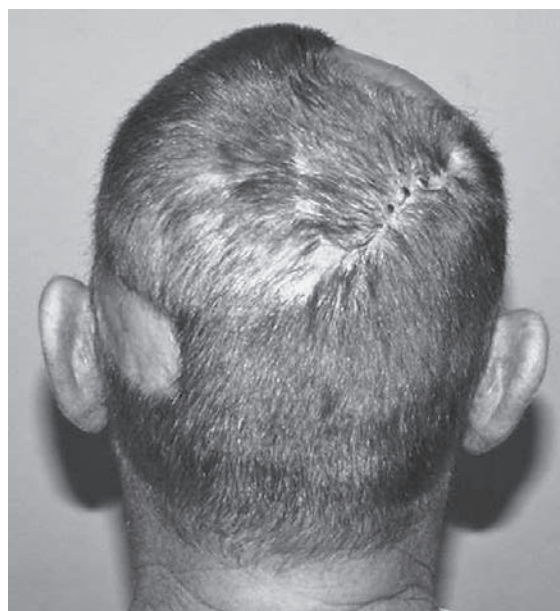

Figure 1b. Defect reconstructed with local flap. Postoperative view.

flaps (Figure 2), which are today accepted as standard methods of reconstruction, even for smaller defects. Duration of hospitalization and the number of surgical procedures were highest in these groups of patients. The reason for this was large tumor or traumatic destruction of the scalp and bone, poor general condition of the patient and greater number of postoperative complications. Thrombosis of microvascular anastomosis immediately postoperatively and partial necrosis of the flap during the subsequent course, were complications in our patients which were resolved by additional surgical procedures, and thus no complete loss of any flap occurred. In one patient reconstruction of the dura fascia latom was necessary and in three patients craniotomy was performed because of a local advanced malignant process and bone infiltration. Cranioplasty was performed with Methylmethacrylate. One patient died 18 months after reconstruction of the scalp and calvaria by latissimus muscle flap, because of progression of a malignant process. Similar results have been published by Ioannides et al., who used latissimus myocutaneous and radial forearm fasciocutaneous flat to reconstruct large defects of the scalp and calvaria in 31 patients, with the loss of one flap and fatal outcome in one patient due to postoperative meningitis (14). Lutz et al used free

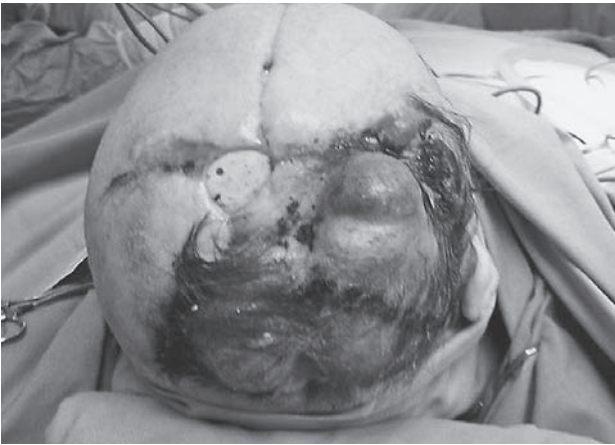

Figure 2a. Scalp defect caused by tumors. Preoperative view.

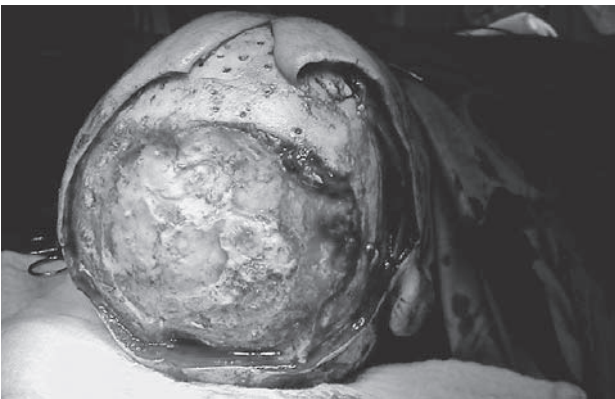

Figure 2b. Operative view. Bone involved.

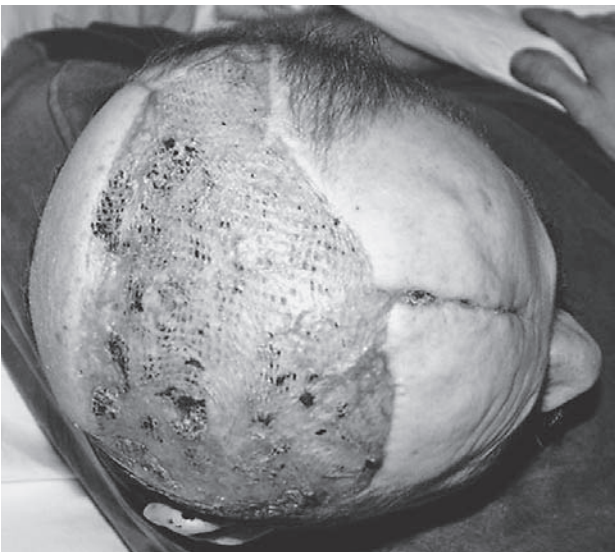


Figure 2c. Postoperative view. Scalp and calvaria defect reconstructed with bone cement and covered with latissimus muscle free flap.

flaps to reconstruct defects of the scalp and calvaria of 5 - 20 cm in diameter. They were unsuccessful in the case of only two patients out of a total of 29. They suggest that the size of the defect is not conditional for reconstruction with free flaps, which was demonstrated in their study (19). With regard to the results Hussussian and co-workers the free tissue transfer was successful in all 32 patients. There was a 59 percent overall complication rate with 32 percent of patients requiring a secondary surgical procedure. Most of the complications were wound-healing complications and there were two cases of vein thrombosis, these were salvaged by revision, and no flaps were lost (20). Bone cement (Methylmethacrylate) was used for reconstruction of the calvarial contour in the patients in this study, which proved to be a good choice with regard to the size of the reconstructed defects and absence of postoperative infections. Mehrara et al. and Abo Sedira et al. used bone cement successfully with minimal morbidity in a majority of patient (21,22). Due to the greater incidence of infection, depending on the wound contamination, some authors do not recommend the use of alloplastic materials in the reconstruction of calvaria defects (12).

CONCLUSION

Today, a whole range of operative techniques for reconstruction can be used to successfully treat defects of the scalp and calvaria. Local flaps are most frequently used for reconstruction of smaller and moderately large defects, and free microvascular tissue transfer for reconstruction of large defects. Successful treatment of the scalp and calvaria defects depends on accurate indication and the choice of an appropriate reconstruction technique.

Because of the increased incidence of scalp and calvaria defects today, specific anatomical structure of the scalp, and consequently the surgical technique, special care should be taken and more surgeons trained to successfully treat patients who occasionally also have serious psychological problems for esthetic reasons.

REFERENCES

1. Stuzin JM, Zide BM. Grabb and Smith's Plastic Surgery (4th ed.). Boston: Little, Brown, 1991;401.

2. Dingman RO, Argenta LC. The surgical repair of traumatic defects of the scalp. *Clin Plast Surg* 1982; 9:131-44.
3. Orticochea M. New three-flap scalp reconstruction techniques. *Br J Plast Surg* 1971; 24:184-8.
4. Argenta LC, Friedman RJ, Dingman RO, Duus EC. The versatility of pericranial flaps. *Plast Reconstr Surg* 1985; 76:695-702.
5. Terranova W. The use of periosteal flaps in scalp and forehead reconstruction. *Ann Plast Surg* 1990; 24: 450-6.
6. Miller GD, Anstee EJ, Snell JA. Successful replantation of an avulsed scalp by microvascular anastomosis. *Plast Reconstr Surg* 1976;58:133-6.
7. McClean D, Buncke H. Autotransplant of omentum to a large scalp defect with microsurgical revascularisation. *Plast Reconstr Surg* 1972;49:268-74.
8. Maxwell P, Stueber K, Hoopes J. A free latissimus dorsi myocutaneous flap. *Plast Reconstr Surg* 1978;62: 462-6.
9. McCarthy JG, Zide BM. The spectrum of calvarial bone grafting: Introduction of the vascularized calvarial bone flap. *Plast Reconstr Surg* 1984;71:10-8.
10. Munro I, Guyuron B. Split rib cranioplasty. *Ann Plast Surg* 1981;7:341.
11. Pensler J, McCarthy JG. The calvarial donor site: An anatomic study in cadavers. *Plast Reconstr Surg* 1985; 75:648-51.
12. Rish B, Dillon J, Meinosh D. Cranioplasty: A review of 1070 cases of penetrating head injury. *Neurosurgery* 1979;4:381-5.
13. Mustoe TA, Corral CJ. Soft tissue reconstructive choices for craniofacial reconstruction. *Clin Plast Surg* 1995; 22(3):543-54.
14. Ioannides C, Fossion E, McGrouther AD. Reconstruction for large defects of the scalp and cranium. *Cranio-maxillofac Surg* 1999;27(3):145-52.
15. Guerrissi JO. Reconstruction of large defects in the scalp with fasciocutaneous flaps. *Scand Plast Reconstr Surg* 1999;33(2):217-24.
16. Mandell DL, Genden EM, Biller HF. Reconstruction of large defects in the scalp with fasciocutaneous flaps. *Scand Journal of Plastic and Reconstr and Hand Surg* 1999;33(2):217-24.
17. Tepavicharova-Romanska P, Zaiakova I, Iankov D, et al. Reconstruction of large defects of the scalp with local fasciocutaneous flaps. *Khirurgiia(Sofia)* 2004;60 (6):26-9.
18. Bizhko IP, Slesarenko SV. Operative treatment of deep burns of the scalp and skull. *Burns* 1992; 18(3):220-3.
19. Lutz BS, Wei FC, Chen HC, Lin CH, Wei CY. Reconstruction of scalp defects with free flaps in 30 cases. *Br Plast Surg* 1998; 51(3):186-90.
20. Hussussian CJ, Reece GP. Microsurgical scalp reconstruction in the patient with cancer. *Plast Reconstr Surg* 2002; 109(6):1828-34.
21. Mehrara BJ, Disa JJ, Pusuc A. Scalp reconstruction. *Surg Oncol* 2006; 1:94(6):504-8.
22. Abo Sedira M, Amin AA, Riffat MA, et al. Locally advanced tumors of the scalp: Egyptian National Cancer Institute experience. *Egypt Natl Canc Inst.* 2006;18(3): 250-7.

Author's address: Zvonimir Zore, M.D., "Sestre Milosrdnice" University Hospital, University Hospital for Tumors, Department of Surgical Oncology, Ilica 197, HR-10000 Zagreb, Croatia; E-mail: zore.zvonimir@gmail.com