

## PLEURAL MESOTHELIOMA: UNEXPECTED FINDING IN A YOUNG MAN

Raza Ullah<sup>1</sup>, Imranullah Khan<sup>2</sup>, Shahida Naz<sup>3</sup>, Aamir Ahmad<sup>4</sup>, Haleema<sup>5</sup>

### ABSTRACT

*Pleural mesothelioma is the disease of the elderly, usually in the seventh decade of life. Asbestos exposure is the most common finding among these patients. Other causes include a simian virus, radiation exposure, genetic predisposition and erionite. Common symptoms include shortness of breath, weight loss, dull achy chest pain on the site of the lesion and anorexia. Pleural effusion is common and video-assisted thoracoscopic (VATS) biopsy is the investigation of choice. pleurectomy, pleuro-pneumonectomy and cisplatin-based therapy are management modalities depending upon the stage of the disease. We are presenting an unusual case of pleural mesothelioma in a young patient with no significant exposure to the causative agent.*

**KEYWORDS:** Malignant Mesothelioma, Young Patient, Pleural Mesothelioma

#### How to cite this article:

Ullah R, Khan I, Naz S, Ahmad A, Haleema. Pleural Mesothelioma: Unexpected Finding In A Young Man. J Gandhara Med Dent Sci. 2022; 9(3): 90-93

#### Correspondence

<sup>1</sup>Raza Ullah, Assistant Professor of Pulmonology, Hayatabad Medical Complex, Peshawar

☎: +92-333-9298991

✉: [dr.raza127@gmail.com](mailto:dr.raza127@gmail.com)

<sup>2</sup>Assistant Professor of Pulmonology, Rehman Medical Institute, Peshawar

<sup>3</sup>Senior Register Dermatology, Pak International Medical College, Peshawar

<sup>4</sup>Specialist Registrar Medicine, Hayatabad Medical Complex, Peshawar

<sup>5</sup>House Officer, Hayatabad Medical Complex, Peshawar

complaints of right-sided chest pain, weight loss and anorexia from the last 6 months. He was on anti-tuberculous therapy based on lymphocytic pleural tape for the last 3 months, without any improvement. On examination, there were decreased breath sounds on the right side with dull percussion notes. He is a teacher by profession with two kids and living in his own house. There was no history of exposure to tuberculosis, radiation, or asbestos. None of his family members was exposed to asbestos. There was no history of malignancy in the family, and he was a non-smoker. X-ray chest was suggestive of right-sided pleural effusion and pleural thickening. CT chest with contrast showed circumferential pleural thickening with nodularity and mediastinal involvement. There was no pleural effusion (fig1).

### INTRODUCTION

Malignant mesothelioma is an insidious neoplasm with a very poor prognosis. It arises from mesothelial surfaces of the pleural cavity, peritoneal cavity, tunica vaginalis, or pericardium. A common cause is asbestos exposure.<sup>1</sup> Other causes include radiation, simian virus infection, erionite and genetics. Common Symptoms include chest pain, dyspnea, cough fatigue and weight loss. Diagnosis is made on histologic examination. A multi-modality management approach needs to be adopted to treat mesothelioma.<sup>2</sup> Treatment in the early stage is pleurectomy or extra-pleural pneumonectomy. In advanced cases, cisplatin-based therapy is tried with inconsistent results.

### CASE REPORT

We are presenting this case with permission from the patient on a consent form. A 30-year-old male patient presented to my clinic with chief

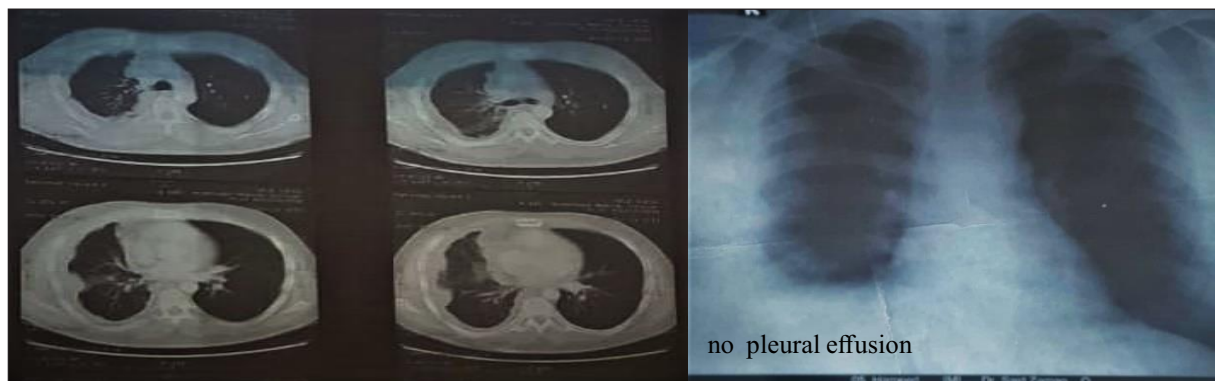


Figure 1: Shown No Pleural Effusion.

He was referred for CT guided biopsy. Histopathology of the specimen showed neoplasm composed of nests of pleomorphic tumor cells.

Immunohistochemical stain is shown in fig.2. Pleural mesothelioma was confirmed.

**Shaukat Khanum Memorial Cancer Hospital & Research Centre**  
 Plot # 5-B, Sector A-2, Office Enclave, Phase - 2, Ferozshah Peshawar - Phone: +92 (91) 5859000 Fax: 92 (91) 5823115  
 Email: info@skhm.org.pk, Website: www.shaukatkhanum.org.pk

**Department of Pathology**

**Histopathology Report** Page 1

VIEW: 21-Jun-2019 05:33:55

|  |  |
|--|--|
| Dept Ref# :<br>MRNO :<br>Name :<br>Age/Sex : 34 Year(s)/Male<br>Phone : 92 0345 9347438, 92 0346 4184559<br>Address : SAKHAKOT MALAKAND, MALAKAND P/A - PAKISTAN | Ordered By :<br>In-house Consultant<br>Report Destination : Main Reception - Path<br>Requested : 12-JUN-2019 15:22:25<br>Specimen Received : 13-JUN-2019 07:18:36<br>Reported : 19-JUN-2019 09:58:31 |
|--|--|

**Spc Nature:** CORE BIOPSY  
**Spc Site:** RIGHT PLEURA  
**History:** Diffuse nodular thickening of right pleura.

**Gross:** Specimen container is labeled with the patient's name and medical record. Received in formalin are three cores measuring 17 mm, 10 mm and 6 mm. The entire specimen is submitted in single block.

**Micro:** Sections show a neoplasm composed of nests of pleomorphic tumor cells.

**IMMUNO/HISTOCHEMICAL STAINS:**

|                     |                    |
|---------------------|--------------------|
| <b>WT1:</b>         | Positive           |
| <b>Cytokeratin:</b> | Positive           |
| <b>Calretinin:</b>  | Positive           |
| <b>BAP1:</b>        | Loss of expression |
| <b>p40:</b>         | Negative           |
| <b>TTF1:</b>        | Negative           |

**Diagnosis:** RIGHT PLEURA, CORE BIOPSY:  
 Suggestive of mesothelioma.


**Note:** Radiological correlation is advised.

**SNOMED:** T-29000      M-09350

Figure 2: Shown Immunohistochemical Stain.

He was referred to Military Hospital-Rawalpindi where his Bone scan was done that was negative for any skeletal metastasis. Decortication standard Pleurectomy along with dissection of the involved

diaphragm was done. The diaphragm was reconstructed with proline mesh. He was started on Pemetrexed and cisplatin and responded very well. He is alive and symptom-free 3 years after diagnosis

|   |                     | <i>Institute of Radiotherapy and Nuclear Medicine (IRNUM)</i> |               |
|--|---------------------|---|---------------|
| <i>University Campus, Peshawar</i>   |                     |   |               |
| <b>PRN:</b>  | 007129/19           | <b>File No.</b>   | NIL           |
| <b>Patient Name:</b>   | Mohammad Hamid Khan | <b>Status:</b>  | Semi Entitled |
| <b>S/O</b>   | Mohammad Wahid      | <b>Entry Date:</b>  | 02-Jul-2019   |
| <b>Age:</b>  | 34 Y                | <b>Contact Nos.:</b>  | 03459347438   |
| <b>Gender:</b>   | Male                | <b>City:</b>  | Malakand      |
| <b>BONE SCAN</b>   |                     |   |               |
| <b>Clinical Features</b>   |                     |   |               |
| Diagnosed case of Mesothelioma   |                     |   |               |
| <b>Procedure</b>   |                     |   |               |
| Bone scan was done 3 hours after i/v injection of Tc-99m MDP. Whole body imaging was carried out with additional static views. |                     |   |               |
| <b>Findings</b>  |                     |   |               |
| The scan reveals normal and symmetrical tracer distribution in the entire skeleton.  |                     |   |               |
| <b>Opinion</b>   |                     |   |               |
| <b>No scan evidence of skeletal metastasis</b>   |                     |   |               |
| <b>Advice</b>  |                     |   |               |

**Figure 3: Bone Scan Report of the Patient.**

## DISCUSSION

Malignant mesothelioma is an uncommon condition with annual new cases of around 3000 in the United States (US).<sup>3</sup> It is an aggressive malignancy and is associated with exposure to asbestos in 50–80% of cases.<sup>4</sup> It usually occurs in the seventh decade of life and is associated with a very poor prognosis.<sup>5</sup> Very few cases of mesothelioma at a young age have been reported up till now. Only 13 patients with confirmed mesothelioma among the pediatric age group have been reported.<sup>6</sup> The male to female ratio is approximately 3:1.<sup>7</sup> Sex distribution among young pleural mesothelioma patients is approximately equal and very much less exposure to asbestos.<sup>8</sup> Our patient also gives no history of exposure to asbestos, the main causing agent of mesothelioma. This difference in causes in young and elderly patients with mesothelioma may be because of genetic reasons, occupational exposure and etiologic agents.<sup>9</sup> Survival in young patients and those not exposed to asbestos have been described to be more favourable than in older people and those exposed to asbestos.<sup>10</sup> Our patient also responded well to treatment and is still alive with almost no symptoms. The literature search also shows the

same findings of good prognosis in young patients with mesothelioma without exposure to asbestos.<sup>11</sup> All these observations suggest the possibilities of different genetic, clinical and histological factors that can have potential effects on prognosis and management. BAP1 mutations and DNA repair genes are less common before 40 years old.<sup>12</sup> Loharamtaweethong et al. reported ALK translocation in a young female patient with peritoneal mesothelioma.<sup>13</sup> Prior to radiation therapy, predisposing germline mutations or factors such as the presence of oncogenic tumor mutations may play a role. Because of the financial issues and lack of easy availability of this facility in this country, we could not go for genetic study. Overall survival in patients with non-asbestos related mesothelioma is better and females are disproportionately longer survivors.<sup>14</sup> Our patient is male and well responded to surgical and chemotherapy intervention. Follow up investigations are normal, and he is back to his usual activity. The simian virus is also considered one of the causes in asbestos non-exposed young patients with mesothelioma. Different mutations are also potential candidates for further research. Although mesothelioma is widely believed to be the

disease of the elderly, the possibility in young patients must be ruled out where signs and symptoms are suggestive of the disease.

**CONFLICT OF INTEREST:** None

**FUNDING SOURCES:** None

## REFERENCES

- Berzenji L, Van Schil P. Multimodality treatment of malignant pleural mesothelioma. *F1000Res* [Internet]. 2018;7:1681.
- Zha L, Kitamura Y, Kitamura T, Liu R, Shima M, Kurumatani N, et al. Population-based cohort study on health effects of asbestos exposure in Japan. *Cancer Sci* [Internet]. 2019;110(3):1076–84.
- Mazurek JM, Syamlal G, Wood JM, Hendricks SA, Weston A. Malignant mesothelioma mortality — United States, 1999–2015. *MMWR Morb Mortal Wkly Rep* [Internet]. 2017;66(8):214–8.
- Spirtas R, Heineman EF, Bernstein L, Beebe GW, Keehn RJ, Stark A, et al. Malignant mesothelioma: attributable risk of asbestos exposure. *Occup Environ Med* [Internet]. 1994;51(12):804–11.
- Vivero M, Bueno R, Chirieac LR. Clinicopathologic and genetic characteristics of young patients with pleural diffuse malignant mesothelioma. *Mod Pathol* [Internet]. 2018;31(1):122–31.
- Moran CA, Albores-Saavedra J, Suster S. Primary peritoneal mesotheliomas in children: a clinicopathological and immunohistochemical study of eight cases. *Histopathology* [Internet]. 2008;52(7):824–30.
- Noone AM, Cronin KA, Altekruse SF, Howlader N, Lewis DR, Petkov VI, et al. Cancer incidence and survival trends by subtype using data from the surveillance epidemiology and end results program, 1992-2013. *Cancer Epidemiology and Prevention Biomarkers*. 2017;26:632–41.
- Teta MJ, Mink PJ, Lau E, Scurman BK, Foster ED. US mesothelioma patterns 1973-2002: indicators of change and insights into background rates. *Eur J Cancer Prev* [Internet]. 2008;17(6):525–34.
- Thomas A, Chen Y, Yu T, Gill A, Prasad V. Distinctive clinical characteristics of malignant mesothelioma in young patients. *Oncotarget* [Internet]. 2015;6(18):16766–73.
- Sugarbaker DJ, Wolf AS, Chirieac LR, Godleski JJ, Tilleman TR, Jaklitsch MT, et al. Clinical and pathological features of three-year survivors of malignant pleural mesothelioma following extrapleural pneumonectomy. *Eur J Cardiothorac Surg* [Internet]. 2011;40(2):298–303.
- Carbone M, Adusumilli PS, Alexander HR Jr, Baas P, Bardelli F, Bononi A, et al. Mesothelioma: Scientific clues for prevention, diagnosis, and therapy. *CA Cancer J Clin* [Internet]. 2019;69(5):402–29.
- Hassan R, Morrow B, Thomas A, Walsh T, Lee MK, Gulsuner S, et al. Inherited predisposition to malignant mesothelioma and overall survival following platinum chemotherapy. *Proc Natl Acad Sci U S A* [Internet]. 2019;116(18):9008–13.
- Loharamtaweethong K, Puripat N, Aonjai N, Sutepvarnon A, Bandidwattanawong C. Anaplastic lymphoma kinase (ALK) translocation in paediatric malignant peritoneal mesothelioma: a case report of novel ALK-related tumour spectrum. *Histopathology* [Internet]. 2016;68(4):603–7.
- Schumann SO, Kocher G, Minervini F. Epidemiology, diagnosis and treatment of the malignant pleural mesothelioma, a narrative review of literature. *J Thorac Dis* [Internet]. 2021;13(4):2510–23.

## CONTRIBUTORS

- Raza Ullah** - Concept & Design; Data Analysis/Interpretation; Drafting Manuscript; Critical Revision
- Imranullah Khan** - Data Acquisition; Critical Revision
- Shahida Naz** - Data Acquisition; Critical Revision
- Aamir Ahmad** - Data Acquisition; Critical Revision
- Haleema** - Data Acquisition; Critical Revision