



## Clinical investigation of the main approaches to exodontics and aesthetic preservation for the dental implant: a concise systematic review

Larissa Galindo Gonçalves<sup>1,2\*</sup>, Welinton Rafael Silva dos Reis<sup>1,2</sup>, Marianna de Paiva Parra<sup>1,2</sup>, Elias Naim Kassis<sup>1,2</sup>

<sup>1</sup> UNORTE - University Center of Northern São Paulo - Dentistry department, Sao Jose do Rio Preto, Sao Paulo, Brazil.

<sup>2</sup> UNIPOS - Post graduate and continuing education, Dentistry department, Sao Jose do Rio Preto, Sao Paulo, Brazil.

\*Corresponding author: Larissa Galindo Gonçalves.

Unorte/Unipós – Graduate and Postgraduate in dentistry, Sao Jose do Rio Preto, Sao Paulo, Brazil.

E-mail: larissa\_galindo@outlook.com

DOI: <https://doi.org/10.54448/mdnt22S318>

Received: 02-11-2022; Revised: 04-26-2022; Accepted: 05-14-2022; Published: 05-31-2022; MedNEXT-id: 22S318

### Abstract

**Introduction:** In the context of tooth extraction and aesthetic care, steps are needed for tooth extraction. Alveolar bone resorption after tooth extraction often leads to situations where the long-term function and esthetic success of dental implant restorations is a challenge. Thus, the Socket shield has been described as an alternative technique to maintain the alveolar ridge in the placement of immediate implants.

**Objective:** Conducted a concise systematic review of key considerations and clinical outcomes of minimally traumatic treatment of tooth extraction and dental implants. **Methods:** The present study followed a concise systematic review model, following the rules of systematic review – PRISMA. The search strategy was performed in the PubMed, Cochrane Library, Web of Science and Scopus, and Google Scholar databases. The present study was carried out from January to March 2022. The quality of the studies was based on the GRADE instrument and the risk of bias was analyzed according to the Cochrane instrument. **Results and Conclusion:** A total of 112 articles were found. A total of 47 articles were fully evaluated and 26 were included in this study. The results suggest that the adjunctive use of connective tissue grafting is not mandatory to achieve successful esthetic results for well-planned immediate implant placement with non-functional immediate provisional restoration in a fresh extraction socket. Still, the success/modified success rate, survival, mean resorption of the oral plate, and patient satisfaction, there were no differences between immediate implants placed with a flap or with an envelope flap of minimal thickness.

**Keywords:** Exodontia. Dental implant. Dental

extraction. Minimally traumatic extraction. Aesthetics.

### Introduction

In the context of tooth extraction and aesthetic care, steps are needed for tooth extraction [1]. All extractions must be performed with precise indication, with defined prosthetic planning, thus avoiding imbalance in the patient's occlusion, swallowing and aesthetics [2]. Furthermore, alveolar bone resorption after tooth extraction often leads to situations where the long-term function and esthetic success of dental implant restorations is a challenge. Socket shield has been described as an alternative technique to maintain the alveolar ridge in the placement of immediate implants [3].

In this sense, rehabilitation with implants requires preservation of the alveolar bone at the implant site and adequate gingival contour, especially in esthetic regions. These requirements can and should be planned from tooth extraction, and for this there are minimally traumatic extraction (MTE) techniques [3]. The conventional extraction technique exerts horizontal movements and/or rotations on the tooth to be extracted enough to break the collagen fibers resulting in bone expansion or fracture of the buccal bone plate, traumatizing the alveolar bone [4,5].

Thus, techniques to enable a less traumatic tooth extraction have been available in recent decades, promoting tooth extraction with preservation of the alveolar bone [6]. In this sense, some techniques emerged with this principle, either with special tweezers or with sophisticated and highly ingenious systems. These new devices perform a traction force in the axial direction of the root of the tooth to be extracted [7].

However, new techniques and instruments for MTE still need to be analyzed, as few studies have evaluated the success rate and limitations of these devices.

In this aspect, some factors are considered decisive for obtaining a positive result in the treatment of implant placement placed immediately in the extraction of the dental socket, such as the preservation of the bone margins of the socket during extraction, the primary stability of the implant in the apical portion of them. along the walls of the socket, careful control of the tissue flap, tight closure adapted to the implant neck and meticulous control of the plaque throughout the healing period [2-4]. Also, the alignment of the implant in relation to the tooth to be restored and the position of the implant head must be located 3 mm apically to the apex of the cement-cement, junction of the adjacent tooth, to allow uniformity of the margin of the cemental junction and accommodation of the abutment and prosthesis subgingivally [5].

In addition, the buccal bone crest is vertically resorbed during the healing process [8]. This resorption process may be a consequence of the decrease in blood supply to the bone plate due to the folding of the mucoperiosteal flap [9]. Another factor to be evaluated after the installation of the immediate implant is the horizontal bone defect, also called gap.

Therefore, the present study performed a concise systematic review of the main considerations and clinical outcomes of minimally traumatic treatment of tooth extraction and dental implants.

## Methods

### Study Design

The present study followed a concise systematic review model, following the rules of systematic review - PRISMA (Transparent reporting of systematic reviews and meta-analysis-<http://www.prisma-statement.org/>).

### Search Strategy and Sources

The search strategy was performed in the PubMed, Cochrane Library, Web of Science and Scopus, and Google Scholar databases. The present study was carried out from January to April 2022.

### Descriptors (MeSH Terms)

The main descriptors (MeSH Terms) used were "Exodontia. Dental implant. Dental extraction. Minimally traumatic extraction. Aesthetics". For greater specification, the description "Minimally traumatic extraction and Aesthetics" for refinement was added during the searches, following the rules of the word PICOS (Patient; Intervention; Control; Outcomes; Study

Design).

### Selection of studies and risk of bias in each study

Two independent reviewers performed research and study selection. Data extraction was performed by reviewer 1 and fully reviewed by reviewer 2. A third investigator decided some conflicting points and made the final decision to choose the articles.

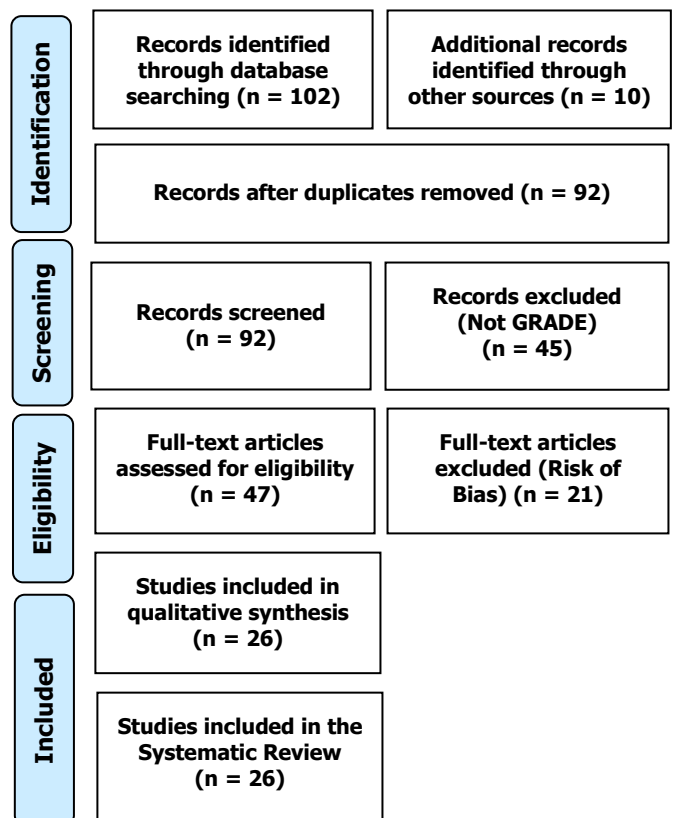
### Study Quality and Bias Risk

The quality of the studies was based on the GRADE instrument and the risk of bias was analyzed according to the Cochrane instrument.

## Results and Discussion

A total of 112 articles were found. Articles that presented low-quality scientific evidence according to GRADE, as well as articles that showed research biases, such as a low number of participants and dubious results were also excluded. A total of 47 articles were fully evaluated and 26 were included in this study. A total of 45 articles were excluded because they did not meet the GRADE classification, and 21 articles were excluded because of the risk of bias (Figure 1).

Figure 1. Eligibility of studies.



As a result, it became evident that the tooth extraction process promotes a series of reparative

processes involving hard tissues (alveolar bone) and soft tissues (periodontal, ligaments and gingiva) [10]. The bone healing process involves the inflammatory, reparative and remodeling phases. In this regard, a study reviewed the medium and long-term clinical results of the socket shield technique in human studies. The studies analyzed showed lower rates of horizontal and vertical alveolar bone resorption, better maintenance of the buccal plate, less marginal bone loss and better esthetic results than the simple placement of immediate implants. However, a lack of homogeneity was found in the methods of evaluation of the different results, surgical procedures and prosthetic management [3].

Also, a multicenter randomized trial compared the 1-year esthetic results of flapless single implants placed in fresh extraction sockets with bone replacement and immediate provisional restoration with or without connective tissue grafting. A total of 59 of 60 patients screened by eight private practices in northern Italy met the inclusion criteria. Of the 59 randomized patients (test group = 31, control group = 28), there was no statistically significant difference between the two groups. One implant failure was recorded in each group. Therefore, the results suggest that the adjunctive use of connective tissue graft is not mandatory to achieve successful esthetic results for a well-planned immediate implant placement with non-functional immediate provisional restoration in a fresh extraction socket [11].

In this aspect, dental implant therapy is a common clinical treatment for missing teeth, however, the aesthetic result is not as satisfactory as expected in some cases. Poor esthetic results are caused by inadequate preparation of hard and soft tissues in this area before treatment. Thus, the socket shield technique can be an alternative for a desirable aesthetic result in dental implant treatments. In this sense, most published studies reported implant survival without complications (90.5%), with follow-up for more than 12 months [12].

Also, a randomized, controlled, single-blind, single-center clinical trial selected adult participants with a need for extraction of a single tooth in the anterior region of the maxilla and premolar. In total, 28 participants were included in the study. Total scores were similar in the control and test groups. The implant survival and success rate after 12 months was 100%. The buccal plate thickness at 12 months post-load was 2.78 mm in the control group and 2.54 mm in the test group, so there was no statistically significant difference between them. The majority of patients in both groups responded 'positive' on the patient satisfaction questionnaire and on the visual analogue scale. Therefore, the success/modified success rate, survival,

mean resorption of the buccal plate and patient satisfaction, there were no differences between immediate implants placed with a flap or with an envelope flap of minimal thickness [13].

Besides, a case report presented the treatment of a 33-year-old patient with generalized genetic microdontia of permanent teeth. Treatment has been multidisciplinary, often using orthodontics and implant dentistry. However, adult patients with generalized microdontia do not benefit from these treatments, so the combination of adhesive dentistry, endodontics, and removable dentures remains a therapeutic alternative to consider. A feature of this treatment was the use of general anesthesia for endodontic treatments and extraction. In-office CAD/CAM and adhesive dentistry have reduced office time and preserved healthy dental tissue [14].

### **Minimally Traumatic Extraction (MTE) and Aesthetics**

All extractions must be performed with precise indication, due to defined prosthetic planning. Also, they should be as painless, safe, and comfortable as possible. Thus, new management and extraction techniques have been tested and used [1,2].

In this sense, in dental implant therapy, the need to preserve as much alveolar bone as possible is of great importance. The placement of implants right after extraction has been much discussed in recent years, due to persistent clinical failures and also the buccal bone loss caused by the extraction itself. These challenges need to be overcome and new technologies are emerging to meet these needs [3]. In particular, when the rehabilitation with implants is in an esthetic region, the procedure requires greater care and becomes more complex, in addition to generally having a higher expectation from the patient [4].

One of the alternatives to MTE is the use of membranes and grafts, used to preserve or recover bone volume after tooth extraction, either at the height or width of the alveolar crest, as well as to compensate for any type of bone loss due to trauma [15]. However, these techniques have the disadvantage of increasing the cost, morbidity, and treatment time, in addition to making it impossible to place implants with immediate loading [16].

In addition, another method found in the literature that enters the context of minimal bone intervention is tooth exfoliation with orthodontic elastics. The method offers a gradual removal of the tooth and is more conservative than the dental extractor, however, like the grafting and membrane techniques, it has the disadvantage of requiring a longer treatment time, with an average extraction time of six weeks [16,17]. For

patients using bisphosphonates for TMS, it appears to decrease the severity of postoperative complications, as bone loss is reduced with this technique [16,18].

In this context, the various TMS techniques have as their main objective the preservation of the buccal alveolar bone and the maintenance of the gingival contour after extraction. For example, have the periostomes, bivers blade, and dental extractors [19-22]. In addition, tooth extractors perform the extraction in the vertical direction, promoting an MTE [23-25]. In this sense, the main indications for dental extractors are when immediate implants will be performed, especially in esthetic areas and fractured teeth below the gingival margin, because with the use of the screw inserted in the residual root, flaps and osteotomies can be avoided. Additionally, dental extractors can be used on any multirooted or single-rooted tooth that is not in the context of contraindications, including fractured roots, non-retained tooth extractor screw, hypercementosis, root divergence in multirooted teeth, and root lacerations [26].

## Conclusion

The results suggest that the adjunctive use of connective tissue grafting is not mandatory to achieve successful esthetic results for well-planned immediate implant placement with non-functional immediate provisional restoration in a fresh extraction socket. Still, the success/modified success rate, survival, mean resorption of the buccal plate, and patient satisfaction, there were no differences between immediate implants placed with a flap or with an envelope flap of minimal thickness.

## Acknowledgement

Not applicable.

## Funding

Not applicable.

## Data sharing statement

No additional data are available.

## Conflict of interest

The authors declare no conflict of interest.

## Similarity check

It was applied by Ithenticate@.

## About the License

© The authors (s) 2021. The text of this article is open access and licensed under a Creative Commons

Attribution 4.0 International License.

## References

1. Juodzbaly G, Stumbras A, Goyushov S, Duruel O, Tözüm TF. Morphological Classification of Extraction Sockets and Clinical Decision Tree for Socket Preservation/Augmentation after Tooth Extraction: a Systematic Review. *J Oral Maxillofac Res.* 2019 Sep 5;10(3):e3. doi: 10.5037/jomr.2019.10303. PMID: 31620265; PMCID: PMC6788426.
2. Krasny M, Krasny K, Kamiński A. Aesthetic and functional restoration of the dental arch continuity in difficult cases of impacted teeth within the frontal segment. *Cell Tissue Bank.* 2021 Jul 14. doi: 10.1007/s10561-021-09943-7. Epub ahead of print. PMID: 34263377.
3. Sáez-Alcaide LM, González Fernández-Tresguerres F, Cortés-Bretón Brinkmann J, Segura-Mori L, Iglesias-Velázquez O, Pérez-González F, López-Pintor RM, Torres García-Denche J. Socket shield technique: A systematic review of human studies. *Ann Anat.* 2021 Nov;238:151779. doi: 10.1016/j.aanat.2021.151779. Epub 2021 Jun 1. PMID: 34087383.
4. Londono J, Ghasemi S, Lawand G, Dashti M. Evaluation of the golden proportion in the natural dentition: A systematic review and meta-analysis. *J Prosthet Dent.* 2021 Sep 3:S0022-3913(21)00415-7. doi: 10.1016/j.prosdent.2021.07.020. Epub ahead of print. PMID: 34489087.
5. Saadoun AP. Anterior Maxillary Growth in Implantology: Complications, Management, and Prevention. *Compend Contin Educ Dent.* 2021 Sep;42(8):e1-e4. PMID: 34433284.
6. Muska, E. et al. Atraumatic vertical tooth extraction: a proof of principle clinical study of a novel system. *OralMaxillofac. Surg., Basel,* 2013, v. 116, n. 5, p.303-310.
7. Hornig, H. P.; Offermann, T. Implant preparation: atraumatic tooth extraction using easy X Trac system tooth extractor. *Dent. Products Report,* 2005, [S. l.], v. 7, no. 1, p. 68-69.
8. Adell R, Lekholm U, Rockler B, Branemark PI. A 15-year study of osseointegrated implants in the treatment of the edentulous jaw. *Int J Oral Surg.* 1981 Dec; 10(6):387-416.
9. Kois JC, Kan JY. Predictable peri-implant gingival aesthetics: surgical and prosthodontic rationales. *Pract Proced Aesthet Dent.,* 2001 Nov-Dec;13(9):691-8.

10. Farina, R.; Trombelli, L. Wound healing of extraction sockets. *Endod. Topics*, Oxford, 2011, v. 25, no. 1, p. 16-43.
11. Ferrantino L, Camurati A, Gambino P, Marzolo M, Trisciuglio D, Santoro G, Farina V, Fontana F, Asa'ad F, Simion M. Aesthetic outcomes of non-functional immediately restored single post-extraction implants with and without connective tissue graft: A multicentre randomized controlled trial. *Clin Oral Implants Res.* 2021 Jun;32(6):684-694. doi: 10.1111/clr.13733. Epub 2021 Mar 24. PMID: 33638216.
12. Ogawa T, Sitalaksmi RM, Miyashita M, Maekawa K, Ryu M, Kimura-Ono A, Sukanuma T, Kikutani T, Fujisawa M, Tamaki K, Kuboki T. Effectiveness of the socket shield technique in dental implant: A systematic review. *J Prosthodont Res.* 2022 Jan 11;66(1):12-18. doi: 10.2186/jpr.JPR\_D\_20\_00054. Epub 2021 Mar 9. PMID: 33692284.
13. Rupchandani R. Do immediately placed implants have better outcomes when placed with a minimal split-thickness envelope flap? *Evid Based Dent.* 2021 Dec;22(4):126-127. doi: 10.1038/s41432-021-0215-x. Epub 2021 Dec 16. Erratum in: *Evid Based Dent.* 2022 Mar;23(1):5. PMID: 34916634.
14. Batisse C, Cousson PY, Nicolas E, Bessadet M. Aesthetic and Functional Rehabilitation of Patients with Genetic Microdontia: A Multidisciplinary Approach. *Healthcare (Basel).* 2022 Mar 5;10(3):485. doi: 10.3390/healthcare10030485. PMID: 35326963; PMCID: PMC8952258.
15. Salomão, M; Alvarez, F. K. Siqueira, J. T. T. Regeneração óssea guiada em defeitos extensos pós-exodontias utilizando membrana exposta ao meio bucal. *ImplantNews*, São Paulo, 2010, v. 7, n. 6, p. 753-759.
16. Oghli, A. A.; Steveling, H. Ridge preservation following tooth extraction: a comparison between atraumatic extraction and socket seal surgery. *Quintessence Int.*, Berlin, 2009, v. 41, no.7, p. 605-609.
17. Regev E, Lustmann, J.; Nashef, R. Atraumatic teeth extraction in bisphosphonate-treated patients. *J. Oral Maxillofac. Surg.*, Philadelphia, 2008, v.66, no. 6, p. 1157-1161.
18. Schropp, L. et al. Bone healing and soft tissue contour changes following single-tooth extraction: a clinical and radiographic 12-month prospective study. *Int. J. Periodontics Restor. Dent.*, Chicago, 2003, v. 23, no. 1, p. 213-323.
19. Dym H, Weiss, A. Exodontia: Tips and Techniques for Better Outcomes. *Dent. Clin. N. Am.*, New York, 2012, v. 56, no.1, p. 245-266.
20. Oliveira AC. et al. Implante imediato unitário em função imediata – relato de caso. *RFO UPF*, Passo Fundo, 2008, v. 13, n. 1, p. 70-74.
21. Babbush, C. A. A. New atraumatic system for tooth removal and immediate implant restoration. *Implant Dent.*, Baltimore, 2007, v. 6, no.2, p. 139-145.
22. Meneses DR. Exodontia atraumática e previsibilidade em reabilitação oral com implantes osseointegráveis: relato de casos clínicos aplicando o Sistema Brasileiro de Exodontia Atraumática Xt Lifting®. *Rev. Port. Estomatol. Cir. Maxilofac.*, Lisboa, 2009, v. 50, n. 1, p. 11-17.
23. Jayme S J. et al. Análise 3D por elementos finitos e descrição de dois casos clínicos sobre o uso de extrator dentário vertical para diminuir o trauma ósseo. *ImplantNews*, São Paulo, 2013, v. 10, n.2, p. 193-200.
24. Paolantonio M, Dolci M, Scarano A, d'Archivio D, di Placido G, Tumini V. Immediate implantation in fresh extraction sockets. A controlled clinical and histological study in man. *J Periodontol.* 2001 Nov; 72(11):1560-71.
25. Franceschi RL, Drechsel L, Schuldt Filho G. Application of Immediate Dentoalveolar Restoration in Alveolus Compromised with Loss of Immediate Implant in Esthetic Area. *Case Rep Dent.* 2018 Jun 21;2018:1672170. doi: 10.1155/2018/1672170. PMID: 30034886; PMCID: PMC6033297.
26. Clauser C, Sforza NM, Menini I, Kalemaj Z, Buti J; Collaborators of Accademia Toscana di Ricerca Odontostomatologica (ATRO) IPI Group. Immediate Postextraction Single-Tooth Implants and Provisional Crowns in the Esthetic Area: 2-year Results of a Cohort Prospective Multicenter Study- Patient-Centered Outcomes. *Int J Oral Maxillofac Implants.* 2020 Jul/Aug;35(4):833-840. doi: 10.11607/jomi.7203. PMID: 32724938.

