



# Major clinical results of virtual zygomatic implant and assessment of the risk of bias: a systematic review

Lucas Furtado<sup>1,2,3</sup>, Natália Roberta Martin<sup>1,2,4</sup>, Régis Manzini<sup>1,2\*</sup>

<sup>1</sup> UNORTE - University Center of Northern São Paulo - Dentistry department, Sao Jose do Rio Preto, Sao Paulo, Brazil.

<sup>2</sup> UNIPOS - Post graduate and continuing education, Dentistry department, Sao Jose do Rio Preto, Sao Paulo, Brazil.

<sup>3</sup> Dr. Lucas Furtado Clinic, Sao Jose do Rio Preto, Sao Paulo, Brazil.

<sup>4</sup> Ms Odontologia, Sao Jose do Rio Preto, Sao Paulo, Brazil.

\*Corresponding author: Prof. Régis Manzini, Unorte/Unipos - Post graduate and continuing education, Dentistry department, Sao Jose do Rio Preto, Sao Paulo, Brazil. E-mail: r01manzini@gmail.com  
DOI: <https://doi.org/10.54448/mdnt22S319>

Received: 02-13-2022; Revised: 04-27-2022; Accepted: 05-18-2022; Published: 05-31-2022; MedNEXT-id: e22S319

## Abstract

**Introduction:** In the context of implantology and severe resorption, zygomatic implants (ZI) are indicated and the procedures can be completed with the placement of a custom-made provisional prosthesis, reducing surgical time and optimizing results. Digital (virtual) optimizations for the ZI were developed in computerized radiology machines that allowed improvements in diagnostic and therapeutic tools.

**Objective:** It was carried out a systematic review of the main considerations and clinical outcomes of using digital tools for the optimization of the virtual zygomatic implant. **Methods:** The rules of the Systematic Review-PRISMA Platform were followed. The research was carried out from January 2022 to April 2022 and developed based on Scopus, PubMed, Science Direct, Scielo, and Google Scholar. The quality of the studies was based on the GRADE instrument and the risk of bias was analyzed according to the Cochrane instrument.

**Results and Conclusion:** A total of 94 articles were found. In total, 62 articles were fully evaluated and 41 were included and evaluated in this study, and of the total of 41 articles, only 14 articles were developed as the main clinical results of the virtual zygomatic implant. Reducing errors and complications is essential if zygomatic implants are to remain a viable treatment alternative, and further research on a guided approach to their placement is encouraged. The surgical guide system showed accuracy for all variables studied and allowed acceptable and accurate implant placement, regardless of the complexity of the case. Thus, the surgical and prosthetic plan, the position, the emergence, the shape of the implants, the position of the provisional prosthesis, the inter-arch relationships,

and the surgical templates were designed in a virtual environment and previously performed by the surgeon in stereolithographic models, allowing the surgical procedure was significantly simplified.

**Keywords:** Zygomatic implant. Virtual zygomatic implant. Quad zygomatic implant. Clinical trials.

## Introduction

In the context of implantology and severe resorption, zygomatic implants (ZI) are indicated and the procedures can be completed with the positioning of a custom-made provisional prosthesis, reducing surgical time and optimizing results [1]. One of the main reasons for the use of ZI is due to the lack of bone in the alveolar crest due to dentoalveolar trauma, traumatic extractions and pathologies such as cancer [2,3].

Thus, the ZI provides remote anchorage for a variety of oral and facial prostheses that contribute to improving the function and quality of life of patients undergoing treatment for maxillary and midfacial tumors [3]. Furthermore, quad-zygomatic implants have been used as a treatment option for patients with severely resorbed maxilla [4]. In this sense, the ZI is an alternative when there is bone loss [5-8]. The ZI has an inclined head, designed to allow the placement of the prosthesis 45 along the axis of the implant, providing an excellent capacity for retention, support and stabilization of the prosthesis [9-12]. ZI is also applied when there is low bone quality and quantity [13].

In this context, bone-implant contact is correlated with implant survival [13-18]. An important variable that alters the zygomatic bone-implant contact is the angle at which the implant is placed [19-21]. Thus, Branemark

et al. [22] introduced a technique called zygomatic fixation. The ZI provides anchorage, as it crosses the maxillary tuberosity, passes through the pyramidal process of the palatine bone and is part of the pterygoid process of the sphenoid bone [23,24].

In this scenario, digital (virtual) optimizations for the ZI were developed in computerized radiology machines that allowed improvements in diagnostic and therapeutic tools. Although ZI surgical guides have been shown to be inaccurate, most clinicians generally perform digital planning and virtual surgery prior to patient intervention [25]. Thus, virtual surgery has advanced significantly in implant dentistry, allowing clinicians to visualize the surgical procedure before performing the intervention on the patient. In addition, virtual surgery provides complementary information that helps to determine the number of implants, the proper implant length and its proper position [25].

In this regard, CAD-CAM technology [26] has helped in the development of minimally invasive surgical techniques guided by intraoral splints [27] or computer-assisted procedures [28-30]. Treatments with conventional implants performed under surgical guides have achieved survival rates similar to conventional procedures [31], providing greater accuracy and precision than previous techniques [32,33].

Therefore, the present study aimed to carry out a systematic review on the main considerations and clinical results of the use of digital tools for the optimization of the virtual zygomatic implant.

## Methods

### Study Design

The rules of the Systematic Review-PRISMA Platform (Transparent reporting of systematic reviews and meta-analysis-[HTTP://www.prisma-statement.org/](http://www.prisma-statement.org/)) were followed.

### Data sources and research strategy

The search strategies for this systematic review were based on the keywords (MeSH Terms): “Zygomatic implant. Virtual zygomatic implant. Quad zygomatic implant. Clinical trials”. The research was carried out in January 2022 to April 2022 and developed based on Scopus, PubMed, Science Direct, Scielo, and Google Scholar. Also, a combination of the keywords with the booleans "OR", "AND", and the operator "NOT" were used to target the scientific articles of interest.

### Study Quality and Bias Risk

The quality of the studies was based on the GRADE

instrument and the risk of bias was analyzed according to the Cochrane instrument.

## Results and Discussion

A total of 94 articles were found. Initially, duplication of articles was excluded. After this process, the abstracts were evaluated and a new exclusion was performed, removing the articles that did not address the theme of this article. In total, 62 articles were fully evaluated and 41 were included and evaluated in this study (Figure 1). And of the total of 41 articles, only 14 articles were developed as the main clinical results of the virtual zygomatic implant.

Figure 1. Flow Chart of Study Eligibility (Systematic Review).

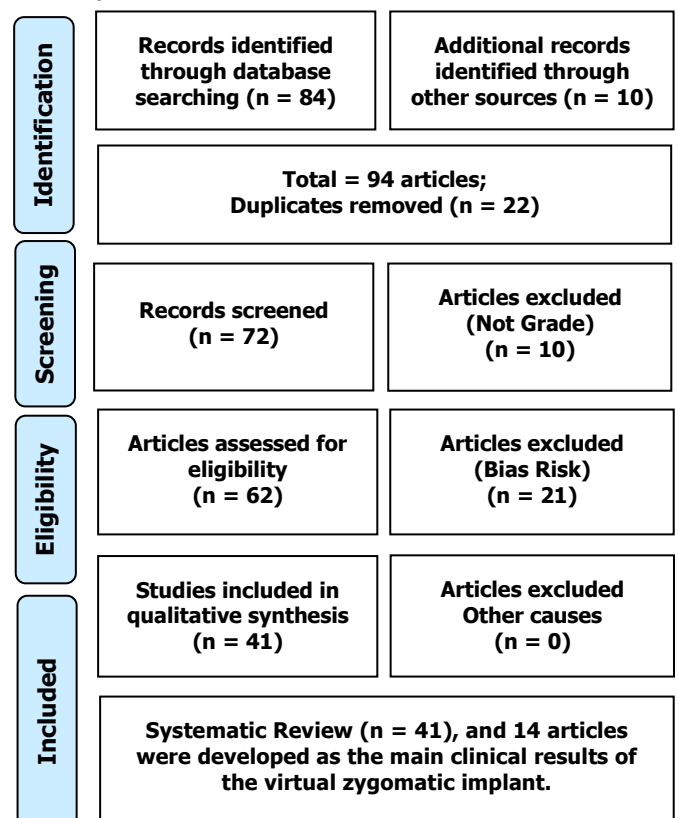
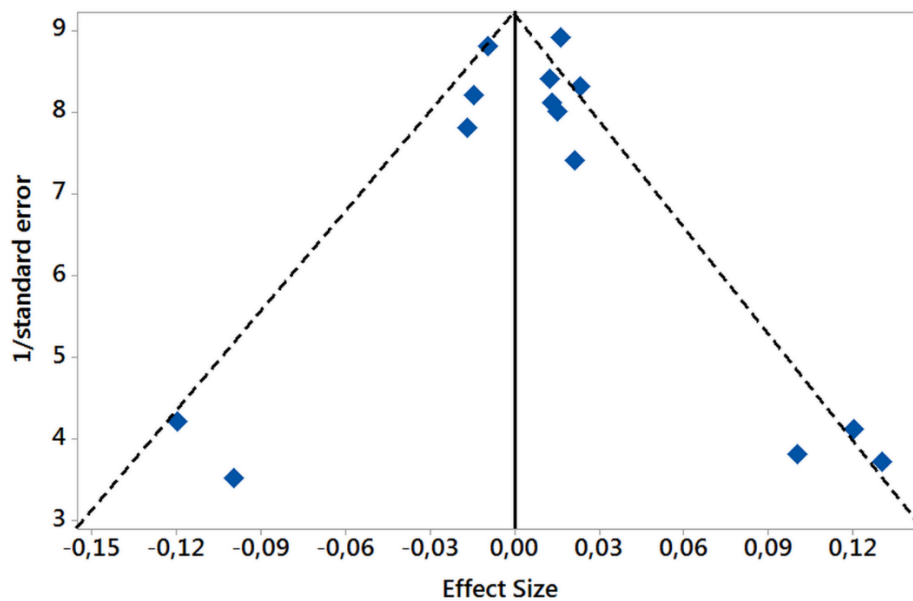


Figure 2 presents the results of the risk of bias in the studies using the Funnel Plot, through the calculation of the Effect Size (Cohen's Test). The sample size was determined indirectly by the inverse of the standard error. The number of clinical studies evaluated was n=14. The graph showed asymmetric behavior, suggesting a significant risk of bias in studies with small sample sizes, which are shown at the bottom of the graph.

This presence of risk of bias is justified by the deficiency in the number of clinical studies with a significant sample size and with methodologies developed as randomized controlled studies.

**Figure 2.** The asymmetric Funnel Plot suggest a risk of bias between the small sample size studies that are shown at the bottom of the graph. N=14 clinical studies.



### Major Clinical Results Of The Virtual Zygomatic Implants (n=14 clinical studies)

Some studies have extended clinical understanding to show the success rate of ZI [1-4, 34-36]. Thus, the study evaluated the anatomical factors that influence the virtual planning of ZI using cone-beam computed tomography scans were performed on 268 maxillary edentulous patients. The concavity sizes found were as follows: 34.95% small, 52.30% medium, and 7.35% large. The mean insertion angle was 43.2 degrees and the mean apical implant anchorage was 9.1 mm. The most frequent implant length was 40mm. Significant differences were found when comparing the different types of concavities to the installation angle, the distance from the apical portion of the implant in contact with the zygomatic bone, and the side-to-side thickness of the zygomatic bone ( $p < 0.001$ ). The medium-sized maxillary sinus concavity had the greatest apical anchorage of the implant (9.7mm) and was the most frequent type (52.30%). Therefore, the zygomatic bone is a viable site for zygomatic implants and the use of specialized implant planning software is an important tool to achieve predictable results for ZI [24].

Also, one study presented a new protocol for ZI placement using pre-surgical planning with computed tomography (CT)/cone-beam (CB) three-dimensional (3D) CT and advanced 3D printing diagnostic technologies. a total of 10 ZI, all placed by the same surgeon. The preoperative positions of the ZI were compared with the postoperative positions of the implants, merging the preoperative and postoperative computed tomography datasets. Deviations from the computerized design to the actual implant positions

ranged from 2 mm to 3 mm with angular deviations ranging from 1.88 to 4.55 degrees. Therefore, ZI placement requires surgical expertise due to the proximity of vital anatomic structures. There was a satisfactory correspondence between the inserted implants and the virtual plane. No adjacent vital anatomical structures were damaged. The new design of the surgical guide allowed the surgeon to visually control the drilling protocol. Positioning the guide close to the entry point of the zygomatic body helped control the drills to the proximity of the exit point, significantly limiting the problems associated with angular deviation [6].

Besides, a human cadaver study evaluated the accuracy of ZI/pterygoid placement using laser-sintered titanium models with custom bone support. A pre-surgical planning was performed using computed tomography scans of each cadaver. The surgical guides were printed with metal laser direct sintering technology. As a result, a total of 40 zygomatic implants and 20 pterygoid implants were inserted in 10 cadavers. The mean deviations between the planned and placed zygomatic and pterygoid implants were respectively (mean  $\pm$  SD):  $1.69^\circ \pm 1.12^\circ$  and  $4.15^\circ \pm 3.53^\circ$  for angular deviation. Linear deviations from the distance:  $0.93 \text{ mm} \pm 1.23 \text{ mm}$  and  $1.35 \text{ mm} \pm 1.45 \text{ mm}$  in the platform depth,  $1.35 \text{ mm} \pm 0.78 \text{ mm}$  and  $1.81 \text{ mm} \pm 1.47 \text{ mm}$  in the plane apical,  $1.07 \text{ mm} \pm 1.47 \text{ mm}$  and  $1.22 \text{ mm} \pm 1.44 \text{ mm}$  in apical depth. Therefore, the surgical guide system showed accuracy for all variables studied and allowed acceptable and accurate implant placement, regardless of the complexity of the case [37].

In addition, a study analyzed a new method through guided surgery for the placement of ZI, using specially designed metallic templates that must be supported by bone. The procedure was completed with the placement of a custom-made provisional prosthesis. A total of 19 patients included in the study had successful implants and prostheses at the time of analysis. Therefore, the surgical and prosthetic plan, the position, the emergence, the shape of the implants, the position of the provisional prosthesis, the interarch relationships and the surgical templates were designed in a totally virtual environment and previously performed by the surgeon in stereolithographic models, allowing the surgical procedure was significantly simplified [38].

In this context, primary reconstruction is usually performed with calvaria grafts, although the use of virtual surgical planning, cutting guides, and patient-specific implants have seen great development in recent years. Thus, a retrospective study was performed in patients diagnosed with intraosseous venous malformation. A total of 8 patients were treated, differentiating two groups according to the technique: four patients were treated using standard surgery with resection and primary reconstruction of the defect with a calvaria graft, and four patients underwent resection and primary reconstruction using surgical planning, cutting guides, models developed with CAD-CAM and PSI (titanium or Polyether-ether-ketone) technology. In the group treated with standard surgery, 75% of patients developed sequelae or morbidities associated with this technique. Operating time ranged from 175 min to 210 min (mean 188.7 min), length of hospital stay ranged from 4 days to 6 days (mean 4.75 days) and postoperative computed tomography 79.75% defect surface. Aesthetic results were excellent in 25% of patients, good in 50% and poor in 25%. In the planned virtual surgery group, 25% had sequelae associated with the surgical treatment. Operation time ranged from 99 min to 143 min, hospital stay ranged from 1 to 2 days and 75% of patients reported excellent results. Postoperative CT scan showed 100% coverage of the defect surface in the planned virtual surgery group. The multi-stage implementation of virtual surgical planning with cutting guides and patient-specific implants has increased reconstructive precision in the treatment of patients diagnosed with intraosseous venous malformation of the zygomatic bone [39].

Yet another retrospective study evaluated the results of simultaneous LeFort I osteotomy and zygomatic/dental implant placement for oral rehabilitation of patients with extremely atrophic/dysmorphic edentulous maxilla. In total, 15 ZI and 33 conventional dental implants were inserted in

eight patients. The mean follow-up of patients was 38.5 months. The implant survival rate was 93.3% for ZI and 100% for conventional dental implants. No intra/postoperative complications were observed. Therefore, simultaneous LeFort I osteotomy associated with zygomatic surgery/dental implant can be considered a valuable treatment option for the rehabilitation of patients with extremely atrophic edentulous maxilla and esthetic problems of the face [40].

Finally, a study analyzed whether digital planning in ZI has any influence on the dimensions and position of the implant, even after performing conventional surgery. A total of 14 ZI were placed in four patients. Pre- and postoperative helical CT scans were performed on each patient to allow comparison between the digital planning and the final position of the implants. Significant differences were observed in the apical three-dimensional deviation with a mean of  $6.114 \pm 4.28$  mm. Only implants placed in the right first molar area reported significant differences for apico-coronal. In addition, implant length greater than 45 mm showed significant differences in oropalatal deviation. Therefore, although planned virtual surgery is a useful tool that helps the clinician to determine the proper number, length and position of the ZI, surgical experience is still mandatory [41].

## Conclusion

Reducing errors and complications is essential if zygomatic implants are to remain a viable treatment alternative, and further research on a guided approach to their placement is encouraged. The surgical guide system showed accuracy for all variables studied and allowed acceptable and accurate implant placement, regardless of the complexity of the case. Thus, the surgical and prosthetic plan, the position, the emergence, the shape of the implants, the position of the provisional prosthesis, the inter-arch relationships, and the surgical templates were designed in a virtual environment and previously performed by the surgeon in stereolithographic models, allowing the surgical procedure was significantly simplified.

## Acknowledgement

Not applicable.

## Ethics approval

Not applicable.

## Informed consent

Not applicable.



## Funding

Not applicable.

## Data sharing statement

No additional data are available.

## Conflict of interest

The authors declare no conflict of interest.

## Similarity check

It was applied by Ithenticate@.

## About the License

© The authors (s) 2022. The text of this article is open access and licensed under a Creative Commons Attribution 4.0 International License.

## References

1. Rigo L, Tollardo J, Giammarinaro E, Covani U, Caso G. Fully Guided Zygomatic Implant Surgery. *J Craniofac Surg*. 2021 Nov-Dec 01;32(8):2867-2872. doi: 10.1097/SCS.00000000000008005. PMID: 34320580.
2. Alterman M, Fleissig Y, Casap N. Zygomatic Implants: Placement Considerations in Implant-Supported Maxillary Prosthesis. *Atlas Oral Maxillofac Surg Clin North Am*. 2021 Sep;29(2):173-183. doi: 10.1016/j.cxom.2021.05.002. Epub 2021 Jul 6. PMID: 34325807.
3. Hackett S, El-Wazani B, Butterworth C. Zygomatic implant-based rehabilitation for patients with maxillary and mid-facial oncology defects: A review. *Oral Dis*. 2021 Jan;27(1):27-41. doi: 10.1111/odi.13305. Epub 2020 Mar 5. PMID: 32048429.
4. Varghese KG, Gandhi N, Kurian N, Daniel AY, Dhawan K, Joseph M, Varghese MG. Rehabilitation of the severely resorbed maxilla by using quad zygomatic implant-supported prostheses: a systematic review and meta-analysis. *J Prosthet Dent*. 2021 Dec 14:S0022-3913(21)00628-4. doi: 10.1016/j.prosdent.2021.11.007. Epub ahead of print. PMID: 34920870.
5. Migliorança RM, Irschlinger AL, Peñarrocha-Diago M, Fabris RR, Javier Aizcorbe-Vicente and Zotarelli Filho IJ. History of zygomatic implants: A systematic review and meta-analysis. *Dent Oral Craniofac Res*, 2019 [doi: 10.15761/DOCR.1000289].
6. Rinaldi M, Ganz SD. Computer-Guided Approach for Placement of Zygomatic Implants: Novel Protocol and Surgical Guide. *Compend Contin Educ Dent*. 2019 Mar;40(3):e1-e4.
7. Wang H, Hung K, Zhao K, Wang Y, Wang F, Wu Y. Anatomical analysis of zygomatic bone in ectodermal dysplasia patients with oligodontia. *Clin Implant Dent Relat Res*. 2019 Apr;21(2):310-316. doi: 10.1111/cid.12731. Epub 2019 Feb 21.
8. Merli M, Moscatelli M, Pagliaro U, Mariotti G, Merli I, Nieri M. Implant prosthetic rehabilitation in partially edentulous patients with bone atrophy. An umbrella review based on systematic reviews of randomised controlled trials. *Eur J Oral Implantol*. 2018;11(3):261-280.
9. Aboul-Hosn Centenero S, Lázaro A, Giralt-Hernando M, Hernández-Alfaro F. Zygoma Quad Compared With 2 Zygomatic Implants: A Systematic Review and Meta-analysis. *Implant Dent*. 2018, Jan 29.
10. Pineau M, Nicot R, Lauwers L, Ferri J, Raoul G. Zygomatic implants in our daily practice. Part II: Prosthetic rehabilitation and effect on quality of life. *Swiss Dent J*. 2018 Sep 10;128(9):694-700.
11. Pineau M, Nicot R, Lauwers L, Ferri J, Raoul G. Zygomatic implants in our daily practice. Part I: Treatment Plan and Surgical Technique. *Swiss Dent J*. 2018 Sep 10;128(9):689-693.
12. Tuminelli FJ, Walter LR, Neugarten J, Bedrossian E. Immediate loading of zygomatic implants: A systematic review of implant survival, prosthesis survival and potential complications. *Eur J Oral Implantol*. 2017;10 Suppl 1:79-87.
13. Molinero-Mourelle P, Baca-Gonzalez L, Gao B, Saez-Alcaide LM, Helm A, Lopez-Quiles J. Surgical complications in zygomatic implants: A systematic review. *Med Oral Patol Oral Cir Bucal*. 2016 Nov 1;21(6):e751-e757.
14. Wu Y, Zhang C, Squarize CH, Zou D. Oral Rehabilitation of Adult Edentulous Siblings Severely Lacking Alveolar Bone Due to Ectodermal Dysplasia: A Report of 2 Clinical Cases and a Literature Review. *J Oral Maxillofac Surg*. 2015, 73(9):1733.e1-12.
15. Lopes, L.F., et al., Placement of dental implants in the maxillary tuberosity: a systematic review. *Int J Oral Maxillofac Surg*. 2015, 44(2): p. 229-38. 21.
16. Ozaki H, Ishikawa S, Kitabatake K, Yusa K, Sakurai H, Iino M. Functional and aesthetic rehabilitation with maxillary prosthesis supported by two zygomatic implants for maxillary defect resulting from cancer ablative surgery: a case report/technique article. *Odontology*. 2015.
17. Takamaru N, Nagai H, Ohe G, Tamatani T,

- Sumida K, Kitamura S, Miyamoto Y. Measurement of the zygomatic bone and pilot hole technique for safer insertion of zygomatic implants. *Int J Oral Maxillofac Surg.* 2015.
18. Monteiro, D.R., et al. Posterior partially edentulous jaws, planning a rehabilitation with dental implants. *World J Clin Cases,* 2015. 3(1): p. 65- 76. 2.
  19. Yates, J.M., et al. Treatment of the edentulous atrophic maxilla using zygomatic implants: evaluation of survival rates over 5-10 years. *Int J Oral Maxillofac Surg.* 2014, 43(2): p. 237-42.
  20. Goiato, M.C., et al. Implants in the zygomatic bone for maxillary prosthetic rehabilitation: a systematic review. *Int J Oral Maxillofac Surg.* 2014, 43(6): p. 748-57. 12.
  21. Fernandez H., et al. Zygomatic implants for the management of the severely atrophied maxilla: a retrospective analysis of 244 implants. *J Oral Maxillofac Surg.* 2014, 72(5): p. 887-91.
  22. Brånemark PI, Gröndahl K, Öhrnell LO, Nilsson P, Petruson B, Svensson B, Engstrand P, Nannmark U. Zygoma fixture in the management of advanced atrophy of the maxilla: technique and long-term results. *Scand J Plast Reconstr Surg Hand Surg.* 2004;38:70-85.
  23. Aparicio C., et al. Zygomatic implants: indications, techniques and outcomes, and the zygomatic success code. *Periodontol.* 2014, 66(1): p. 41-58. 16.
  24. Moro SA, Thomé G, Padovan LEM, da Silva RD, Tioffi R, Fontão FNGK. A zygomatic bone study using virtual dental implant planning software. *J Oral Implantol.* 2021 Jun 5. doi: 10.1563/aaaid-joi-D-20-00149. Epub ahead of print. PMID: 34091691.
  25. Jung RE, Schneider D, Ganeles J, Wismeijer D, Zwahlen M, Hämmerle CH, et al. Computer technology applications in surgical implant dentistry: a systematic review. *Int J Oral Maxillofac Implants.* 2009;24:92–109.
  26. Verstreken K, Van Cleynenbreugel J, Marchal G, Naert I, Suetens P, van Steenberghe D. Computer-assisted planning of oral implant surgery: a three-dimensional approach. *Int J Oral Maxillofac Implants.* 1996;11(6):806–810.
  27. Chrcanovic BR, Oliveira DR, Custódio AL. Accuracy evaluation of computed tomography-derived stereolithographic surgical guides in zygomatic implant placement in human cadavers. *J Oral Implantol.* 2010;36(5):345–355.
  28. Schramm A, Gellrich NC, Schimming R, Schmelzeisen R. Rechnergestützte insertion von Zygomatikumimplantaten (Brånemark-system) nach ablativer Tumorchirurgie. *Mund Kiefer Gesichtschir.* 2000;4(5):292–295.
  29. Wang F, Bornstein M, Hung K, Fan S, Chen X, Huang W, et al. Application of real-time surgical navigation for zygomatic implant insertion in patients with severely atrophic maxilla. *J Oral Maxillofac Surg.* 2018;76(1):80–87.
  30. Tahmaseb A, Wismeijer D, Coucke W, Derksen W. Computer technology applications in surgical implant dentistry: a systematic review. *Int J Oral Maxillofac Implants.* 2014;29(Supplement):25–42.
  31. Walker-Finch K, Ucer C. Five-year survival rates for implants placed using digitally-designed static surgical guides: a systematic review. *Br J Oral Maxillofac Surg.* 2020;58(3):268–276.
  32. Schneider D, Sancho-Puchades M, Mir-Marí J, Mühlemann S, Jung R, Hämmerle A randomized controlled clinical trial comparing conventional and computer-assisted implant planning and placement in partially edentulous patients. Part 4: accuracy of implant placement. *Int J Periodontics Restorative Dent.* 2019;39(4):e111–e122.
  33. Schirotti G, Angiero F, Zangerl A, Benedicenti S, Ferrante F, Widmann G. Accuracy of a flapless protocol for computer-guided zygomatic implant placement in human cadavers: expectations and reality. *Int J Med Robot Comput Assist Surg.* 2015;12(1):102–108.
  34. Chrcanovic BR, Abreu MH. Survival and complications of zygomatic implants: a systematic review. *Oral Maxillofac Surg.* 2013, 17(2): p. 81-93. 17.
  35. Ugurlu, F., et al. Rehabilitation of posterior maxilla with zygomatic and dental implant after tumor resection: a case report. *Case Rep Dent,* 2013. 2013: p. 930345. 4. X.

