



Major cellular and molecular processes and clinical outcomes in bone regeneration for successful dental implantation: a systematic review

Karina da Silva Gonzaga^{1,2*}, Sara Alves Silva^{1,2}, Matheus Maia Munhos^{1,2}, Elias Naim Kassis^{1,2}

¹ UNORTE - University Center of Northern São Paulo - Dentistry department, Sao Jose do Rio Preto, Sao Paulo, Brazil.

² UNIPOS - Post graduate and continuing education, Dentistry department, Sao Jose do Rio Preto, Sao Paulo, Brazil.

*Corresponding author: Karina da Silva Gonzaga.

Unorte/Unipos – Graduate and Postgraduate in dentistry, Sao Jose do Rio Preto, Sao Paulo, Brazil.

E-mail: karinasilva.gonzaga@outlook.com

DOI: <https://doi.org/10.54448/mdnt22S317>

Received: 02-13-2022; Revised: 04-25-2022; Accepted: 04-26-2022; Published: 05-12-2022; MedNEXT-id: e22S317

Abstract

Introduction: In the context of bone regeneration, bone defects still represent a major challenge in oral and maxillofacial clinical and surgical treatment. The biomimetic design of biomaterials by simulating the natural structure and composition of bone tissue has gradually become a point of research interest due to its advantages of simplicity and efficiency. **Objective:** It was to carry out a systematic review on cellular and molecular processes, as well as to present the main clinical approaches of bone regeneration for dental implants. **Methods:** The present study followed a systematic review model, following the rules of systematic review – PRISMA. The search strategy was performed in the PubMed, Cochrane Library, Web of Science and Scopus, and Google Scholar databases. The quality of the studies was based on the GRADE instrument and the risk of bias was analyzed according to the Cochrane instrument. **Results:** A total of 142 articles were found. A total of 84 articles were fully evaluated and 33 were included in this study. Literary findings have shown that the lack of bone in the alveolar ridges has been a major problem in functional aesthetic recovery in patients who have suffered dentoalveolar trauma. The osteoinduction process is influenced by several factors, requiring the presence of inducers, which include β -glycerolphosphate, ascorbic acid, and dexamethasone. Mesenchymal stem cells acquire the morphology and components of osteoblastic membranes and begin to express alkaline phosphatase to deposit extracellular matrix rich in calcium and certain proteins, such as osteopontin and osteocalcin. The Bio Oss® (Geistlich) biomaterial, because it is biodegradable, biocompatible, non-toxic, and has low immunogenicity and bio stimulators, can act in the

regeneration of bone tissue. Application of FRP and implant placement provides stable clinical results for severely atrophic maxilla 2-4 mm. Bovine xenograft alone and in combination with liquid FRP are both successful in achieving bone augmentation around implants and produce a small change in marginal bone level and a high implant survival rate after loading.

Conclusion: Through the results of the present study, it was evidenced that the success of the dental implant is directly related to successful osseointegration.

Keywords: Bone regeneration. Molecular and cellular processes. Osseous integration. Dental implants.

Introduction

In the context of bone regeneration, bone defects still represent a major challenge in oral and maxillofacial clinical and surgical treatment. The regeneration of this tissue based on tissue engineering technology has a good prospect of clinical application with the use of scaffolds. In this sense, the biomimetic design of biomaterials by simulating the natural structure and composition of bone tissue has gradually become a point of research interest due to its advantages of simplicity and efficiency [1].

In this scenario, the maxillary sinus is the largest of the paranasal sinuses and its function is to contribute to the resonance of phonation and aid in the production of mucus in the nasal cavity. It also acts in the equalization of barometric pressures in the nasal cavity, which is covered by a membrane called Schneider's membrane. While the goblet cells produce the mucus, these cilia generate movements that cause this mucus to be directed towards the drainage site of the maxillary sinus. In around 25% of all maxillary sinuses, there is an accessory bone located in a lower portion than the

main ostium [2-5].

In this sense, when there is a loss of a dental element in the posterior region of the maxilla, there is natural resorption of the alveolar process and, at the same time, pneumatization of the maxillary sinus occurs. It will increase its volume towards the place where the roots existed and this will often make it difficult or impossible to restore implants in place. For this reason, the maxillary sinus floor elevation procedure should be performed, or short implants when possible [3,4].

Thus, when graft procedures are required, the focus is often on the type of biomaterial to be used and the success and predictability of our results do not depend only on the biomaterial. The morphology will have an impact mainly because the defects have different vascularization capacities, different osteogenic cell recruitment capacities, different natural stabilization capacities of grafts [4].

In addition, several surgical techniques can be used to reconstruct the atrophic alveolar ridge, techniques isolated or associated with autogenous, allogeneic, xenogeneic grafts, and alloplastic biomaterials. The autogenous bone graft is the only one capable of presenting three important biological properties (osteogenesis, osteoinduction, and osteoconduction) guaranteeing a self-regenerative potential. As a disadvantage to the autogenous bone graft, the need for second surgical access in the donor area stands out, resulting in longer surgical time, morbidity, and a consequent greater resistance of the patient to the proposed treatment [4].

Furthermore, alloplastic is synthetic, inorganic, and biocompatible bone substitutes that function as defect fillers to repair skeletal defects, depending on pore diameter and porosity. Calcium phosphate cement and their ceramic variants of β -tricalcium phosphate (β -TCP) and biphasic calcium phosphates (hydroxyapatite (HA) and β -TCP ceramics), calcium sulfate, bioactive glasses, and bone substitutes based on polymers that include polycaprolactone variants. The combination of calcium sulfate and β -TCP provides better material handling. The evidence is in favor of angiogenesis. One such product, EthOss® Regeneration, Silsden, UK, won several international awards as a commercial success [6].

In this context, allogeneic, xenogeneic, and alloplastic bone grafts present themselves as an alternative for the treatment of bone deficiencies in the jaws, since they avoid the need for second surgical access, increasing osteoconduction and cell migration (osteoinduction) [7,8]. Also in this context, platelet concentrates have been proposed as regenerative

materials in tissue regeneration procedures, such as PRP (platelet-rich plasma) and FRP (fibrin-rich plasma) that act as autogenous platelet aggregates with osteoinductive properties. These biomaterials, due to their low morbidity and possible regenerative potential, have been indicated for use in combination with other biomaterials [9].

Besides, the most used xenograft in guided bone regeneration procedures is deproteinized bovine bone mineral, commercially known as Bio-Oss®, it is the most researched product in regenerative dentistry worldwide. It is a bone of bovine origin processed to produce natural bone minerals without organic elements [10]. Due to its great resemblance to human bone, Bio Oss® is incorporated in the natural process of modeling and remodeling. The highly porous structure of Bio Oss® offers plenty of room for the formation of blood vessels (angiogenesis) and the deposit of newly formed bone (osteogenesis) [10,11].

Therefore, the present study aimed to carry out a systematic review of cellular and molecular processes, as well as to present the main clinical approaches of bone regeneration for dental implants.

Methods

Study Design

The present study followed a systematic review model, following the rules of systematic review - PRISMA (Transparent reporting of systematic review and meta-analysis, access available in: <http://www.prisma-statement.org/>).

Data Sources

The search strategy was performed in the PubMed, Cochrane Library, Web of Science and Scopus, and Google Scholar databases. The present study was carried out from January to March 2022.

Descriptors (MeSH Terms)

The main descriptors (MeSH Terms) used were "*Bone regeneration. Molecular and cellular processes. Osseous integration. Dental implants*". For greater specification, the description "bone regeneration" for refinement was added during the searches, following the rules of the word PICOS (Patient; Intervention; Control; Outcomes; Study Design).

Selection of studies and risk of bias in each study

Two independent reviewers (1 and 2) performed research and study selection. Data extraction was performed by reviewer 1 and fully reviewed by reviewer

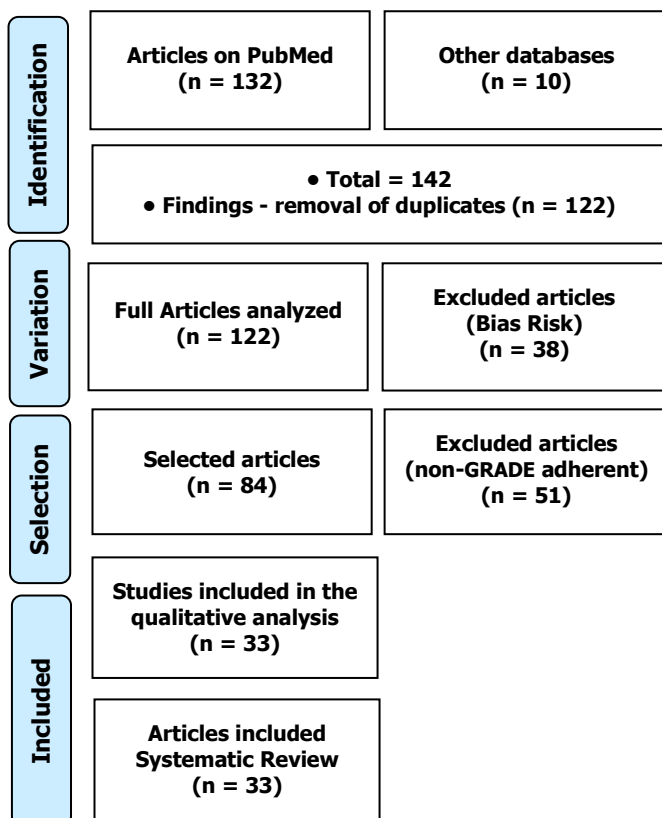
2. A third investigator decided some conflicting points and made the final decision to choose the articles. Only studies reported in English were evaluated. The quality of the studies was based on the GRADE instrument and the risk of bias was analyzed according to the Cochrane instrument.

Results

Article Series and Eligibility

A total of 142 articles were found. Initially, the duplication of articles was excluded. After this process, the abstracts were evaluated and a new exclusion was performed, removing the articles that did not include bone regeneration and dental implant. Articles that presented low quality of scientific evidence according to GRADE, as well as articles that showed research biases, such as a low number of participants and dubious results, were also excluded. A total of 84 articles were fully evaluated and 33 were included in this study (Figure 1).

Figure 1. Article selection (Systematic Review).



Literary findings have shown that the lack of bone in the alveolar crests has been a major problem in functional aesthetic recovery in patients who have suffered dentoalveolar trauma, as well as traumatic tooth extractions, congenital tooth absence, maxillary and mandibular pathologies, in addition to infections due to emotional and the possibility of deformity and

also the economic impact they cause on the National Health System [12,13].

Bone loss can also occur due to periodontal disease, traumatic surgeries, or even for physiological reasons due to lack of adequate or inadequate prosthetic loading [14]. Trauma to the face can affect both soft tissues (skin, muscles, nerves) and hard tissues (bones, teeth), so these injuries can affect the victim's quality of life and health [14].

Still, at the microscopic level, the bone structure consists of osteoprogenitor cells, osteoblasts, osteocytes, osteoclasts (remodeling cells), and a non-mineralized extracellular matrix called osteoid, composed of collagen type I and non-collagen proteins, such as osteonectin, osteocalcin, bone morphogenetic protein (BMP), glycosaminoglycans and bone sialoproteins [15]. Osteoprogenitor cells are small spindle cells found on all non-resorbable bone surfaces, derived from primitive mesenchymal cells and form a population and precursor cells that can differentiate into more specialized cells, such as osteoblasts and osteocytes [15].

Osteoblasts are responsible for the production of bone matrix, rich in collagen (mainly type I) and essential for subsequent mineralization, by the adhesion of hydroxyapatite crystals of calcium, magnesium, potassium, sodium, and carbonate in collagen fibrils [16]. Osteoblasts are also rich in alkaline phosphatase, which has a high value in periods of bone formation. The osteoblast-mediated process of new bone formation is called osteogenesis [15]. It is known that osteoblasts bind directly to collagen through integrin-RDG (-Arg-Gly-Asp-) interaction sites.

The osteoinduction process is influenced by several factors, requiring the presence of inducers, which include β -glycerolphosphate, ascorbic acid, and dexamethasone. In the presence of these substances, mesenchymal cells acquire the morphology and components of osteoblastic membranes and begin to express alkaline phosphatase, to deposit extracellular matrix rich in calcium and certain proteins, such as osteopontin and osteocalcin [16].

Organic phosphates, such as β -glycerolphosphate, promote osteogenesis due to their role in mineralization and modulation of osteoblast activity. Thus, free phosphates can induce mRNA and protein expression, exemplified by the osteopontin protein. If organic phosphate, eg β -glycerol phosphate is present, the formation of mineral content, hydroxyapatite, which is formed between collagen fibers occurs. Other compounds, such as phosphoric ascorbic acid, are also used in osteogenic induction, in the involvement of increased alkaline phosphatase activity, and the promotion of osteocalcin and osteopontin production

[16,17].

Bone morphogenetic proteins (BMP) function as growth factors with a specific role in the proliferation and differentiation of mesenchymal stem cells present in the lesion niche [18]. BMP-4 is involved in the early stages of osteogenesis; Furthermore, it was demonstrated that the differentiation of human mesenchymal stem cells in the osteogenic lineage requires the presence of BMP-4 in the first days of culture and that these cells after 21 days express specific proteins of the osteogenic lineage, such as osteonectin, osteocalcin, and osteopontin [18].

In this way, bioengineering and cell therapy work together for Regenerative Medicine, favoring and improving biological conditions to accelerate tissue repair and regeneration and thus maintain tissue homeostasis. This condition is maintained because the necessary cellular elements, cellular proliferation, differentiation factors, and supramolecular structures are provided, which guarantees the functional stereochemical organization of the generated tissues and their systemic integration [17,19]. In this sense, normal bone formation and tissue restoration involve coordinated interaction between bone-forming cells and biological signals. Osteoblasts can produce new bone together with biomaterials and can initiate the release of biological signals that guide the bone formation and remodeling [12].

These biological signals attract bone-forming cells to the receptor site. Growth factors and other proteins are some biological signals that may be involved in bone neoformation and tissue remodeling. In addition, through chemotaxis, there is a migration of bone-forming cells to the application area, as the stimulation of cell migration occurs in response to chemical stimuli [18].

Monocytes, macrophages, and endothelial cells contribute to bone remodeling, either through contact with osteogenic cells or through the release of soluble factors such as cytokines and GF [19]. In the skeletal system, TNF- α stimulates bone and cartilage resorption and inhibits collagen and proteoglycan synthesis. IL-1 induces the expression of a wide variety of cytokines. LIF and IL-6 are two such molecules that are known to stimulate the differentiation of mesenchymal progenitor cells into the osteoblastic lineage, they are also potent anti-apoptotic agents of osteoblasts. In bone, the main sources of IL-6 are osteoblasts and not osteoclasts. Prostaglandin E2 (PGE2) is also directly related to the expression of the cytokine IL-6 [18].

Also, FRP contributes positively with several cytokines and other growth factors to the bone formation process, acting as a catalyst [20-22]. The most critical phase of the sinus membrane elevation

procedure after osteotomy of the lateral wall of the maxillary sinus is its detachment [23]. At this stage, Schneider's membrane ruptures may occur, around 15.0% of the cases, which, depending on the size of the perforation, may make the graft unfeasible, mainly due to the containment character of the graft material that the membrane exerts [24-26].

Thus, tissue engineering is a tool that allows, through the creation of an adequate biological niche, the construction, and regeneration of many tissues and organs. For this, xenografts, autografts, and allografts are used, with and without the use of cells [27,28]. Thus, the Bio Oss® (Geistlich) biomaterial, as it is biodegradable, biocompatible, non-toxic, and has low immunogenicity and bio stimulators, can act in the regeneration of bone tissue, as it establishes with the adenomatous mesenchymal stem cells the appropriate biological niche (favorable microenvironment) for bone growth [28].

In this context, a study of 60 patients clinically and histologically investigated the potential use of FRP associated with Bio-Oss® deproteinized bovine bone for sinus grafting with severe maxillary atrophy compared to a control group with Bio-Oss® alone. Thus, the use of FRP, together with the "piezosurgery" technique, reduced the healing time to before 150 days, as described in the literature, favoring bone regeneration. Thus, in 106 days it was already possible to obtain good primary stability of the endosteal implants [29].

Another study with 82 patients analyzed the biomechanical stability of the increased sites in the maxillary bone when using a new class of moldable biomaterials with self-leveling calcium phosphate, with and without the addition of FRP in the subperiosteal, also with the use of "piezosurgery". There were significant improvements, with almost double mechanical stability, with the addition of FRP [30].

A retrospective study of 16 patients evaluated the short-term performance of modified maxillary sinus osteotomy with an application of FRP compared with placement of a short implant in cases with a residual bone height of 2-4 mm. All implants were stable, with a survival rate of 100.0%. Six-month follow-up showed a significant reduction in alveolar bone height (2.90 ± 0.22 mm), with $p < 0.05$, without the use of FRP. Furthermore, after the second six-month follow-up, there was even more bone resorption (0.14 ± 0.11 mm) ($p < 0.05$). Therefore, with the application of FRP and placement of implants, stable clinical results were obtained for severely atrophic maxilla with 2-4 mm [31].

Also, another study with 50 patients, aged between 36 and 69 years, evaluated changes in alveolar bone height, using radiographic examination and Straumann implant, with survival rate after maxillary height

increase and sinus elevation with autogenous bone in combination with venous blood platelet-rich plasma (VS), with $n=25$ for each group. Panoramic radiographs were taken preoperatively, immediately, at 6 months and 1 year postoperatively. The results showed a difference in the mean values of bone height between the groups, with $p = 0.001$. Thus, significant differences were also observed between the "immediate", "postoperative" and "six months" phases, $p < 0.01$, for the use of FRP. In the SV group, there were also significant differences ($p=0.0280$) between "postoperative", "immediate" and "six months". Therefore, both groups showed a reasonable increase in alveolar bone height after sinus augmentation, with no significant difference. However, within one year postoperatively, the FRP group had a significant difference compared to the SV group, with more predominant results [32].

Besides, a randomized controlled clinical study evaluated in patients with horizontal bone deficiency in the posterior regions of the mandible the success of augmentation after guided bone regeneration (GBR) performed simultaneously with implant placement using xenograft of bovine origin alone and in combination with rich liquid fibrin in platelets (liquid-FRP). To assess the change in augmentation thickness, the primary outcome of the study, cone-beam computed tomography was performed at the implant sites after completion and 6 months after surgery. Secondary outcomes were marginal bone level and implant survival rate at prosthesis delivery and at 6-month, 1-year, and 2-year follow-up after loading. Twenty patients with 50 implants were analyzed for the test group and 20 patients with 48 implants for the control group. At 6 months postoperatively, the mean values of thickness of increase were 1.63 ± 0.21 mm, 2.59 ± 0.34 mm and 3.11 ± 0.36 mm for the test group and 1.34 ± 0.14 mm, 2.49 ± 0.24 mm and 2.97 ± 0.24 mm for the control group at 2 mm, 4 mm and 6 mm below the implant shoulder ($p < 0.001$, $p = 0.007$ ep = 0.036, respectively). Mean marginal bone loss was less than 1 mm for both study groups during the 2-year follow-up after prosthetic loading. The implant survival rate was 100% for both study groups. Therefore, bovine xenograft alone and in combination with liquid FRP are both successful in achieving bone augmentation around implants and produce a small change in marginal bone level and a high implant survival rate after loading [33].

Conclusion

Through the results of the present study, it was evidenced that the success of the dental implant is directly related to osseointegration. However, this is a

complex process with many factors interfering with the formation and maintenance of bone tissue around the implant. In addition, a healthy, compatible host bone layer that allows primary stability is required. It is essential that the dentist master the knowledge in the healing process of post-extraction sockets, in order to provide correct planning of the cases. Thus, the development of bone regeneration improves the epithelial barriers for the bone graft, favoring greater predictability in alveolar and peri-implant reconstructions and presenting a good prognosis. The optimized processes of implantology and biomaterials allow the installation of implants in areas of low bone thickness, width, and height, with simpler surgeries and with a higher rate of success and patient comfort.

Acknowledgement

Not applicable.

Funding

Not applicable.

Ethics approval

Not applicable.

Informed consent

Not applicable.

Data sharing statement

No additional data are available.

Conflict of interest

The authors declare no conflict of interest.

Similarity check

It was applied by Ithenticate@.

About the License

© The authors (s) 2022. The text of this article is open access and licensed under a Creative Commons Attribution 4.0 International License.

References

1. Jiang XQ. Advances in biomimetic modification of materials for oromaxillofacial bone regeneration and dental implant]. Hua Xi Kou Qiang Yi Xue Za Zhi. 2021 Apr 1;39(2):123-128. Chinese. doi: 10.7518/hxkq.2021.02.001. PMID: 33834665; PMCID: PMC8055768.
2. Zaki J, Yusuf N, El-Khadem A, Scholten RJPM, Jenniskens K. Efficacy of bone-substitute

- materials use in immediate dental implant placement: A systematic review and meta-analysis. *Clin Implant Dent Relat Res*. 2021 Aug;23(4):506-519. doi: 10.1111/cid.13014. Epub 2021 Jun 12. PMID: 34118175; PMCID: PMC8453723.
3. Almansoori AA, Kwon OJ, Nam JH, Seo YK, Song HR, Lee JH. Mesenchymal stem cells and platelet-rich plasma-impregnated polycaprolactone- β tricalcium phosphate bio-scaffold enhanced bone regeneration around dental implants. *Int J Implant Dent*. 2021 May 5;7(1):35. doi: 10.1186/s40729-021-00317-y. PMID: 33948811; PMCID: PMC8096877.
 4. Gugliandolo A, Fonticoli L, Trubiani O, Rajan TS, Marconi GD, Bramanti P, Mazzon E, Pizzicannella J, Diomedede F. Oral Bone Tissue Regeneration: Mesenchymal Stem Cells, Secretome, and Biomaterials. *Int J Mol Sci*. 2021 May 15;22(10):5236. doi: 10.3390/ijms22105236. PMID: 34063438; PMCID: PMC8156243.
 5. Mazzoneto, R. Reconstruções em Implantodontia – Protocolos clínicos para o sucesso e a previsibilidade. Ed. Napoleão, 2009, 1ª Edição. Nova Odessa – SP, Brasil.
 6. Cheah CW, Al-Namnam NM, Lau MN, Lim GS, Raman R, Fairbairn P, Ngeow WC. Synthetic Material for Bone, Periodontal, and Dental Tissue Regeneration: Where Are We Now, and Where Are We Heading Next? *Materials (Basel)*. 2021 Oct 15;14(20):6123. doi: 10.3390/ma14206123. PMID: 34683712; PMCID: PMC8537464.
 7. Nícoli LG, Pigossi SC, Araújo RFdSB, Marcantonio C, Marcantonio E, Marcantonio JR. E. Multidisciplinary approach to oral rehabilitation with dental implants after gunshot injury. A clinical report. *The Journal of Prosthetic Dentistry*. 2018; 119 (3): 329 – 33.
 8. Zhao R, Yang R, Cooper PR, Khurshid Z, Shavandi A, Ratnayake J. Bone Grafts and Substitutes in Dentistry: A Review of Current Trends and Developments. *Molecules*. 2021 May 18;26(10):3007. doi: 10.3390/molecules26103007. PMID: 34070157; PMCID: PMC8158510.
 9. Dohan DM, Choukroun J, Diss A, Dohan SL, Dohan AJJ, Mouhyi J, et al. Platelet-rich-fibrin (FRP); A second generation concentrate. Part I: Technological concepts and evolution. *Oral Sugery, Oral Medicine, Oral Pathology, Oral Radiology and Endodontology*. 2006; 101 (3): e 37- e 44.
 10. Xuan F, Lee CU, Son JS, Jeong SM, Choi BH. A comparative study of the regenerative effect of sinus bone grafting with platelet-rich fibrin-mixed Bio-Oss® and commercial fibrin-mixed Bio-Oss®: an experimental study. *J Craniomaxillofac Surg*. 2014 Jun;42(4):e47-50. doi: 10.1016/j.jcms.2013.05.029. Epub 2013 Aug 2].
 11. Moreira AC, Silva JR, Samico RP, Nishioka GNM, Nishioka RS. Application of Bio-Oss in tissue regenerative treatment prior to implant installation: literature review. *Braz Dent Sci*. 2019, 22(2).
 12. Calasans MD, Fernandes GVO, Granjeiro JM. Preservação alveolar com enxertos após exodontias e previamente à instalação de implantes. *Revista Implantnews*, 2011, 6: 583-590.
 13. Fardin AC et al. Enxerto Ósseo em Odontologia: Revisão de Literatura. *Innov Implant J, Biomater Esthet, São Paulo*, 2010, 5 (3): 48-52.
 14. Fontanari LA; Manne JM; Junior WT. Utilização de enxerto homogêneos para reconstrução em áreas atroficas pré-implante: banco de ossos. *Revista Implantnews*, 2007, 5 (6) : 539-597.10
 15. Aubin JE, Liu F. The osteoblast lineage. In: Bilizekian, J., Raisz, L., and Rodan, G., editors. *Principles of Bone Biology*. San Diego, CA: Academic Press: 1996, 39-50.
 16. Nardi NB, Meirelles SL. Mesenchymal stem cells: isolation, in vitro expansion and characterization. *HEP* 2006; 174 : 249-82.
 17. Vacanti JP, Langer R. Tissue engineering: The design and fabrication of living replacement devices for surgical reconstruction and transplantation. *Lancet*,1999; 354: 32–34.
 18. Mesimäki K, Lindroos B, Törnwall J, Mauno J, Lindqvist C, Kontio R, Miettinen S, Suuronen R: Novel maxillary reconstruction with ectopic bone formation by GMP adipose stem cells. *Int J Oral Maxillofac Surg* 2009, 38 : 201-209.
 19. Zotarelli Filho IJ, Frascino LF, Greco OT, Araujo JDD, Bilaqui A, Kassis EN, Ardito RV and Bonilla-Rodriguez GO. Chitosan-collagen scaffolds can regulate the biological activities of adipose mesenchymal stem cells for tissue engineering. *J Regen Med Tissue Eng*. 2013; 2:12. <http://dx.doi.org/10.7243/2050-1218-2-12>.
 20. Ehrenfest, D., Rasmusson, L. e Albrektsson, T. Classification of platelet concentrates: from pure platelet-rich plasma (P-PRP) to leucocyte- and platelet-rich fibrin (L-FRP). *Cell Press*, 2009; 27.
 21. Lopez-Vidriero, E., et al. The use of platelet-rich plasma in arthroscopy and sports medicine: optimizing the healing environment. *Arthroscopy*, 2010; 26:269-278.

- 22.** Lynch, S., et al. The Effects of Short-Term Application of a Combination of Platelet-Derived and Insulin-Like Growth Factors on Periodontal Wound Healing. *Journal of Periodontology*, 1991; 62:458-467.
- 23.** Messoria M et al. Análise da eficiência do protocolo de dupla centrifugação para o preparo do plasma rico em plaquetas (PRP) – estudo experimental em coelhos. *RSBO- Revista Sul-Brasileira de Odontologia*, 2010; 6:291-296.
- 24.** Messoria M., et al. A standardized research protocol for platelet-rich plasma (PRP) preparation in rats. *Revista Sul-Brasileira de Odontologia*, 2011; 8:299-304.
- 25.** Perez M, et al. Relevant Aspects of Centrifugation Step in the Preparation of Platelet-Rich Plasma. *International Scholarly Research Notices of Hematology*, 2014; 8:1-8.
- 26.** Tejero R, Anitua E, Orive G. Toward the biomimetic implant surface: Biopolymers on titanium-based implants for bone regeneration. *Journal of Progress in Polimeral Science*, 2014; 39:1406-1447.
- 27.** Liu Y, Clark RAF, Huang L, Rafailovich MH. Hyaluronic acid-gelatin fibrous scaffold produced by electrospinning of their aqueous solution for tissue engineering applications. In *Advances in Material Design for Regenerative Medicine, Drug Delivery and Targeting/ Imaging* 2010; 1140:131-136.
- 28.** Maiorana C, Sommariva L, Brivio P, Sigurtà D, Santoro F. Maxillary sinus augmentation with anorganic bovine bone (Bio-Oss®) and autologous platelet-rich plasma: preliminary clinical and histologic evaluations. *Int J Periodontics Restorative Dent* 2003 Jun;23 (3): 227-235.
- 29.** Tatullo M, Marrelli M, Cassetta M, Pacifici A, Stefanelli LV, Scacco S, Dipalma G, Pacifici L, Inchingolo F. Platelet Rich Fibrin (P.R.F.) in Reconstructive Surgery of Atrophied Maxillary Bones: Clinical and Histological Evaluations. *International Journal of Medical Sciences*. 2012; 9(10):872-880. doi: 10.7150/ijms.5119.
- 30.** Angelo T, Marcel W, Andreas, K, Izabela, S. Biomechanical Stability of Dental Implants in Augmented Maxillary Sites: Results of a Randomized Clinical Study with Four Different Biomaterials and FRP and a Biological View on Guided Bone Regeneration. *Hindawi Publishing Corporation BioMed Research International*, 2015, <http://dx.doi.org/10.1155/2015/850340>.
- 31.** Chen, Y, Cai,Z, Zheng, D, Lin,P, Cai,Y, Hong, S, Lai & Dong Wu, Y. Inlay osteotome sinus floor elevation with concentrated growth factor application and simultaneous short implant placement in severely atrophic maxilla. *Scientific Reports* 2016, 6:27348 DOI: 10.1038/srep27348.
- 32.** Kumar, NK, Shaik ,M, Rao Nadella,K, Chintapalli, BM. Comparative Study of Alveolar Bone Height and Implant Survival Rate Between Autogenous Bone Mixed with Platelet Rich Plasma Versus Venous Blood for Maxillary Sinus Lift Augmentation Procedure. *J. Maxillofac. Oral Surg.* (Apr–June 2015) 14(2):417–422 DOI 10.1007/s12663-014-0643-7.
- 33.** Işık G, Özden Yüce M, Koçak-Topbaş N, Günbay T. Guided bone regeneration simultaneous with implant placement using bovine-derived xenograft with and without liquid platelet-rich fibrin: a randomized controlled clinical trial. *Clin Oral Investig.* 2021 Sep;25(9):5563-5575. doi: 10.1007/s00784-021-03987-5. Epub 2021 May 28. PMID: 34047835.

