



Clinical approaches and removal of cast metallic posts for their replacement by the fiberglass posts: a concise systematic review

Débora Stefanini de Oliveira^{1,2*}, Giulia Viana Alvarenga^{1,2}, Carla Roberta Pamplona Bossa^{1,2}, Ana Paula Bernardes Rosa Maluf^{1,2}, Leandro Moreira Tempest^{1,2}, Carlos Alberto Costa Neves Buchala^{1,2}

¹ UNORTE - University Center of Northern São Paulo - Dentistry department, Sao Jose do Rio Preto, Sao Paulo, Brazil.

² UNIPOS - Post graduate and continuing education, Dentistry department, Sao Jose do Rio Preto, Sao Paulo, Brazil.

*Corresponding author: Débora Stefanini de Oliveira.

Unorte/Unipos – Graduate and Postgraduate in dentistry, Sao Jose do Rio Preto, Sao Paulo, Brazil.

E-mail: deborastefanini@hotmail.com

DOI: <https://doi.org/10.54448/mdnt22S302>

Received: 02-16-2022; Revised: 04-20-2022; Accepted: 04-21-2022; Published: 05-04-2022; MedNEXT-id: e22S302

Highlights

- ✓ The choice of technique for removing posts must be specific;
- ✓ For the removal of metallic posts, wear, ultrasound, and seizure/removal with some traction device are used;
- ✓ Fiber posts fractured in the canal, normally absorb ultravibration and therefore rotary instruments are more suitable for its removal;
- ✓ It is a safe procedure when indicated and executed correctly, sensitive to technique and operator (knowledge and experience), and in some cases, it may take a long time for removal;
- ✓ In cases where no technique can be applied, there is the option of paraendodontic surgery or tooth extraction.

Abstract

Introduction: A successful placement of an intraradicular post needs a good endodontic treatment. Consideration should also be given to the possibility of its future removal. Authors have shown that approximately 10% of cases of teeth indicated for endodontic retreatment require removal of intraradicular posts. **Objective:** To carry out a concise systematic review to analyze the reasons for replacing intraradicular posts, the most effective and used techniques for removing the metallic post, the manufacture of the fiberglass post, and the difference between the two types of posts. **Methods:** The present study followed a systematic review model, following the rules of systematic review – PRISMA. The search strategy was performed in the PubMed, Cochrane

Library, Web of Science and Scopus, and Google Scholar databases. **Results and Conclusion:** A total of 112 articles were found. A total of 56 articles were fully evaluated and 18 were included in this study. Based on the objective and results found in the present study, the review demonstrated the main advantages and disadvantages of the clinical performance of cast metal posts and fiberglass posts, as well as the reason for switching from metal to fiberglass posts. Despite the wear caused by endodontic treatment, it is important to check the remaining dentin to choose the best retainer, observing the amount of this remaining structure, as it directly influences the selection of the post. Regarding the removal of the metallic pin, wear, ultrasound, and seizure/removal with some traction device are used. The replacement of the metallic post can opt for fiberglass posts because they have a greater advantage compared to the metallic post, mainly for aesthetics, the manufacturing technique is more agile, they do not generate risks of root fracture and if, for any eventuality, it needs to be removed. to portray the channel, the technique is smooth and easy.

Keywords: Metal posts. Fiberglass posts. Intra-radicular posts. Removal Techniques. Aesthetics. Removal metal posts.

Introduction

Teeth with endodontic treatments, in most cases, present extensive loss of tooth structure, greater fragility due to the loss of dentin by instrumentation, and, consequently, greater risk of fracture [1]. For this fatality not to occur, intra-radicular posts are indicated, which are devices to improve the aesthetic function, the

retention of direct or indirect restorations, and promote greater resistance to fracture of the remnant, thus, it has gained importance in dental offices [2,3].

In this context, for the placement of an intraradicular post, a well-done endodontic treatment is needed, which does not present a periapical lesion and allows 4 mm of apical sealing [4]. The use of this mechanism leads to the probability of its removal at some point in life, mainly for endodontic retreatment, due to poorly performed root canal treatment, failed biomechanical preparation, and non-obturation and non-instrumentation of canals [5].

In this aspect, when an intraradicular post is used, the possibility of its future removal must also be taken into account, mainly due to periapical alterations of endodontic origin. Authors have shown that approximately 10% of cases of teeth indicated for endodontic retreatment require removal of intraradicular posts [6]. Paraendodontic surgery is an option for resolving periapical pathologies without removing the post and endodontic retreatment, which may have local and systemic contraindications and an unfavorable prognosis. The use of techniques that employ traction with different devices, wear with rotary instruments and ultrasonic vibration are choices with a good chance of success when choosing to remove the posts. Its success rate is linked to biological biocompatibility, dimensional stability, non-corrosive, radiopacity, and low cost [7].

In this scenario, the possibilities for endodontic retreatment are conventional and para-endodontic surgery, but it is better to choose conventional surgery, as it has shown higher success rates over the years than surgery and managed to eliminate intracanal contamination, which is the most common reason for infection [8]. This removal can also be for reasons of caries between post and tooth. To remove it can lead to possible risks of root fracture, due to 3 factors such as wide posts, thin root structure, and attempted removal at an angle opposite to its direction of incorporation. The biggest difficulties of this practice are the length, shape, type, and diameter of the post, the cement used, the capacity of the professional, and the resources available [9].

Besides, cast metal posts are widely used because they exhibit clinical success, correct adaptation, and high rigidity, however, they are not aesthetic and cause great stress on the remainder and thus possible fracture risks. As they present an intraradicular preparation with a greater amount of structural loss for its placement, it leads to a decrease in the resistance of the tooth. Devices and drills can be used to remove the molten metallic pin, its removal occurs for the same reasons

mentioned above. Its replacement can opt for fiberglass posts as they have a greater advantage compared to metallic posts, mainly due to aesthetics, the manufacturing technique is more agile, they do not generate risks of root fracture and if for any eventuality, it needs to be removed to retract the canal, the technique is smooth and easy [6,8].

Therefore, the present study aimed to carry out a concise systematic review to analyze the reasons for replacing intraradicular posts, the most effective techniques used to remove the metallic post, the manufacture of the fiberglass post, and the difference between the two types of posts.

Methods

Study Design

The present study followed a systematic review model, following the rules of systematic review - PRISMA (Transparent reporting of systematic review and meta-analysis, access available in: <http://www.prisma-statement.org/>).

Data Sources

The search strategy was performed in the PubMed, Cochrane Library, Web of Science and Scopus, and Google Scholar databases. The present study was carried out from January to March 2022.

Descriptors (MeSH Terms)

The main descriptors (MeSH Terms) used were "Metal posts. Fiberglass posts. Intra-radicular posts. Removal Techniques. Aesthetics". For greater specification, the description "Removal metal posts" for refinement was added during the searches, following the rules of the word PICOS (Patient; Intervention; Control; Outcomes; Study Design).

Selection of studies and risk of bias in each study

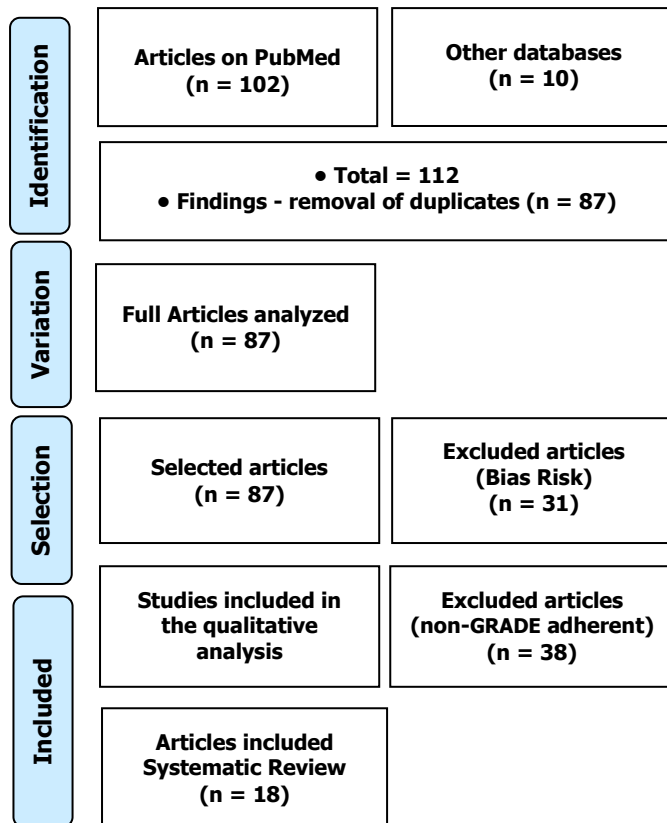
Two independent reviewers (1 and 2) performed research and study selection. Data extraction was performed by reviewer 1 and fully reviewed by reviewer 2. A third investigator decided some conflicting points and made the final decision to choose the articles. The quality of the studies was based on the GRADE instrument and the risk of bias was analyzed according to the Cochrane instrument.

Results and Discussion

A total of 112 articles were found. Articles that presented low-quality scientific evidence according to GRADE, as well as articles that showed research biases,

such as a low number of participants and dubious results were also excluded. A total of 56 articles were fully evaluated and 18 were included in this study (Figure 1).

Figure 1. Article selection (Systematic Review).



After analyzing the literary findings, it became clear that the main purpose of using posts or cores in endodontics is the replacement of lost tooth structure that facilitates the support and retention of the crown. The posts used in dentistry, whether metallic or fiberglass, are structures that support the retention of restorations. These are alternatives widely used by dentists and, in this way, the numerous researches in the area develop posts of different materials [10].

Thus, metallic posts are prefabricated or customized structures, which are cemented in endodontically treated teeth, in order to increase the retention of restorations. The more juxtaposed and fitted the pin, it will have greater stability. Metal posts have a high modulus of elasticity (more rigid).

Main Indications of Metallic Posts [10]:

- ✓ Endodontically treated teeth, with significant loss of coronal structure (greater than 50%) and noble structures, such as marginal ridges and pulp chamber roof. The loss of these structures leads to an increase in the deflection of the cusps and remaining coronary structures leading to fracture;

- ✓ The posterior teeth receive forces in the vertical direction, eliminating the use of intra-radicular posts in adhesive restorations. However, when the coronary loss is very extensive, an indirect metal post should be indicated, to provide retention to prosthetic crowns;
- ✓ On the other hand, on the anterior teeth the forces impinge obliquely and horizontally. The intraradicular post dissipates forces along the coronal portion and root, preventing fracture;
- ✓ In teeth responsible for disocclusion guide such as canines, posts are recommended. Patients with parafunctional habits tend to use a lot of shear force, which contributes to the indication of the pin to dissipate stress.

Contra-indications of the Metal Posts:

- ✓ Dilacerated canals compromise the insertion of the pin at adequate depth;
- ✓ Very dilated canals that have little dentin on the root walls require the use of resin to reinforce the walls prior to the installation of the intra-canal post;
- ✓ Number of clinical steps for application of the adhesive system (acid, primer and adhesive);

Prefabricated fiber posts reduce the incidence of root fractures compared to prefabricated metallic or conventional metallic posts. Fiber systems are cemented with adhesive systems, preferably dual or chemically activated adhesives.

Main Advantages [11]:

- ✓ Increases root strength;
- ✓ The modulus of elasticity is similar to that of dentin, presenting greater resistance to fatigue. Different from metallic posts, which can generate areas of stress concentration, which can cause, as a consequence, cracks and fractures in the dental structure;
- ✓ Less stress on the root structure;
- ✓ Lower risk of root fracture.

Disadvantages:

- ✓ Higher risk of marginal leakage at the tooth-restoration interface [12].

Removal of Posts - Criteria

According to some authors [4,6], the teeth recommended for post removal are those endodontically treated with indication for reintervention. Those that are usually associated with apical lesions, which present signs and symptoms of inflammation, another criterion

that influences the removal is the type of tooth, its location in the arch, accessibility and good visualization of the operative field, which are extremely important criteria [13].

Also, removal is associated with several variables in relation to the post, such as the type of post, cast or prefabricated, shape: conical or parallel (with parallels resisting 4.5 times more traction than conicals), surface smooth, serrated or rough, thin or voluminous volume (very voluminous ones, when they occupy more than two thirds of the length of the tooth and are well adapted, can generate risks during the removal attempt), short or long length [13].

Regarding the material, the noble or non-noble alloy, titanium or reinforced fiber, regarding the cementing agent zinc phosphate, glass ionomer or resin-based types of cement, regarding the adaptation: well or poorly adapted to the thickness of the agent. cement used [14].

Also, the posts that are more difficult to remove are those that are positioned along the axis of the channel in a parallel or slightly conical shape, voluminous, with rough surfaces, and which are cemented by a small line of a cementing agent. Generally, posts that are cemented with resin-based types of cement require more time to remove than those cemented with zinc phosphate and glass ionomer [14].

Removal Risks

Removing posts should take into account the length and size of the root. Inadequate preparation for the placement of the post can cause the root walls to become thin and cracks to occur, or there is a risk of apical or lateral perforation when the diameter of the post is too large. Note the importance of anatomical knowledge of the root and radiographic evaluation to make the best planning and avoid damage to the root [15].

According to Mesquita and Kunert (2006) [16], when the patient reports hearing a 'click', the fracture may have occurred at the time of removal of the pin. Visually around the fracture or fissure, there will be no blood or pigmentation around it. When the fracture occurred a few days earlier, there is a dark pigmentation of the dentin around the fracture.

Removal Techniques

In this scenario, there are several techniques and instruments for removing intraradicular posts, namely: rotary instruments, ultrasound equipment, metallic post extractors, and special grasping forceps. Each technique is used according to the type of post in question and its need for removal [6].

Besides, the association of techniques for removing intraradicular retainers has shown greater efficiency when compared to isolated techniques, promoting greater safety and predictability. The technique performed by ultrasound vibration facilitates the fragmentation of the existing cement between the post and the canal walls, facilitating the subsequent traction force removal technique that will be used [17].

Still, some authors evaluated the isolated or associated application of wear and ultrasonic vibration on the remaining cement line or the coronal portion of the core, in the force exerted to remove the intracanal fused post in Nickel-Chromium cores, cemented with zinc phosphate. It was concluded that the associated form is better than the isolated form. Among the types of associated techniques, the one that presented the greatest effectiveness and safety was the use of wear, application of ultrasonic vibration in the cement line, and traction for the removal of the intraradicular post [18].

Also, ultrasound promotes the breakage of the cement between the prosthesis and the tooth structure, but it can be used in association with a hammer with a guide or prosthesis bag to break the frictional retention of the preparations. Impact hammers are capable of displacing prosthesis artifacts through controlled movements in a direction of force and impact pressure of the guide hammer plunger, as they have tips with different adaptive curvatures for removal [18].

After removing the post, an adequate cleaning must be carried out, removing the cement remains and dirt with the use of passive ultrasonic irrigation. The integrity of the canal walls is observed and deviations or wear that may prevent the correct restoration of the tooth is made. It should be analyzed if there are any problems such as root perforations and/or vertical fracture lines of the root to indicate the most appropriate treatment, which may be endodontics, extraction, or replacement of the post [6].

Besides, when the removal device is placed in contact with the dentin, it produces a tension in it that takes 24 hours to recover its normality, therefore, right after the removal of the post, it is not indicated to start an endodontic or prosthetic treatment, so that it does not occur. spontaneous fracture in dentin [1-3]. After removing the post, during canal retreatment or making a new prosthetic piece, it is extremely important to correctly clean the inner portion of the provisional, which can be cleaned with ultrasound tips, which facilitate the removal of the cement [16]. Also, the ultrasonic technique used to remove the posts generates heat when constant irrigation is not used. This increase in temperature causes damage to the periodontium and adjacent structures, and necrosis, bone resorption, and ankylosis may occur [18].

Conclusion

Based on the objective and results found in the present study, the review demonstrated the main advantages and disadvantages of the clinical performance of cast metal posts and fiberglass posts, as well as the reason for switching from metal to fiberglass posts. Despite the wear caused by endodontic treatment, it is important to check the remaining dentin to choose the best retainer, observing the amount of this remaining structure, as it directly influences the selection of the post. Regarding the removal of the metallic pin, wear, ultrasound, and seizure/removal with some traction device are used. The replacement of the metallic post can opt for fiberglass posts because they have a greater advantage compared to the metallic post, mainly for aesthetics, the manufacturing technique is more agile, they do not generate risks of root fracture and if, for any eventuality, it needs to be removed. to portray the channel, the technique is smooth and easy.

Acknowledgement

Not applicable.

Ethics approval

Not applicable.

Informed consent

Not applicable.

Funding

Not applicable.

Data sharing statement

No additional data are available.

Conflict of interest

The authors declare no conflict of interest.

Similarity check

It was applied by Ithenticate@.

About the License

© The authors (s) 2022. The text of this article is open access and licensed under a Creative Commons Attribution 4.0 International License.

References

1. Brezinsky S, Bowles W, McClanahan S, Fok A, Ordinola-Zapata R. In Vitro Comparison of Porcelain Fused to Metal Crown Retention after Endodontic Access and Subsequent Restoration: Composite, Amalgam, Amalgam with Composite Veneer, and Fiber Post with Composite. *J Endod.* 2020 Nov;46(11):1766-1770. doi: 10.1016/j.joen.2020.08.009. Epub 2020 Aug 17. PMID: 32818565.
2. Papalexopoulos D, Samartzi TK, Sarafianou A. A Thorough Analysis of the Endocrown Restoration: A Literature Review. *J Contemp Dent Pract.* 2021 Apr 1;22(4):422-426. PMID: 34267013.
3. Al-Dabbagh RA. Survival and success of endocrowns: A systematic review and meta-analysis. *J Prosthet Dent.* 2021 Mar;125(3):415.e1-415.e9. doi: 10.1016/j.prosdent.2020.01.011. Epub 2020 Mar 18. PMID: 32197821.
4. Albuquerque RDC, Alvim HH. Posts pré-fabricados e núcleos de preenchimento. In: Mendes WB, Miyashita E, et al. (Ed.). *Reabilitação Oral: Previsibilidade e longevidade.* São Paulo: Editora Napoleão, 2011. cap. 15, p.393- 418.
5. de Moraes Melo Neto CL, Costa GT, Lorga T, Santin GC, Mondelli J, Sabio S. Effect of using the New Glass Fiber Pin in Resin Composite Restorations. *J Contemp Dent Pract.* 2018 May 1;19(5):541-545. PMID: 29807964.
6. Zuolo ML. et al. *Remoção de posts: protocolos clínicos.* 1 ed. São Paulo: Quintessence editora, 2016.
7. da Costa Fartes OA, de Resende LM, Cilli R, do Carmo AMR, Baroudi K, Cortelli JR. Retention of Provisional Intraradicular Retainers Using Fiberglass Posts. *J Int Soc Prev Community Dent.* 2020 Sep 28;10(5):666-673. doi: 10.4103/jispcd.JISPCD_298_20. PMID: 33282778; PMCID: PMC7685286.
8. Azambuja TWFD, Bercini F, Alano F. Cirurgia paraendodôntica: revisão da literatura e apresentação de casos clínico-cirúrgicos. 2006. 24-29 (47). *Revista da Faculdade de Odontologia de Porto Alegre.*
9. Andrade SA. Cast metal posts versus glass fibre posts: which treatment of choice based on cost-minimisation analysis? *Evid Based Dent.* 2021 Dec;22(4):128-129. doi: 10.1038/s41432-021-0226-7. Epub 2021 Dec 16. Erratum in: *Evid Based Dent.* 2022 Mar;23(1):5. PMID: 34916635.
10. Skupien JA, Cenci MS, Opdam NJ, Kreulen CM, Huysmans MC, Pereira-Cenci T. Crown vs. composite for post-retained restorations: A randomized clinical trial. *J Dent.* 2016 May;48:34-9. doi:

- 10.1016/j.jdent.2016.03.007. Epub 2016 Mar 11. PMID: 26976553.
11. Figueiredo FE, Martins-Filho PR, Faria-E-Silva AL. Do metal post-retained restorations result in more root fractures than fiber post-retained restorations? A systematic review and meta-analysis. *J Endod.* 2015 Mar;41(3):309-16. doi: 10.1016/j.joen.2014.10.006. Epub 2014 Nov 11. PMID: 25459568.
 12. Sarkis-Onofre R, Jacinto RC, Boscato N, Cenci MS, Pereira-Cenci T. Cast metal vs. glass fibre posts: a randomized controlled trial with up to 3 years of follow up. *J Dent.* 2014 May;42(5):582-7. doi: 10.1016/j.jdent.2014.02.003. Epub 2014 Feb 12. PMID: 24530920.
 13. Braga NM, Paulino SM, Alfredo E, Sousa-Neto MD, Vansan LP. Removal resistance of glass-fiber and metallic cast posts with different lengths. *J Oral Sci.* 2006 Mar;48(1):15-20. doi: 10.2334/josnusd.48.15. PMID: 16617196.
 14. Zuolo ML. et al. *Reintervention in Endodontics.* 1 ed. São Paulo: Quintessence editora, 2014.
 15. Mazaro JVQ. et al. Fatores determinantes na seleção de posts intraradiculares. *Revista Odontologia UNESP*, v. 35, n. 4, p. 223-31, 2006.
 16. Mesquita E, Kunert IR. *O ultra-som na Prática Odontológica.* Porto Alegre: Artmed Editora, 2006. ISBN 8536315040.
 17. Pantoja CADMS. et al. Remoção de retentores metálicos intraradiculares com o Saca-posts M&V: relato de casos clínicos. *RPG Revista de Pós-Graduação*, v. 18, n. 4, p. 260-265, 2011. ISSN 0104-5695.
 18. Berbert F. et al. Efeito do desgaste da linha de cimento, da vibração ultra-sônica e da associação de ambas sobre a força de tração empregada na remoção de posts intraradiculares. *Rev Odontol UNESP*, v. 31, n. 2, p. 215-29, 2002.